

## Case Report

# Treatment of hematuria caused by renal arteriovenous malformation in pregnant patients

Yuedong Chen, Fei Liu, Jinchun Xing, Rongfu Liu

*Department of Urology and Center of Urology, The First Affiliated Hospital of Xiamen University, Xiamen 361003, P. R. China*

Received December 3, 2014; Accepted January 29, 2015; Epub February 15, 2015; Published February 28, 2015

**Abstract:** This study is to investigate hematuria in pregnant patients caused by renal arteriovenous malformation and to evaluate the efficacy of superselective renal angiography and embolization used for treatment of renal arteriovenous malformation. Two cases of hematuria in pregnant patients caused by renal arteriovenous malformation were enrolled. Case 1 was a 28-year-old woman with repeatedly intermittent hematuria at week 7 during gestation. Case 2 was a 30-year-old woman with repeatedly intermittent hematuria at week 8 during gestation. B ultrasound and CT were performed to detect hydronephrosis. Renal arteriovenous malformation was diagnosed by selective angiography. Both the patients were treated with embolization. The 2 cases were successfully embolized with different materials including gelfoam and coils. Both of the 2 patients were recovered well and discharged successful after the operation. In conclusion, superselective renal angiography and embolization are effective methods for diagnosis and treatment of renal arteriovenous malformation in pregnant patients.

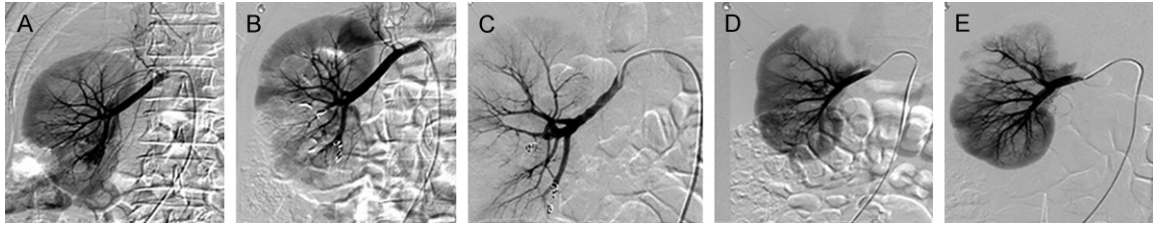
**Keywords:** Renal arteriovenous malformation, pregnancy, hematuria

## Introduction

Renal arteriovenous malformation is more common in females than in males and more frequently diagnosed in right kidney than in left kidney of people at the 30-40 years of age [1]. Renal arteriovenous malformation is a rare disease, with an incidence of about 0.04%. Renal arteriovenous malformation leading to hematuria in pregnant patients has an incidence of less than 0.04%, with only few cases reported in pregnant women so far [2]. The clinical manifestations of renal arteriovenous malformation mainly include gross hematuria, urinary retention, and lumbar pain. Renal arteriovenous malformation can be divided into two major categories, the congenital and acquired renal arteriovenous malformation. Acquired renal arteriovenous malformation includes traumatic, iatrogenic, neoplastic, inflammatory, idiopathic, or spontaneous types [3]. Due to the incomplete structure of arteriovenous malformations, various degrees of hyaline even occur in some vessels, leading to easy rupture and bleeding of dysplastic vessels. The hyperdynamic circulatory state in pregnant patients makes abnor-

mal blood vessels prone to rupture, easily resulting in hematuria. The gross bleeding often causes blood clots filling in the bladder, leading to difficulty in urinating or even the hydronephrosis of kidney. Progressive decreased hemoglobin usually occurs in the patients, and the blockage of ureters caused by blood clots results in the lumbar pain and even renal colic in patients. B ultrasound inspection can help to detect the blood clots in the bladder, and urinary system CT examination can help to determine the hematocele of kidneys or ureters. CT also assists to exclude calculus, tumors, and other causes of hematuria [4].

Renal angiography is still the gold standard of diagnosis for renal arteriovenous malformation. Renal arteriography can directly and comprehensively display the location, shape, number, blood supply, and changes in hemodynamics [5]. However, as renal arteriography is radioactive, it is a contraindicated inspection item for pregnant women [6]. The 2 pregnant cases in this study with obvious hematuria and progressive decreased hemoglobin were treated with conservative treatment, which was not effec-



**Figure 1.** Two cases. A-C. Case 1. A. Before the embolization, angiography showed clear arteriovenous shunt in lower pole artery of right kidney. Two superselective microcatheters were used for the blood supply artery. Micro-coils including 2 MWCE-18S-3/2-TORNADO and 1 MWCE-18S-4/2-TORNADO were inserted for embolization and a small amount of gelatin sponge was injected. B, C. After embolization, the angiography was performed. The malformation disappeared. The remnants substance of the right kidney and renal blood flow showed no abnormalities. Abnormal tortuous small vessels were still visible in the lower pole, but no obvious abnormalities triage and contrast agent extravasation detectible. D, E. Case 2. D. The gross arteriovenous regurgitation was observed in the central of right kidney, and superselective microcatheters were used for the blood supply artery. Gelatin sponge and one tower-shaped micro-coil were inserted for embolization. E. The angiography after embolization showed that the malformation disappeared.

tive. Therefore, they were treated with renal arteriography.

## Case report

Case 1 (Figure 1A-C) was a 28-year old pregnant patient with intermittent hematuria in week 7 during gestation, accompanied by the right side lumbar pain. B ultrasound inspection found that the size of heterogeneous focus in bladder was about  $8.6 \times 5.2$  cm, which was possibly a blood clot. Urinary System CT found hydronephrosis of the right kidney and hematocele of the right pelvis, right ureter blood, and bladder. When the bladder was flushed, the gross blood clots were intermittently discharged out. Right renal arteriography and embolization were carried out under local anaesthesia and obvious arteriovenous shunt of lower pole in right kidney was observed. Hematuria disappeared on the day of embolization. After about 200 ml of fresh blood clots were flushed out, the bladder was smooth with clear liquid flushed out. Lumbar pain on the right side appeared on the day of the operation, accompanied by nausea, vomiting, and fever after 48 hours. B ultrasound inspection showed no obvious abnormalities in the bladder. The patient recovered well and was discharged 9 days after the operation.

Case 2 (Figure 1D and 1E) was a 30-year old pregnant patient with intermittent hematuria appeared in week 8 during gestation, accompanied by lumbar pain on the right side. B ultrasound inspection showed hydronephrosis of both kidneys, with slightly higher echo found in the right renal sinus than in the left renal sinus.

The flocculent heterogeneous echo texture in the bladder was also found. Right renal arteriography and embolization were carried out under local anaesthesia, and obvious arteriovenous shunt in the central of right kidney was found. Gelatin sponge particles and micro-tower coils were used for the selective embolization of vascular lesions. Hematuria disappeared on the day of embolization. CT examination after the operation indicated the cortex-like multiple low density lesions in the upper right kidney, suggesting that ischemic and mild infarction occurred. The patient recovered well and was discharged 8 days after the operation.

## Discussion

Hematuria caused by renal arteriovenous malformations in pregnant women is rarely reported. In this study, 2 pregnant patients with lumbar pains and hematuria, hematoma, urine retention, and decreased levels of haemoglobin were admitted in the hospital. Previously, the main treatments for renal arteriovenous malformation include nephrectomy or partial nephrectomy, renal artery ligation and other methods. However, since arterial embolization was successfully used for treatment of renal arteriovenous malformation, it has become one of the effective methods [7]. Therefore, the treatments of renal arteriovenous malformation mainly are surgery and interventional embolization. Embolization is the preferred treatment of renal arteriovenous malformation because it can reduce the trauma and preserve renal function [8]. Surgery or embolization for

patients should be chosen based on the general conditions of patients, such as symptoms and arteriovenous malformation [9, 10]. Furthermore, another study shows that large arteriovenous malformation of multiple blood supply requires surgical ligation and the removal of abnormal lesions. After treated with renal artery embolization, the gross hematuria disappeared in both cases on the day of surgery, obtaining significant therapeutic effect.

## Disclosure of conflict of interest

None.

**Address correspondence to:** Dr. Jinchun Xing, Department of Urology and Center of Urology, The First Affiliated Hospital of Xiamen University, Xiamen 361003, P. R. China. Tel: 086-13606061735; E-mail: xmuurology@126.com

## References

- [1] Motta J, Breslin DS, Vogel F, Muecke EC and Fracchia JA. Congenital renal arteriovenous malformation in pregnancy presenting with hypertension. *Urology* 1994; 44: 911-4.
- [2] Ali M, Aziz W and Abbas F. Renal arteriovenous malformation: an unusual cause of recurrent haematuria. *BMJ Case Rep* 2013; 2013.
- [3] Morin RP, Dunn EJ and Wright CB. Renal arteriovenous fistulas: a review of etiology, diagnosis, and management. *Surgery* 1986; 99: 114-8.
- [4] Ishikawa T, Fujisawa M, Kawabata G and Kamidono S. Assessment of availability of magnetic resonance angiography (MRA) in renal arteriovenous fistula. *Urol Res* 2004; 32: 104-6.
- [5] Bookstein JJ and Goldstein HM. Successful management of postbiopsy arteriovenous fistula with selective arterial embolization. *Radiology* 1973; 109: 535-6.
- [6] Perrin M, Lousquy R, Rossignol M and Bonnin P. Renal arteriovenous fistula revealed by severe hypertension during pregnancy. *BMJ Case Rep* 2013; 2013.
- [7] Nishijima I, Ikemura R, Gushiken M, Miyagi K and Iha K. Nonsurgical treatment of scalp arteriovenous malformation using a combination of ultrasound-guided thrombin injection and transarterial coil embolization. *J Vasc Surg* 2012; 55: 833-6.
- [8] Zhang B, Jiang ZB, Huang MS, Zhu KS, Guan SH and Shan H. The role of transarterial embolization in the management of hematuria secondary to congenital renal arteriovenous malformations. *Urol Int* 2013; 91: 285-90.
- [9] Mishina M, Segawa T, Kakehi Y, Arai Y, Hida S, Takeuchi H, Yosida O and Nishimura K. Transcatheter embolization of huge renal arteriovenous aneurysm: a case report-review of 270 cases of renal arteriovenous fistula reported in Japan. *Hinyokika Kyo* 1991; 37: 273-7.
- [10] Wortman A, Miller DL, Donahue TF and Petersen S. Embolization of renal hemorrhage in pregnancy. *Obstet Gynecol* 2013; 121: 480-3.