

Original Article

***Enterobacter cloacae* infection after anterior cervical decompression and fusion: case study and literature review**

Hongli Wang, Lixun Wang, Yong Yang, Feizhou Lu, Xiaosheng Ma, Xinlei Xia, Jianyuan Jiang

Department of Orthopaedics, Huashan Hospital, Fudan University and Spine Center Fudan University, Shanghai 200040, China

Received December 14, 2014; Accepted February 3, 2015; Epub March 15, 2015; Published March 30, 2015

Abstract: Wound infection after anterior cervical decompression and fusion can lead to disastrous consequences despite a low incidence rate. Although Gram-positive bacteria such as *Staphylococcus aureus* are the most common pathogenic bacteria, some rare bacteria such as conditional pathogenic bacteria may also result in such a condition. To the best of our knowledge, *E. cloacae*-caused acute infection after anterior cervical decompression and fusion has not been reported. Here, we report an *E. cloacae*-caused acute infection after anterior vertical decompression and fusion. This infection was eventually controlled by virtue of an early diagnosis and the correspondingly-adopted anti-infection, internal fixation removal, and drainage treatments. Exploring the reasons underlying acute infection after anterior cervical decompression and fusion caused by rare bacteria, particularly *E. cloacae*, by analyzing this case was the basic therapeutic principle in this study. We believe that the therapeutic principle for *E. cloacae*-caused wound infection after anterior cervical internal fixation is basically consistent with that for other bacterium-caused wound infections after spinal internal fixation. Sufficient drainage, the adoption of sensitive antibacterials, and internal fixation removal as early as possible when necessary are the essential measures in infection control.

Keywords: Cervical vertebrae, anterior cervical decompression and fusion, complication, wound infection, *Enterobacter cloacae*

Introduction

Anterior cervical operation (ACO), particularly anterior cervical decompression and fusion (ACDF), has been extensively applied in clinical practice. However, ACO involves complicated anatomic structures, as a consequence of which complications may occur. Among different complications of ACO, postoperative infection is a serious one. Although ACO leads to an incidence rate of postoperative infection between 1% and 3%, which is lower compared with the posterior approach [1], patients subjected to the anterior upper cervical transoral approach are still at high risk of infection. Post-cervical operation infection can be classified into early and delayed infection [2]. Early infection generally occurs within several weeks after operation, whereas delayed infection normally occurs several months later. The risk factors of post-cervical operation infection primarily

include patients' general conditions, such as diabetes, obesity, long-term use of hormones, long-term smoking or alcoholism, and so on [3, 4]. Additionally, operation related factors (such as intraoperative contamination, the use of an implant, and operating time elongation), an excessively long time of drainage tube detention after operation, and distant infection all contribute to its development.

The common pathogenic bacteria that induce post-cervical operation infection mainly include skin flora such as *Staphylococcus aureus*, *Staphylococcus epidermidis*, and *diphtheroid bacillus*, *Streptococcus pneumoniae*, and Gram-negative bacillus. Most infections caused by *Mycobacterium tuberculosis*, *fungi*, and parasites occur in patients with immune deficiency. Only very few opportunistic infections such as *Candida albicans* infection may occur in these patients. Furthermore, immunosuppression

Treatment of post-operative *E. cloacae* infection

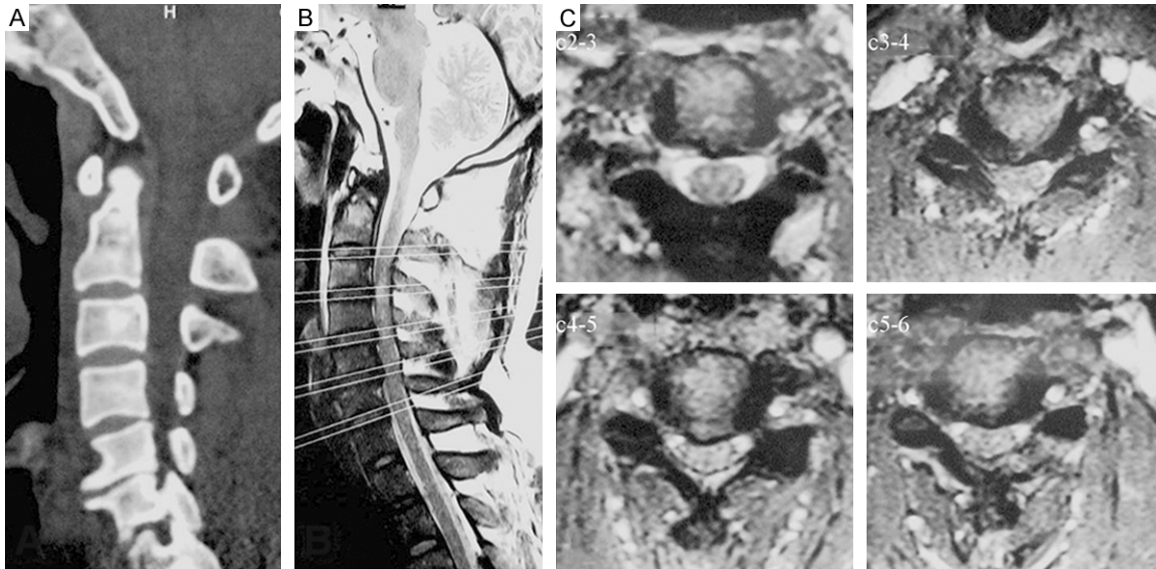


Figure 1. Preoperative CT did not show apparent osseous abnormalities, such as bone fractures and dislocation (A). MRI showed spinal stenosis at C3-4, C4-5, and C5-6, apparent spinal cord compression, and abnormal signals in the C3-4 spinal cord (B and C).

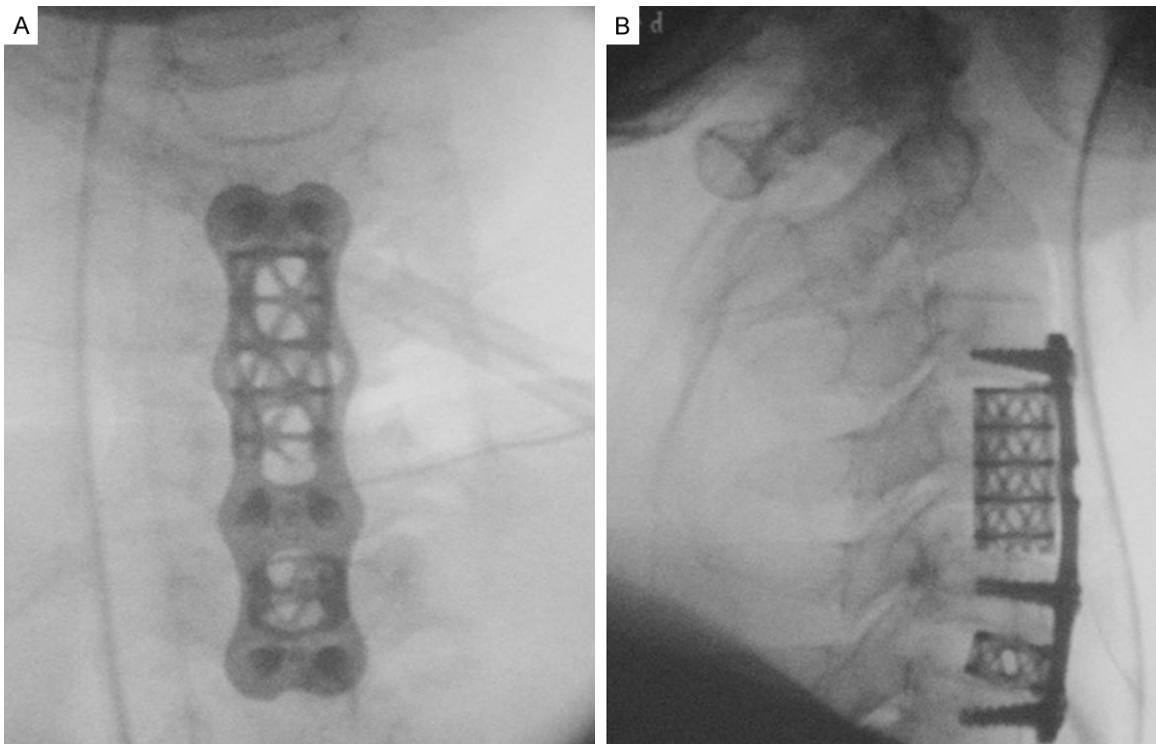


Figure 2. After anterior cervical C4 subtotal resection, C5-6 discectomy, titanium mesh and autogenous bone graft fusion, and C3-6 anterior plate internal fixation were performed, frontal and lateral X-ray radiographs of the cervical vertebrae were immediately taken.

and the long-term use of broad spectrum antibiotics may also lead to infection caused by *fungi* and rare bacteria.

In clinical practice, we found a post-ACO infection in a patient without immune deficiency, and the pathogenic bacteria were *E. cloacae*.

Treatment of post-operative *E. cloacae* infection

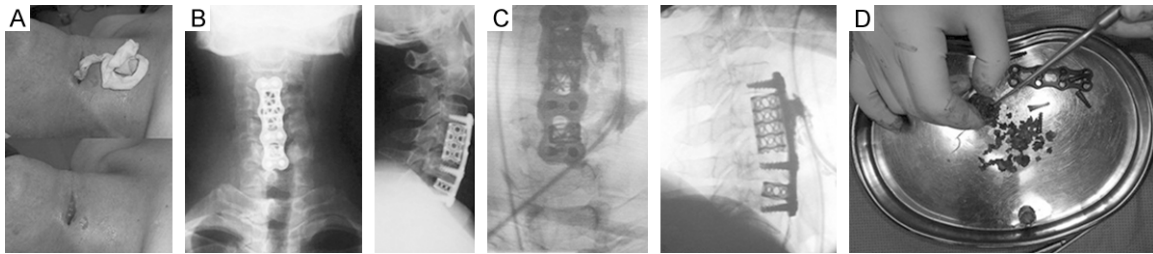


Figure 3. Patient's conditions 4 d after the operation. A: The patient's body temperature rose to 38.2°C and swelling appeared around the wound with the overflow of stink dark red pus. B: The patient presented with hyperpyrexia and wound exudates, and frontal and lateral X-ray re-examination of the cervical vertebrae did not show apparent abnormal changes, such as internal fixation loosening and translocation. C: A slit pore in the deep fascia connected to the deep tissue and contrast aggregation around the plate and titanium mesh were observed during debridement. D: The plate and titanium mesh were removed during debridement, and bone graft particles released a foul odor.

To the best of our knowledge, no study of such a wound infection has been reported.

Case report

A 50-year-old male patient was hospitalized one week after cervical spinal cord injury due to limb numbness and motion limitation after a downstairs fall. This study was conducted in accordance with the declaration of Helsinki. This study was conducted with approval from the Ethics Committee of Huashan Hospital, Fudan University. Written informed consent was obtained from the patient. The patient had a medical history of appendectomy eight years before, but no history of diabetes or immune deficiency. His body mass index was 24.5. He had no addiction of excessive drinking or smoking. Medical examination showed apparently faded superficial sensation of the four limbs, the strengths of bilateral shoulder-shrugging muscles at level IV, the strength of the right anconeus muscle at level III, the strength of the right hand at level III, the strength of the left upper limb muscle at level 0, the strengths of both lower limb muscles at level IV, and bilateral knee and ankle hyperreflexia. A pathological sign of (-) was concluded. Preoperative computed tomography (CT) did not show apparent osseous abnormalities, such as fractures and dislocations (**Figure 1A**). Magnetic resonance imaging (MRI) showed spinal stenosis at C3-4, C4-5, and C5-6, apparent spinal cord compression, and abnormal signals in the C3-4 spinal cord (**Figure 1B** and **1C**). The patient was diagnosed with cervical spinal cord injury and central cord syndrome. By consent of the patient, anterior cervical C4 subtotal resection, C5-6 discectomy, titanium mesh and autogenous

bone graft fusion, and C3-6 anterior plate internal fixation were performed smoothly (**Figure 2**). The intraoperative bleeding volume was approximately 200 ml and no blood transfusion was performed. Cefazolin at 2.0 g was intravenously given 30 min before the operation. After the operation, an intravenous injection of 2.0 g of cefazolin was given every 12 h within 48 h. During the first 24 h after the operation, a total of 40 ml of pale bloody liquid was drained from the wound. During the following 24 h, the volume was about 5 ml. The drainage tube was then removed. The patient's upper limb muscle strength recovered gradually to level III and his bilateral upper limb numbness was relieved to some extent.

At 4 d after the operation, the patient reported swelling and pain at the cervical wound. His body temperature rose to 38.2°C. Medical examination showed apparent swelling and pressing pain around the wound with the overflow of stink dark red pus (**Figure 3A**). Laboratory examination was then performed. According to blood routine examination, the white blood count (WBC) was $12.38 \times 10^9/L$ with a neutrophilic granulocyte percentage (N%) of 70.8%, the erythrocyte sedimentation rate (ESR) was 35 mm/h, and the C-reactive protein content (CRP) was 37.80 mg/L. Frontal and lateral X-ray re-examination of the cervical vertebrae showed good internal fixation without apparent translocation (**Figure 3B**).

Bacterial culture and a drug sensitive test of the wound exudates were performed immediately after the infection was observed. Incision and drainage were performed and a strip of gauze was detained for the sake of drainage.

Treatment of post-operative *E. cloacae* infection

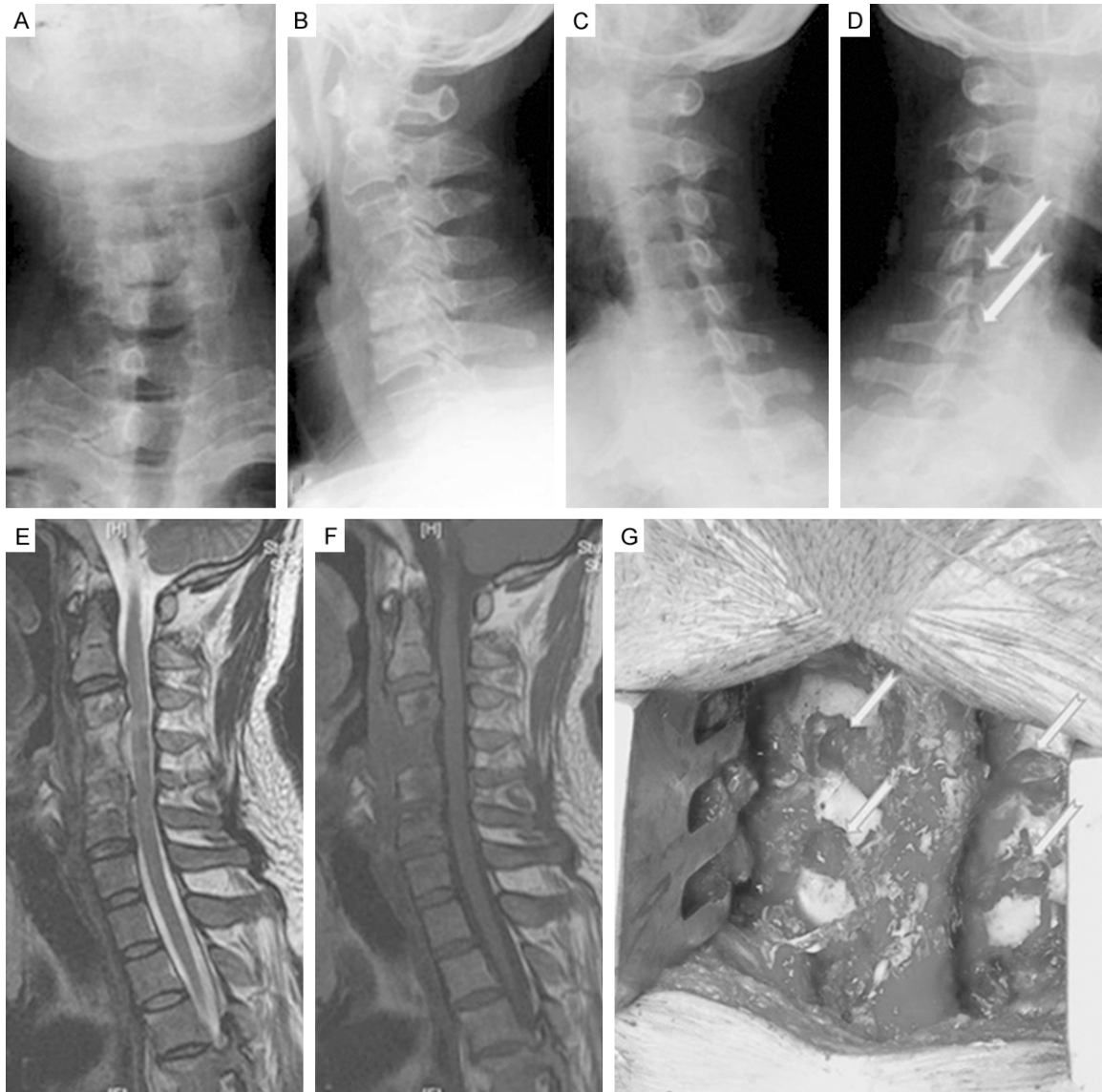


Figure 4. Patient's conditions 4 months after operation. A-F: The patient reported aggravated numbness and asthenia of both upper limbs; medical examination showed hypermyotonia of the four limbs, right upper limb muscle strength at level IV, left upper limb muscle strength at level III, bilateral lower limb muscle strengths at level IV+, and sensation disorders of both upper limbs; and X-ray and MRI re-examination exhibited cervical lordotic curve loss in the operative region and slight stenosis of the right intervertebral foramen between C5 and C6 but without apparent spinal cord compression. G: Considering that foraminal stenosis and root compression might be caused by intervertebral height loss, posterior C5-6 foraminotomy was performed.

Meanwhile, norvancomycin and fosfomycin were given for anti-infection. The bacterial culture of the superficial exudates disclosed *Streptococcus intermedius*. According to the results of the drug sensitive drug test, norvancomycin and fosfomycin were continuously administered. After a poor anti-infective effect was confirmed, fosfomycin was withdrawn and cefepime and rifampicin were added. However, the patient's body temperature remained 37.6-

38.5°C, local swelling at the wound did not noticeably fade away, the exudation of pus persisted, and the symptoms of infection was hard to control. Blood routine re-examination showed the WBC, N%, ESR, and CRP at $8.60 \times 10^9/L$, 82.7%, 52 mm/h, and 31.80, respectively. An encroachment of the infection on deep tissues or even the centrum vertebrae was considered. After consent was obtained from the patient 14 d after the operation, ante-

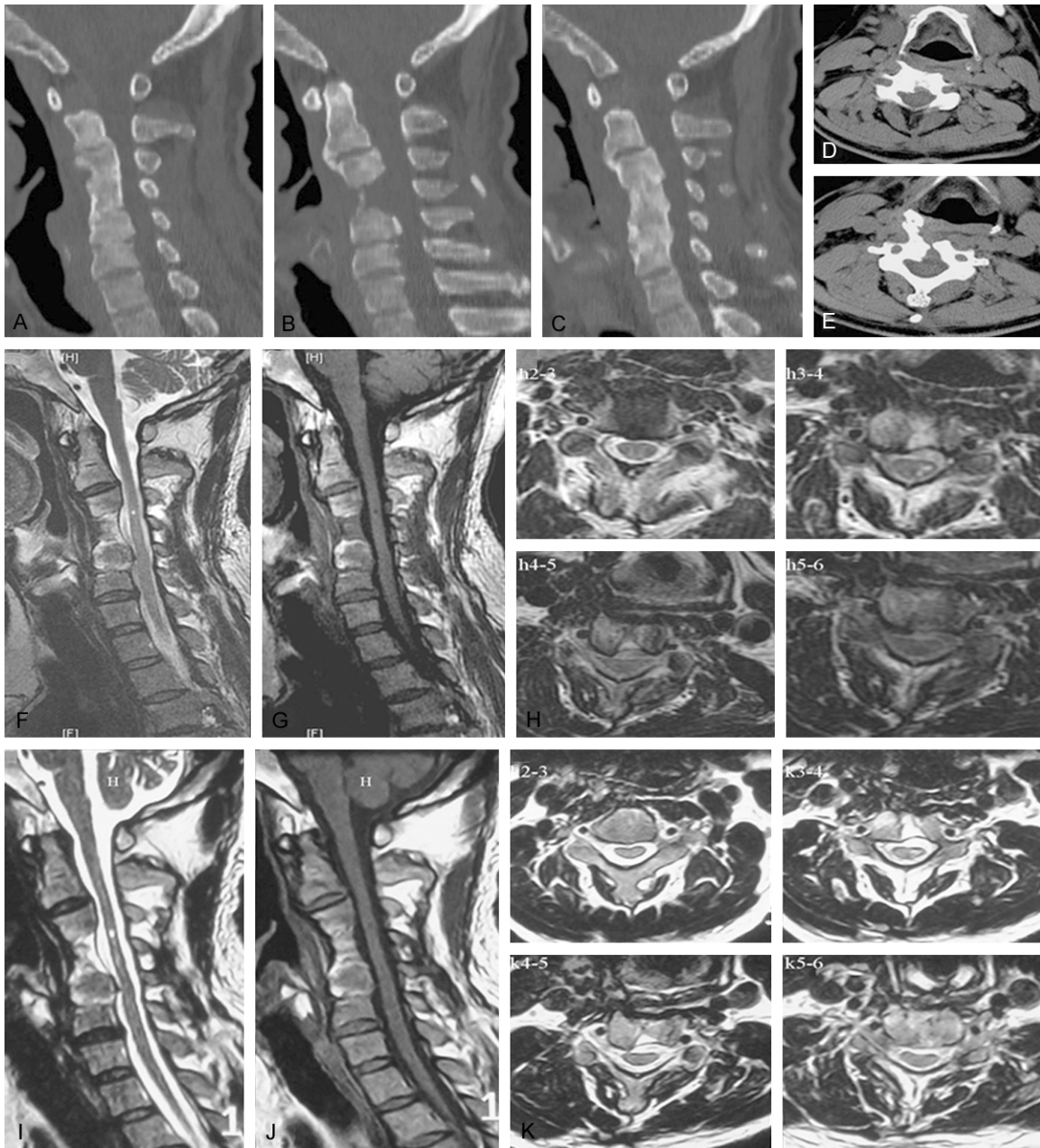


Figure 5. Follow-up results 7 months and 2 years after internal fixation removal. A-E: The CT review 7 months after internal fixation removal showed that the cervical lordotic curves in the operative region were lost, but osseous fusion was achieved at both sides of the operated segment. F-H: MRI did not show apparent spinal cord compression; the T2 weighted image exhibited abnormal hyperintensities in the horizontal cord of C3-4 and the T1 weighted image exhibited hypointensities, suggesting an irreversible damage to the spinal cord. I-K: The MRI review 2 years after the operation showed that although there was no apparent spinal cord compression at the operated segment, the abnormal signals in the horizontal spinal cord of C3-4 still existed.

rior cervical local probing and debridement were performed, and whether the internal fixity was necessary to be detained was determined according to intraoperative conditions. During the operation, a slit pore in the deep fascia connected to deep tissues and contrast aggrega-

tion around the plate and titanium mesh were observed (**Figure 3C**). The plate and titanium mesh were removed. Bone graft particles released a foul odor (**Figure 3D**). After the operation, negative pressure drainage was kept. Meanwhile, combined modality therapies

Treatment of post-operative *E. cloacae* infection

including fasting, cervical immobilization, and nutritional support were given. The bone graft particles underwent bacterial culture and a drug sensitive test. The result of bacterial culture showed *E. cloacae* (3+). According to the results of the drug sensitive test, intravenous dripping of amoxicillin/clavulanic acid (2.4 g twice per day) and levofloxacin (0.5 once per day) was given. At 2 d after the operation, the patient's body temperature fell to 37.2°C and then gradually to 36.7°C. The blood routine examination at 3 d showed WBC, N%, and ESR at $8.08 \times 10^9/L$, 72.4%, and 40 mm/h, respectively. Meanwhile, the drainage volume of the inflammatory liquid from the wound decreased gradually. At 7 d, the drainage tube was extracted and liquid diet was given. At 14 d, the wound healed completely and the sutures were removed. The patient received consecutive intravenous dripping of the above-mentioned antibiotics for two weeks. His cervical part was immobilized using a hard cervical support for three months after the operation.

At 4 months after the operation, the patient reported aggravated numbness and asthenia of both upper limbs. Medical examination showed hypermyotonia of the four limbs, the right upper limb muscle strengths at level IV, the left upper limb muscle strength at level III, bilateral lower limb muscle strengths at level IV+, and sensation disorders of both upper limbs. X-ray and MRI re-examination exhibited cervical lordotic curve loss in the operative region and slight stenosis of the right intervertebral foramen between C5 and C6, but without apparent spinal cord compression (**Figure 4A-F**). Considering that foraminal stenosis and root compression might be caused by intervertebral height loss, posterior C5-6 foraminotomy was performed (**Figure 4G**). After the operation, the patient's shoulder-shrugging muscle strengths restored to some extent and the symptom of upper limb numbness improved slightly.

During the follow-ups, the patient's numbness of both upper limbs persisted. The CT review 7 months after internal fixation removal showed that his cervical lordotic curves in the operative region were lost, but osseous fusion was achieved at both sides of the operated segment (**Figure 5A**). MRI did not show apparent spinal cord compression. The T2 weighted image exhibited abnormal hyperintensities in

the horizontal cord of C3-4 and the T1 weighted image exhibited hypointensities. These results suggested an irreversible damage to the spinal cord (**Figure 5B**). According to the final follow-up two years after the operation, the patient's numbness of both lower limbs continued, and his muscle strengths of both lower limbs, the right upper limb, and the left upper limb were at levels IV+, IV, and III, respectively. His anterior cervical wound healed without infection recurrence. The MRI review showed that although there was no apparent spinal cord compression at the operated segment, the abnormal signals in the horizontal spinal cord of C3-4 still existed (**Figure 5C**).

Discussion

Cervical operation is subject to class IV aseptic operation except that the original disease itself is infective. It only leads to a low incidence rate of post-operative infection, which is lower than lumbar operation. The infection incidence rate lies between 1% and 3% and, furthermore, ACO has a lower infection incidence rate than the posterior approach [5]. However, ACO is likely to result in numerous serious complications, such as superior laryngeal and recurrent laryngeal nerve injuries, spinal cord or nerve root injuries, hematoma, and so on [6]. Therefore, great attention should be given to post-ACO infection. Once its diagnosis and treatment are delayed, serious consequences may arise.

A number of risk factors are related with the development of post-cervical operation infection. First, patients' general conditions constitute the internal factors. Diabetes, obesity, a great age, malnutrition, smoking, and alcoholism all increase the incidence rate of postoperative infection. Furthermore, the use of adrenal cortex hormones and a history of autoimmune disease such as ankylosing spondylitis are also its high risk factors. Second, operation related factors are also contributive to the development of post-cervical operation infection, such as operative contamination, internal fixation and the use of artificial bones, revision surgery, operating time elongation, multiple-segment operation, surgical trauma [7], and posterior operation. In addition, preoperative wound infection, postoperative infection of other systems such as the urinary system, excessively long time of drainage tube detention after operation, neglect of wound cleaning,

Treatment of post-operative *E. cloacae* infection

blood transfusion, excessive hemorrhage, post-operative observance in the intense care unit all have a role [8].

Patients with spinal trauma have a much higher risk of postoperative infection than those receiving selective spinal operation. Patients undergoing acute spinal trauma surgery have an incidence rate of wound infection of 9.4% (some studies have reported that the total incidence rate is between 9% and 15%), whereas those undergoing selective spinal surgery have an incidence rate of 3-6% [9, 10]. Therefore, spinal column and spinal cord injuries may be high risk factors of postoperative wound infection, and nerve injury after trauma is closely correlated with postoperative infection [11]. In this study, the male patient suffered from cervical trauma accompanied with spinal cord injury. These were possibly some of the factors causing the postoperative infection in this patient.

Based on the aforementioned, it is clear that post-ACO infection has numerous high risk factors. However, the exact factors correlated with a specific infection are always uncertain. A possible explanation may be that multiple factors jointly participate in the development of post-ACO infection.

Pathogenic bacteria that cause post-ACO infection bear similarities to those causing infections at other spinal sites, and the frequently-obtained results of bacterial culture are Gram-positive bacteria such as *Staphylococcus aureus* and *Staphylococcus epidermidis* and some Gram-negative bacteria like *Micrococcus scarlatinae*, *Escherichia coli*, *Enterococcus*, and *Klebsiella pneumonia* [12, 13]. Our literature review denied the existence of any released report of anterior cervical *E. cloacae* infection. In the case reported in this study, the early bacterial culture of the exudates showed *Streptococcus intermedius*. However, 10 days of the targeted anti-infective therapy according to the drug sensitive test result failed to achieve a satisfactory curative effect. Thus, the bacterial culture + drug sensitive test of the bone graft particles was conducted after internal fixation removal. The results of bacterial culture demonstrated *E. cloacae*, and the targeted anti-infective therapy according to the results of the drug sensitive test achieved a satisfactory anti-infective effect. Based on the curative

effect, we believe that the pathogenic bacteria causing the deep infection in this patient were *E. cloacae* and that *Streptococcus intermedius* cultured from the superficial exudates might be responsible for a combined infection and the sample contamination.

Post-ACO infection can be classified into acute and delayed postoperative infection in terms of its occurrence time. The bacteria that commonly cause acute and delayed infections are somewhat different. The most common bacteria responsible for acute infection is *Staphylococcus aureus*, followed by other Gram-positive bacteria such as *Micrococcus scarlatinae*, *Coagulase negative staphylococcus*, and so on. In addition, Gram-negative bacteria such as *Escherichia coli*, *Bacillus proteus*, and *Pseudomonas aeruginosa* can also cause such a condition [14]. Delayed infection, with the exception of tuberculosis, is frequently caused by low-virulence *Propionibacterium*, *Staphylococcus epidermidis*, and *Peptostreptococcus*, and its underlying mechanisms include intraoperative skin contamination, aseptic inflammation, and haematogenous dissemination [15, 16]. *E. cloacae*, as an intestinal normal flora, only result in a very low infection rate in adults with normal immunity. However, with the extensive application of cephalosporin, they have become more and more important pathogenic bacteria of hospital infection. In hospital infections, *Enterobacter* accounts for 5-7% of bacteremia; surgical wound infection ranks the fourth position, in which *E. cloacae* and *Enterobacter aerogenes* are the most responsible bacteria [17]. *E. cloacae* infection mostly takes the form of infection at polytrauma sites. It may also be manifested by cervical epidural abscess induced by *E. cloacae*-caused bacteremia [18]. In addition, HIV patients are also at risk of lumbar vertebral infection by *E. cloacae*. However, *E. cloacae* infection after ACDF has not been reported. Therefore, the case in this study belongs to a rare post-ACO acute infection which was caused by rare bacteria.

The diagnosis of post-ACO acute infection is not difficult, which primarily occurs 10 d after operation with the manifestations of a body temperature elevation, swelling around the incision, and purulent secretions or pus that can be extracted through a puncture. The indices of ESR and CRP have auxiliary diagnostic significance. The increases in WBC and N% suggest a

Treatment of post-operative *E. cloacae* infection

bacterial infection. CRP shows a sensitive advantage in the diagnosis of post-spinal column surgery infection over ESR and WBC, and can be used to monitor possible infection 7 d after operation [19]. A reduction in the lymphocyte count at the early stage after operation is of significance for the early diagnosis of post-spinal column surgery infection [20]. Although blood culture and wound exudate culture both play important roles in infection diagnosis, they have certain false negative rates due to the application of broad-spectrum antibiotics. Furthermore, imaging examination can be utilized in the evaluation of the involvement of the centrum vertebrae, as well as the involvement degrees of the paravertebral soft tissues. X-ray examination has low sensitivity and specificity. By contrast, MRI cannot only show the number of the involved centrum vertebrae and the range of the disease, but timely display possibly complicated retropharyngeal abscess. For these reasons, MRI has become the most reliable imaging diagnostic method [21]. In addition, a correct judgment on a deep infection or not is particularly significant to therapeutic measure determination.

Once wound infections are confirmed, different therapeutic measures will be adopted according to different infected sites. For superficial subcutaneous infection, debridement and rinsing can be performed and sensitive antibiotics are given. However, for an infection deep to the internal fixity, the patient should be transferred to the operating room as early as possible. There, the principle of aseptic processing should be stuck to. Specifically, the wound is rinsed using physiological saline and the exudates from the deep layer are collected for culture. After the result of the biological test is obtained, antibiotics are determined according to the drug sensitive test. If the infection is a combined one, drug combination should be used. Layer-by-layer separation is performed and the necrotic tissues are removed until the deepest infected site. In addition, wound rinsing and soaking with diluted iodine solution can reduce the wound infection rate. A sufficiently long time of perfusion and drainage should also be ensured after a thorough debridement.

Debridement and drainage as well as systemic or local antibiotic administration are necessary in the treatment of wound infection. As for internal fixation removal, no agreement has been

reached. Some scholars hold that if the wound infection is well controlled under the actions of debridement, rinsing, and drainage combined with systemic and local antibiotic administration, the internal fixity may be detained [22]. This is because that internal fixation can maintain spinal stabilization. Meanwhile, the detention of the internal fixity avoids a reoperation and reduces the patient's economic burden. However, for delayed postoperative infection, if examination confirms that the fixed segment has reached an osseous fusion, internal fixation can be removed during debridement. For uncontrollable post-internal fixation infection with an unhealed sinus tract, internal fixation removal can be considered and further treatment can then be performed after the infection is well controlled. Internal fixation removal combined with antibiotic administration can cure infections. In chronic infection, the detention of the internal fixity can lead to insufficient drainage, and revision operation can only be performed after the infection is completely controlled for the sake of stability [23]. In this study, the reported case is subject to an acute infection after ACDF. The internal fixity was removed mainly based on the consideration that the infection had involved deep layers. In addition, the conditional pathogenic bacteria of this infection were *E. cloacae* which have high resistance to drugs. If an infection caused by such bacteria is not timely controlled, the spinal column and spinal cord will be endangered.

Conclusion

To the best of our knowledge, the case reported in this study is the first report of post-ACO *E. cloacae* infection in literatures. ACDF has a low postoperative wound infection rate. Infections caused by *E. cloacae* as conditional pathogenic bacteria are even much less. However, for patients at high risk of postoperative infection, particularly those in whom empirical anti-infective therapy fails to achieve a good curative effect, the possibility of infection caused by rare conditional pathogenic bacteria such as *E. cloacae* cannot be excluded. Judging the involved depth of the infection at an early stage, conducting bacterial culture using the collected deep lesion tissue, and then choosing sensitive antibiotics according to the results obtained from culture and the drug sensitive test for an anti-infective treatment play critical roles. For patients in whom deep tissues are infected and

an anti-infective therapy fails to achieve a satisfactory control effect, debridement and drainage should be performed timely. When necessary, internal fixation should be removed.

Disclosure of conflict of interest

None.

Address correspondence to: Jianyuan Jiang, Department of Orthopaedics, Huashan Hospital, Fudan University and Spine Center Fudan University, Shanghai 200040, China. Tel: +86-21-52887122; Fax: +86-21-52887136; E-mail: xwdoccn@yeah.net

References

- [1] Smith JS, Shaffrey CI, Sansur CA, Berven SH, Fu KM, Broadstone PA, Choma TJ, Goytan MJ, Noordeen HH, Knapp DR Jr, Hart RA, Donaldson WF 3rd, Polly DW Jr, Perra JH and Boachie-Adjei O. Rates of infection after spine surgery based on 108,419 procedures: a report from the Scoliosis Research Society Morbidity and Mortality Committee. *Spine* 2011; 36: 556-563.
- [2] Ho C, Sucato DJ, Richards BS. Risk factors for the development of delayed infections following posterior spinal fusion and instrumentation in adolescent idiopathic scoliosis patients. *Spine* 2007; 32: 2272-2277.
- [3] Patel N, Bagan B, Vadera S, Maltenfort MG, Deutsch H, Vaccaro AR, Harrop J, Sharan A, Ratliff JK. Obesity and spine surgery: relation to perioperative complications. *J Neurosurg Spine* 2007; 6: 291-297.
- [4] Olsen MA, Nepple JJ, Riew KD, Lenke LG, Bridwell KH, Mayfield J, Fraser VJ. Risk factors for surgical site infection following orthopaedic spinal operations. *J Bone Joint Surg Am* 2008; 90: 62-69.
- [5] Boakye M, Patil CG, Santarelli J, Ho C, Tian W, Lad SP. Cervical spondylotic myelopathy: complications and outcomes after spinal fusion. *Neurosurgery* 2008; 62: 455-462.
- [6] Winslow CP, Winslow TJ, Wax MK. Dysphonia and dysphagia following the anterior approach to the cervical spine. *Arch Otolaryngol Head Neck Surg* 2001; 127: 51-55.
- [7] Cizik AM, Lee MJ, Martin BI, Bransford RJ, Bel-labarba C, Chapman JR, Mirza SK. Using the Spine Surgical Invasiveness Index to Identify Risk of Surgical Site Infection. *J Bone Joint Surg Am* 2012; 94: 335-342.
- [8] Pories SE, Gamelli RL, Mead PB, Goodwin G, Harris F, Vacek P. The epidemiologic features of nosocomial infections in patients with trauma. *Arch Surg* 1991; 126: 97-99.
- [9] Brown EM, Pople IK, de Louvois J, Hedges A, Bayston R, Eisenstein SM, Lees P. Spine update: prevention of postoperative infection in patients undergoing spinal surgery. *Spine (Phila Pa 1976)* 2004; 29: 938-945.
- [10] Picada R, Winter RB, Lonstein JE, Denis F, Pinto MR, Smith MD, Perra JH. Postoperative deep wound infection in adults after posterior lum-bosacral spine fusion with instrumentation: incidence and management. *J Spinal Disord* 2000; 13: 42-45.
- [11] Rehtine GR, Bono PL, Cahill D, Bolesta MJ, Chrin AM. Postoperative wound infection after instrumentation of thoracic and lum-bar fractures. *J Orthop Trauma* 2001; 15: 566-569.
- [12] Beiner JM, Grauer J, Kwon BK, Vaccaro AR. Postoperative wound infections of the spine. *Neurosurg Focus* 2003; 15: E14.
- [13] Weinstein MA, McCabe JP, Cammisa FP Jr. Postoperative spinal wound infection: a review of 2,391 consecutive index procedures. *J Spinal Disord* 2000; 13: 422-426.
- [14] Sapico FL. Microbiology and antimicrobial therapy of spinal infections. *Orthop Clin North Am* 1996; 27: 9-13.
- [15] Bose B. Delayed infection after instrumented spine surgery: case reports and review of the literature. *Spine J* 2003; 3: 394-399.
- [16] Viola RW, King HA, Adler SM, Wilson CB. Delayed infection after elective spinal instrumentation and fusion: a retrospective analysis of eight cases. *Spine (Phila Pa 1976)* 1997; 22: 2444-2450.
- [17] Marce S, Antoine JF, Schaefferbeke T, Vernhes JP, Bannwarth B, Dehais J. Enterobacter cloacae vertebral infection in heroin addict with HIV infection. *Ann Rheum Dis* 1993; 52: 695.
- [18] Vilke GM, Honingford EA. Cervical spine epidural abscess in a patient with no predisposing risk factors. *Ann Emerg Med* 1996; 27: 777-780.
- [19] Takahashi J, Ebara S, Kamimura M, Kinoshita T, Itoh H, Yuzawa Y, Sheena Y, Takaoka K. Early-phase enhanced inflammatory reaction after spinal instrumentation on surgery. *Spine (Phila Pa 1976)* 2001; 26: 1698-1704.
- [20] Takahashi J, Shono Y, Hirabayashi H, Kamimura M, Nakagawa H, Ebara S, Kato H. Usefulness of white blood cell differential for early diagnosis of surgical wound infection following spinal instrumentation surgery. *Spine (Phila Pa 1976)* 2006; 31: 1020-1025.
- [21] Hadjipaviou AG, Mader JT, Necessary JT, Muffoletto AJ. Hematogenous pyogen-lespinal infections and their surgical management. *Spine (Phila Pa 1976)* 2000; 25: 1668-1679.
- [22] Aydinli U, Karaeminoğullari O, Tışkaya K. Post-operative deep wound infection in instrumented spinal surgery. *Acta Orthop Belg* 1999; 65: 182-187.
- [23] Hedequist D, Haugen A, Hresko T, Emans J. Failure of attempted implant retention in spinal deformity delayed surgical site infections. *Spine (Phila Pa 1976)* 2009; 34: 60-64.