Int J Clin Exp Med 2015;8(3):3912-3923
www.ijcem.com /ISSN:1940-5901/IJCEM0005259

Original Article

Management for the anterior combined with posterior urethral stricture: a 9-year single centre experience

Tuo Deng[1], Banghua Liao[1], Deyi Luo[1], Bing Liu[2], Kunjie Wang[1], Jiaming Liu[1], Tao Jin[1]

[1]*Department of Urology, West China Hospital, Sichuan University, Chengdu 610041, P.R. China;* [2]*Department of Ophthalmology, West China Hospital, Sichuan University, Chengdu 610041, P.R. China*

Received December 26, 2014; Accepted February 20, 2015; Epub March 15, 2015; Published March 30, 2015

Abstract: Objective: Therapy for anterior combined with posterior urethral stricture is difficult and controversial. This study aims to introduce a standard process for managing anterior combined with posterior urethral stricture. Patients and methods: 19 patients with anterior combined with posterior urethral stricture were treated following our standard process. Average (range) age was 52 (21-72) years old. In this standard process, anterior urethral stricture should be treated first. Endoscopic surgery is applied for anterior urethra stricture as a priority as long as obliteration does not occur, and operation for posterior urethral stricture can be conducted in the same stage. Otherwise, an open reconstructive urethroplasty for anterior urethral is needed; while in this condition, the unobliterated posterior urethra can also be treated with endoscopic surgery in the same stage; however, if posterior urethra obliteration exists, then open reconstructive urethroplasty for posterior urethral stricture should be applied 2-3 months later. Results: The median (range) follow-up time was 25.8 (3-56) months. All 19 patients were normal in urethrography after 1 month of the surgery. 4 patients (21.1%) recurred urethral stricture during follow-up, and the locations of recurred stricture were bulbomembranous urethra (2 cases), bulbar urethra (1 case) and bladder neck (1 case). 3 of them restored to health through urethral dilation, yet 1 underwent a second operation. 2 patients (10.5%) complaint of dripping urination. No one had painful erection, stress urinary incontinence or other complications. Conclusions: The management for anterior combined with posterior urethral stricture following our standard process is effective and safe.

Keywords: Anterior urethral stricture, combined, posterior urethral stricture, standard process, surgical management

Introduction

Urethral stricture, caused by scar tissue, refers to the narrowing and even obliteration of urethra. It is a very common refractory urological disease happening to any age's men and women, especially male patients and easily recurred, the incidence of which was reported as 0.9% [1] in developed countries. Urethral stricture can directly lead to voiding dysfunction and may also cause renal impairment, thus to reduce the quality of patients' life and damage to patients' health severely.

The male urethra consists of two segments: the anterior urethra including bulbar and penile urethra, and the posterior urethra divided into membranous and prostatic urethra. Since their different anatomical positions, several factors should be taken into consideration when choosing the surgery method such as position, length and degree of the narrowing, cause of the urethral stricture, past treatment and patients' desire [2]. Patients with anterior combined with posterior urethral stricture exist anterior and posterior urethral strictures at the same time. However, the surgery managements differ in the anterior and posterior urethral stricture due to their anatomical positions, which makes it difficult to handle this disease.

Up to the present, the treatment of single anterior or posterior urethral stricture is relatively definitive and has been reported by a number of studies, however, studies on the management of the anterior combined with posterior urethral stricture are few and controversial due to its low incidence. This study aims to share

the 9-year experience of management for anterior combined with posterior urethral stricture following a standard process in our single centre. This is, to the best of our knowledge, the first original article that described a standard process of management for anterior combined with posterior urethral stricture.

Patients and methods

Subjects

19 male patients suffering from anterior combined with posterior urethral stricture received surgical treatment following our standard process in West China Hospital from 2005 to 2013. Average (range) age was 52 (21-72) years old.

Standard process

Before the operations, all patients underwent routine urine test and urine culture, further being treated by sensitive antibiotics according to the drug sensitive test if patients complaint of urinary tract infectious symptoms or urine culture was positive. Surgical treatment would be carried out subsequently if only the infection was under control. What's more, patients had to take the urethrography or urethroscope to confirm the narrowing positions. Preoperative vulvar skin preparation and soaked in the 0.1% povidone iodine solution was routinely conducted.

The principle of surgical managements for anterior combined with posterior urethral stricture in our standard process is that the anterior urethral stricture should be treated first. Transurethral endoscopic treatment (cold-knife internal urethrotomy, bladder neck narrowing with electrotomy) or urethral dilation (external orifice narrowing with dilation, urethra stricture with filiform bougie dilation) is applied for anterior urethra stricture as a priority as long as obliteration does not occur, and operation for posterior urethral stricture can be conducted in the same stage. Otherwise, a dorsal plus ventral onlay free graft urethroplasty for anterior urethral is needed; while in this condition, the unobliterated posterior urethra can also be treated with endoscopic surgery or urethral dilation in the same stage; however, when posterior urethra obliteration exists, if we performed a one-stage operation on the anterior and posterior urethra at the same time, the reconstructed part would have the risk of poor healing due to lacking blood supply, thus, transperineal stricture resection and tension-free end to end anastomosis for posterior urethral stricture should be applied 2-3 months later. All 19 patients' surgery managements were conducted by one experienced surgeon (K. W.) according to standard surgical procedures.

After surgeries, postoperative antibiotics and multiple side hole silastic tube indwelling were daily used. Patients accepting urethral construction had the surgical dressings changed 3 days after the operation and removed after 5 days. The wound should be exposed meanwhile. In 4-6 weeks, they needed to receive the urethrography again and silastic tube would be removed.

Efficacy evaluation

Success: Urethrography demonstrates an unobstructed urinary tract 1 month after the surgery. Patients urinate smoothly and need not receive a second surgery on account of complications or recurred obstructed symptoms.

Failure: Patients experience unsuccessful self-urination or dripped urination after catheter being removed, which could not remit by urethral dilation. They have to undergo surgery again.

Recurrence: Difficult urination or thin uroflow recurs after the surgery, and urethrography or urethroscope points out the narrowing part diameter is less than 16 Fr. A second surgery is necessary to eliminate the obstruction.

Follow-up

All patients had indwelling multiple side hole silastic tube (14-20Fr) and average (range) time was 31 (21-42) days. Urethrography was taken after 4-6 weeks and silastic tube could be removed. 3 months later, patients got a repeated urethrography, and the following reexamination was every 6 months. Telephone follow-up has been accomplished based on the self-made follow-up chart and average (range) follow-up time was 25.8 (3-56) months. Self-made follow-up chart includes if patients complain of dripped urination, pain erection or stress urinary incontinence and experience recurred nar-

Table 1. Patient Characteristics and demographics

	Patients with the anterior combined with posterior urethral stricture (n = 19)
Age (year)	52 ± 16.9
Follow-up time (month)	25.8 ± 18.2
No. causes of urethral stricture	
Trauma	9
Iatrogenic	7
Unknown factors	3
Anterior urethra	
Length of urethral stricture (cm)	2.4 ± 2.1
No. narrowing position	
External orifice	3
Penile urethra	13
Bulbar urethra	3
No. degree of anterior urethral stricture	
Non-obliteration	12
Obliteration	5
Proximal and distal transection or axis offset	2
Posterior urethra	
Length of urethral stricture (cm)	1.6 ± 0.5
No. narrowing position	
Membranous urethra	8
Bulbomembranous urethra	9
Bladder neck	2
No. degree of anterior urethral stricture	
Non-obliteration	11
Obliteration	7
Proximal and distal transection or axis offset	1

rowing, locations of recurred narrowing, treatments of recurred narrowing, and other complications and their treatments.

Results

Demographic characteristics

The baseline statistics of 19 patients were listed in **Tables 1** and **2**. Causes of the anterior combined with posterior urethral stricture included trauma (9 cases [47.4%]), iatrogenic operation (7 cases [36.8%]) and unknown factors (3 cases [15.8%]). 7 iatrogenic cases were composed by 4 cases of transurethral resection of prostate (TURP), 1 case of prostatectomy, 1 case of repeated urethral dilation and 1 case of indwelling catheter. Among these patients, the mean (range) length of anterior urethral stricture was 2.4 (0.5-8.0) centimeters. Penile urethra was the most common narrowing position, making up 68.4% (13 cases) of all patients and narrowing occurring on the external orifice and bulbar urethra was 15.8% (3 cases for each) respectively. The degree of anterior urethral stricture differed in cases with 36.8% (7 cases) cases obliterated completely or proximal and distal transection or axis offset and with the remaining 63.2% (12 cases) not obliterated. Penile urethral stricture happened in the above 7 cases with the average (range) narrowing length of 3.5 (0.5-8) centimeters, while the other 12 cases 1.6 (0.5-3.5) centimeters. Compared to anterior urethra, narrowing in posterior urethra was shorter with the average (range) narrowing length 1.6 (0.7-2.5) centimeters and the most common parts were bulbomembranous urethra (9 cases [47.4%]) and membranous urethra (8 cases [42.1%]), yet the bladder neck (2 cases [10.5%]) was rare and no prostatic urethra involved. The number of complete obliteration, proximal and distal transection or axis offset cases (8 cases [42.1%]) was a little less than non-obliteration ones (11 cases [57.9%]), with the average (range) narrowing length 1.9 (1.5-2.5) centimeters and 1.3 (1.5-2.5) centimeters respectively.

Surgical management

Among the 19 patients, 12 had urinary tract infectious symptoms or urine culture was positive. After administered with antibiotics in accordance with the drug sensitive test, urine culture returned to normal. Following our standard process, 19 patients were divided into 4 groups:

Group I: 9 cases, with both anterior and posterior urethra not obliterated completely. Average (range) narrowing length of the anterior urethra

Table 2. Patient details

No.	Group	Age (year)	Gender	Follow-up time (month)	Causes of urethral stricture	Narrowing position		Length of urethral stricture (cm)		Degree of urethral stricture		Staging surgery
						Anterior urethra	Posterior urethra	Anterior urethra	Posterior urethra	Anterior urethra	Posterior urethra	
1	I	33	male	51	Trauma	External orifice	Bulbomembranous urethra	0.5	0.7	Non-obliteration	Non-obliteration	One-stage
2	I	72	male	50	Iatrogenic (TURP)	Penile urethra	Bladder neck	1.5	-	Non-obliteration	Non-obliteration	One-stage
3	I	52	male	44	Unknown factors	Penile urethra	Bulbomembranous urethra	2.0	1.5	Non-obliteration	Non-obliteration	one-stage
4	I	21	male	5	Trauma	External orifice	Bulbomembranous urethra	-	1.0	Non-obliteration	Non-obliteration	one-stage
5	I	59	male	5	Iatrogenic (TURP)	Penile urethra	Bladder neck	0.5	-	Non-obliteration	Non-obliteration	One-stage
6	I	65	male	42	Iatrogenic (indwelling catheter)	Penile urethra	Bulbomembranous urethra	- (Narrow ring)	- (Narrow ring)	Non-obliteration	Non-obliteration	One-stage
7	I	72	male	38	Iatrogenic (repeated urethral dilation)	Bulbar urethra	Membranous urethra	1.0	1.5	Non-obliteration	Non-obliteration	One-stage
8	I	72	male	30	Iatrogenic (TURP)	Penile urethra	Bulbomembranous urethra	3.5	1.0	Non-obliteration	Non-obliteration	One-stage
9	I	42	male	30	Unknown factors	Penile urethra	Bulbomembranous urethra	3.0	1.0	Non-obliteration	Non-obliteration	One-stage
10	II	71	male	3	Iatrogenic (prostatectomy)	Penile urethra	Membranous urethra	5.0	2.0	Obliteration	Non-obliteration	One-stage
11	II	53	male	5	Unknown factors	Penile urethra	Bulbomembranous urethra	8.0	1.5	Obliteration	Non-obliteration	One-stage
12	III	34	male	29	Trauma	External orifice	Bulbomembranous urethra	-	-	Non-obliteration	Proximal and distal transection	One-stage
13	III	44	male	56	Trauma	Bulbar urethra	Bulbomembranous urethra	1.0	2.5	Non-obliteration	Obliteration	One-stage
14	III	70	male	10	Trauma	Bulbar urethra	Membranous urethra	1.0	2.0	Non-obliteration	Obliteration	One-stage
15	IV	66	male	25	Iatrogenic (TURP)	Penile urethra	Membranous urethra	1.0	1.5	axis offset	Obliteration	Two-stage
16	IV	30	male	8	Trauma	Penile urethra	Membranous urethra	3.0	2.0	axis offset	Obliteration	Two-stage
17	IV	58	male	10	Trauma	Penile urethra	Membranous urethra	2.0	1.5	Obliteration	Obliteration	Two-stage
18	IV	37	male	10	Trauma	Penile urethra	Membranous urethra	5.0	2.5	Obliteration	Obliteration	Two-stage
19	IV	36	male	39	Trauma	Penile urethra	Membranous urethra	0.5	1.5	Obliteration	Obliteration	Two-stage

TURP = transurethral resection of prostate.

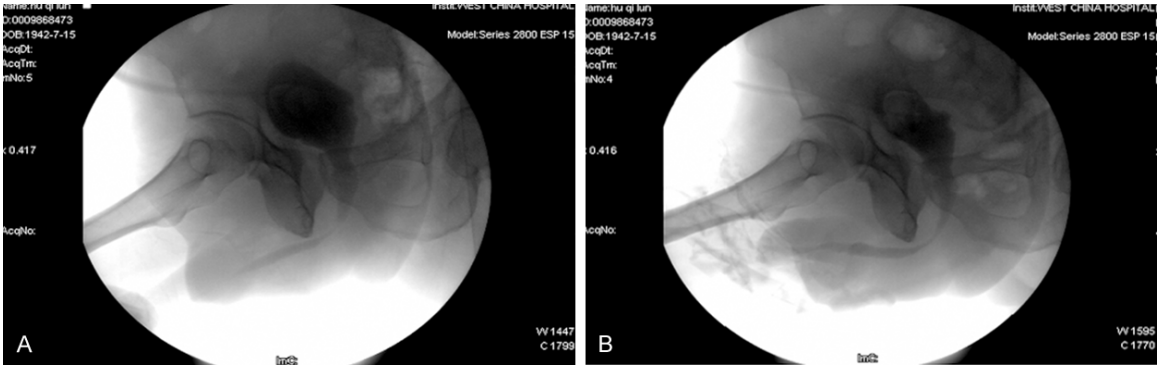

Figure 1. Pre- and postoperative X-ray urethrography of a Group II patient. A. Preoperative; B. One month postoperative.

was 1.7 (0.5-3.5) centimeters, while that of the posterior urethra was 1.1 (0.7-1.5) centimeters. We chose the one-stage transurethral endoscopic treatment or urethral dilation to deal with the anterior and posterior urethral stricture simultaneously.

Group II: 2 cases, with anterior urethra obliterated completely, proximal and distal transection or axis offset and posterior urethra not obliteration. Average (range) narrowing length of the anterior urethra was 6.5 (5.0-8.0) centimeters, while that of the posterior urethra was 1.8 (1.5-2.0) centimeters. These patients underwent one-stage dorsal plus ventral onlay free graft urethroplasty for anterior urethral stricture, and posterior urethral stricture was handled by transurethral endoscopic treatment or urethral dilation in the same stage (**Figure 1**).

Group III: 3 cases, with posterior urethra obliterated completely, proximal and distal transection or axis offset and anterior urethra not obliterated. Average (range) narrowing length of the anterior urethra was 1 centimeter, while that of the posterior urethra was 2.3 (2-2.5) centimeters. Patients in this group received transurethral endoscopic treatment or urethral dilation for anterior urethral stricture. Posterior urethral stricture was solved by transperineal stricture resection and tension-free end to end anastomosis in the same stage.

Group IV: 5 cases, with anterior and posterior urethra obliterated completely, proximal and distal transection or axis offset. Average (range) narrowing length of the anterior urethra was 2.3 (0.5-5.0) centimeters, while that of the posterior urethra was 1.8 (1.5-2.5) centimeters. We conducted a two-step operation for the anterior and posterior urethral stricture separately. One-stage surgery was dorsal plus ventral onlay free graft urethroplasty for anterior urethral stricture, and two-stage surgery was transperineal stricture resection and tension-free end to end anastomosis for posterior urethral stricture (**Figure 2**). The mean (range) interval time of two steps were 83 (50-140) days.

Prognosis

Urethrography taken 1 month after the surgery indicated no obvious narrowing in all 19 patients. The median (range) follow-up time was 25.8 (3-56) months. 4 patients (21.1%) recurred urethral stricture during follow-up, and the locations of recurred stricture were bulbomembranous urethra (2 cases), bulbar urethra (1 case) and bladder neck (1 case). 3 of recurred patients restored to health through urethral dilation, yet 1 underwent a second operation. 2 cases (10.5%) complaint of dripped urination, but no one had painful erection or stress urinary incontinence. No complications occurred such as wound infection, urinary fistula or urinary diverticulum. Success, recurrence and complication rates of each subgroup are shown in **Table 3**.

Discussion

The managements for 19 patients diagnosed with anterior combined with posterior urethral stricture following our standard process in West China Hospital from 2005 to 2013 were described in this study. Surgical success rate for 19 patients was 100%, and recurrence and complication rate during follow-up period was 21.1% (4 cases) and 10.5% (2 cases) respec-

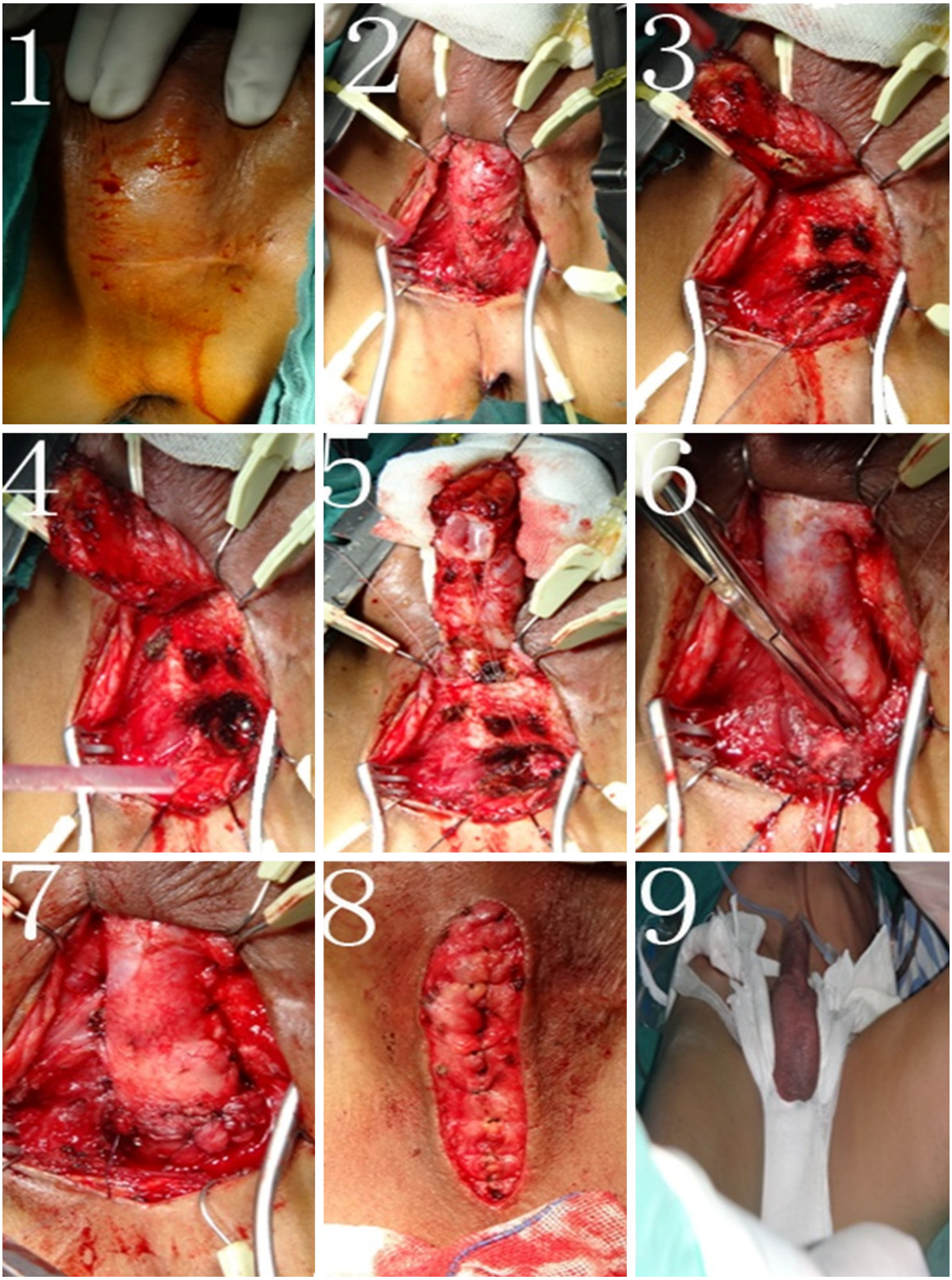

Figure 2. Two-stage open reconstructive urethroplasty for posterior urethral stricture. This patients belongs to Group IV, who had undergone a one-stage open reconstructive urethroplasty for anterior urethral stricture 140 days ago.

tively. What's more, 4 recurrent cases all restored to health through transurethral endoscopic treatment or urethral dilation. No complications occurred such as wound infection,

Table 3. Results of surgical therapy during follow-up period

	No.	Degree of narrowing		Stricture length/cm		Success		Recurrence		Complication	
		Anterior	Posterior	Anterior	Posterior	No.	%	No.	%	No.	%
Group I	9	Non-obliteration	Non-obliteration	1.7 ± 1.2	1.1 ± 0.3	9	100	4	44.4	1	11.1
Group II	2	Obliteration or transection	Non-obliteration	6.5 ± 2.1	1.8 ± 0.4	2	100	0	0	0	0
Group III	3	Non-obliteration	Obliteration or transection	1	2.3 ± 0.4	3	100	0	0	0	0
Group IV	5	Obliteration or transection	Obliteration or transection	2.3 ± 1.8	1.8 ± 0.5	5	100	0	0	1	20

urinary fistula or urinary diverticulum. This is the first original article described a standard process of management for anterior combined with posterior urethral stricture. Due to the difficulty and controversy in the management of the anterior combined with posterior urethral stricture and no guidelines or reports have appeared yet for directions, our 9-year single centre experience of standard managements can provide some degree of references for urologists.

According to our data, iatrogenic operation, mainly the prostate electroexcision in our study, has gradually become a leading cause of the anterior combined with posterior urethral stricture. Reports showed the incidence of urethral stricture after prostate electroexcision was 1.8%-6.9% [3], but no statistics of the anterior combined with posterior urethral stricture reported. Other iatrogenic operation contains transurethral prostatectomy, urethral dilation and indwelling catheter. In these cases, we have to take measures to avoid injury or stimulation of the urethral tissue, as the enough control of the urinary tract infection, adequate lubrication during operation and temperate perfusate [4, 5].

Furthermore, as trauma weighs the most among factors causing the anterior combined with posterior urethral stricture, appropriate early treatments must benefit for further ones. Towler and Melekos etc. mentioned that in addition to the suprapubic catheterization, early urethral realignment over a splinting catheter by instrumentation and endoscopy via both suprapubic and urethral routes should also be involved in the primary treatments [6, 7]. As is proved by some studies, early urethral realignment could help to prevent intractable urethral stricture and reduce the cost [8].

12 patients having urinary tract infectious symptoms or positive urine culture result shared the percentage as high as 63.2%. All pathogen turned out to be gram-negative bacteria. We analyzed that pelvic trauma could lead to infection directly and the infectious incidence after prostate electroexcision may reach to 21.6% as reported [9]. As a consequence, we have to consider the possibility of urinary tract infection besides conducting the suprapubic catheterization before those patients undergo selective operation for their urethra stricture. We advise the preventive use of antibiotics in addition to the regular handling and the improved nursery of suprapubic puncture syrinx to reduce the infectious incidence so that patients could feel less uncomfortable and have better outcomes.

Blood supply of male urethra depends on the anatomical positions. The branches of internal pudendal artery, urethral bulbar artery and urethral artery supply the anterior urethra, while the posterior urethra relies on the prostate branches of inferior vesical artery, middle hemorrhoidal artery and branches of internal pudendal artery. Although plenty of anastomotic branches exist between anterior and posterior urethra, the main blood supply of corpus spongiosum is axial. When single anterior or posterior urethral stricture received open urethroplasty surgery causes amputation of corpus spongiosum, the urethra mainly depends on its proximal and distal axial blood supply. However, if open urethroplasty surgeries are applied for both anterior and posterior urethral strictures at the same time, the urethra between two stricture sites will lack blood supply. That is to say, for the anterior combined with posterior urethral stricture, when both of the anterior and posterior urethral strictures need to be operated on, we have to choose a staging operation in order to avoid undesirable healing or even necrosis due to the short blood supply. However, the operation sequence remains no consistent idea and no reports have been published yet.

In our standard process of management for the anterior combined with posterior urethral stricture, we treated anterior urethral stricture first.

We established this principle based on the following reasons. First, as the main causes of anterior combined with posterior urethral stricture were pelvic traumas, and guideline recommends that one-stage indwelling catheter or suprapubic cystostomy and two-stage urethra reconstruction for urethral trauma [10]. According to the guideline, surgery of the anterior urethra should be 3 months after trauma, and that of the posterior urethra should be taken in 6 months. We handled anterior urethral stricture first, in this way, we could make certain the anterior urethra gains enough blood supply for resolving well after reconstruction, and will not miss the opportunity of the surgery on the posterior urethra. Second, a stent tube is needed to be indwelt after surgery for urethral stricture for the healing of wound surface, reducing the recurrence, and so on. For the patients with anterior combined with posterior urethral stricture, if we treat posterior urethral stricture first, then a stent tube cannot be indwelt in the posterior urethra through the narrow anterior urethra. Final, as the success rates of open reconstructive urethroplasty for anterior and posterior urethral strictures are 85-90% [11, 12] and 93% [13] respectively, we considered that the harder one should be treated first, which may make the second-stage surgery easier and gain a higher overall success rate.

When the narrowing is not obliterated, direct vision internal urethrotomy (DVIU) has a good effect on the primary bulbar or membranous urethral stricture with shorter narrowing (less than 1.5 centimeters). It had a fairly high success rate (75%) for the bulbar urethral stricture as reported [14]; however, the recurrence rate was also 50%-60% [14, 15]. A prospective study revealed DVIU was not superior to the urethral dilation [16]. Therefore, in our standard process, we considered DVIU or urethral dilation as a priority therapy for the short and mild scarred anterior and posterior urethral stricture, both of which are not obliterated.

For the anterior urethral stricture completely obliterated or not suitable for transurethral endoscopic treatment, such as the long narrowing (more than 1.5centimeters) or recurred urethral stricture, open urethroplasty is essential. The treatment has a long-term success rate of 90% through the stricture resection plus end to end anastomosis applied on the narrowing shorter than 2.5 centimeters in bulbar urethral stricture [17-19]. Nevertheless, if the same method is used on narrowing longer than 2.5 centimeters in bulbar or penile urethral stricture, patients tend to have penis curvature or pain erection. On this occasion, we should conduct free graft urethroplasty [20]. 7 patients in our study underwent the dorsal plus ventral onlay free graft urethroplasty enjoying a higher success rate and abundant cover of the scar tissue by epithelium, for fear of recurred narrowing to the greatest extent [21].

For the posterior urethral stricture completely obliterated or not suitable for transurethral endoscopic treatment, thorough stricture resection plus tension-free end to end anastomosis urethroplasty has long been regarded as an effective method. In terms of the surgery difficulties and high requirements of doctors, we performed the mucosal eversion end-to-end anastomosis.

For the patients with both anterior and posterior urethral strictures needed open urethroplasty, after one-stage open urethroplasty for anterior urethral stricture, scarring and adhesion in the operating site of anterior urethra may reduce the ductility of urethra, which could make the two-stage stricture resection plus tension-free end-to-end anastomosis for posterior urethral stricture difficult. However, with the development of open urethroplasty for posterior urethral stricture, several surgical techniques have been applied to improve the efficacy of tension-free end-to-end anastomosis, such as corporal splitting, partial pubectomy, and so on [22, 23]. In the two-stage open urethroplasty for posterior urethral stricture, we also utilized corporal splitting, partial pubectomy, and the good ductility of bulbar urethra, which made the tension-free end-to-end anastomosis satisfactory. All 5 patients got desired efficacy.

Time of indwelling multiple side hole silastic tube lasted for 4-6 weeks (mean indwelling time was 30.5 ± 4.9 days), in accordance with many recent studies [24-26]. Longer time of indwelling stent tube is beneficial for the healing of wound surface, edema vanishing, avoiding infection and poor healing caused by urine permeating, preventing urethral displacement before healing and reducing the recurrence. However, several studies chose a shorter time [2, 27], since the present opinion demonstrates

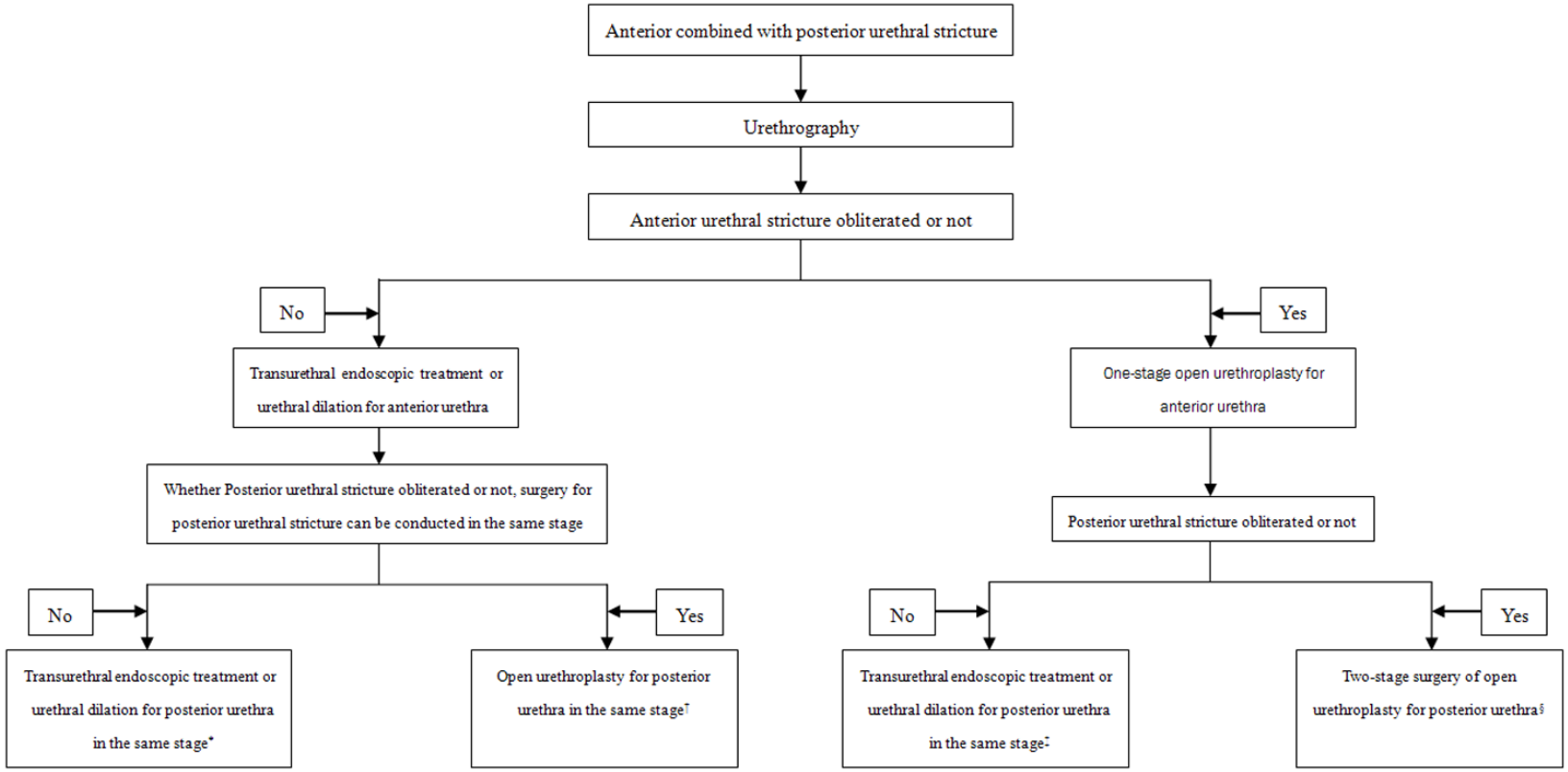

Figure 3. Standard management of the anterior combined with posterior urethral stricture. *9 cases in our study. Symptoms recurred in 4 (44.4%) of them during the follow-up. 1 case complaint of dripped urination. No other complications occurred. †3 cases in our study. No one recurred during the follow-up. No complications occurred. ‡2 cases in our study. No one recurred during the follow-up. No complications occurred. §5 cases in our study. No one recurred during the follow-up. 1 case complaint of dripped urination. No other complications occurred.

the longer time stent tube stays, the higher infectious rate appears [28, 29]. What's more, even prophylactic use of antibiotics cannot reduce the incidence of urinary infection [30]. However, among our 19 patients, no infection happened. We assume that indwelling stent tube for 4-6 weeks contribute to recovery of the injured urethra and do not increase the infectious rate. However, further prospective studies are needed to confirm this assumption.

So far, there are few studies on the treatment of anterior combined with posterior urethral stricture, yet some have reported the treatment of long-segment urethral stricture extending from anterior to posterior urethra. Tavakkoli Tabassi et al. [31] treated 17 pan-urethral stricture patients with one-stage transperineal dorsally placed buccal mucosal grafts urethroplasty, all of whose strictures extending from anterior to posterior urethra. Its success rate was 88.2%, while recurrence and complication rate during follow-up time was 17.6% (3 cases) and 35.3% (6 cases) respectively, which are similar to our results. Mathur et al. [32] adopted tunica albuginea urethroplasty for 86 patients with pan-urethral stricture, and the recurrence rate was 10.5% (9 cases) after 3 years' follow-up. Its low recurrence rate may due to low percentage of patients with strictures extending to posterior urethra (24/86, 27.9%). Considering the treatment efficacy of single anterior or posterior urethral stricture, internal urethrotomy is similar to urethral dilation, whose success rates vary widely, ranging from 8-80% [11, 33, 34], and recurrence rate is 50-60% [10, 11]. What's more, success rates of open reconstructive urethroplasty for anterior and posterior urethral strictures are 85-90% [11, 12] and 93% [13] respectively. Thus, the efficacy of our standard managements for 19 patients with anterior combined with posterior urethral stricture is not worse than the treatment efficacy of single anterior or posterior urethral stricture.

Above all, in our standard process of managements for the anterior combined with posterior urethral stricture, situation of anterior urethral stricture should be taken into primary consideration when design surgeries. First, endoscopic surgery or urethral dilation is applied for anterior urethra stricture as a priority as long as obliteration does not occur, and operation for posterior urethral stricture can be conducted in the same stage. Second, when obliteration happens to anterior urethra, an open reconstructive urethroplasty is needed; while in this condition, the unobliterated posterior urethra can also be treated with endoscopic surgery or urethral dilation in the same stage. Final, if anterior and posterior urethra obliterations both exist, open reconstructive urethroplasty for posterior urethral stricture should be applied 2-3 months later. We suggest the following algorithm for the management of anterior combined with posterior urethral stricture (**Figure 3**).

Some limitations should be stated about this study. First, insufficient patients were included in this study because of uncommon cases. Second, the follow-up time of some patients was inadequate. Thus, our experience of therapy for the anterior combined with posterior urethral stricture should be treated as preliminary.

Conclusion

We recommended that anterior urethral stricture in patients with anterior combined with posterior urethral stricture should be treated first. And according to our 9-year single centre experience, this standard process of management for the anterior combined with posterior urethral stricture is effective and safe.

Acknowledgements

We would like to thank all our teachers and colleagues in the Department of Urology, West China Hospital, Sichuan University for their supports to this work.

Disclosure of conflict of interest

None.

Address correspondence to: Kunjie Wang, Department of Urology, West China Hospital, Sichuan University, No. 37 Guo Xue Xiang, Chengdu, Sichuan, 610041, P.R. China. Tel: 86-18980601848; E-mail: wangkj@scu.edu.cn

References

[1] Anger JT, Buckley JC, Santucci RA, Elliott SP and Saigal CS. Trends in stricture management among male Medicare beneficiaries: underuse of urethroplasty? Urology 2011; 77: 481-485.

[2] Xu YM, Qiao Y, Sa YL, Wu DL, Zhang XR, Zhang J, Gu BJ and Jin SB. Substitution urethroplasty of complex and long-segment urethral stricturest: a rationale for procedure selection. Eur Urol 2007; 51: 1093-1098.
[3] Nabi G, Devinder S, Dogra RN and Dinda AK. Malignant anterior urethral strictures: a rare complication of transurethral resection of malignant prostate. Int urol Nephrol 2002; 34: 73-74.
[4] Rassweiler J, Teber D, Kuntz R and Hofmann R. Complications of transurethral resection of the prostate (TURP)-incidence, management, and prevention. Eur Urol 2006; 50: 969-980.
[5] Park JK, Lee SK, Han SH, Kim SD, Choi KS and Kim MK. Is warm temperature necessary toprevent urethral stricture in combined transurethral resection andvaporization of prostate? Urology 2009; 74: 125-129.
[6] Towler JM and Eisen SM. A new technique for the management of urethral injuries. Br J Urol 1987; 60: 162-6.
[7] Melekos MD, Pantazakos A, Daouaher H and Papatsoris G. Primary endourologic re-establishment of urethral continuity after disruption of prostatomembranous urethra. Urology 1992; 39: 135-8.
[8] Chang PC, Hsu YC, Shee JJ, Huang ST, Huang HC, Chen Y and Hsieh ML. Early Endoscopic Primary Realignment Decreases Stricture Formation and Reduces Medical Costs in Traumatic Complete Posterior Urethral Disruption in A 2-Year Follow-up. Chang Gung Med J 2011; 34: 179-85.
[9] Colau A, Lucet JC, Rufat P, Botto H, Benoit G and Jardin A. Incidence and risk factors of bacturia after transurethral resection of the prostate. Eur Urol 2001; 39: 272-276.
[10] Summertom DJ, Djakovic N, Kitrey ND, Kuehhas F and Lumen N, Serafetinidis E. Guidelines on Urological Trauma. European Association of Urology 2013.
[11] Naudé AM and Heyns CF. What is the place of internal urethrotomy in the treatment of urethral stricture disease? Nat Clin Pract Urol 2005; 2: 538-545.
[12] Wong SS, Aboumarzouk OM, Narahari R, O'Riordan A and Pickard R. Simple urethral dilation, endoscopic urethrotomy, and urethroplasty for urethral stricture disease in adult men. Cochrane Database Syst Rev 2012; 12: CD006934.
[13] Cooperberg MR, McAninch JW, Alsikafi NF and Elliott SP. Urethral reconstruction for traumatic posterior urethral disruption: outcomes of a 25-year experience. J Urol 2007; 178: 2006-2010.
[14] Pansadoro V and Emiliozzi P. Internal urethrotomy in the management of anterior urethral strictures: long-term followup. J Urol 1996; 156: 73-75.
[15] Verges J, Desgrez JP, Claude JM and Cabane H. Internal urethrotomy. Resection of urethral stricture (over 5 years' follow-up). Ann Urol 1990; 24: 73-75.
[16] Steenkamp JW, Heyns CF and de Kock ML. Internal urethrotomy versus dilation as treatment for male urethral strictures: a prospective, randomized comparison. J Urol 1997; 157: 98-101.
[17] Santucci RA, Mario LA and McAninch JW. Anastomotic urethroplasty for bulbar urethral stricture: analysis of 168 patients. J Urol 2002; 167:1715-9.
[18] Eltahawy EA, Virasoro R, Schlossberg SM, McCammon KA and Jordan GH. Long-term follow-up for excision and primary anastomosis for anterior urethral strictures. J Urol 2007; 177: 1803-6.
[19] Barbagli G, De Angelis M, Romano G and Lazzeri M. Long-term follow-up of bulbar end-to-end anastomosis: a retrospective analysis of 153 patients in a single center experience. J Urol 2007; 178: 2470-3.
[20] Andrich DE and Mundy AR. What is the best technique for urethroplasty? Eur Urol 2008; 54: 1031-41.
[21] Jiang LH, Li H, Jin T and Wang KJ. Clinical treatment of anterior urethral stricture using dorsal plus ventral free-graft urethroplasty. J Sichuan Univ (Med Sci Edi) 2011; 42: 736-738.
[22] Fu Q, Zhang J, Sa YL, Jin SB and Xu YM. Transperineal bulboprostatic anastomosis in patients with simple traumatic posterior urethral strictures: a retrospective study from a referral urethral center. Urology 2009; 74: 1132-6.
[23] Kizer WS, Armenakas NA, Brandes SB, Cavalcanti AG, Santucci RA and Morey AF. Simplified reconstruction of posterior urethral disruption defects: limited role of supracrural rerouting. J Urol 2007; 177: 1378-81.
[24] Erickson BA, Breyer BN and McAninch JW. Single-stage segmental urethral replacement using combined ventral onlay fasciocutaneous flap with dorsal onlay buccal grafting for long segment strictures. BJU Int 2011; 109: 1392-1396.
[25] Meeks JJ, Erickson BA and Gonzalez CM. Full-Thickness Abdominal Skin Graft for Long-Segment Urethral Stricture Reconstruction. Int Braz J Urol 2008; 34: 602-608.
[26] Kumar S, Bansal P, Vijay MK, Dutta A, Tiwari P, Sharma PK, Goel A, Bera MK, Kundu AK and Hazra A. Buccal Mucosal Graft Urethroplasty in Long Segment Anterior Urethral Stricture - Is it Gold Standard? Saudi J Kidney Dis Transpl 2013; 24: 115-120.
[27] Onol SY, Onol FF, Gümüş E, Topaktaş R and Erdem MR. Reconstruction of distal urethral

strictures confined to the glans with circular buccal mucosa graft. Urology 2012; 79: 1158-1162.
[28] Saint S, Lipsky BA and Goold SD. Indwelling urinary catheters: a one-point restraint. Ann Intern Med 2002; 137: 125-128.
[29] Cornia PB, Amory JK, Fraser S, Saint S and Lipsky BA. Computer-based order entry decreases duration of indwelling urinary catheterization inhospitalized patients. Am J Med 2003; 114: 404-407.
[30] Niel-Weise BS and van den Broek PJ. Antibiotic policies for short-term catheter bladder drainage in adults. Cochrane Database Syst Rev 2005; 20: CD005428.
[31] Tavakkoli Tabassi K, Mansourian E and Yarmohamadi A. One-stage transperineal repair of pan-urethral stricture with dorsally placed buccal mucosal grafts: results, complications, and surgical technique. Urol J 2011; 8: 307-312.
[32] Mathur RK and Sharma A. Tunica albuginea urethroplasty for panurethral strictures. Urol J 2010; 7: 120-124.
[33] Santucci R and Eisenberg L. Urethrotomy has a much lower success rate than previously reported. J Urol 2010; 183: 1859-1862.
[34] Greenwell TJ, Castle C, Andrich DE, MacDonald JT, Nicol DL and Mundy AR. Repeat urethrotomy and dilation for the treatment of urethral stricture are neither clinically effective nor cost-effective. J Urol 2004; 172: 275-277.