

## Case Report

# Giant hydronephrosis secondary to ureteropelvic junction obstruction in adults: report of a case and review of literatures

Guanghui Hu, Min Luo, Yunfei Xu

*Department of Urology of Shanghai Tenth People's Hospital, Tongji University, Shanghai, China*

Received December 26, 2014; Accepted February 20, 2015; Epub March 15, 2015; Published March 30, 2015

**Abstract:** Giant hydronephrosis is rare to be seen in adults. Herein, we report a case of a 20-year-old male referred for abdominal pain. A radiological study revealed a giant left hydronephrosis. Nephrectomy was performed. During the operation, the ureteropelvic junction obstruction position was revealed.

**Keywords:** Giant hydronephrosis, ureteropelvic junction obstruction

### Introduction

The Majority of published cases of giant hydronephrosis occur in infants and children, and are congenital ureteropelvic junction. It's uncommon in adults and is easy to be misdiagnosed. The aim of this paper is to present one case of giant hydronephrosis in adult along with a review of the current literature.

### Case report

A 20-year-old male referred to our urology emergency clinic with abdominal pain. He had diffuse abdominal pain and persistent constipation for several months but denied having urological symptoms. The boy referred to physical outpatient clinic several times, but physicians simply diagnosed it as digestive system disorders and prescribed some pills for him. The patient felt a little better. However, the pain got severe after playing basketball two weeks ago. The physical examination revealed a protuberant abdomen with a mildly tender, palpable mass on the left side that extended across the midline. Pertinent laboratory data were white blood cell count  $4.87 \times 10^9/L$ , red blood cell count  $4.46 \times 10^{12}/L$ , platelets count  $138/L$ , creatinine  $106.2 \mu\text{mol}/L$ , albumin  $49 \text{ g}/L$ .

Computerized tomography revealed a massive pelvicaliceal dilatation of the left kidney cross-

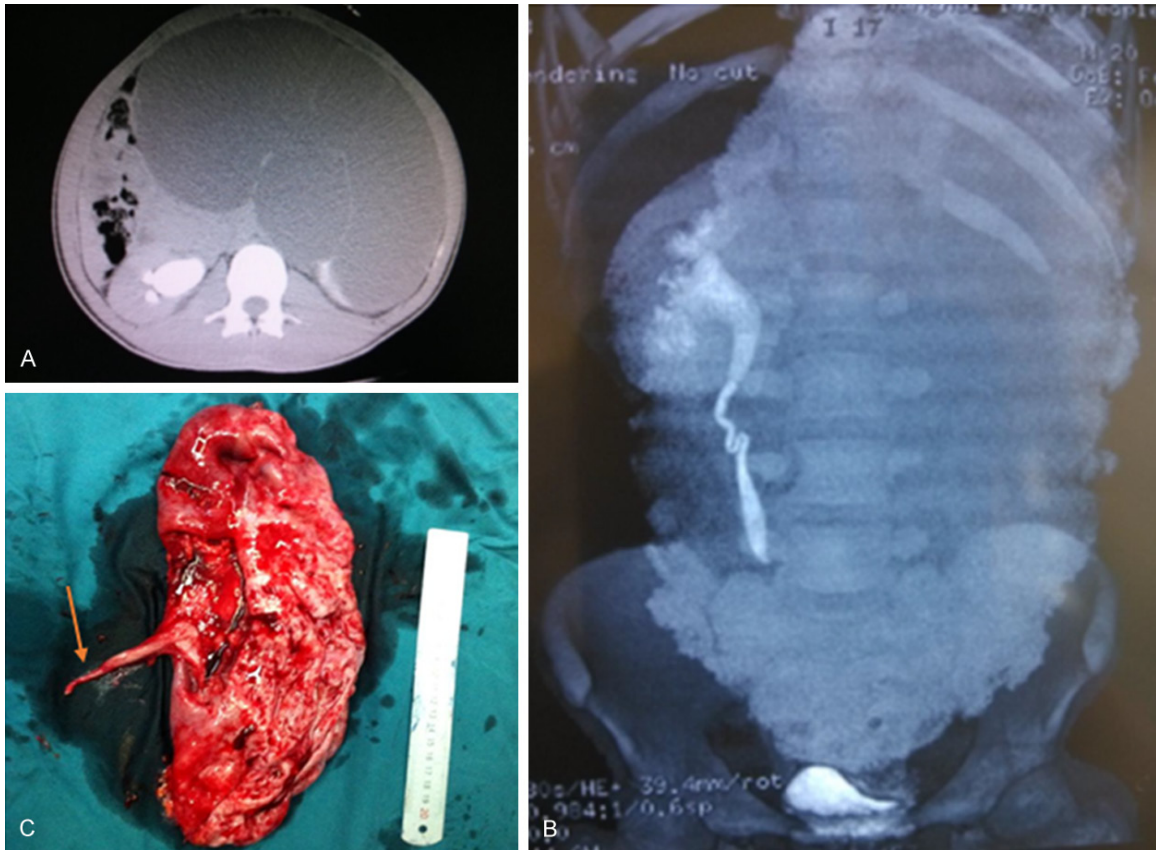
ing the midline and extending into the pelvis (**Figure 1**). The mass extended to the right kidney, squeeze the adjacent organs, even the right upper ureter was squeezed which lead to hydronephrosis of right kidney. No significant parenchymal uptake was noted on the left side. The nephro-dynamic imaging showed the bilateral glomerular filtration rate (GFR) were  $1.43 \text{ ml}/\text{min}$  (left) and  $74.48 \text{ ml}/\text{min}$  (right).

In consideration of the mass was too huge, open left nephrectomy was performed to remove the huge hydronephrosis. No solid elements suspicious for malignancy were identified intraoperatively. 8000 ml fluid was sucked out from the collecting system during the operation. The obstruction position was found and revealed. Histopathological examination of the specimen confirmed massive dilatation of the pelvicaliceal system and chronic inflammatory responses. Convalescence was uneventful.

### Discussion

Giant hydronephrosis is rare to be seen in adults. In 1939, Stirling defined giant hydronephrosis as the presence of fluid exceeding 1,000 ml in the collecting system [1]. Now more than 600 cases have been reported worldwide to date, with most cases reported within the last 15 years [2].

## Giant hydronephrosis secondary to ureteropelvic junction obstruction



**Figure 1.** CT (A) and CTU (B) revealed a massive pelvicaliceal dilatation of the left kidney crossing the midline and extending into pelvis. The left kidney is almost no function left. Ureteropelvic junction obstruction were identified intraoperatively. The whole kidney display a cystic change (C).

Ureteropelvic junction (UPJ) obstruction is the most frequently revealed cause of hydronephrosis with an estimated incidence of 1 in 1000-1500 [3]. Other causes including ureter calculous, transitional cell carcinoma of pelvis, squamous cell carcinoma of the renal pelvis or renal, ureteral ectopia, duplicated collecting system, renal malformations, polar or aberrant vessels have been described in adults [4-7]. UPJ obstruction is mostly considered as a functional obstruction originating from abnormalities in the smooth muscle of the pelvis and ureter [8]. Due to the patient had not been detected after born, and without any symptoms before diagnosed, we couldn't figure out the congenital or postnatal cause of the UPJ obstruction. However, the patient got lung tuberculosis nearly ten years ago. Although cured, the patient couldn't remember the detail and we couldn't trace the medical record either.

Even giant hydronephrosis has been reported over 600 cases, it is still not easy to differen-

tially diagnosis. It usually presents with vague symptoms such as nausea, fatigue or dyspepsia, urinary tract infection, renal insufficiency, or gross hematuria after trauma in adults [9]. Giant hydronephrosis is a slowly progressive disease; patients may remain asymptomatic until late phase [10]. A wide range of differential diagnosis includes intraperitoneal, and retroperitoneal cysts, pseudomyxoma, renal tumor pancreatic pseudocysts, retroperitoneal tumor, and ovarian cysts or tumor [11]. The most important aspect of management is early diagnosis with accurate pre-operative delineation of anatomy of the affected kidney. The initial clinical diagnosis in our patients was also incorrect. The patient simply complained about the mild diffuse abdominal pain or uncomfortable feeling and persistent constipation in the outpatient department. All the symptoms which were similar to the presentation of gastrointestinal disease can easily confound physician's diagnosis. Usually, it is not likely consider a giant hydronephrosis diagno-

## Giant hydronephrosis secondary to ureteropelvic junction obstruction

sis firstly. Awareness of this situation, the clinician and radiologist could readily diagnose and provide appropriate therapy. Nowadays, diagnostic instruments such as enhanced CT scans, antegrade or retrograde and excretory urograms, ultrasonography have facilitated the diagnosis of hydronephrosis, accurate diagnosis of giant hydronephrosis in individual cases is improved.

Management of giant hydronephrosis is surgical. Nephrectomy is the usual method of treatment, as there is often poorly functioning renal tissue. Taking into consideration the huge volume of kidney, open surgery usually is the first choice. Recently, some researchers have reported using laparoendoscopic retroperitoneoscopic nephrectomy and found it is technically feasible and safe for selected patients [13]. However, the safe and efficacy needs to be compared trial with open nephrectomy. In our case the patient underwent open nephrectomy, and the patient was discharged uneventfully at the 9th postoperative day.

### Disclosure of conflict of interest

None.

**Address correspondence to:** Dr. Ming Luo or Dr. Yunfei Xu, Department of Urology of Shanghai Tenth People's Hospital, Tongji University, Shanghai, China. E-mail: lm1191@163.com (ML); dhguanghui@gmail.com (YFX)

### References

- [1] Crooks KK, Hendren WH, Pfister RC. Giant hydronephrosis in children. *J Pediatr Surg* 1979; 14: 844-50.
- [2] Ochsner MG, Fuselier HA Jr, Brannan W, Simo JB. Congenital giant hydronephrosis in adults. *Urology* 1977; 10: 422.
- [3] Chang CP, McDill BW, Neilson JR, Joist HE, Epstein JA, Crabtree GR, Chen F. Calcineurin is required in urinary tract mesenchyme for the development of the pyeloureteral peristaltic machinery. *J Clin Invest* 2004; 113: 1051-1058.
- [4] Demirtaş A, Sahin N, Akınsal EC, Ekmekçiöğlü O, Tatlışen A. Primary obstructive megaureter with giant ureteral stone: a case report. *Case Rep Urol* 2013; 19: 85-92
- [5] Ashraf SM, Raza MH, Aziz M, Maheshwari V. A rare association of giant hydronephrosis and transitional cell carcinoma. *J Indian Med Assoc* 1991; 89: 277.
- [6] Ujike T, Noda Y, Oka D, Takada S, Fujimoto N, Koide T, Kobayashi Y. Squamous cell carcinoma of the renal pelvis with giant hydronephrosis. *Hinyokika Kyo* 2003; 49: 757-9.
- [7] Kimura R, Koyama K, Abe H. A case of sarcomatoid renal cell carcinoma associated with giant hydronephrosis. *Hinyokika Kyo* 2012; 58: 435-8.
- [8] Mendelsohn C. Functional obstruction: the renal pelvis rules. *J Clin Invest* 2004; 113: 957-959.
- [9] Kaya C, Pirincci N, Karaman MI. A rare case of an adult giant hydronephrosis due to ureterovesical stricture presenting as a palpable abdominal mass. *Int Urol Nephrol* 2005; 37: 681-683.
- [10] Ardiçoğlu A, Yüzgeç V, Atikeler MK. Case of adult giant hydronephrosis as unusual cause of intraabdominal mass. *Int Urol Nephrol* 2003; 35: 2003.
- [11] Mountney J, Chapple CR, Johnson AG. Giant hydronephrosis-a diagnostic dilemma. *Urol Int* 1998; 61: 121-123.
- [12] Tombari AA, Power RF, Harper JM, Politano VA. Giant hydronephrosis-a case report with review of the literature. *J Urol* 1968; 100: 120-3.
- [13] Wu ZH, Xu YM, Yu JH, Chen J, Liu J, Wang S, Chen K. Laparoendoscopic single-site retroperitoneoscopic nephrectomy for giant. *J Endourol* 2014; 28: 1328-32.