

## Original Article

# Children with congenital cystic adenomatoid malformation of the lung CT diagnosis

Zeng-Jun Zhang, Ming-Xia Huang

Department of CT, Children Hospital of Xi'an, Xi'an 710002, Shaanxi Province, PR China

Received January 9, 2015; Accepted February 24, 2015; Epub March 15, 2015; Published March 30, 2015

**Abstract:** In this study, we aim to investigate the imaging appearances of congenital cystic adenomatoid malformation (CCAM) of the lung, and to enhance the understanding of this disease. A total of 11 cases with CCAM of the lung were confirmed by surgery and pathology. Preoperative chest computed tomography (CT) scan was performed in all patients, and high resolution CT scan was performed in lesion areas of 7 cases. Our results showed that there were 3 cases involving left and right lung, 5 cases involving right lung and 3 cases involving left lung. CT scan showed 6 cases with single or multiple air-filled cavities ( $> 2$  cm in diameter) and 5 cases with multiple honeycomb-like cysts ( $< 1$  cm in diameter). The cysts of CCAM contained air in 9 cases and a small amount of liquid in 2 cases. The complications of CCAM included different degree of emphysema in 7 patients, mediastinal hernia in 5 cases and congenital pulmonary sequestration in 1 case. All lesions have certain space-occupying effect. In conclusion, CT manifestation of CCAM of lung has certain characteristics and can provide reliable information for diagnosis of the disease.

**Keywords:** Cystic adenomatoid malformation, congenital, CT diagnosis

## Introduction

Congenital cystic adenomatoid malformation (CCAM) is a rare congenital developmental deformity of the lower respiratory tract, with its cause remaining yet unknown. CCAM accounts for 25% of congenital pulmonary malformations, and most cases of CCAM are found in neonates and infants while are infrequent in adulthood [1, 2]. The pathological changes of CCAM patients include expansion of pulmonary lobe or segment, single or multiple cystic shadows, and ipsilateral pulmonary tissue compression and pulmonary hypoplasia. The main clinical manifestations are coughing, fever, asthma and other recurrent respiratory tract infection symptoms. CCAM is often misdiagnosed as pulmonary cyst, pulmonary bullae and pneumothorax by X-ray examination. In recent years, with the progress of inspection technology, especially the application of multi-slice spiral CT and post-processing software, the image diagnosis rate is getting higher and higher. This enhances the understanding of CCAM, and its diagnostic reports also gradually increased.

In this study, we performed multi-slice spiral CT on 11 cases of CCAM confirmed by operation and pathology in our hospital from January 2006 to March 2012. We present the clinical features and radiological findings of 11 CCAM patients to provide reliable information for diagnosis of the disease.

## Subjects and methods

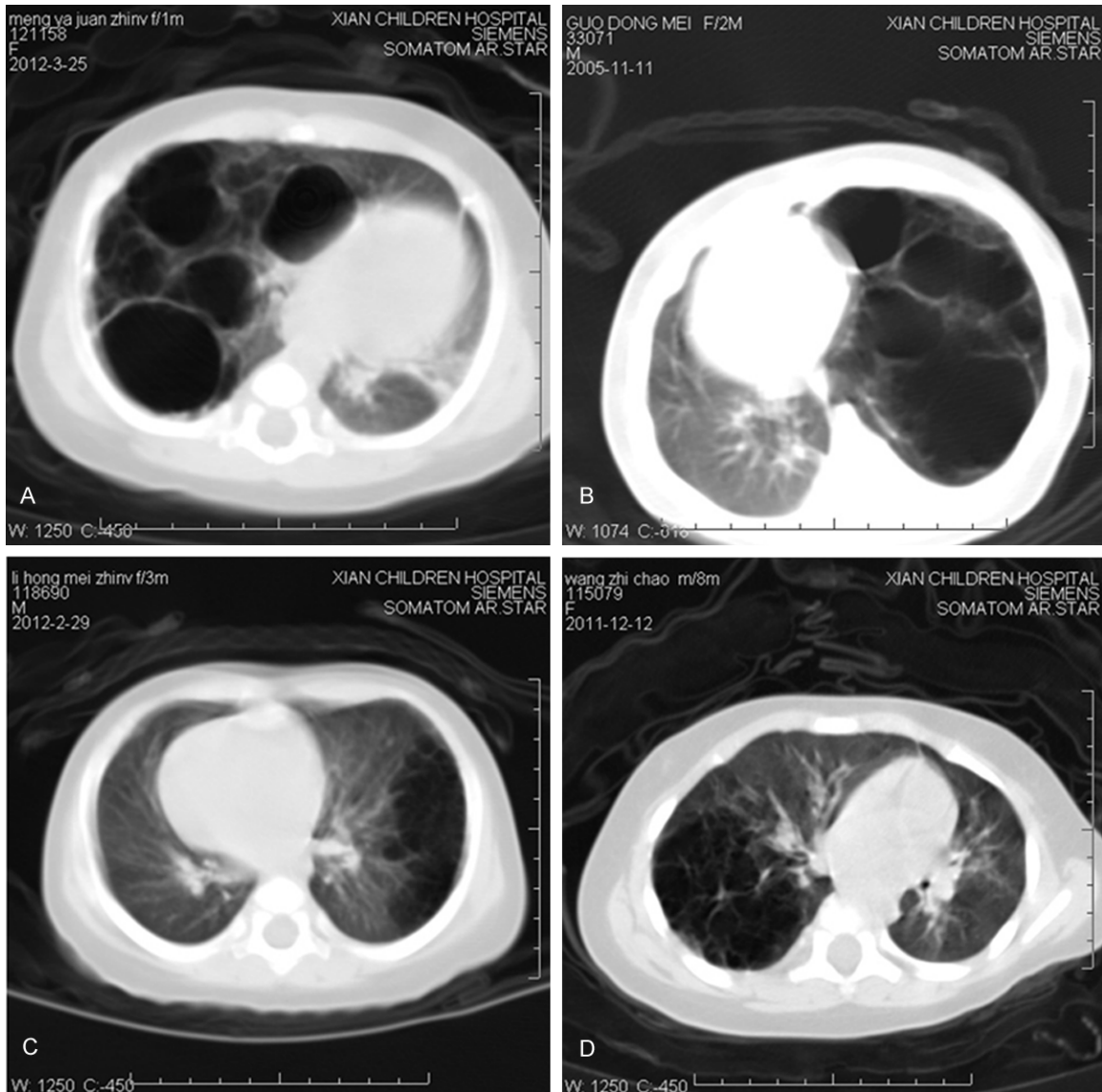
### Subjects

Among 11 cases of CCAM there were 6 male and 5 female, with the mean age of 2.7 years old, aging from 6 days to 4.5 years old. Clinical manifestations included recurrent respiratory tract infection, coughing, fever and asthma, with history of 9 days to 4 years. The 11 cases of CCAM were all confirmed by operation, pathology and preoperative chest CT scan. High resolution CT scanning was performed on lesion areas of 7 cases.

### CT scan

The SOMATOM AR-star whole body spiral CT scanner (Siemens Company, Germany) was

## Diagnosis of Children with CCAM by CT



**Figure 1.** The CT manifestations of CCAM. A. Right lower pulmonary lobe shows cystic shadow of different sizes with diameter > 2 cm, the cystic wall thickness varies, with a number of lucency shadow among vesicles. The heart shadow is shifted leftward. B. Left lower pulmonary lobe shows cystic shadow of different sizes with 2~6 cm in diameter, with thin and irregular wall. The surrounding lung tissue is compressed and shows ring morphology. The mediastinal heart shadow is shifted rightward. C. Left lower pulmonary lobe shows cystic shadow of different sizes with diameter < 1 cm. The wall is thin and irregular, and the mediastinal heart shadow is shifted rightward. D. Right lower pulmonary lobe shows multiple small cystic shadow of honeycomb like, and the mediastinal heart shadow is shifted rightward.

used in scanning. Chest routine scanning of the lesion site was performed followed by high resolution scanning with 5 mm slice thickness. Retention enema with 10% chloral hydrate (0.5~0.8 ml/kg) was performed in uncooperative children.

### Results

There were 3 cases involving left and right lung, 5 cases involving right lung, and 3 cases

involvement left lung. CT manifestations showed 6 cases with single or multiple air-filled cavities (> 2 cm in diameter) (**Figure 1A, 1B**), and 5 cases with multiple honeycomb like cavity (< 1 cm in diameter) (**Figure 1C, 1D**). Among all 11 cases of CCAM, cysts contained air in 9 cases and contained a small amount of liquid in 2 cases. There were 7 cases complicated with different degree of emphysema, 5 cases complicated with mediastinal hernia and 1 case

complicated with congenital pulmonary sequestration. All lesions have certain space-occupying effect.

### Discussion

#### *The etiology and pathogenesis of CCAM*

CCAM is a hamartoma like cystic malformation disease caused by abnormal pulmonary development, with a very low incidence in children. There is no unified understanding of CCAM etiology [2]. Now it is believed that CCAM is a developmental anomaly characterized by excessive bronchioles growth, which is similar to hamartoma, but generally no cartilage tissue. In embryonic development process, defects in bronchial lung buds and branch may occurs by unknown factors, leading to bronchial atresia, absence bronchus, and the formation of the hamartoma like malformation. Cass detected cell proliferation and apoptosis index in all CCAM lesions and normal lung tissues whose gestational weeks were matched. He found that compared with normal lung tissues, in CCAM lesions cell proliferation index was increased by 2 fold and apoptotic body was reduced by 5 fold, and this indicated that CCAM may be caused by cell proliferation and apoptosis imbalance in lung development stage [3]. Other scholars proposed that the occurrence of CCAM may be related to abnormal expression of glial cell line-derived neurotrophic factor (GDNF), Hoxb 5, cyclin D1 and PCNA genes [4, 5]. In 1977, Stocker [6] divided CCAM according to the histopathology into three types: type I accounts for 75% of CCAM and consists of a single or a plurality of vesicles with different sizes, including at least one sac with diameter > 2 cm. The sac is covered with pseudostratified ciliated columnar epithelium, containing smooth muscle in thin cyst wall and a small amount of elastic fibers, with mucinous epithelium and cartilage in part cases; type II accounts for 0%~15% of CCAM and consists of a plurality of vesicles with diameter < 1 cm, with their sac covered with cilia cube and columnar epithelium; type III consists of larger solid masses and countless vesicles of alveolar size (< 2 mm in diameter), which is extremely rare. Langston [7] thought the various types of CCAM have different etiology. Type I CCAM refers to the large pulmonary cyst malformation with diameter > 2 cm, often involving the unilateral lobe, with mul-

tipale and multilocular cyst in the adjacent lobes occasionally. This type shows cysts with bronchial characteristics in cystic wall, and the respiratory epithelium is covered on the fibrous tissue and smooth muscle. However, the cysts are communicated with surrounding bronchial tube and pulmonary parenchyma, so it is difficult to be regarded as true cyst. The cyst wall contains respiratory epithelium and a small amount of bronchial like smooth muscle, but there are no cartilages or glands. In some cyst wall, there is gastrointestinal tract mucous epithelium, and confirmed the foregut origin of lung tissue [8]. Therefore, the images of type 1 CCAM can be differentiated from those of bronchogenic cyst. Type 1 CCAM is communicated with pulmonary parenchyma with gas accumulation, while bronchogenic cyst has no gas accumulation if not combined with cystic wall infection and necrosis. Pulmonary parenchyma outside type I CCAM cysts have characteristics of bronchial obstruction, and a high proportion of the type I type CCAM has the arterial supply from body circulation. The typical pathological characteristics of type II CCAM is wide microencapsulated performance in local pulmonary parenchyma, with increased bronchial structure and alveolar number. Type III CCAM is characterized by extensive pulmonary parenchymal hyperplasia and hyperinflation.

#### *Pathology*

The pathological characteristics of CCAM is the over proliferation and abnormal immature structure of the terminal bronchioles mesenchymal components [9]. CCAM can be divided into three types according to standard Stocker histopathological classification. The most remarkable characteristic lesion of type I is the existence of large thick wall cavity (Diameter > 2 cm). In this group of our patients, the lung tissue showed multiple cysts with bronchial impassability, and one of the largest cyst had cavity with 9 cm in diameter, surrounded by small capsules. In some cases, the cystic cavity contained mucoid secretions. Sac lining was covered with pseudostratified ciliated columnar epithelium, with smooth muscle and elastic tissue around thick wall. There were alveolar structures between large cysts or within adjacent large cyst. Type II CCAM is characterized by many lesions with separated cystic cavities, with the maximum diameter often less than I

cm. The cysts are lined with a cubic to high columnar ciliated epithelium and only a little pseudostratified epithelium, and this structure is similar to expanded alveoli between the respiratory bronchioles and cysts with epithelial lining. Type III CCAM shows generally large and solid lung tissue mass with significant mediastinal shift.

### *CT performance*

Combined with CT performance and Stocker pathological type, we divided CCAM into three types. Type I are composed of single or multiple vesicles of different sizes, with at least one vesicle diameter > 2 cm. There were 6 cases of type I CCAM and accounted for about 54%. CT imaging showed single or multiple air-filled vesicles with different sizes within unilateral or bilateral lung, with the diameter between 2 cm and 9 cm. The cyst wall is thin and irregular, with several small and medium around cystic cavities. Large cystic cavity was compressed by pulmonary tissue and showed ring structure, and the mediastinal heart shadow was displaced to the left. There were 5 Type II in our results, accounting for about 45% of CCAM patients. The performance showed multiple vesicles within unilateral or bilateral lung, which were gathered in honeycomb like performance with unclear view, and at least one vesicle was composed with sac with diameter < 1 cm. Type III CCAM was composed of large follicular solid masses and countless vesicles of alveolar size. This type is extremely rare and there is not one case in our study.

### *Diagnosis*

Some scholars have proposed the prenatal diagnosis of CCAM: when ultrasound of fetal lung revealed cystic or solid lesions accompanied by polyhydramnios, fetal edema [10]. Polyhydramnios may be caused by reduced swallowing of amniotic fluid by esophageal compression of pulmonary lesions, or by too much liquid production of lesion lobe. Fetal edema may be due to blood reflux disorder by severe mediastinal displacement inducing heart and big vein compression. Prenatal diagnosis can take active measures to improve the survival rate and postnatal diagnosis is based on progressive dyspnea, recurrent pulmonary infection, fever, cough and asthma [11]. Compared with X-ray plain film, CT imaging can

better display the detailed lesions and changes in interval and adjacent pulmonary tissues, and improves significantly the detection rate of CCAM follicular cavity lesion and facilitate the differential diagnosis and clinical treatment options.

### *Differential diagnosis*

(1) Multilocular cyst of lung: This is generally single or multiple cysts, with thick and smooth cystic wall. The gas-liquid surface is visible when secondary infection occurs, and mediastinal displacement of heart is not obvious.

(2) Lung abscess: Lung abscess has a history of apparent pulmonary infection, accompanied by pleural disease, and can be significantly improved by anti-inflammatory treatment.

(3) Pulmonary sequestration: This disease can form several thick wall cavities with gas-liquid surface when infection is communicated with bronchial tube. Diagnosis can be confirmed on the basis of predilection site of pulmonary sequestration and abnormal blood circulation found by enhanced CT scan. Although CT scan has certain characteristics and important diagnosis value, the final diagnosis still needs to rely on pathological examination.

(4) Esophageal hiatal hernia or diaphragmatic hernia: These diseases are often accompanied by vomiting, and CT examination can discover the stomach and intestines within the chest cavity, and diagnosis can be confirmed by barium examination.

(5) Congenital lobar emphysema: The pathology of this disease is characterized by alveolar cavity expansion with normal lung structure. The affected lung shows volume expansion and enhanced transparency, with surrounding stretch of sparse lung texture.

(6) Cystic pulmonary blastoma: The tumor is often located in peripheral lung, and near the mediastinum and pulmonary pleura. CT scan shows cystic solid mass with clear boundary and false capsule, and tumor is generally not communicated with bronchial tube.

(7) Cystic bronchiectasis: This disease is rare in children and can be congenital. It shows cystic cavity with gas and gas-liquid surface, with cav-

ities of similar size, and the ipsilateral lung volume can be reduced.

## Conclusion

CT manifestation of CCAM has certain pathological characteristics and can provide reliable information for diagnosis of the disease.

## Disclosure of conflict of interest

None.

**Address correspondence to:** Dr. Zeng-Jun Zhang, Department of CT, Children Hospital of Xi'an, No. 69 Xijuyuan Road, Xi'an 710002, Shaanxi Province, PR China. Tel: +086-029-87692072; Fax: +086-029-87692009; E-mail: zhangzengjunct@aliyun.com

## References

- [1] Gornall AS, Budd JL, Draper ES, Konje JC, Kurinczuk JJ. Congenital cystic adenomatoid malformation: accuracy of prenatal diagnosis, prevalence and outcome in a general population. *Prenat Diagn* 2003; 23: 997-1002.
- [2] Laberge JM, Flageole H, Pugash D, Khalife S, Blair G, Filiatrault D, Russo P, Lees G, Wilson RD. Outcome of the prenatally diagnosed congenital cystic adenomatoid lung malformation: a Canadian experience. *Fetal Diagn Ther* 2001; 16: 178-186.
- [3] Cass DL, Quinn TM, Yang EY, Liechty KW, Crombleholme TM, Flake AW, Adzick NS. Increased cell proliferation and decreased apoptosis characterize congenital cystic adenomatoid malformation of the lung. *J Pediatr Surg* 1998; 33: 1043-1046.
- [4] Fromont-Hankard G, Philippe-Chomette P, Delezoide AL, Nessmann C, Aigrain Y, Peuchmaur M. Glial cell-derived neurotrophic factor expression in normal human lung and congenital cystic adenomatoid malformation. *Arch Pathol Lab Med* 2002; 126: 432-436.
- [5] Wang X, Wolgemuth DJ, Baxi LV. Overexpression of HOXB5, cyclin D1 and PCNA in congenital cystic adenomatoid malformation. *Fetal Diagn Ther* 2011; 29: 315-320.
- [6] Stocker JT, Madewell JE, Drake RM. Congenital cystic adenomatoid malformation of the lung. Classification and morphologic spectrum. *Hum Pathol* 1977; 8: 155-171.
- [7] Langston C. New concepts in the pathology of congenital lung malformations. *Semin Pediatr Surg* 2003; 12: 17-37.
- [8] Wang NS, Chen MF, Chen FF. The glandular component in congenital cystic adenomatoid malformation of the lung. *Respirology* 1999; 4: 147-153.
- [9] Giubergia V, Barrenechea M, Siminovich M, Pena HG, Murtagh P. Congenital cystic adenomatoid malformation: clinical features, pathological concepts and management in 172 cases. *J Pediatr (Rio J)* 2012; 88: 143-148.
- [10] Chen WS, Yeh GP, Tsai HD, Hsieh CT. Prenatal diagnosis of congenital cystic adenomatoid malformations: evolution and outcome. *Taiwan J Obstet Gynecol* 2009; 48: 278-281.
- [11] Shanmugam G, MacArthur K, Pollock JC. Congenital lung malformations—antenatal and postnatal evaluation and management. *Eur J Cardiothorac Surg* 2005; 27: 45-52.