

Original Article

The role of n-butyl-2-cyanoacrylate in the repair of traumatic diaphragmatic injuries

Gurhan Bas¹, Orhan Veli Ozkan², Orhan Alimoglu¹, Ramazan Eryilmaz³, Mustafa Sahin⁴, Ismail Okan⁴, Ugur Cevikbas⁵

¹Department of Surgery, Umraniye Training and Research Hospital, Istanbul, Turkey; ²Department of Surgery, School of Medicine, University of Sakarya, Sakarya, Turkey; ³Department of Surgery, School of Medicine, University of Akdeniz, Antalya, Turkey; ⁴Department of Surgery, Vakif Gureba Training and Research Hospital, Istanbul, Turkey; ⁵Department of Pathology, School of Medicine, University of Istanbul, Istanbul, Turkey

Received December 24, 2014; Accepted March 17, 2015; Epub April 15, 2015; Published April 30, 2015

Abstract: Diaphragmatic injuries either by blunt or penetrating trauma require prompt surgical intervention and are often exigent to repair. N-butyl-2-cyanoacrylate (n-butyl-2-CA) is a tissue adhesive which has gained wide application in many areas of surgery including emergency. To repair the extensive injuries of the diaphragm it may be necessary the use of synthetic mesh by fixing it with sutures or staples. The use of tissue adhesives may circumvent the potential problems associated with mesh fixation. This study aimed to evaluate the efficacy and safety of tissue adhesives usage for mesh fixation in diaphragmatic injury repair. Twenty-four rats were divided into 3 groups each of them containing 8 rats. A 1- cm diaphragmatic defect was created in all rats. The defect was repaired by polypropylene suture in Group I, by mesh fixed with sutures in group II and by mesh fixed with n-butyl-2-CA in group III. The rats were sacrificed after 1 month. The episode of hernia and the adhesions were assessed by adhesion density score. Also, the abscess and inflammation in the repaired tissue were evaluated microscopically. The Kruskal-Wallis test was performed for the histopathological analysis. No diaphragmatic hernia was detected in any group. While Group III had higher adhesion density scores than group I (P: 0.027), there were no differences between group III and II (P: 0.317) and group II and I (P = 0.095) regarding adhesion density scores. The inflammation grade was higher in group III than group I and II (P < 0.001) and was higher in group II than group I (P < 0.05). There was no differences between each groups, concerning microabscess formation (P > 0.05). Repair of traumatic diaphragmatic injury in penetrating wound, with polypropylene mesh fixed by n-butyl-2-CA in rats appears to be as efficacious and safe as conventional methods in early period. However, further experimental and clinical study are needed to compare the long-term results of adhesive mesh repair with those of the traditional sutured techniques.

Keywords: Diaphragmatic injury, repair, synthetic graft, cyanoacrylate

Introduction

The diaphragmatic injuries are detected in various frequencies depending on the type of trauma. The incidence of diaphragmatic injuries after gun-shot wounds and perforating traumas were reported 46% and 15%-26%, respectively. However, the incidence decreases to 4.5% after blunt trauma. Depending on the nature of trauma, the injuries may be subtle especially in penetrating, isolated traumas. They are often unnoticed during first evaluation of the patient and lead to serious impact afterwards [1-3]. Therefore, in case of suspicion further diagnostic tests are warranted. A large tear in the cen-

tral tendon is typically noticed after blunt trauma.

Since the laparoscopy becomes more frequently and efficiently used in trauma, the alertness of diaphragmatic injuries and laparoscopic treatment are increased [4]. While small lacerations are closed with a nonabsorbable running sutures, large defects with extensive tissue loss may require synthetic mesh in the repair. Since the diaphragm is moveable, the repair by synthetic graft with suture fixation is technically challenging. Besides, there is a risk for phrenic nerve injury due to the sutures used in graft fixation [1, 5, 6].

Repair of traumatic diaphragmatic injuries

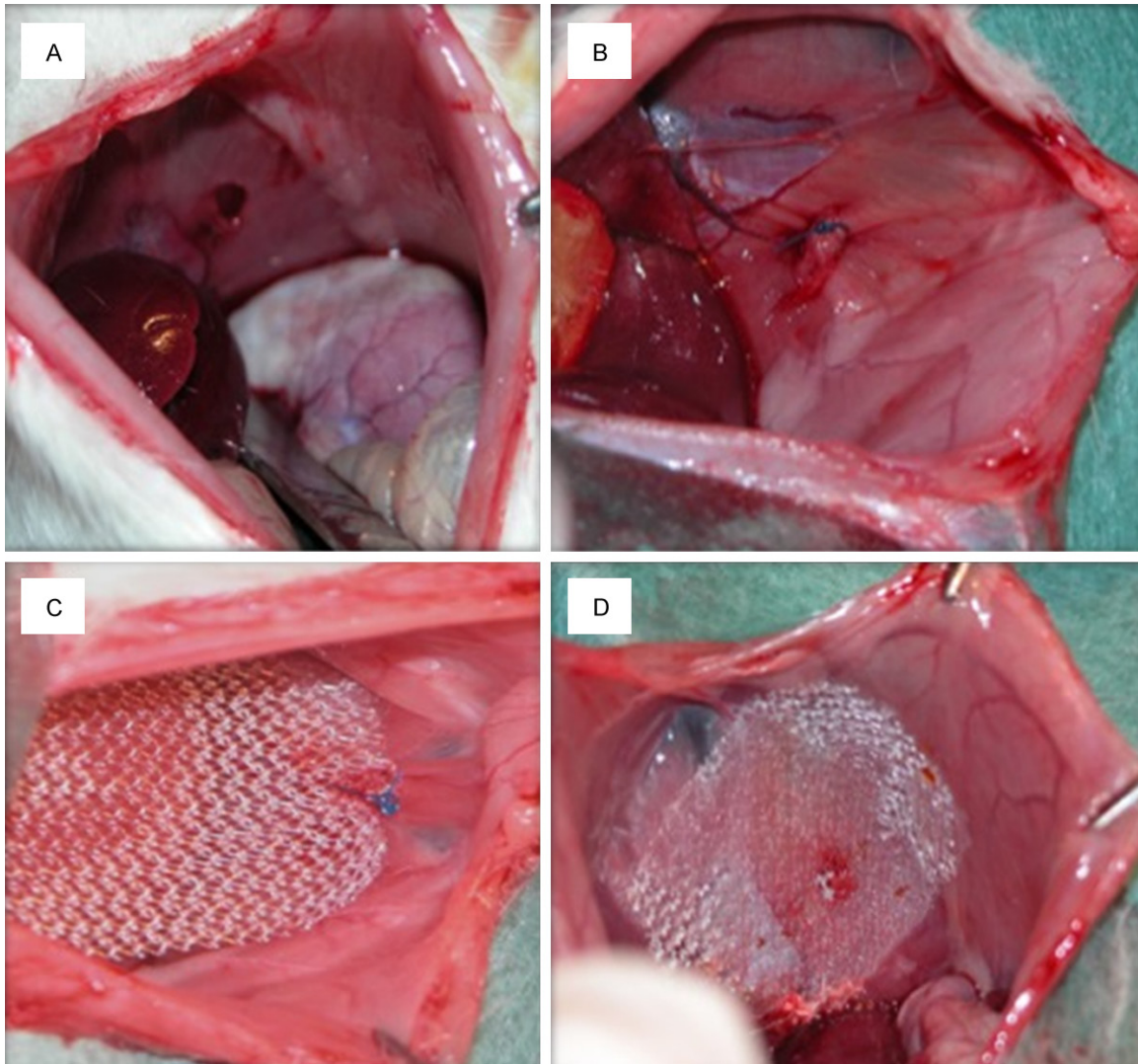


Figure 1. A: Diaphragmatic rupture; B: Repairing of the defect on the diaphragm with the polypropylene suture; C: Fixation of the polypropylene mesh with the suture; D: Fixation of the polypropylene mesh with the cyanoacrylate.

Cyanoacrilate has found a widespread practical use in medicine as a tissue adhesive [7-10]. Fixation of synthetic graft by other tissue adhesives in inguinal hernia repair was reported recently [11]. TIMELI study [11] is a major international trial which stated that a tissue adhesive, Tissucol, was efficient and safe compared with sutures, for mesh fixation in patients undergoing Lichtenstein technique for primary inguinal hernia repair. However, there was no report on the use in the repair of diaphragmatic injuries.

The present study aims to compare the efficacy and safety of diaphragmatic repair with synthetic graft by fixing cyanoacrilate and other

techniques in rats with experimentally induced diaphragmatic injury.

Materials and methods

The study was carried out in Istanbul University Experimental Medical Research Unit. Twenty four Wistar-Albino male rats weighing 250-300 gr were used. The rats were kept under routine laboratory conditions and fed on chow and ad libitum.

Rats were divided into three groups each containing 8 rats. Anesthesia were instituted by intraperitoneal injection of ketamine hydrochloride 90 mg/kg (Ketalar flakon, Eczacibasi, Istanbul). The abdominal region was shaved

Table 1. Repairing region adhesion scores

Subject	Group I	Group II	Group III
1	3	3	3
2	3	2	3
3	3	3	3
4	3	3	3
5	2	3	3
6	1	3	3
7	1	3	3
8	2	3	3

There was no difference between adhesion scoring between Groups III and II ($P: 0.33$). However, the adhesion scores of Group III was higher than Group I ($P: 0.031$). Statistical study was done with student t test and the Kruskal-Wallis test.

and cleaned with by povidone-iodide. A midline 3 cm long laparotomy incision was performed. At laparotomy, left diaphragm was identified and a 1 cm incision at the center was done with a No. 11 scalpel (**Figure 1**). In Group I, the defect was immediately repaired with running 4/0 polypropylene sutures (2a). In Group II, the diaphragmatic defect was repaired with polypropylene mesh (Ethicon Inc, USA) fixed with polypropylene sutures (2b). The repair was carried out with polypropylene mesh fixed to diaphragm with n-butyl-2-cyanoacrilate (Liqui Band™, Medlogix Global LDT, Polymount, England) in Group III (2c). The developed pneumothorax was treated with an angiocath No. 22 inserted into the thoracic cavity of the rats. Peritoneum and the abdominal fascia were closed with 4/0 silk with continuous sutures.

Thirty days later, relaparotomy was carried out under the same conditions above discussed. The extent of adhesions developed during healing was classified and scored as 0 with no adhesion, 1 corresponds to adhesion which can be separated with mild dissection, 2 to adhesion separated by blunt dissection, 3 to adhesion separated with sharp dissection. The diaphragm was completely excised and fixed in 10% formaline solution to evaluate the healing process and inflammation histologically. The tissue was stained with haematoxylin eosin. A microscopic score was obtained for each rat. Microscopic analysis was performed by an investigator who was not involved in the experimental procedures. The presence and extent of fibroblastic activity; the amount of giant cells, plasma cells, and lymphocytes and the micro-

abscess formation were assessed using a semi-quantitative method (1; less, 2; moderate, 3; many). Statistical analysis: Data were analyzed by a statistical software (SPSS for windows 11.5, SPSS Inc. Chicago, IL, USA). Statistical study was done with student t test and the Kruskal-Wallis test. The Kruskal-Wallis test was performed for the histopathological analysis. P value less than 0.05 was accepted as significant.

Results

After completion of surgical procedure, none of the rats were died during follow-up. At laparotomy, the healing process was completed macroscopically in all rats. None of the rats had diaphragmatic hernia due to the healing defect. The attachment of polypropylene mesh and the diaphragm was firm in all rats of both Group II and III. No detachment or slipping of the mesh was noticed.

The adhesions to the diaphragm was noticed in all subjects. Omentum and liver was the the most frequently attached organs. There was no difference between adhesion scoring between Groups III and II ($P: 0.33$). However, the adhesion scores in Group III was higher than Group I ($P: 0.031$). Although the adhesion scores of Group II were higher than Group I, the difference didn't reach statistical significance ($P: 0.08$) (**Table 1**).

The average scores of inflammation and healing was higher in Group III than both Groups I and II ($P < 0.001$). They were also significantly higher in Group II compared to Group I ($P < 0.05$) (**Figure 2A-C**). There was no difference between groups with respect to microabscess formation, which is indicator of faulty healing ($P < 0.05$).

Discussion

The diaphragmatic injuries could be due to penetrating or severe blunt traumas. They are usually associated with additional organ injuries. Although the actual incidence of traumatic diaphragm rupture is difficult to extract from literature, it varies between 0.8% [12] to 5.2% in patients with multiple trauma [13]. Approximately one forth of the diaphragmatic ruptures are due to penetrating trauma, while the rest was seen in blunt trauma [1, 14-17]. The inju-

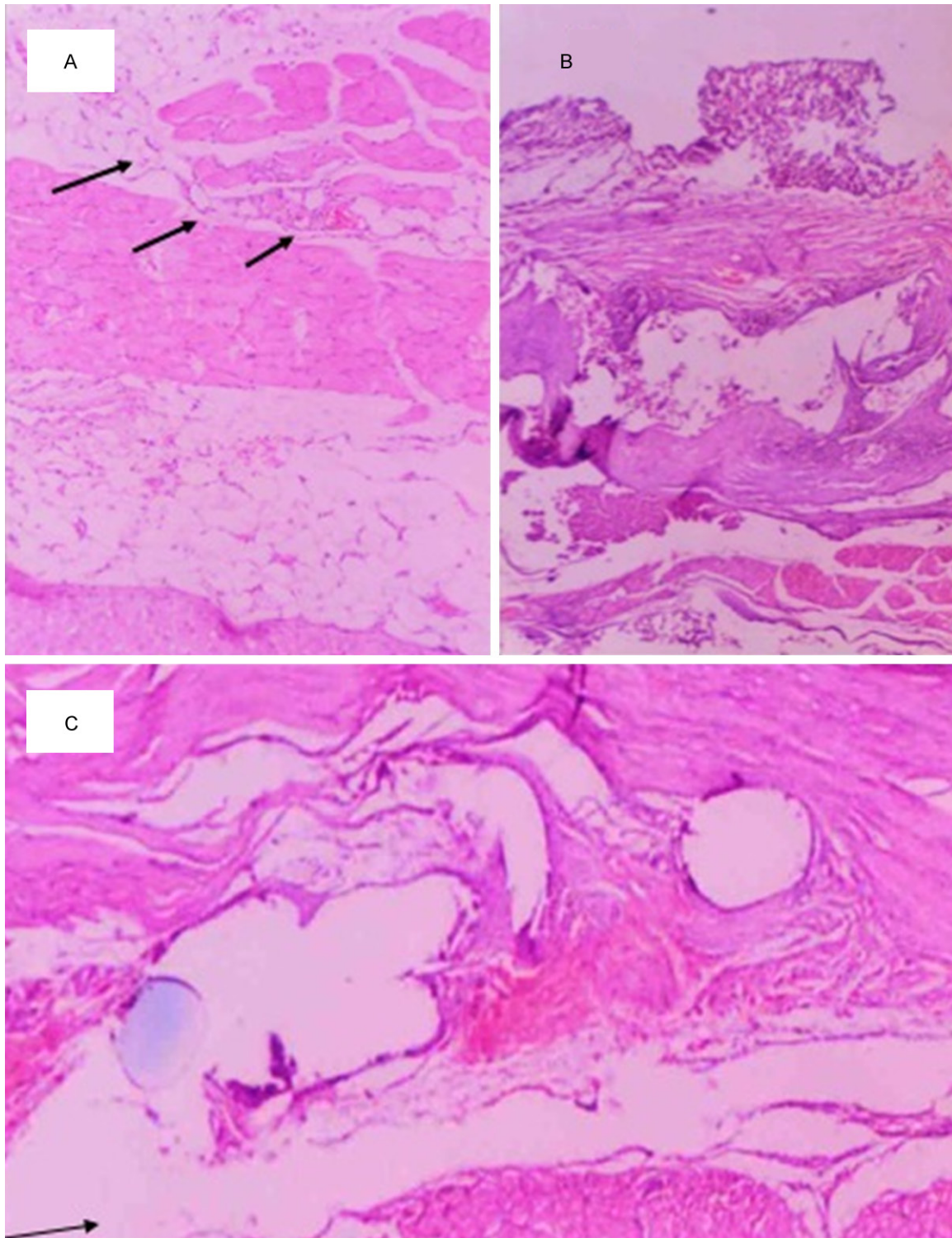


Figure 2. A: At the middle, striated muscles of diaphragm, fat tissue, few lymphocyte and fibrocyte groups. Minor inflammatory response in group I demonstrated with arrow (Hematoxyline-Eosine-H.E-x 125); B: At the middle in the large area striated muscle of the diaphragm, here widespread lymphocyte, plasmocyte, giant cells in the middle wide foreign substance (cyanoacrilate appearance). Severe inflammatory reaction around the polypropylene mesh fixed with n-butyl-2-CA in Group III (H.E \times 125); C: At the middle, striated muscles of diaphragm, intermediate, moderate lymphocyte, plasmocyte, giant cells and at the middle foreign substances. Moderate inflammatory reaction around the polypropylene mesh in group II (Arrow: Mesh-structured appearance) (H.E \times 125).

ries are usually located in the tendinous portion of the diaphragm. The right diaphragm is protected by the bulk of liver especially in blunt traumas. The basic mechanism of the blunt diaphragmatic rupture is due to the kinetic force implemented by a sudden increase in intra-abdominal pressure. During serious traumas, intra-abdominal pressure increases 10 times which is transmitted rapidly to diaphragmatic dome. The injuries due to the stabbing wounds could be in various size and depth. However, the injuries of gun-shot wounds are more serious and usually are together with tissue loss. Since the defect in diaphragm cannot heal spontaneously due to the pressure differences between two cavities, abdominal organs could herniate to the pleural-cavity [1, 18]. The herniation could take place immediately after trauma or it takes months even years. Therefore the diagnosis of diaphragmatic injury could be difficult, moreover, it could be overlooked in explorative laparotomy. Indeed, the diaphragmatic injury in 7% to 61% of polytrauma patients could go unnoticed and diagnosis was established preoperatively only in 43% of the patients [19, 20]. In a significant portion of patients the injury was recognized during exploration of abdominal or thoracic cavity due to the other pathologies [21, 22]. To keep in mind the possibility of diaphragmatic rupture after trauma is the most important parameter to help establishing the diagnosis [23].

Cyanoacrylates are formed as the end product of the reaction between alkyl cyanoacetate and formaldehyde. The reactive reagents are fluid monomers and water-consistent. They gained increased popularity in various branches of surgery as a tissue adhesive. The successful utilization of cyanoacrylates have been reported in biliary fistules [24], esophageal and gastric varicose bleedings [25, 26], peptic ulcer bleedings [26], intestinal anastomoses [27], treatments of enterocutaneous fistulas [28], and skin closures [29]. Cyanoacrylate recently has been reported to be used successfully to secure the graft in inguinal hernia repair instead of using suture materials. No harmful side effect or toxicity has been reported. Bacteriocidal or bacteriostatic effect have also been shown [30].

The treatment of diaphragmatic injury is a surgical repair commonly performed by abdominal approach but also to a lesser extent, by thorac-

ic or thoracoabdominal incision. Since the diagnostic laparoscopy increasingly used in trauma patients, laparoscopic repair became progressively more popular [4, 5, 17]. Surgery could be done in the acute settings together with the management of concomitant organ injuries. The small diaphragmatic injuries can be repaired with running sutures of absorbable or non-absorbable material. The defects with tissue lost especially after gun-shot wounds are best managed with implementation of prosthetic material. The late repairs usually require prosthetic material due to the long-standing changes, retraction of the edges and the weakness in diaphragm [22, 31]. Instead of using prosthesis, autogenic materials such as fascia lata and dura have also been reported [32, 33]. Polypropylene mesh is the most frequently used material. Polytetrafluoroethylene, marlex, and dacrone have also been reported albeit to a lesser extent [23, 34]. Fixation of the graft to diaphragm is carried out by nonabsorbable sutures or staplers. The management of diaphragmatic hernia is still demanding for surgeons. The morbidity and mortality are affected by the presence of associated organ injuries [1, 14, 15, 17]. However, the dehiscence of the suture and recurrence of hernia is an important cause for the late morbidity [6]. The repair of the defect is also technically difficult since the diaphragm is a mobile organ. Moreover, the sutures both in primary repair or in fixation of the mesh could cause phrenic nerve damages. Especially, fixation of the defects involving the posterolateral, pericardial, paraesophageal region and the adhered points of the diaphragm is rather difficult [35].

Therefore, we aimed to investigate an easy, safe and effective way of repairing in traumatic diaphragm injuries. The use of cyanoacrylate for fixing the mesh into the diaphragm instead of sutures have been tested. It well known that using a prosthetic material causes adhesion formation. Intraabdominal adhesions were more pronounced in both prosthetic mesh repair group than primary suturing as expected. However, there were no difference between cyanoacrylate-fixing group and suture-fixing group with regard to intraabdominal adhesions. The inflammation and healing process were markedly augmented in cyanoacrylate-group. It has already been reported that tissue adhesives induced a strong inflammatory reaction by acting as foreign substance [36]. There were

no microabscess formation which is an indicative of graft rejection or failure. However, as the study was terminated after one month, it is inappropriate to draw conclusions about late recurrence.

As a result, fixation of the graft to diaphragm with cyanoacrylate is a fast, easy, and convenient way in traumatic diaphragm repair. Since application of adhesives takes less time it could save time in emergency operations. But, further studies are needed to get the late results of the cyanoacrylate-fixation of the prosthetic material in traumatic diaphragm injuries.

Disclosure of conflict of interest

None.

Address correspondence to: Dr. Orhan V Ozkan, Department of General Surgery, Faculty of Medicine, Sakarya University, Adnan Menderes Caddesi, Saglik Sokak No. 193, Sakarya 54100, Turkey. Tel: +90-264-2552106; Fax: +90-264-2552106; E-mail: veliorhan@hotmail.com

References

- [1] Schumpelick V, Steinau G, Schluper I, Prescher A. Surgical embryology and anatomy of the diaphragm with surgical applications. *Surg Clin North Am* 2000; 80: 213-239.
- [2] Moore JB, Moore EE, Thompson JS. Abdominal injuries associated with penetrating trauma in the lower chest. *Am J Surg* 1980; 140: 724-730.
- [3] Murray JA, Demetriades D, Asensio JA, Cornwell EE 3rd, Velmahos GC, Belzberg H, Berne TV. Occult injuries to the diaphragm: prospective evaluation of laparoscopy in penetrating injuries to the left lower chest. *J Am Coll Surg* 1998; 187: 626-630.
- [4] Mjoli M, Oosthuizen G, Clarke D, Madiba T. Laparoscopy in the diagnosis and repair of diaphragmatic injuries in left-sided penetrating thoracoabdominal trauma: Laparoscopy in trauma. *Surg Endosc* 2015; 29: 747-752.
- [5] Güloğlu R, Arıcı C, Kocataş A, Necefli A, Asoğlu O, Alish H. Diafragma Yaralanmaları. *Çağdaş Cerrahi Derg (Turkish)* 1996; 10: 168-671.
- [6] Kamelgard JI, Harris L, Reardon MJ, Reardon PR. Thoracoscopic repair of a recurrent diaphragmatic hernia four years after initial trauma, laparotomy, and repair. *J Laparoendosc Adv Surg Tech A* 1999; 9: 171-175.
- [7] Ellis DA, Shaikh A. The ideal tissue adhesive in facial plastic and reconstructive surgery. *J Otolaryngol* 1990; 19: 68-72.
- [8] Jallali N, Haji A, Watson CJ. A prospective randomized trial comparing 2-octyl cyanoacrylate to conventional suturing in closure of laparoscopic cholecystectomy incisions. *J Laparoendosc Adv Surg Tech A* 2004; 14: 209-211.
- [9] Nipshagen MD, Hage JJ, Beekman WH. Use of 2-octyl-cyanoacrylate skin adhesive (Dermabond) for wound closure following reduction mammoplasty: a prospective, randomized intervention study. *Plast Reconstr Surg* 2008; 122: 10-18.
- [10] Gürhan Ulusoy M, Kankaya Y, Uysal A, Sungur N, Koçer U, Kankaya D, Oztuna D. "Lid technique": cyanoacrylate-assisted anastomosis of small-sized vessels. *J Plast Reconstr Aesthet Surg* 2009; 62: 1205-1209.
- [11] Campanelli G, Pascual MH, Hoferlin A, Rosenberg J, Champault G, Kingsnorth A, Bagot d'Arc M, Miserez M. Post-operative benefits of Tisseel(®)/Tissucol (®) for mesh fixation in patients undergoing Lichtenstein inguinal hernia repair: secondary results from the TIMELI trial. *Hernia* 2014; 18: 751-760.
- [12] Chen JC, Wilson SE. Diaphragmatic injuries: Recognition and management in sixty-two patients. *Am Surg* 1991; 57: 810-816.
- [13] Estrera AS, Platt MR, Mills LS. Traumatic injuries of the diaphragm. *Chest* 1979; 75: 306-313.
- [14] Bergin D, Ennis R, Keogh C, Fenlon HM, Murray JG. The "dependent viscera" sign in CT diagnosis of blunt traumatic diaphragmatic rupture. *AJR Am J Roentgenol* 2001; 177: 1137-1140.
- [15] Alimoglu O, Eryilmaz R, Sahin M, Ozsoy MS. Delayed traumatic diaphragmatic hernias presenting with strangulation. *Hernia* 2004; 8: 393-396.
- [16] Mihos P, Potaris K, Gakidis J, Paraskevopoulos J, Varvatsoulis P, Gougoutas B, Papadakis G, Lapidakis E. Traumatic rupture of the diaphragm: experience with 65 patients. *Injury* 2003; 34: 169-172.
- [17] Shah R, Sabanathan S, Mearns AJ, Choudhury AK. Traumatic rupture of diaphragm. *Ann Thorac Surg* 1995; 60: 1444-1449.
- [18] Sharma OP. Traumatic diaphragmatic rupture: not an uncommon entity—personal experience with collective review of the 1980's. *J Trauma* 1989; 29: 678-682.
- [19] Christophi C. Diagnosis of traumatic diaphragmatic hernia: analysis of 63 cases. *World J Surg* 1983; 7: 277-280.
- [20] Payne JH Jr, Yellin AE. Traumatic diaphragmatic hernia. *Arch Surg* 1982; 117: 18-24.
- [21] Colliver C, Oller DW, Rose G, Brewer D. Traumatic intrapericardial diaphragmatic hernia diagnosed by echocardiography. *J Trauma* 1997; 42: 115-117.
- [22] Kuhn R, Schubert D, St Wolff, Marusch F, Lippert H, Pross M. Repair of diaphragmatic rup-

Repair of traumatic diaphragmatic injuries

- ture by laparoscopic implantation of a polytetrafluoroethylene patch. *Surg Endosc* 2002; 16: 1495.
- [23] Matseych OY. Blunt diaphragmatic rupture: four year's experience. *Hernia* 2008; 12: 73-78.
- [24] Seewald S, Groth S, Sriram PV, Xikun H, Akaraviputh T, Mendoza G, Brand B, Seitz U, Thonke F, Soehendra N. Endoscopic treatment of biliary leakage with n-butyl-2 cyanoacrylate. *Gastrointest Endosc* 2002; 56: 916-919.
- [25] Dhiman RK, Chawla Y, Taneja S, Biswas R, Sharma TR, Dilawari JB. Endoscopic sclerotherapy of gastric variceal bleeding with n-butyl-2-cyanoacrylate. *J Clin Gastroenterol* 2002; 35: 222-227.
- [26] Yok KY, Kum CK, Goh PM. Endoscopic hemostasis of upper gastrointestinal bleeding with histoacryl: last resort before surgery. *Endoscopy* 1996; 28: 256-258.
- [27] Tebala GD, Ceriati F, Ceriati E, Vecchioli A, Nori S. The use of cyanoacrylate tissue adhesive in high-risk intestinal anastomoses. *Surg Today* 1995; 25: 1069-1072.
- [28] Santos F, Campos J, Freire J, Andrade A, Tavora I, Castelo HB. Enterocutaneous fistulas: an unusual solution. *Hepatogastroenterology* 1997; 44: 1085-1089.
- [29] Hallock GG. Expanded applications for octyl-2-cyanoacrylate as a tissue adhesive. *Ann Plast Surg* 2001; 46: 185-189.
- [30] Olson ME, Ruseska I, Costerton JW. Colonization of n-butyl-2-cyanoacrylate tissue adhesive by *Staphylococcus epidermidis*. *J Biomed Mater Res* 1988; 22: 485-495.
- [31] Mansour KA. Trauma to the diaphragm. *Chest Surg Clin N Am* 1997; 7: 373-383.
- [32] Suzuki K, Takahashi T, Itou Y, Asai K, Shimota H, Kazui T. Reconstruction of diaphragm using autologous fascia lata: an experimental study in dogs. *Ann Thorac Surg* 2002; 74: 209-212.
- [33] Koot VC, Bergmeijer JH, Molenaar JC. Lyophilized dura patch repair of congenital diaphragmatic hernia: occurrence of relapses. *J Pediatr Surg* 1993; 28: 667-668.
- [34] Pojarliev T, Tzvetkov I, Blagov J, Radionov M. Laparoscopic repair of traumatic rupture of the left diaphragm cupola with prosthetic mesh. *Surg Endosc* 2003; 17: 660.
- [35] Matthews BD, Bui H, Harold KL, Kercher KW, Adrales G, Park A, Sing RF, Heniford BT. Laparoscopic repair of traumatic diaphragmatic injuries. *Surg Endosc* 2003; 17: 254-258.
- [36] Landegren T, Risling M, Persson JK. Local tissue reactions after nerve repair with ethyl-cyanoacrylate compared with epineural sutures. *Scand J Plast Reconstr Surg Hand Surg* 2007; 41: 217-227.