

Case Report

Hyperreactio luteinalis after delivery: a case report and literature review

Chunrun Yang^{1*}, Hongqing Wang^{1*}, Yonghui Zou^{1*}, Weiguo Cui², Junjun Yang³, Tao Li¹, Changzhong Li¹, Jie Jiang⁴

¹Department of Obstetrics and Gynecology, Shandong Provincial Hospital Affiliated to Shandong University, Jinan, P. R. China; ²Department of Orthopedics, Fourth People's Hospital of Langfang, Langfang, P. R. China; ³Department of Neurology, Fourth People's Hospital of Langfang, Langfang, P. R. China; ⁴Department of Obstetrics and Gynecology, Qilu Hospital, Shandong University, Jinan, P. R. China. *Equal contributors.

Received January 5, 2015; Accepted February 21, 2015; Epub April 15, 2015; Published April 30, 2015

Abstract: Hyperreactio luteinalis (HL), characterized by bilateral functional multicystic ovarian enlargement during pregnancy and puerperium, mostly occurs in third trimester. As a rare benign disease, HL is usually self-limited. However, some cases are diagnosed by unnecessary operation. This is a case report of HL appearing a week after delivery. The patient took a puncture biopsy of ovarian tumor guided by ultrasound to rule out of ovarian malignancy. Without any specific treatment, the disease regressed spontaneously.

Keywords: Hyperreactio luteinalis, pregnancy, ovarian cysts, enlarged ovaries

Case report

A 31-year-old woman at 39 weeks' of gestation gave birth to a healthy baby boy on April 3, 2014. She felt abdominal pains and distension, with no farting and defecating 7 days later. Then she was admitted to local hospital for examinations. Transabdominal ultrasound assessment revealed a left ovary of 11.8 × 7.3 × 6.1 cm and a right ovary of 14.8 × 8.6 × 7.0 cm with a small quantity of free fluid in the pouch of Douglas (1.7 cm). Moreover the patient was advised to have an abdominal X-ray. It seemed to be gas-liquid flat in the enteric cavity. After 5 days of promoting gastrointestinal peristalsis and defecation, there was no distinct improvement on the patient.

On 16th April, 2014, the patient was transferred to Shandong Province Hospital for further treatment. She complained of mildly increased abdominal discomfort and distension. On ultrasonogram, the ovaries have shown an appearance of spoke-wheel. Large bilateral multilocular masses measured 10.2 × 8.0 × 7.0 cm in the left ovary and 16.0 × 8.4 × 8.4 cm in the right ovary, with little ascites (1.5 cm) (**Figure 1**). Blood analysis has shown a high level of serum beta human chorionic gonadotropin (β-HCG 20.41 mIU/ml) and cancer antigen 125

(CA 125 496.30 U/ml). As a result, she was taken measures to improve conditions by intravenous albumin and fluid infusion.

We cannot determine the nature of ovarian cysts, benign nor malignant. Then the patient took a puncture biopsy of ovarian tumor guided by ultrasound. The pathology indicated a few neutrophils and lymphocytes, without cancer cells. Furthermore, the symptoms have shown dramatic improvement. Hence, further rehydration was carried out as symptomatic treatment over the following week. The patient was discharged from hospital on 21st April, 2014, with further observation scheduled.

This further observation was performed in Shandong Province Hospital two weeks later. Repeated ultrasound revealed both ovaries are smaller than before (7.1 × 3.4 × 3.9 cm in the left ovary and 12.0 × 8.2 × 6.5 cm in the right) with multiple cysts (**Figure 2**). Moreover, serum CA125 has reduced to 133.00 U/ml.

The patient came back to the hospital for checkup on 7th Jun, 2014. Ultrasound assessment revealed a lightly enlarged right ovary of 9.0 × 6.5 × 4.1 cm and a left ovary of 5.1 × 2.8 × 2.7 cm (**Figure 3**). The serum CA125 has

Hyperreactio luteinalis after delivery

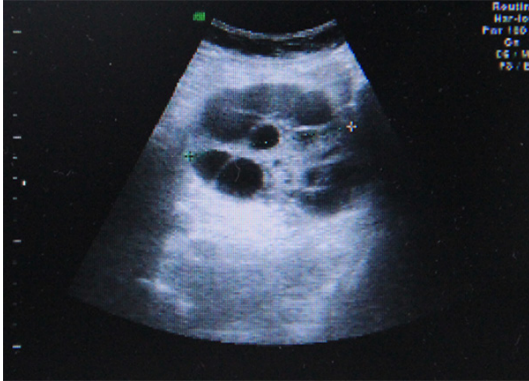

Figure 1. Right ovary in the ultrasoundgram on 16th April, 2014.

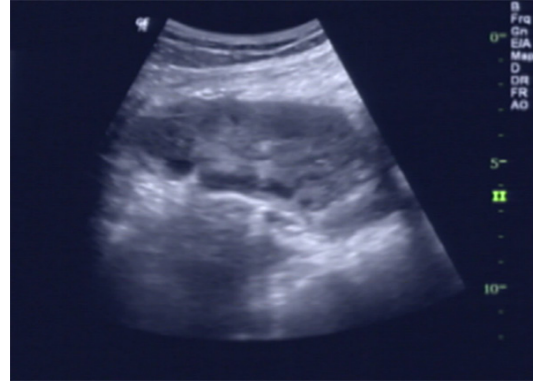

Figure 3. Right ovary in the ultrasoundgram on 7th June 2014.

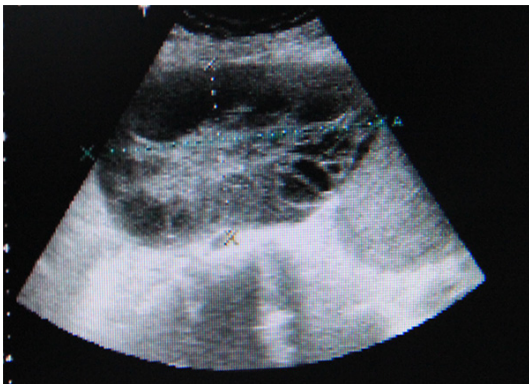


Figure 2. Right ovary in the ultrasoundgram on 7th May, 2014.

decreased to 19.71 U/ml (reference range, 0-39 U/ml). Pelvic ultrasound performed 3 months after delivery confirmed normal ovaries bilaterally with no residual cysts, and the patient has remained in good status in the following six months.

Discussions

The reported is what we believe to be the first case of hyperreactio luteinalis after delivery. HL is a rare benign condition with bilateral functional multicystic ovarian enlargement occurred in the pregnancy, which can clear without specific treatment [1, 2].

HL, without affecting outcome of pregnancies generally, is mostly seen in third trimester, whereas few cases occur in first trimester [3]. It's reported that a multiparous woman with PCOS through ovulation induction presents with HL in first trimester [4]. When ovarian hyperstimulation syndrome (OHSS), also characterised by enlarged bilateral multicystic ova-

ries, occurs in first trimester, termination of the pregnancy is unavoidable sometimes. OHSS is a severe complication in pregnancy following ovulation induction with exogenous gonadotrophins. And OHSS has been demonstrated to be related to polycystic ovary syndrome (PCOS), hypothyroidism, pituitary gonadotropin-secreting adenoma, or mutation of the FSH receptor [5]. Both of HL and OHSS can be nausea and vomiting, lower abdominal pain, loss of appetite and water electrolyte disorder, even ascites [6]. Our patient is spontaneous singleton pregnancy, leading to a presumptive diagnosis of HL. And everything is normal in the whole pregnancy, so we consider it the first case of hyperreactio luteinalis after delivery.

HL in pregnancy is associated with theca lutein cysts (TLCs) and increased production of HCG [5-8]. While someone reports HCG can be at a normal level [1, 9]. HL appears to be related to multiple gestations and gestational trophoblastic disease [5, 10]. While Atis A et al. reported HL occurred with normal singleton pregnancy. The mater sometimes present with signs of virilization, such as hirsutism, clitoromegaly, deepening of voice during pregnancy, and so on [11-13]. And some female fetuses appear virilization too [14]. Besides, several complications of thyroid dysfunction, hyperemesis gravidarum, preeclampsia, HELLP syndrome, premature delivery, fetal growth restriction, placental insufficiency, and delayed lactation have been reported [2, 6, 13-15].

Surgical treatment is required for most these patients. Firstly, cesarean section is preferred because of obstruction of the birth canal by enlarged ovaries [11]. And more than 37% of cases are diagnosed in the caesarean [5]. Secondly, we can taken a biopsy of ovarian cyst

Hyperreactio luteinalis after delivery

Table 1. Change of ovaries and CA 125 in the progress of disease

	April 3, 2014	April 16, 2014	May 5, 2014	June 7, 2014
Volume of left ovary (cm ³)	11.8 × 7.3 × 6.1	10.2 × 8.0 × 7.0	7.1 × 3.4 × 3.9	5.1 × 2.8 × 2.7
Volume of right ovary (cm ³)	14.8 × 8.6 × 7.0	16.0 × 8.4 × 8.4	12.0 × 8.2 × 6.5	9.0 × 6.5 × 4.1
CA 125 (U/ml)	-	496.30	133.00	19.71

or wedge resection, even sometimes oophorectomy because of ovarian torsion, infarction and hemorrhage or to rule out of ovarian malignancy. But HL does not need any specific treatment except observation, unless complications occur [1]. And both ovaries can regress spontaneously, so was our patient (**Table 1**).

In conclusion, there are only very few case report of HL occurring after delivery. It's reported that HL is diagnosed accidentally in few pregnancy women by cesarean section, while they are not asymptomatic, accompanying preeclampsia and hyperandrogenism. So we believe that the cases referred occurred in pregnancy and our patient is the first case of HL after delivery. Moreover, we got a presumptive diagnosis of HL through puncture biopsy guided by ultrasound, avoiding unessential surgical excision fortunately.

Disclosure of conflict of interest

None.

Address correspondence to: Changzhong Li, Department of Obstetrics and Gynecology, Shandong Provincial Hospital Affiliated to Shandong University, 324 Jingwu Road, Jinan 250012, Shandong, People's Republic of China. Tel: 86-531-85187890; Fax: 86-531-80676123; E-mail: 15168888909@163.com

References

- [1] Skandhan AK and Ravi V. Hyperreactio luteinalis: An often mistaken diagnosis. *Indian J Radiol Imaging* 2014; 24: 84-86.
- [2] Atis A, Cifci F, Aydin Y, Ozdemir G and Goker N. Hyperreactio luteinalis with preeclampsia. *J Emerg Trauma Shock* 2010; 3: 298.
- [3] Onodera N, Kishi I, Tamaoka Y, Yamazaki K and Kamei K. A case of recurrent hyperreactio luteinalis. *Am J Obstet Gynecol* 2008; 198: e9-10.
- [4] Detti L, Phillips OP, Schneider M and Lambrecht LE. Fetal reduction for hyperreactio luteinalis. *Fertil Steril* 2011; 96: 934-938.
- [5] Abe T, Ono S, Igarashi M, Akira S, Watanabe A and Takeshita T. Conservative management of

hyperreactio luteinalis: a case report. *J Nippon Med Sch* 2011; 78: 241-245.

- [6] Cavoretto P, Giorgione V, Sigismondi C, Mangili G, Serafini A, Dallagiovanna C and Candiani M. Hyperreactio luteinalis: timely diagnosis minimizes the risk of oophorectomy and alerts clinicians to the associated risk of placental insufficiency. *Eur J Obstet Gynecol Reprod Biol* 2014; 176: 10-16.
- [7] Takeda T, Minekawa R, Makino M, Sugiyama T, Murata Y and Suehara N. Hyperreactio luteinalis associated with severe twin-to-twin transfusion syndrome. *Gynecol Obstet Invest* 2002; 53: 243-246.
- [8] Masuyama H, Tateishi Y, Matsuda M and Hiramatsu Y. Hyperreactio luteinalis with both markedly elevated human chorionic gonadotropin levels and an imbalance of angiogenic factors subsequently developed severe early-onset preeclampsia. *Fertil Steril* 2009; 92: 393.e1-3.
- [9] Hanprasertpong T and Hanpresertpong J. Polyhydramnios, an unusual complication in pregnancy with hyperreactio luteinalis: a case report. *J Med Assoc Thai* 2013; 96: 239-242.
- [10] Lynn KN, Steinkeler JA, Wilkins-Haug LE and Benson CB. Hyperreactio luteinalis (enlarged ovaries) during the second and third trimesters of pregnancy: common clinical associations. *J Ultrasound Med* 2013; 32: 1285-1289.
- [11] Baxi LV, Grossman LC and Abellar R. Hyperreactio luteinalis in pregnancy and hyperandrogenism: a case report. *J Reprod Med* 2014; 59: 509-511.
- [12] Angioni S, Portoghese E, Milano F, Melis GB and Fulghesu AM. Hirsutism and hyperandrogenism associated with hyperreactio luteinalis in a singleton pregnancy: a case report. *Gynecol Endocrinol* 2007; 23: 248-251.
- [13] Page SM and O'Brien J. Hyperreactio luteinalis with clitoromegaly in a twin pregnancy. *Rev Obstet Gynecol* 2009; 2: 3-4.
- [14] Simsek Y, Celen S, Ustun Y, Danisman N and Bayramoglu H. Severe preeclampsia and fetal virilization in a spontaneous singleton pregnancy complicated by hyperreactio luteinalis. *Eur Rev Med Pharmacol Sci* 2012; 16: 118-121.
- [15] Haq AN. Hyperreactio luteinalis associated with pregnancy induced hypertension. *J Coll Physicians Surg Pak* 2010; 20: 137-139.