

Original Article

A novel endovenous laser ablation strategy of treatment of greater saphenous vein varicosities with difficult wire placement

Yan Liang¹, Yusheng Jia², Zhidong Zhang³, Futian Xu⁴, Qian Yang⁵, Jianzhang Yan⁴, Dengpeng Gao⁴, Liheng Liu⁴, Ruijian Zhang⁴, Yubo Guo⁴, Qingfu Zhang¹, Yong Li³

¹Microcirculation Center, The First Hospital of Hebei Medical University, China; ²Department of Surgery, The Second Hospital of Yutian County in Hebei Province, China; ³Third Department of General Surgery, The Fourth Hospital of Hebei Medical University, China; ⁴Department of General Surgery, People's Hospital of Langfang City, China; ⁵Department of Vascular Surgery, The First Hospital of Hebei Medical University, China

Received January 16, 2015; Accepted March 30, 2015; Epub April 15, 2015; Published April 30, 2015

Abstract: Aim: To investigate the efficacy and early postoperative morbidity of a novel endovenous laser ablation (IEVLA) strategy of treatment of the great saphenous vein (GSV) with difficulty of wire placement. Methods: Sixty patients with serious GSV incompetence in 73 limbs were randomized into two treatment groups: Group 1 underwent traditional endovenous laser ablation (TEVLA) surgery and group 2 received IEVLA. Local pain, ecchymosis, induration, paraesthesia in treated regions, thrombotic diseases, vein diameter, treated vein length, delivered energy, operation duration, success rate in placement of the laser fiber and venous clinical severity (VCS) scores were recorded for both group. Follow-up were conducted on the 2nd day, 7th day, and 1st, 2nd, 3rd and 6th month postoperatively. Results: In group 1, induration was present in 18 cases, ecchymosis in 19, paraesthesia in 9, pulmonary embolism (PE) in 1 case, and deep vein thrombus (DVT) in 3. While in group 2, induration present in 29, ecchymosis in 23, paraesthesia in 17 with and no patients were complicated with PE or DVT. Although no difference in improvement of VCS score existed between the two groups at each follow-up time point, group 2 had significantly shorter operation time and higher success rate ($P < 0.05$). Conclusion: IEVLA is a more effective and safe technique for treatment of serious GSV varicosities with difficulty of wire placement.

Keywords: Endovenous laser ablation, varicose veins, great saphenous vein

Introduction

Venous varicosis is a common condition occurring in about 40% of men and 32% of women [1]. Although this disorder in early phases appears benign and asymptomatic, it commonly associates with problems including pain, itching, night cramps, fatigue, heaviness, and in a proportion of patients, chronic venous insufficiency characterized by ankle edema, eczema, hyperpigmentation, and leg ulceration [1-3]. The interference of patients' quality of life by this venous insufficiency is comparable to other common chronic diseases such as arthritis, diabetes and cardiovascular disease [4]. The majority of varicose veins are in great saphenous vein (GSV) incompetence, with or without incompetent perforators. Traditional treatment of GSV varicosities is ligation of the saphenofemoral

junction (SFJ) combined with GSV stripping. However, the associated morbidity and patients' dissatisfaction are considerable, and development of novel treatments is in great need [5].

Endovenous treatment modalities (laser ablation, radiofrequency ablation and foam sclerotherapy) for venous varicosis have been readily accepted by both patients and doctors. Puglisi, et al [6] first described endovenous laser ablation (EVLA) of the GSV in 1989 and Navarro, et al [7] first reported successful result in 2001. Many subsequent studies further used this minimally invasive technique, with improved efficiency, health-related quality of life (HRQOL), reduce serious side effects and postoperative pain, and shortened operational and postoperative recovery time [8-12].

Table 1. Preoperative patient demographics

Parameters	Group 1 (N = 30) TEVLA	Group 2 (N = 30) IEVLA
Number of treated legs	34	39
Gender (M/F)	18/12	19/11
Mean age (years, $\bar{x} \pm s$)	52.0 \pm 8.3	50.0 \pm 7.1
Mean GSV diameter		
SFJ level (mm, $\bar{x} \pm s$)	12.9 \pm 4.5	12.3 \pm 4.1
Mean reflux duration at SFJ (s, $\bar{x} \pm s$)	6.9 \pm 1.8	6.2 \pm 1.4
CEAP classification/limb		
C3	13	15
C4	18	19
C5	3	5
Ep	34	39

M: Male; F: Female; GSV: Great saphenous vein; SFJ: Saphenofemoral junction; TEVLA: traditional endovenous laser ablation; IEVLA: improved endovenous laser ablation; CEAP: clinical etiological anatomical pathological.

However, in our clinical practice, came cross situations difficult performing EVLA procedure. Especially when the varicose veins are tortuous, have small diameters, or large dilated branches emanating from it, or contained thrombotic, sclerotic segments (after a DVT or a previous EVLA), it can be difficult to place in the vein trunk of a guide-wire, catheter and laser fiber through percutaneous cannulation on the distal end of the GSV. Under such circumstances, we usually rotate the wire under monitoring with duplex ultrasound, or switch the wire to a hydrophilic one. Occasionally these endeavors solve the problem. Levent Oğuzkurt did differently by making a second (or even a third) puncture at higher levels, and completed ablation segment by segment, when severe tortuosity or obstructions of the vein could not be crossed [13]. However, this maneuver had risk of intravascular thrombus shedding, and was not effective in managing venous varicosity, collapse, or small veins. Furthermore, the segment-by-segment ablation was time-consuming and laborious. Herein we reported a novel strategy for endovenous laser ablation (IEVLA): ligation of the GSV at high level, followed by pressing the femoral vein by a finger to allow full expansion of the lower limbs superficial venous line saphenous to facilitate guidewire process. Our data demonstrated that the new method of IEVLA was superior to the traditional procedure in managing tortuous, small, branching, or

thrombotic veins, in terms of duration of operation and successful rate of surgery.

Materials and methods

Patients

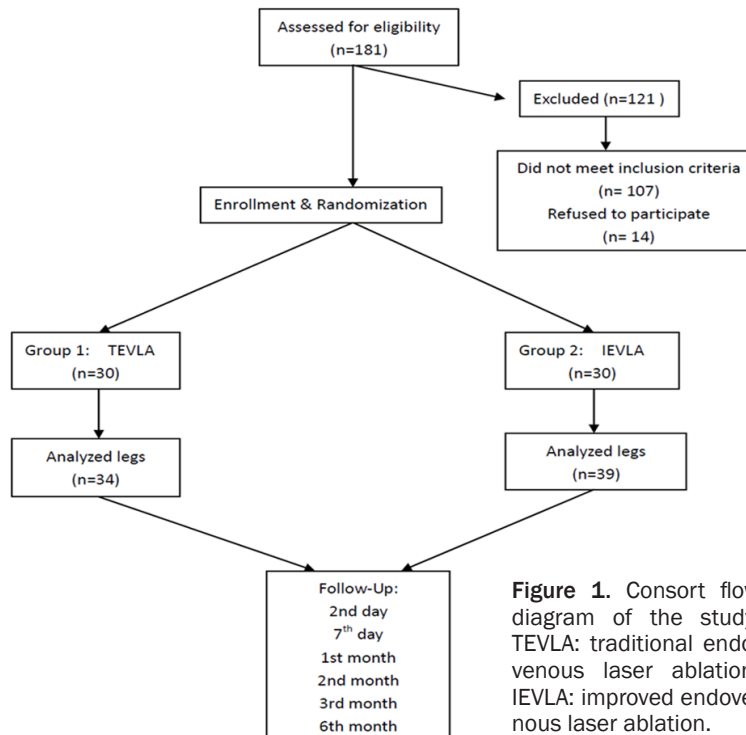
From March 2010 to February 2012, 60 patients, with thrombotic (superficial veins) or severe tortuous lower limb veins in a total 73 legs were recruited into the study at the General Surgery Department of the People's Hospital of Langfang City, China. The study was approved by the hospital Ethics Committee, and written informed consents were obtained from all patients.

Physical examination and duplex ultrasound assessment with HD11 XE Diagnostic Ultra-sound (Philips Ultra-sound, Inc. Bothell, WA, USA) were performed on all patients to evaluate the deep and superficial veins of both lower limbs for Clinical Etiological Anatomical Pathological (CEAP) classification. Patients classified as CEAP class III or greater with documented GSV insufficiency on duplex venous examination were included in the present study (Table 1). Venous clinical severity (VCS) scores were also recorded for each patient. Reflux was defined as retrograde flow in the proximal part of the vein with a duration of 0.5 seconds or longer after a Valsalva maneuver or on manual compression/decompression of the calf to assess the distal part of the vein. A perforator was considered to be incompetent if its diameter was 4 mm or greater and/or its outward directional flow exceeded 0.5 seconds. The diameter of the GSV was measured at the level of the SFJ.

The exclusion criteria were history of previous DVT, superficial thrombophlebitis, sclerotic segments (after a DVT), non-healing ulcers, concomitant peripheral arterial disease (Ankle Brachial Pressure Index < 0.8), difficulty in ambulation, pregnancy or breast-feeding, recurrent varicose veins, reflux in other axial veins, (anterior accessory great saphenous vein, small saphenous vein) and perforators.

The 60 patients (73 limbs) were randomized into two groups based on a computer-generated randomization list. Group 1, 34 lower limbs

Treatment of greater saphenous vein varicosities



in 30 patients, was treated with the 810 nm diode laser (HOP-100 semiconductor laser therapy machine, Long Hui Heng Medical Science and Technology Development Co., Ltd., Beijing, China) and TEVLA. Group 2, 39 lower limbs in 30 patients, was treated using the HOP-100 semiconductor laser therapy machine and the IEVLA.

Operational procedure

All patients underwent the EVLA procedure with local tumescent anesthesia (5 mL of epinephrine, 5 mL of bicarbonate and 35 mL of 1% lidocaine diluted in 500 mL of saline).

For patients in group 1, all GSVs were cannulated percutaneously with a 18-gauge needle at the ankle level of the GSV with the assistance of a tourniquet, followed by insertion of a guide-wire (Radifocus Guide Wire M, Terumo Corporation, Tokyo, Japan) through the needle and placement of a 6-F introducer catheter (Angiographic catheter, Terumo Corporation, Tokyo, Japan) over the guide-wire into the GSV. After withdrawal of the guide-wire, the laser fiber was placed through the catheter. The position of the tip of the laser fiber was ed 1-2 cm below the SFJ, confirmed by direct visualization of the red aiming beam through the skin.

For the patients in group 2, at first, the GSV was ligated at a high level (distal ends of the 5 contributory branches) through a groin incision. The femoral vein on the surgical side was block by finger pressure in time at the level of ending section of GSV to allow maximal expansion of the superficial of the lower limb, followed by percutaneous cannulation of GSVs with a 18-gauge needle at the ankle level. Then the guide-wire was inserted through the needle and the 6-F introducer catheter was inserted into the GSV along the guide-wire. After withdrawal of the guide-wire, the laser fiber was placed through the catheter. The tip of the laser fiber was positioned 1-2 cm below the SFJ, confirmed by direct visualization

of the red aiming beam through the vein. Then the blocking of the femoral vein was relieved.

If there was difficulty in placement of the laser fiber, a segment-by-segment ablation of the trunk of the GSV was performed guided by ultrasound. Laser energy set to 15 W was applied for both groups using the continuous mode and a constant pullback with a rate corresponding to 90 J/cm linear endovenous energy density (LEED). Concomitant phlebectomies for superficial vein thrombus and/or laser ablation in or around branches of varicose veins was performed for both groups, and a compression bandage was applied over the course of the treated vein for 24 h. Patients wore graduated compression stockings (20-30 mmHg, knee-high) for 3 months postoperatively. Patients were advised to walk regularly on the 2nd day post operation, and diclofenac 50 mg twice daily was prescribed as required.

Follow-up

Patients were re-examined on day 2 and 7 and at one, two, three and six months after surgery, with clinical examination and duplex ultrasound to detect incompetent veins. VCS scores, post-operative pain, side effects, adverse events,

Table 2. Operative data

Parameters	Group 1 (N = 30) TEVLA	Group 2 (N = 30) IEVLA	P value
Mean treated GSV length (cm, $\bar{X} \pm s$)	57.4 \pm 10.1	55.1 \pm 9.8	NS
Used laser power (W)	15	15	NS
LEED (J/cm)	90	90	NS
Success rate of laser fiber placement (Success/total, %)	24/34 (70.6%)	36/39 (92.3%)	0.016
Mean total energy/limb (J) of GSV ($\bar{X} \pm s$)	5438 \pm 918	5126 \pm 886	NS
Mean procedure duration/limb (min) (EVLA only) or (EVLA and Miniphelectomy) ($\bar{X} \pm s$)	55.0 \pm 12.1	38.0 \pm 9.3	< 0.001
Immediate postoperative closure rate (%)	100	100	NS

GSV: Great saphenous vein; LEED: linear endovenous energy density; TEVLA: traditional endovenous laser ablation; IEVLA: improved endovenous laser ablation; NS: not significant ($P > 0.05$).

Table 3. Changes in venous clinical severity score (VCSS)

	TEVLA	IEVLA	F	P
Preoperative	9.60 \pm 2.34	9.80 \pm 2.17	705.216	0.000
PO second day	5.63 \pm 1.13	5.40 \pm 1.28		
PO seventh day	4.40 \pm 0.81	4.03 \pm 0.85		
PO first month	3.83 \pm 0.91	3.47 \pm 0.82		
PO second month	3.37 \pm 0.93	3.30 \pm 0.79		
PO third month	3.17 \pm 0.83	3.07 \pm 0.83		
PO sixth-month	3.00 \pm 0.79	2.90 \pm 0.85		
F	0.319		1.205*	
P	0.574			0.296*

*: the value of F and P of interaction between time and group; PO: postoperative; All data are represented by mean \pm standard deviation.

operation duration, success rate in the placement of the laser fiber, and recurrence rate was evaluated and recorded at each visit. Local pain, duration of pain, duration of requirement for analgesia, return to daily activities, ecchymosis, skin burn, skin necrosis, indurations and paraesthesia over treated parts of legs were also recorded at postoperative follow-up visits. These parameters were recorded in a written form by the patients during the follow-up visits. Ecchymosis and paraesthesia were recorded in regions of the limb adjacent to the ablated vein segments. The areas of ecchymosis and paraesthesia were not measured.

Statistical analysis

Comparison of varicosis recurrence, postoperative complications, morbidity and side-effect rates between the two groups was conducted with Chi-square test. Comparison of duration of limb pain and analgesia need was done by using a Wilcoxon rank sum test. Comparison of duration of procedure and recovery time between the two groups was performed with t test. Movement dysfunction, DVT and PE in

both groups was compared using Fisher's exact test. VCS scores at different time points was analyzed by repeated measure ANOVA. A P value of < 0.05 was considered significant. All analyses were performed using SPSS® for Windows version 15.0 (SPSS, Chicago, IL, USA).

Results

A total of 121 patients were excluded from the study due to pregnancy, history of previous DVT, additional peripheral arterial diseases, additional reflux in other venous seg-

ments, or CEAP class II or below. Patient enrollment in this study was shown in a CONSORT diagram (**Figure 1**). Demographic details and results of preoperative clinical and US examinations are shown in **Table 1**. A total of 34 limbs in 30 patients in group 1 and 39 limbs in 30 patients in group 2 were treated as specified. Operative data are shown in **Table 2**. Our goal of achieving a LEED of 90 J/cm was achieved in both groups. The IEVLA saved an average of 17 minutes, 31% of the operation time. Also, treatment with IEVLA had higher successful rate of percutaneous access and endovenous placement of the laser fiber in the trunk of veins, comparing to that of with TEVLA performed in group 1 (92.3% vs 70.6%, $P < 0.05$). Unsuccessful operation required puncturing the trunk and placement of the laser fiber segment by segment, under the guidance of US.

No patient was lost from this series during the 6-month follow-up period. No evidence of residual flow or venous reflux was found on ultrasound imaging at any time during follow-up. VCS scores improved significantly in both groups at all follow-up visits (**Table 3**; **Figure 2**)

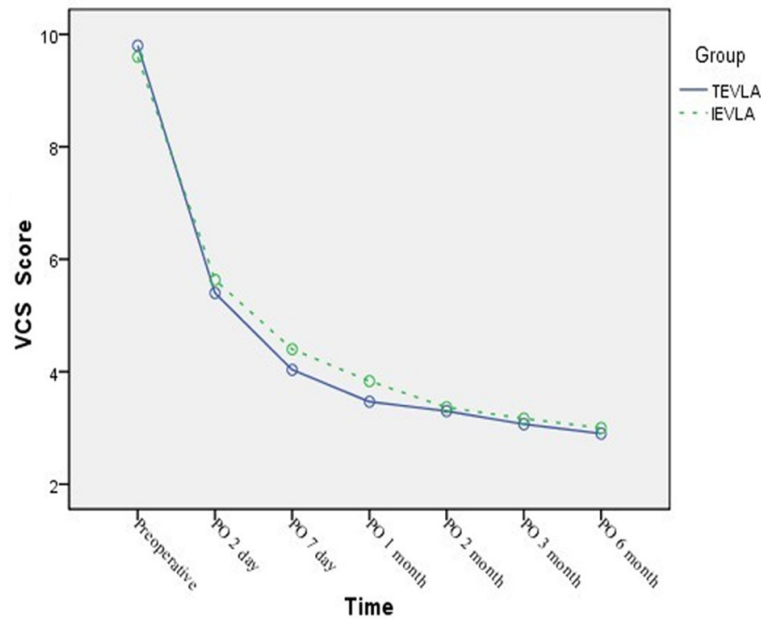


Figure 2. Changes in venous clinical severity (VCS) score. PO: postoperative.

with significant difference existed between the two groups overall ($F = 705.216$, $P = 0.000$) but not for each time point. No interaction was identified between group and time ($F = 1.205$, $P = 0.296$). The results suggested that IEVLA was more effective than TEVLA did.

Table 4 summarizes the side effects and other evaluations of the outcomes. The most frequent side effects in both groups were ecchymosis, indurations and minor paraesthesia, with no difference existing between the two groups for each of them (P all > 0.05). Severe complications such as skin burns and formation of arterio-venous fistulas were not observed. Duration of pain and need for analgesia post-operative were similar in the two groups ($P > 0.05$). Subcutaneous indurations along the treated veins after EVLA resembling palpable cord or a shortened muscle at the medial part of the thigh were noticed in 18 limbs in group 1 and 29 limbs in group 2 ($P > 0.05$), lasting for a mean of 8 weeks in both groups. Paraesthesia in the region of the treated veins was present and not different in both groups.

Post-EVLA, DVT was identified in 3 limbs in 3 patients in group 1. Of them, one presented in close proximity to the superficial-deep venous junction. The thrombus dissolved spontaneously without anticoagulation. The other two pa-

tients presented with extension of the saphenous thrombus into the femoral vein. One of them was treated with warfarin for a 1-month period, and the other was treated with a once daily dose of low molecular weight heparin. Ten days post-EVLA, one patient with PE presented to the emergency room following bilateral TEVLA for bilateral GSV disease.

Severe limb edema and pain was noticed in one female patient in group 1 on the day after surgery. Although treatment with limb elevation and analgesic temporarily relieved the patient's pain, and reduced the swelling, the patient complained of movement limitation of the ankle,

foot drop and flexion deformity of the five toes on day 17 postoperatively.. She was referred to rehabilitation therapy.

Discussion

The technical success rates of EVLA are near 100% among recent studies [5, 14, 15], and the long-term success rates (up to 5 years) range from 90% to 100% [11, 12] based on duplex ultrasound assessment of the treated veins. In our study, we had 100% ablation of veins in both groups within six months. More important, the IEVLA strategy greatly reduced duration of surgery and improved successful rate of surgery managing complicated venous varicosis.

Under most circumstances, it is difficult to advance the wire in the EVLA operation. However, if the varicose vein is tortuous, has a small diameter, has a large dilated branch emanating from it, or contains thrombotic, sclerotic segments (after a DVT or a previous EVLA), it is a dilemma to do so. For such cases, we usually had to ablate the trunk of the GSV segment-by-segment, or rotated the wire, or switch to a hydrophilic wire as described elsewhere [13]. These additional steps not only elongated operation time, but also could cause vascular mural thrombus shedding or other thrombotic diseases.

Table 4. Postoperative data

Parameters	Group 1 (N = 30) TEVLA	Group 2 (N = 30) IEVLA	P value
Pain duration (day) mean (range)	3.5 (3-8)	4.0 (2-8)	0.357
Duration of analgesia need (day) mean (range)	5.0 (2-10)	6.5 (2-10)	0.472
Induration (number of limbs)	18	29	0.057
Ecchymosis (number of limbs)	19	21	0.861
Skin necrosis (number of limbs)	0	0	NS
Skin burn (number of limbs)	0	0	NS
Paraesthesia (number of limbs)	9	17	0.128
Deep vein thrombosis/total limbs	3/34	0/39	0.096
Pulmonary embolus	1	0	1.000
Movement dysfunction/total limbs	1/34	0/39	0.466
Return to daily activity (day, $\bar{x} \pm s$)	3.8 \pm 2.7	3.4 \pm 2.3	0.539
6th month closure rate (%)	100	100	NS

TEVLA: traditional endovenous laser ablation; IEVLA: improved endovenous laser ablation; NS: no significant.

By employing IEVLA, we could avoid these complications, and vascular collapse or vasoconstriction, not only facilitated the surgery.

In this prospective randomized study, we found that IEVLA not only saved operation time but also improved rate of surgery success Dogancin and Demirkilic [16] reported the mean time of operation was about 35 min, which was close to the time of IEVLA in this study. However, our patients had severer varicose.

Recent literature indicate that ligation and non-ligation of the SFJ have no difference in DVT incidence [17-20]. However, in this study, three patients were complicated with DVT (3/30, 10%) and one with PE (1/30, 3%) in the TEVLA group, higher than that reported elsewhere (no more than 1%) [8, 21, 22]. Ultrasound examination demonstrated that the DVTs in the three patients extended from the GSV into the common femoral vein at/or proximal to a site of recent thermoablation. This thrombus extending from the site of thermoablation is called heat-induced thrombosis (EHIT). Nevertheless, none of the patients in the IEVLA group experienced this kind of thrombus due to ligation of the SFJ. As known, factors that may increase the risk of DVT include: patient age, undiagnosed hypercoagulable states and severity of chronic venous disease [23, 24]. In this study, patients were all classified as CEAP class III or greater, and had riskfactors for hypercoagu-

lation. These conditions may account for the higher incidence of thrombotic complications. In the view of another study [25], we propose that patients with serious varicose veins and hypercoagulable states and/or thrombus in the GSV system be treated with IEVLA, not TEVLA.

Our data also showed that no differences existed between the two groups in term of other side effects, i.e., pain, indurations, ecchymosis, paraesthesia, skin necrosis and skin burn, and

time to return to daily activity, duration of analgesia need, the thromblysis rate and VCS scores. These results were compatible with other studies [8, 21, 26, 27]

However, in the TEVLA group, there was a patient with movement dysfunction, who necessitated rehabilitation therapy. We do not know the underlying cause of the dysfunction yet.

A limitation of this study is that the postoperative follow-up time is short. It is possible that the venous varicose veins could recur. Further research is warranted with longer follow-up time.

Acknowledgements

This study was supported by the Science and Technology Research and Development Program of Langfang city (2011013011) and Department of Statistics, Hebei Medical University.

Disclosure of conflict of interest

None.

Address correspondence to: Yong Li, Third Department of General Surgery, The Fourth Hospital of Hebei Medical University, No. 12 Jiankang Road, Shijiazhuang, 050011, Hebei Province, China. E-mail: li_yong_hbth@126.com

References

- [1] Evans CJ, Fowkes FG, Ruckley CV, Lee AJ. Prevalence of varicose veins and chronic venous insufficiency in men and women in the general population: Edinburgh Vein Study. *J Epidemiol Community Health* 1999; 53: 149-53.
- [2] Callam MJ, Harper DR, Dale JJ, Ruckley CV. Chronic ulcer of the leg: clinical history. *Br Med J (Clin Res Ed)* 1987; 294: 1389-91.
- [3] Fiebig A, Krusche P, Wolf A, Krawczak M, Timm B, Nikolaus S, Frings N, Schreiber S. Heritability of chronic venous disease. *Hum Genet* 2010; 127: 669-74.
- [4] Andreozzi GM, Cordova RM, Scomparin A, Martini R, D'Eri A, Andreozzi F; Quality of Life Working Group on Vascular Medicine of SIAPAV. Quality of life in chronic venous insufficiency. An Italian pilot study of the Triveneto Region. *Int Angiol* 2005; 24: 272-7.
- [5] van den Bos R, Arends L, Kockaert M, Neumann M, Nijsten T. Endovenous therapies of lower extremity varicosities: a meta-analysis. *J Vasc Surg* 2009; 49: 230-9.
- [6] Puglisi B, T.A, San Filippo F. Application of the ND-YAG laser in the treatment of varicose syndrome. *J Libby Eurotext* 1989: 39-842.
- [7] Navarro L, Min RJ and Bone C. Endovenous laser: a new minimally invasive method of treatment for varicose veins—preliminary observations using an 810 nm diode laser. *Dermatol Surg* 2001; 27: 117-22.
- [8] Min RJ, Khilnani N and Zimmet SE. Endovenous laser treatment of saphenous vein reflux: long-term results. *J Vasc Interv Radiol* 2003; 14: 991-6.
- [9] Nootheti PK, Cadag KM and Goldman MP. Review of intravascular approaches to the treatment of varicose veins. *Dermatol Surg* 2007; 33: 1149-57; discussion 1157.
- [10] Disselhoff BC, Buskens E, Kelder JC, der Kinderen DJ, Moll FL. Randomised comparison of costs and cost-effectiveness of cryosurgery and endovenous laser ablation for varicose veins: 2-year results. *Eur J Vasc Endovasc Surg* 2009; 37: 7.
- [11] Ravi R, Trayler EA, Barrett DA, Diethrich EB. Endovenous thermal ablation of superficial venous insufficiency of the lower extremity: single-center experience with 3000 limbs treated in a 7-year period. *J Endovasc Ther* 2009; 16: 500-5.
- [12] Spreafico G, Kabnick L, Berland TL, Cayne NS, Maldonado TS, Jacobowitz GS, Rockman CR, Lamparello PJ, Baccaglini U, Rudarakanchana N, Adelman MA. Laser saphenous ablations in more than 1,000 limbs with long-term duplex examination follow-up. *Ann Vasc Surg* 2011; 25: 71-8.
- [13] Oguzkurt L. Endovenous laser ablation for the treatment of varicose veins. *Diagn Interv Radiol* 2012; 18: 417-22.
- [14] van den Bos RR, Kockaert MA, Neumann HA, Nijsten T. Technical review of endovenous laser therapy for varicose veins. *Eur J Vasc Endovasc Surg* 2008; 35: 88-95.
- [15] Theivacumar NS, Beale RJ, Mavor AI, Gough MJ. Initial experience in endovenous laser ablation (EVLA) of varicose veins due to small saphenous vein reflux. *Eur J Vasc Endovasc Surg* 2007; 33: 5.
- [16] Doganci S and Demirkilic U. Comparison of 980 nm laser and bare-tip fibre with 1470 nm laser and radial fibre in the treatment of great saphenous vein varicosities: a prospective randomised clinical trial. *Eur J Vasc Endovasc Surg* 2010; 40: 254-9.
- [17] Bush RG. Regarding "Laser therapy and radiofrequency ablation of the great saphenous vein: analysis of early efficacy and complications". *J Vasc Surg* 2006; 43: 642.
- [18] Gale SS, Dosick SM, Seiwert AJ, Comerota AJ. Regarding "Deep venous thrombosis after radiofrequency ablation of greater saphenous vein". *J Vasc Surg* 2005; 41: 374.
- [19] Gradman WS. Adjunctive proximal vein ligation with endovenous obliteration of great saphenous vein reflux: does it have clinical value? *Ann Vasc Surg* 2007; 21: 155-8.
- [20] Manfrini S, Gasbarro V, Danielsson G, Norgren L, Chandler JG, Lennox AF, Zarka ZA, Nicolaides AN. Endovenous management of saphenous vein reflux. Endovenous Reflux Management Study Group. *J Vasc Surg* 2000; 32: 330-42.
- [21] Agus GB, Mancini S, Magi G; IEWG. The first 1000 cases of Italian Endovenous-laser Working Group (IEWG). Rationale, and long-term outcomes for the 1999-2003 period. *Int Angiol* 2006; 25: 209-15.
- [22] Ravi R, Rodriguez-Lopez JA, Trayler EA, Barrett DA, Ramaiah V, Diethrich EB. Endovenous ablation of incompetent saphenous veins: a large single-center experience. *J Endovasc Ther* 2006; 13: 5.
- [23] Puggioni A, Kalra M, Carmo M, Mozes G, Gloviczki P. Endovenous laser therapy and radiofrequency ablation of the great saphenous vein: analysis of early efficacy and complications. *J Vasc Surg* 2005; 42: 488-93.
- [24] Hingorani AP, Ascher E, Markevich N, Schutzer RW, Kallakuri S, Hou A, Nahata S, Yorkovich W, Jacob T. Deep venous thrombosis after radiofrequency ablation of greater saphenous vein: a word of caution. *J Vasc Surg* 2004; 40: 500-4.
- [25] Marsh P, Price BA, Holdstock J, Harrison C, Whiteley MS. Deep vein thrombosis (DVT) after venous thermoablation techniques: rates of

Treatment of greater saphenous vein varicosities

endovenous heat-induced thrombosis (EHIT) and classical DVT after radiofrequency and endovenous laser ablation in a single centre. *Eur J Vasc Endovasc Surg* 2010; 40: 521-7.

[26] Sharif MA, Soong CV, Lau LL, Corvan R, Lee B, Hannon RJ. Endovenous laser treatment for long saphenous vein incompetence. *Br J Surg* 2006; 93: 831-5.