

Original Article

Lateral tarsal artery flap: an option for hypopharyngeal reconstruction in patients with hypopharyngeal carcinomas after surgery

Chengyuan Wang^{1,2*}, Qiang Wang^{2*}, Zengtao Wang³, Guojun Li⁴, Dazhang Yang¹

¹Department of Otolaryngology Head and Neck Surgery, China-Japan Friendship Hospital, Beijing 100029, China; ²Department of orthopedics, Shenmu County Hospital 719300, Shanxi Province, China; ³Department of Hand and Foot Surgery, Provincial Hospital Affiliated to Shandong University, Jinan 250021, China; ⁴Department of Head and Neck Surgery, The University of Texas MD Anderson Cancer Center, Houston, TX 77030, USA. *Equal contributors.

Received January 30, 2015; Accepted April 3, 2015; Epub April 15, 2015; Published April 30, 2015

Abstract: Background: Hypopharyngeal reconstruction following resection of hypopharyngeal carcinoma has utilized local, regional and free tissue transfer flap options. No single surgical technique is currently in use for hypopharyngeal reconstruction that is applicable to all patients. In this article, we introduce the application of the lateral tarsal artery flap (LTA flap) as a reconstructive option following hypopharyngeal oncologic ablation. Methods: From June 2010 to January 2012, four patients of hypopharyngeal carcinomas underwent total laryngectomy and partial pharyngectomy followed by single-stage reconstruction with LTA flaps. After operation, patients were treated with radical radiotherapy within four weeks. All the patients were followed up. Results: All flaps survived, with an average size of 7.5 cm × 5.8 cm (range of 8.0-7.0 cm × 6.0-5.0 cm). There were no complications or contractures during the follow-up. Normal diets were adopted two weeks after operation. The follow-up ranged from 12-20 months (mean: 15 months). There were no distal stenosis or pharyngocutaneous fistula nor were there any donor-site complications. Conclusion: The LTA flap could be a viable option for hypopharyngeal reconstruction following head and neck oncologic resection. It seems that LTA flap would be a promising flap deserving extensively research.

Keywords: Lateral tarsal artery flap, free flaps, head and neck reconstruction, hypopharyngeal carcinoma

Introduction

Hypopharyngeal squamous cell cancer (HypSCC) is an ominous disease that is frequently diagnosed in advanced stages. HypSCC resection should keep a safe macroscopic surgical margin of at least three cm. Except for tumors limited to the medial wall of the piriform fossa, almost invariably a total laryngectomy with sub-total or circumferential hypopharyngectomy is required [1]. After extensive HypSCC removal, the repair of the devastating pharyngeal defect is one of the most challenging procedures for the head neck reconstructive surgeon. The gold standard for hypopharyngeal reconstruction is to avoid acute or chronic pharyngocutaneous fistulas, to minimize donor site morbidity and to perform a reliable surgery [2]. Several reconstructive modalities have been described,

either with a pedicled flap or free flap. With the help of microsurgical techniques, free flaps such as jejunum [3], radial fasciocutaneous [4] and anterolateral thigh (ALT) flap [5] are widely used in reconstruction of hypopharyngeal defects [6, 7].

They have facilitated single-stage repair and minimized the postoperative complications [8]. Unfortunately, there is still no such perfect technique and we continue to fall short of some of these hypopharyngeal reconstruction goals. It is imperative to develop a more reliable reconstructive strategy that allows an expedient functional restoration to maximize quality of life from the short-term or palliative point of view. In this article, we have introduced the novel application of LTA flap in hypopharyngeal reconstruction resulting from head and neck ablative sur-

LTA flap for hypopharyngeal reconstruction

Table 1. Demographics and tumor data for four patients

Case	Age/gender	TNM	PD	OP	Flap	Size (cm)	RT	DS	PF	Follow up (months)	OR
1	59/m	T4 N2M0	scc	LPG	LTA	8.0 × 6.0	72Gy	no	no	12	svr
2	63/m	T4 N1M0	scc	LPG	LTA	7.0 × 6.0	72Gy	no	no	14	svr
3	68/m	T4 N2M0	scc	LPG	LTA	7.0 × 5.0	72Gy	no	no	16	svr
4	76/m	T4 N1M0	scc	LPG	LTA	8.0 × 6.0	72Gy	no	no	20	svr

(pathological diagnosis, PD; squamous cell carcinoma, scc; oncologic operation, OP; laryngopharyngectomy, LPG; radiotherapy, RT; distal stenosis, DS; pharyngocutaneous fistula, PF; oncologic result, OR; survival without recurrence, svr).

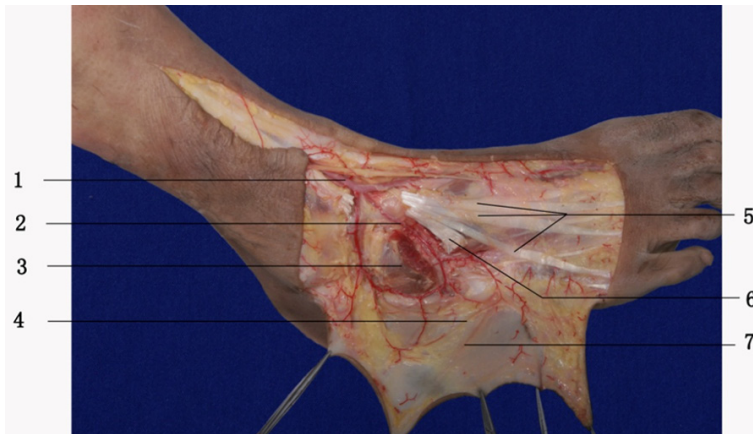


Figure 1. The anatomy of LTA and LTA flap. 1 dorsalis pedis artery; 2 LTA; 3 extensor digitorum brevis was traversed to expose the LTA; 4 lateral dorsal cutaneous nerve of foot; 5 tendon of peroneus tertius muscle; 6 extensor digitorum longus; and 7 small saphenous vein.

gery. The LTA flap has unique features such as large size, thin, hairless and easy to harvest. It has effectively avoided distal stenosis or pharyngocutaneous fistula and improved the post-operative life quality of advanced HypSCC patients.

Methods

Study patients

Comprehensive therapy was applied to four patients with advanced hypopharyngeal cancers from the second half of 2011 to January 2012 (**Table 1**). The pathological diagnosis was squamous cell carcinoma for all the cases. All patients underwent total laryngectomy and partial pharyngectomy with bilateral neck dissection. Because the remnant healthy mucosa to close the neo-pharynx was less than the 2.5 cm standard [9], the devastating pharyngeal cavity was reconstructed with LTA flap simultaneously. All patients gave written informed consent, and the Ethics Committee of China-Japan Friendship Hospital approved the protocol of this study.

Surgical anatomy

The LTA flap is a perforator-based flap. The surface umbriferous line of LTA extends from the pulsating point of dorsal pedal artery to the bottom of the fifth metatarsal bone. The LTA originates from dorsal pedal artery and crosses the navicular bone. It passes to arrive at the fifth metatarsal bone in an arched direction laterally, lying upon the tarsal bones, and covered by the Extensor digitorum brevis. The LTA anastomoses with branches of the arcuate, anterior lateral malleolar and lateral plantar arteries as well as

the perforating branch of the peroneal artery. The perforators of LTA may be septocutaneous or/and musculocutaneous type. The septocutaneous perforators locate near the middle point of the line drawn from lateral malleolus to fibular side of the fifth metatarsal head. The septocutaneous perforators feed the rich arborizing and interconnected plexus under the skin of lateral dorsal aspect of foot and mainly provide blood supply to LTA flap. It runs with the lateral terminal branch of the deep fibular nerve. The lateral dorsal cutaneous nerve of the foot passes the LTA flap [10, 11] (**Figure 1**).

Flap harvest and transplant

The LTA flap was performed under tourniquet control. The perforators of LTA were detected by a handheld Doppler probe. According to the defect, the lateral dorsal aspect of foot was marked around perforator point. The surface umbriferous line of LTA was located in the axis of the flap. First incision was made from the tibial side of flap to expose the extensor digitorum brevis. The perforators of LTA were exposed clearly when the extensor digitorum brevis was

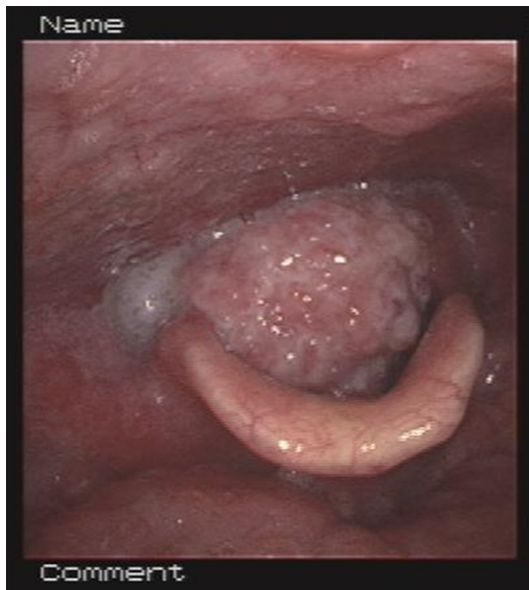

Figure 2. Carcinoma of the hypopharynx invaded larynx from post cricoid area.

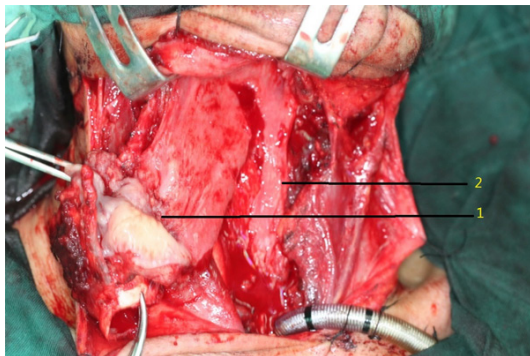


Figure 3. Remaining healthy mucosa of the hypopharynx. 1. Total larynx and partial pharynx were removed for keeping tumor free border. 2. Strip pharyngeal mucosa was left.

elevated upward gently. The extensor digitorum brevis was transected for a better exposure.

The remainder of the flap borders were incised and sutured around to prevent the fascia and skin from separating in the course of dissection. The flap was raised at the subfacial level. The vena comitans of LTA and lateral dorsal cutaneous nerve of foot were carefully protected during the dissection until they perforated into the cutaneous level. The LTA was traced back to the original point of dorsal pedal artery. It was then ligated and cut. The donor site was covered by a full skin graft from the abdomen. The free LTA flap was transplanted into repair

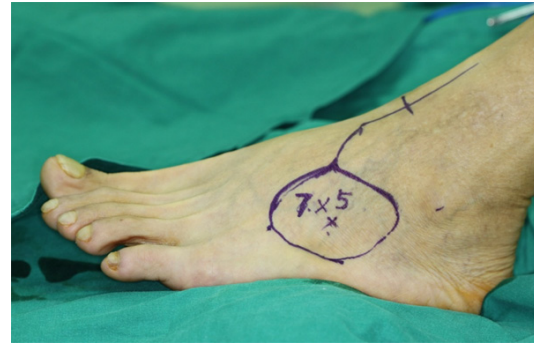


Figure 4. The LTA flap design. 7 × 5 cm LTA flap was marked.

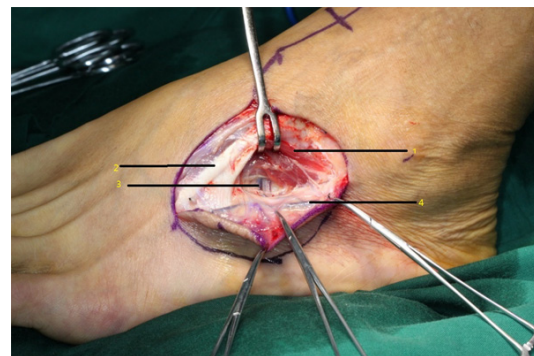


Figure 5. The perforator of the LTA flap. 1. extensor digitorum brevis; 2. extensor digitorum longus; 3. LTA perforators; and 4. small saphenous vein.

hypopharyngeal defect by LTA anastomosing with branch of superior thyroid artery, the vena comitans of LTA anastomosing with superior thyroid vein or superficial vein of cervix under microscope. Vessels were anastomosed by end-to-end interrupted technique.

Results

Four patients of our series took total laryngectomy and partial pharyngectomy. Ablative defects were reconstructed by LTA flap. The largest skin flap was 8.0 × 6.0 cm with an average size of 7.5 × 5.8 cm (range of 8.0~7.0 × 6.0~5.0 cm). Flaps were raised in approximately one and a half hours and performed immediately after the head and neck resection. All flaps survived without complication. Before being discharged, the patients were decannulated. Normal diets were adopted two weeks after operation. All patients were treated with radical radiotherapy within four weeks after operation. Foot wounds healed in two weeks. The patient follow-up ranged from 12-20

LTA flap for hypopharyngeal reconstruction

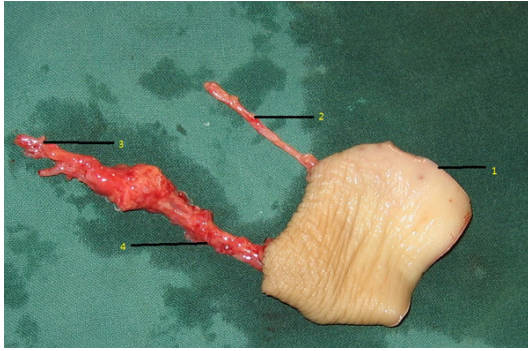


Figure 6. 1. Free LTA flap; 2. Dorsalis pedis artery; 3. LTA; and 4. Small saphenous vein.

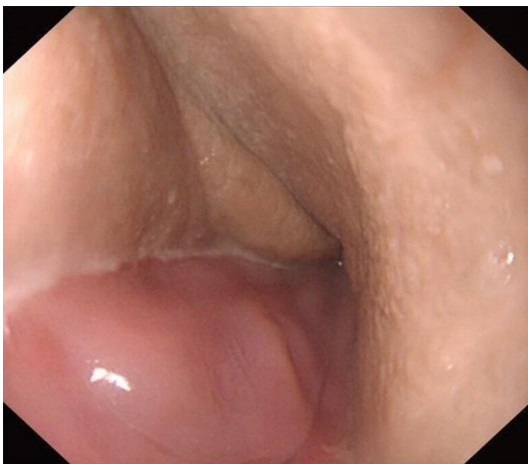

Figure 7. Sixteen months after LTA flap reconstruction. Entrance of esophagus closed well.

months (mean of 15 months) but each Patient was followed up for at least 12 months. There was no hypopharyngeal stenosis, neck infection or tumor recurrence. None of the patients was worried about covert scar appearance on foot and abdomen.

Here we reported our cases. A 68-year-old man was diagnosed with T4 N2M0 squamous cell carcinoma of the hypopharynx. The patient underwent comprehensive therapy including surgery and postoperative radiotherapy. After a salvage total laryngectomy and partial pharyngectomy with bilateral neck dissection, the remaining healthy mucosa to close neo-pharynx was less than 2.5 cm. The pharyngeal defect size was 7.0 cm in length and 5.0 cm in diameter. The reconstruction was achieved by lateral tarsal artery flap and the flap survived well. Normal diet was adopted two weeks after the operation. The postoperative radiotherapy

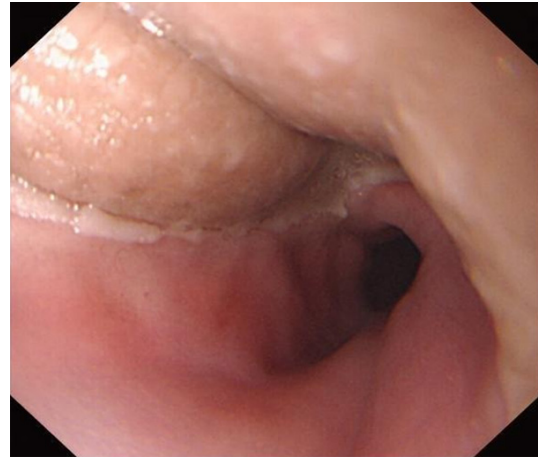


Figure 8. Esophagus inlet after 16 months post LTA flap reconstruction. There is no stenosis.

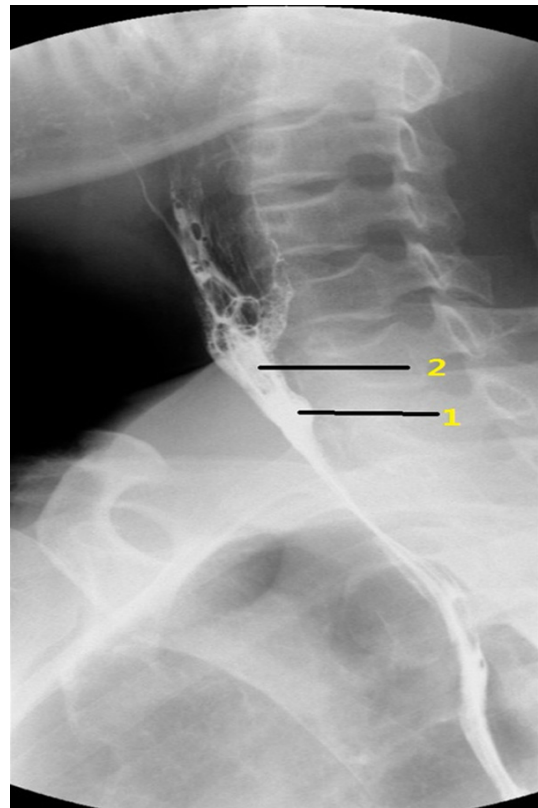


Figure 9. Esophagography results in 16 months post LTA flap reconstruction. There is no stiffness sign of esophagus inlet. 1. new pharynx reconstructed by LTA flap; 2 Esophagus inlet.

was admitted within four weeks. During the follow-up period of 16 months, tumor recurrence, distal stenosis or pharyngocutaneous fistula did not occur (**Figures 2-9**).

Discussion

The LTA flap cadaveric injection studies were first performed by Zheng in 1997 [10]. In anatomy, the external diameter of lateral tarsal artery is 1.42 ± 0.34 mm, its length is 6.2 ± 1.1 cm and the patency of the LTA is 100% [12, 13]. There are two venae comitantes with the external diameter of 1.9 ± 0.5 mm and 2.0 ± 0.4 mm, respectively [10]. The LTA flap can be used as pedicle or free type. Qiu [14] first described its clinical use in foot defect repair in 1998. From among six clinical cases, five flaps survived well and one case had partial necrosis. In 2009, Huang [11] reported LTA flap in repairing first web space of hand. In 2010, Hu [15] reported ALT flaps in repairing hand and foot Cutaneous Defects. Because it provides a thin, pliable and vascularized tissue for replacing the skin in particular areas, it is more and more popular in hand and foot surgery.

Advanced hypopharyngeal carcinomas are typically treated with laryngopharyngectomy and radiotherapy. When the healthy mucosa necessary to primarily close the neopharynx is less than 2.5 cm, the flap is needed to close the defect to prevent the pharyngocutaneous fistula and or postoperative dysphagia [9]. In the four cases in this study, the neopharynx was reconstructed by LTA flap after total laryngectomy and partial hypopharyngectomy. Its largest size was 8×6 cm with an average size of 7.5×5.8 cm. The proper size of LTA flap contributed to the repair hypopharyngeal cavity easily without any tension. However, there is a lack of anatomical study on the maximum size of the LTA flap that can be safely harvested from the foot without complication such as necrosis. It is important to always pay attention to the bleeding and color changing of the flap edge in dissection that can help to prevent ischemia and necrosis of LTA flap. According to our experience, the mean thickness of LTA flap was about 2 mm, a little thinner than hypopharyngeal wall (2.89 ± 0.56 mm) [16]. It was easy to suture edges of these two different types of tissues together in an eversion fashion. Furthermore, the LTA flap was pliable and hairless. In neopharynx reconstruction, thinner and softer flap maybe associated with excellent functional results in deglutition and may prevent stenosis. LTA flap could be a perfect functional substitute for hypopharynx. Patients with LTA flap repair gradually returned to normal diet after 14 days

post-operation. All patients were treated with radical radiotherapy within four weeks after operation. During the follow-up period, distal stenosis or pharyngocutaneous fistula did not occur in any of the cases. However, it was reported that distal stenosis rates occurred in forearm and anterolateral thigh flaps in 0-36% (mean of 11%) and 0-30% (mean, 9%) of the cases; respectively. The rate of pharyngocutaneous fistula occurrence in forearm and anterolateral thigh flaps were 2-53% (mean of 20%) and 0-25% (mean of 15%); respectively [17]. As an effective method of pharyngeal reconstruction, LTA flap helped to recover quickly, to restore swallowing effectively and to withstand the radiotherapy subsequently. The result of the LTA flap in hypopharyngeal reconstruction was really encouraging. Even though it did not necessarily mean that the LTA flap was superior to the forearm or anterolateral thigh flaps in avoiding digestive conduit stenosis and pharyngocutaneous fistula. Due to insufficient number of cases, there was not enough statistical proof demonstrating that the LTA flap could be a promising flap deserving extensively research.

The LTA flap is an artery flap based on septocutaneous or musculocutaneous perforators supplied by the LTA. After arising from dorsal pedal artery, LTA passes in an arched direction outwards, lying upon the tarsal bones, covered by the extensor digitorum brevis [18]. It is important to detect the perforator before operation, even though the absence of anatomic anomaly of LTA is rarely documented. The perforator often is located near the middle point of the imaginary line drawn from lateral malleolus to fibular side of the fifth metatarsal head. Because of its being covered with very thin skin, the perforator could be easily and quickly detected by Doppler. We recommend that, first incision begins from tibial side. It is easy and safe to expose the extensor digitorum brevis and LTA perforator. The extensor digitorum brevis should always be transected for a better operative field exposure. The LTA tightly attaches to the tarsal bone below it. In order to protect LTA perforator, the vascular pedicle, with the tissue around it, should be elevated directly from tarsal bone. At this point, a meticulous manipulation is absolutely necessary. The mean time of LTA flap dissection is about one and a half hours, much slower than forearm flap dissection but same as anterolateral thigh flap in China-Japan Friendship Hospital. Thus,

free LTA flap does not increase the manipulation difficulties as compared to the conventional microsurgical workhorse flaps.

Because the foot lateral dorsal cutaneous nerve passes through the LTA flap, it has the ability to provide sensory innervation for better functional reconstruction of hypopharynx. Furthermore, compared with forearm or anterolateral thigh flap, the scar appearance on foot is less noticeable than others. We believe that the LTA flap has several advantages in hypopharyngeal reconstruction that are mentioned in the next few sentences. It is easy to harvest the LTA flap with relatively constant anatomy. The pedicle of LTA flap is large and long. The LTA flap has superficial and deep venous systems, which allows for flexibility of venous anastomosis. The LTA flap is often thin, pliable and often hairless. Also LTA flap has the ability to provide the sensory innervation without significant donor site morbidity. The detailed anatomic and clinical data are still lacking in regard to the maximum size of the LTA flap. However, LTA flap is empirically smaller in size than pectoral or ALT flaps.

In conclusion, there is no single surgical technique that is currently in use and applicable to all patients for hypopharyngeal reconstruction. This is the first report of LTA flap used in hypopharyngeal reconstruction. LTA flap has the advantages of being thin, pliable, and hairless, having a long pedicle, being easy to harvest and possessing an acceptable donor site morbidity. The reconstructive armamentarium of head and neck surgeons should encompass every option in order to appropriately deal with specific clinical needs and patient requirements. LTA flap can provide a safe, reliable and one-stage functional reconstruction of hypopharyngeal defects.

Disclosure of conflict of interest

None.

Abbreviations

LTA, lateral tarsal artery; HypSCC, hypopharyngeal squamous cell cancer; ALT, anterolateral thigh.

Address correspondence to: Chengyuan Wang, Department of Otolaryngology Head and Neck Surgery, China-Japan Friendship Hospital, Beijing 100029,

China. Tel: +86-10-84205362; Fax: +86-10-84205362; E-mail: zryhyent@gmail.com

References

- [1] Ho CM, Lam KH, Wei WI, Yuen PW, Lam LK. Squamous cell carcinoma of the hypopharynx-analysis of treatment results. *Head Neck* 1993; 15: 405-412.
- [2] Ho MW, Houghton L, Gillmartin E. Outcomes following pharyngolaryngectomy reconstruction with the anterolateral thigh (ALT) free flap. *Br J Oral Maxillofac Surg* 2012; 50: 19-24.
- [3] Seidenberg BR, Hurwitt E. Immediate reconstruction of the cervical esophagus by a revascularized isolated jejunal segment. *Ann Surg* 1959; 149: 162-171.
- [4] Harii K, Ebihara S, Ono I, Saito H, Terui S, Takato T. Pharyngoesophageal reconstruction using a fabricated forearm free flap. *Plast Reconstr Surg* 1985; 75: 463-476.
- [5] Song YG, Chen GZ, Song YL. The free thigh flap: a new free flap concept based on the septocutaneous artery. *Br J Plast Surg* 1984; 37: 149-159.
- [6] Murray DJ, Novak CB, Neligan PC. Fasciocutaneous free flaps in pharyngolaryngo-oesophageal reconstruction: a critical review of the literature. *J Plast Reconstr Aesthet Surg* 2008; 61: 1148-1156.
- [7] Wei FC, Jain V, Celik N, Chen HC, Chuang DC, Lin CH. Have we found an ideal soft-tissue flap? An experience with 672 anterolateral thigh flaps. *Plast Reconstr Surg* 2002; 109: 2219-2226.
- [8] Disa JJ, Pusic AL, Hidalgo DA, Cordeiro PG. Microvascular reconstruction of the hypopharynx: defect classification, treatment algorithm, and functional outcome based on 165 consecutive cases. *Plast Reconstr Surg* 2003; 111: 652-660.
- [9] Hui Y, Wei WI, Yuen PW, Lam LK, Ho WK. Primary closure of pharyngeal remnant after total laryngectomy and partial pharyngectomy: how much residual mucosa is sufficient. *Laryngoscope* 1996; 106: 490-494.
- [10] Heping Z, Hanguo X, Yi G. Applied Anatomy of Lateral Pedal Retrograde Flap with Lateral Tarsal Artery. *J Fujian Med Univ* 1997; 31: 200-202.
- [11] Huang D, Wang HG, Zhao CY, Wu WZ. An alternative approach in the treatment of thumb web contracture skin defects: lateral tarsal artery flap. *Chin Med J (Engl)* 2009; 122: 2133-2137.
- [12] Sham E, Choi WT, Flood SJ. Lateral supramalleolar flap in reconstruction of pressure ulcers in patients with spinal cord injury. *ANZ J Surg* 2008; 78: 167-171.

- [13] Touam C, Rostoucher P, Bhatia A, Oberlin C. Comparative study of two series of distally based fasciocutaneous flaps for coverage of the lower one-fourth of the leg, the ankle, and the foot. *Plast Reconstr Surg* 2001; 10: 383-392.
- [14] Changsheng Q, Weihong X, Heping Z. Anatomic study and clinic application of lateral pedal retrograde flap with lateral tarsal artery. *Chin J Clin Anatom* 1998; 16: 113-115.
- [15] Hu Yong WZ, Shuyuan L. Lateral Tarsal Artery Flap in Repairing Hand and Foot Cutaneous Defects. *Chin J Min Inv Sur* 2010; 10: 732-734.
- [16] Xinyu HJ. Normal CT manifestations of hypopharynx at the level of cricoid cartilage in adults. *Chin J Radiolog* 2008; 42: 724-728.
- [17] Piazza C, Taglietti V, Nicolai P. Reconstructive options after total laryngectomy with subtotal or circumferential hypopharyngectomy and cervical esophagectomy. *Curr Opin Otolaryngol Head Neck Surg* 2012; 20: 77-88.
- [18] Zhengtao W. *Clinical Anatomic Atlas of Microsurgery*. Shandong Sci Tech Press 2009; 22: 691-675.