

## Original Article

# Diagnostic value of strain ratio measurement in differential diagnosis of thyroid nodules coexisted with Hashimoto thyroiditis

Jianhong Wang<sup>1</sup>, Ping Li<sup>2</sup>, Lingling Sun<sup>3</sup>, Yongmei Sun<sup>2</sup>, Shibao Fang<sup>2</sup>, Xuejun Liu<sup>4</sup>

<sup>1</sup>Organ Transplantation Center, Affiliated Hospital of Qingdao University, Qingdao 266003, China; <sup>2</sup>Department of Ultrasound, Affiliated Hospital of Qingdao University, Qingdao 266003, China; <sup>3</sup>Department of Pathology, Affiliated Hospital of Qingdao University, Qingdao 266003, China; <sup>4</sup>Department of Radiology, Affiliated Hospital of Qingdao University, Qingdao 266003, China

Received February 5, 2015; Accepted April 4, 2015; Epub April 15, 2015; Published April 30, 2015

**Abstract:** Objective: To evaluate the differential diagnostic potential of lesion stiffness assessed by the sonoelastographic strain index ratio (SR) for thyroid nodules coexist with Hashimoto thyroiditis (HT). Methods: A total of 50 focal thyroid nodules from 36 patients with HT (mean age 38.4 years; range 19-77) scheduled for fine-needle aspiration or thyroid surgery were included. After a routine conventional ultrasound evaluation, real-time ultrasound elastography examinations were performed. Strain and area ratios of each lesion were calculated within the same machine. Histological diagnosis was used as the reference standard. The elastography images were scored according to the Asteria elasticity score. The area under the curve (AUC) and cut-off point were obtained by receiver operating curve (ROC). Sensitivity, specificity and accuracy were compared. Results: A total of 38 nodules were benign and 12 were malignant on pathology. The mean strain ratios of benign and malignant lesions were 2.89 and 7.83 respectively. When a cut-off point of 5.03 was used, SR had a sensitivity of 75.0%, a specificity of 92.1% and an accuracy of 84.0%. The AUC values were 0.836. The diagnostic accuracy of the SR was superior to that of elastographic score. Conclusion: Real-time elastography is a promising tool for differential diagnosis of thyroid nodules coexist with HT, and SR measurement could be an effective predictor. The best cut-off point for benign and malignant nodules in patients with HT was 5.03.

**Keywords:** Elastography, strain ratio, thyroid nodule, Hashimoto disease, ultrasound

## Introduction

Hashimoto thyroiditis (HT) is a very common chronic autoimmune disease with lymphocytic infiltration and fibrosis. This inflammation is primarily related to the formed autoantibodies against to the thyroid tissue [1]. The disease causes stiff gland while changing the ultra-structure of the thyroid gland. Nodules are frequently seen in HT. Malignancy is also observed in HT patients with nodule of similar frequency [2, 3]. In fact, there is an increased risk of lymphoma and possibly an increased risk of papillary thyroid carcinoma in patients with HT [4, 5].

For this reason, it is important to detect the malignancy in thyroid nodule in HT patients. Ultrasound (US) has emerged as an excellent tool for detecting thyroid nodules. But it has

limitations in the differential diagnosis between benign and malignant nodules, especially for atypical nodules. Elastography is a newly developed technique that measures the elasticity (degree of tissue distortion) of thyroid nodules using ultrasonography under the application of an external force [6]. Elastography may reduce unnecessary surgeries and has been reported to be useful in the assessment of malignancy [7]. Malignant nodules are harder in consistency and have a greater elastography score and strain index under elastographic evaluation. However, the diagnostic value of strain ratio (SR) measurement in patients with HT has not been well documented. Thus, the goal of the present study was to investigate whether SR measurement method can be applied as effective predictors in characterizing lesions precisely.

**Table 1.** Elasticity score of thyroid nodules and elastographic characteristic of each score

1	Elasticity in the whole examined area	Homogeneously green
2	Elasticity in a large portion of the examined area	Almost the whole tumor is in light green with some peripheral and/or central blue areas
3	No elasticity in a large portion of the examined area	Almost the whole tumor is in hard blue with some light green and red areas
4	No elasticity in the whole examined area	Homogeneously hard blue

## Materials and methods

### Patients

The study was performed in accordance with the ethical guidelines of the Declaration of Helsinki and was approved by the institutional ethics board of Qingdao University Affiliated Hospital. From June 2012 to May 2013, a total of 50 thyroid nodules in 36 patients with HT (2 males and 34 were females; age range, 19 to 77 years; mean age, 38.4 years) were analyzed in the study. Of these patients, 17 (47.2%) presented with a single nodule, and 19 (52.7%) exhibited multiple nodules. The final diagnoses were confirmed by cytology after fine-needle aspiration (FNA) or histology after thyroid surgery. The indication for surgery was goiter with compressive symptoms or progressive growth, or suspicion of malignancy. Surgery was also scheduled for FNA-proven malignancy. Follow-up of 6 months or more was performed for each benign nodule diagnosed by FNA.

The diagnosis of HT was made in the presence of a positive test for thyroglobulin antibody (TgAb) and/or thyroid peroxidase (TPOAb) antibody, and a hypoechoic pattern of the thyroid at US.

### Ultrasound examinations

All examinations were performed using a Hitachi HA-900 (Hitachi Medical, Tokyo, Japan) US scanner. A linear array transducer having a 15- to 4-MHz frequency bandwidth was used for all the conventional US and real-time elastosonography examinations.

### Conventional ultrasound examination

For all patients, the US examination started with B-mode and color Doppler imaging. The patient was positioned on his or her back with the neck slightly extended over a pillow. The suspicious regions including the nodules and

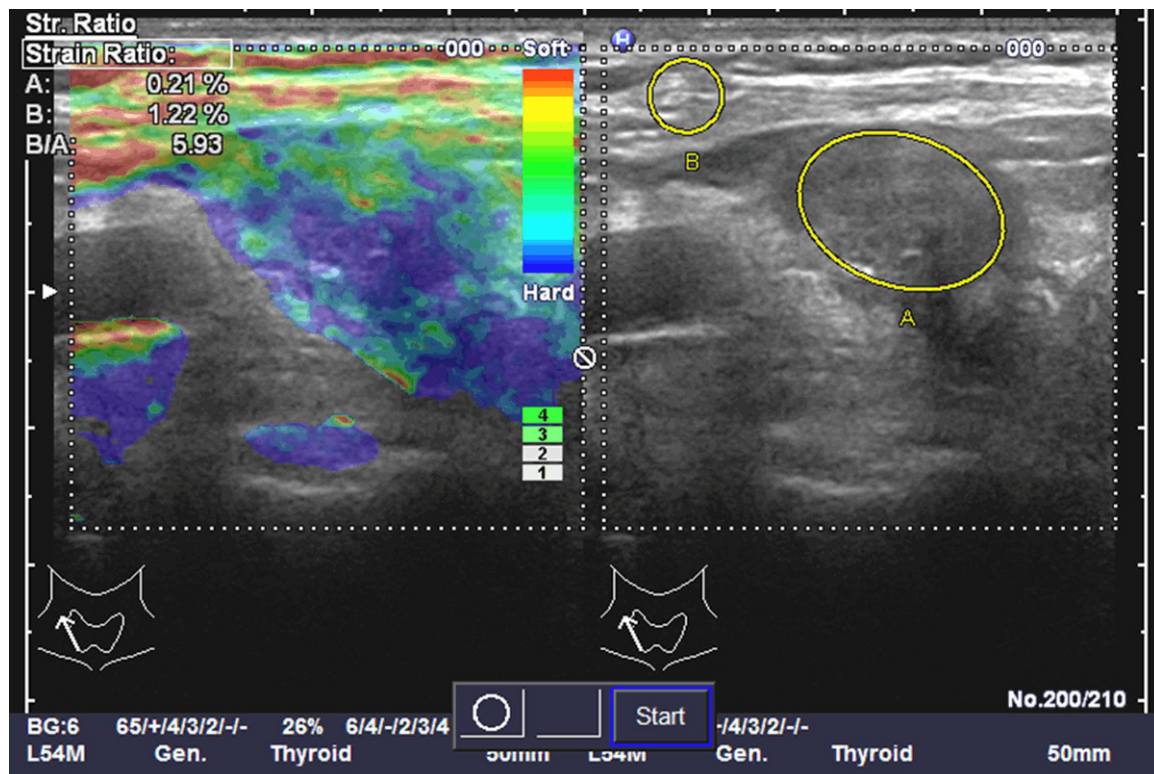
the surrounding tissue were examined carefully. On conventional US, the following features were evaluated for every nodule: lesion shape, border, number, echo, halo, calcification, flow classification, flow resistance index, and neck lymph node swelling, etc. Color Doppler ultrasound was carried out on all patients to evaluate the vascularity of the thyroid nodule. Four types of vascularity were identified. 0: no blood flow, I: little blood flow, 1~2 point blood flow, pine diameter <2 mm, II: centre blood flow, one main blood vessel, III: abundant blood flow, at least four blood vessels, interweave [8].

### Real-time elastosonography in elasticity imaging score

After conventional US, real-time elastosonography images were obtained by the same operator using the same transducer. With US probe, light compression was applied to the anterior neck above the examined lesion to fix the position of the thyroid gland and limit its lateral movement. US elastographic measurement was performed using the same real-time instrument and the same probe. The probe was placed on the neck with light pressure, and a box was highlighted by the operator that included the nodule to be evaluated. It was important that the level of pressure was maintained constantly throughout the examination, and the pressure indicators on the screen were readed as 2~4. The US elastogram was displayed over the B-mode image in a color scale that ranges from red, for components with greatest elastic strain (i.e. softest components), to blue for those nodes with no strain (i.e. hardest components). The US elastographic image was matched with an elasticity color scale and classified into four scores on the classes of tissue stiffness: **Table 1** [9].

### Real-time elastosonography in elasticity strain ratio

After obtaining the strain image, we used the SR software, which the US machine was



**Figure 1.** Measure the strain ratio of the thyroid nodule and sternocleidomastoid. A: the thyroid lesion, B: the sternocleidomastoid. The strain ratio of B/A as the strain index.

**Table 2.** Diagnostic performance of conventional ultrasound criteria in differentiating thyroid nodules

	US feature	PTC (n=12)	BN (n=38)	P	Sensitivity (%)	Specificity (%)
Shape	Irregular	9	8	0.0000	75	78.9
	Oval	3	30			
Margin	Poor	8	18	0.0215	66.7	52.6
	Well	4	20			
Hale	Presence	4	17	0.4215	33.3	55.2
	Absence	8	21			
Echo	Hypoecho	11	20	0.0000	91.6	47.3
	Nonhypoecho	1	18			
Calcification	Micro	7	1	0.0000	58.3	97.4
	None or coars	5	37			
Flow grade	Grade II~III	8	18	0.0172	66.7	52.6
	Grade 0~I	4	20			

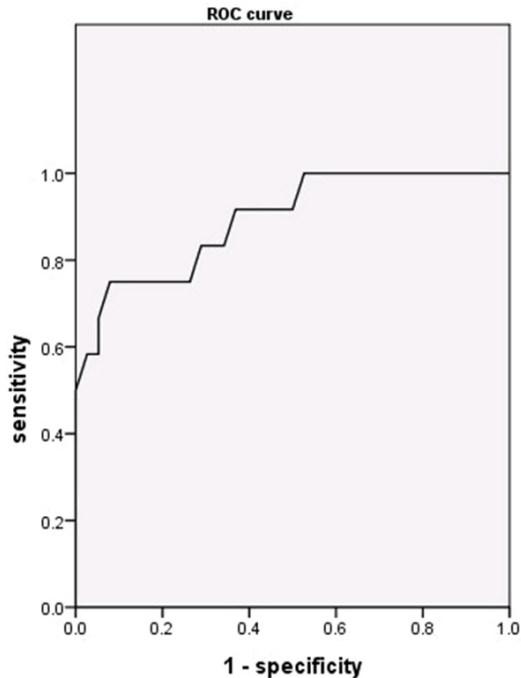
equipped with, to measure the SR of the thyroid nodule and sternocleidomastoid. We first contoured the target lesion as A, then selected the sternocleidomastoid as B, and the SR of B/A as the strain index was obtained, which reflected the lesion stiffness, (**Figure 1**).

The US images were acquired, reviewed, and interpreted by two ultrasonographers, who had

5 years of experience in thyroid US and 2 years of experience in US elastography and were blinded to the patients' final diagnosis.

#### Statistical analysis

The statistical analyses were carried out using SPSS version 16.0 (Chicago, IL, USA). Statistical analysis was performed for all variables with



**Figure 2.** ROC curve analysis of strain ratio measurement in differential diagnosis of benign and malignant nodules with HT.

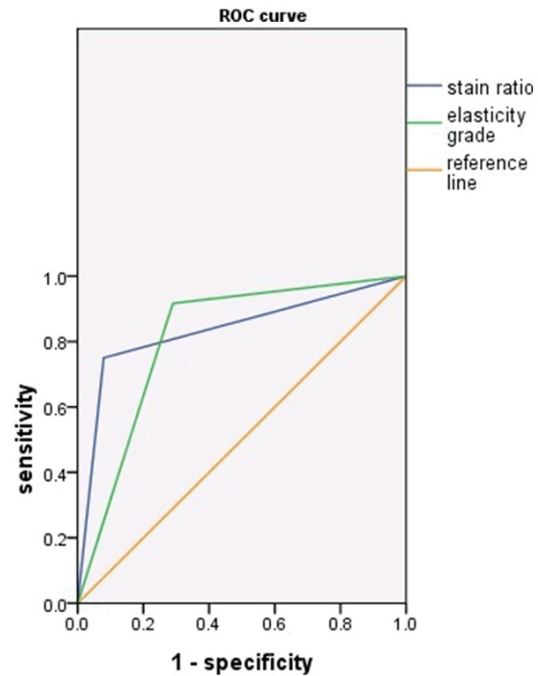
paired Student's t-test or t-test. Receiver operating characteristics (ROC) curve analysis was performed to evaluate the diagnostic accuracy of elastosonography with elastography score and SR in the diagnosis of malignancy. ROC curves were used to determine sensitivity, specificity, and also to extrapolate the optimum cut-off value for SR. Two-tailed  $P < 0.05$  was considered to be statistically significant.

## Results

Of the 50 nodules, 12 (24%) were malignant and 38 (76%) were benign. The result showed that papillary thyroid carcinoma (100%) and nodular goiter (47.3%) were the commonest malignant and benign types respectively.

### Conventional US

The diagnostic performances of the main features of conventional US in detecting malignancy were summarized in **Table 2**. The presence of microcalcifications (sensitivity shown as 58.3%, and specificity shown as 97.4%,  $P = 0.000$ ) was the most predictive US feature for malignancy and had the highest specificity. The highest sensitivity was found for hypoechoic



**Figure 3.** ROC curve analysis of elasticity score and strain ratio in differential diagnosis of benign and malignant nodules with HT.

nodules (91.6%), but specificity was very low (47.4%). Only the presence of a halo sign was not predictive of malignancy (sensitivity shown as 33.3% and specificity shown as 55.2%,  $P = 0.421$ ).

### Real-time elastosonography in elasticity imaging score

Of all 50 nodules, 28 had an elasticity score of 1-2, of which 27 benign and one malignant; 22 had an elasticity score of 3-4, of which 11 benign and 11 malignant. Elasticity scores of 1-2 were observed in the majority of benign nodules, while scores of 3-4 were in the majority of malignant nodules. The sensitivity, specificity and accuracy were 91.7%, 71.1% and 76.0% respectively.

### Real-time elastosonography in elasticity strain ratio

Comparing the same depth of thyroid tissue, the mean SR for malignant lesions was 7.83, and for the benign lesions it was 2.87. There were statistically significant differences between the SR of malignant and benign nodules ( $P < 0.05$ ).



The following below curve (**Figure 2**) demonstrates the ROC for SR measurement method in characterizing the nature of thyroid lesion; malignant or benign. The area under the curve (AUC) was 0.836 with 95% CI level ranging from 0.681-0.990. The maximal Youden Index was 0.67 while calculating the best cut-off point. The best cut-off point was 5.03. With the best cut-off point, the sensitivity, specificity and accuracy for SR index method was 75.0%, 92.1% and 84.0% respectively. The diagnostic accuracy of the SR was superior to that of elastographic score (**Figure 3**).

## Discussion

It is well known that benign and malignant nodules can coexist within diffuse HT [10]. Conforti et al. [11] reported 1.6 times increased cancer risk in nodules with HT according to the general population with nodules. Being entirely different in treatment and prognosis between HT and thyroid cancer, it is very important to clarify diagnosis before surgery. The FNA has proved to be an efficient tool for thyroid cancer diagnosis. Despite the advantages of FNA, it is an invasive procedure and subject to sampling and analysis uncertainties. Thus, more reliable criteria for determining which nodules should be aspirated and which should be followed up are needed [12].

US is a particularly useful tool in the detection and measurement of thyroid nodules as well as improving the quality of FNA sampling. In comparison with the previous literature [13], our study showed microcalcifications was the most predictive US feature for malignancy. Other features like poor margin halo and irregular shape were commoner within malignant lesions. These features, however, were not specific enough to reliably diagnose malignancy.

Malignant lesions are often associated with changes in the mechanical properties of tissue; therefore elastography has been used to differentiate cancers from benign lesions in prostate, breast, thyroid, and liver [14, 15]. Real-time elastosonography has great potential as an adjunctive tool for the diagnosis of thyroid cancer with HT. In a review of 92 patients with single thyroid nodule, Rago et al. [16] scored tissue stiffness on US elastography from one

(greatest elastic strain) to five (no strain). In 32 patients which conventional US failed to predictive of malignancy, an elasticity imaging score observed in six of seven (86%) malignant lesions. US elastography showed great potential as an adjunctive tool for the diagnosis of thyroid cancer. But it was reported that nodules with macrocalcifications were responsible for a high false positive rate on elastosonography [17]. Thus, we selected 36 patients who had solid nodules without coarse calcification for the analysis. Conventional US maintains a pivotal importance to define which nodules are suitable for the US elastographic characterization.

In the previous study of the application of SR for US elastography in diagnosis of benign and malignant thyroid nodule [18, 19], there was fewer reports on the precise cut-off point reported on the literature. Liu et al. [18] reported that cut-off point of 5.25 describe the best diagnostic performances with the sensitivity of 81.5% and specificity of 96.8%; the diagnostic accuracy of the SR was superior to that of elastographic score. In that study, SR of the lesion and thyroid parenchyma was measured. Since sonographic appearance of HT is very complex, it may be not accurate by measuring SR of the lesion and thyroid parenchyma. Therefore we measure SR of the lesion and sternocleidomastoid instead of thyroid parenchyma. Similarly, in our study we found 5.03 was the best cut-off point to characterize the nature of thyroid lesions with the sensitivity of 75.0%, specificity of 92.1% and accuracy of 84.0%. With SR measurement method, we significantly improved the diagnostic performances than conventional US method. Compared to the elastographic score (sensitivity of 91.7%, specificity of 71.1%, and accuracy of 76.0%), ROC curve analysis showed the diagnostic accuracy of the SR was superior to that of elastographic score. Since the diagnostic value of SR measurement and elastographic score in patients with HT has not been well documented, larger prospective studies are needed to confirm these results and establish the diagnostic accuracy of this new technique.

In conclusion, US elastography is a promising imaging technique that is useful in the differential diagnosis of thyroid nodules with HT. The

SR measurement is a more accurate way which can provide quantitative information. The best cut-off point for benign and malignant nodules in Hashimoto disease was 5.03.

## Acknowledgements

This study was supported by Science Award Foundation for The Excellent Youth Scientist of Shandong Province (Grant#: BS2013YY053) and Science and Technology Development Plan of Qingdao City, China (Grant#: KJZD-13-38-JCH).

## Disclosure of conflict of interest

None.

**Address correspondence to:** Dr. Xuejun Liu, Department of Radiology, Affiliated Hospital Of Qingdao University, 16 Jiangsu Road, Qingdao 266003, China. Tel: +86-53282911004; Fax: +86-532829-11841; E-mail: xuejunliu139@yeah.net

## References

- [1] Marcocci C, Vitti P, Cetani F, Catalano F, Concetti R and Pinchera A. Thyroid ultrasonography helps to identify patients with lymphocytic thyroiditis who are prone to develop hypothyroidism. *J Clin Endocrinol Metab* 1991; 72: 209-213.
- [2] Cooper DS, Doherty GM, Haugen BR, Kloos RT, Lee SL, Mandel SJ, Mazzaferri EL, McIver B, Pacini F, Schlumberger M, Sherman SI, Steward DL and Tuttle RM. Revised American Thyroid Association management guidelines for patients with thyroid nodules and differentiated thyroid cancer: the American Thyroid Association (ATA) guidelines taskforce on thyroid nodules and differentiated thyroid cancer. *Thyroid* 2009; 19: 1167-1214.
- [3] Kim KW, Park YJ, Kim EH, Park SY, Park do J, Ahn SH, Park do J, Jang HC and Cho BY. Elevated risk of papillary thyroid cancer in Korean patients with Hashimoto's thyroiditis. *Head Neck* 2011; 33: 691-695.
- [4] Kwak JY, Kim EK, Ko KH, Yang WI, Kim MJ, Son EJ, Oh KK and Kim KW. Primary thyroid lymphoma: role of ultrasound-guided needle biopsy. *J Ultrasound Med* 2007; 26: 1761-1765.
- [5] Larson SD, Jackson LN, Riall TS, Uchida T, Thomas RP, Qiu S and Evers BM. An increased incidence of well-differentiated thyroid cancer associated associated with Hashimoto's thyroiditis and the role of the PI3K/AKT pathway. *J Am Coll Surg* 2007; 204: 764-773
- [6] Lyshchik A, Higashi T, Asato R, Tanaka S, Ito J, Mai JJ, Pellot-Barakat C, Insana MF, Brill AB, Saga T, Hiraoka M and Togashi K. Thyroid gland tumor diagnosis at US elastography. *Radiology* 2005; 237: 202-211.
- [7] Gharib H, Papini E, Paschke R, Duick DS, Valcavi R, Hegedüs L, Vitti P; AACE/AME/ETA Task Force on Thyroid Nodules. American Association of Clinical Endocrinologists, Associazione Medici Endocrinologi, and European Thyroid Association Medical guidelines for clinical practice for the diagnosis and management of thyroid nodules: executive summary of recommendations. *Endocr Pract* 2010; 16: 468-75.
- [8] Adler DD, Carson PL, Rubin JM and Quinn-Reid D. Doppler ultrasound color flow imaging in the study of breast cancer: preliminary findings. *Ultrasound Med Biol* 1990; 16: 553-559.
- [9] Asteria C, Giovanardi A, Pizzocaro A, Cozzaglio L, Morabito A, Somalvico F and Zoppo A. US-elastography in the differential diagnosis of benign and malignant thyroid nodules. *Thyroid* 2008; 18: 523-531.
- [10] Takashima S, Matsuzuka F, Nagareda T, Tomiyama N and Kozuka T. Thyroid nodules associated with Hashimoto's thyroiditis: assessment with US. *Radiology* 1992; 185: 125-130.
- [11] Consorti F, Loponte M, Milazzo F, Potasso L and Antonaci A. Risk of malignancy from thyroid nodular disease as an element of clinical management of patients with Hashimoto's thyroiditis. *Eur Surg Res* 2010; 45: 333-337.
- [12] Ross DS. Nonpalpable thyroid nodules: managing an epidemic. *J Clin Endocrinol Metab* 2002; 87: 1938-1940.
- [13] Liu B, Liang J, Zheng Y, Xie X, Huang G, Zhou L, Wang W and Lu M. Two-dimensional shear wave elastography as promising diagnostic tool for predicting malignant thyroid nodules: a prospective single-centre experience. *Eur Radiol* 2015; 25: 624-34.
- [14] König K, Scheipers U, Pesavento A, Lorenz A, Ermert H, Senge T. Initial experiences with real-time elastography guided biopsies of the prostate. *Int J Urol* 2005; 174: 115-117.
- [15] Lee SH, Moon WK, Cho N, Chang JM, Moon HG, Han W, Noh DY, Lee JC, Kim HC, Lee KB and Park IA. Shear-wave elastographic features of breast cancers: comparison with mechanical elasticity and histopathologic characteristics. *Invest Radiol* 2014; 49: 147-155.
- [16] Rago T, Santini F, Scutari M, Pinchera A and Vitti P. Elastography: new developments in ultrasound for predicting malignancy in thyroid nodules. *J Clin Endocrinol Metab* 2007; 92: 2917-2922.
- [17] Sebag F, Vaillant-Lombard J, Berbis J, Griset V, Henry JF, Petit P and Oliver C. Shear wave elas-

- tography: a new ultrasound imaging mode for the differential diagnosis of benign and malignant thyroid nodules. *J Clin Endocrinol Metab* 2010; 95: 5281-5288.
- [18] Liu F and Xiao Y. The application of strain ratio for ultrasonic elastography in diagnosis of benign and malignant thyroid nodule. *Chin J Med Ultrasound (Electronic Edition)* 2010; 7: 671-678.
- [19] Koizumi Y, Hirooka M, Kisaka Y, Konishi I, Abe M, Murakami H, Matsuura B, Hiasa Y and Onji M. Liver fibrosis in patients with chronic hepatitis C: noninvasive diagnosis by means of real-time tissue elastography-establishment of the method for measurement. *Radiology* 2011; 258: 610-617.