

Original Article

Is dabigatran efficacy enough to prevent stroke in atrial fibrillation patient with high CHADS₂ score during peri-procedural catheter radiofrequency ablation? A case report with literature review

Xiang-Min Shi, Fu-Kun Chen, Zhuo Liang, Jian Li, Kun Lin, Jian-Ping Guo, Zhao-Liang Shan

Department of Cardiology, The General Hospital of PLA, Beijing 100853, China

Received February 6, 2015; Accepted April 5, 2015; Epub April 15, 2015; Published April 30, 2015

Abstract: Atrial fibrillation (AF) is a major cause of thromboembolic (TE) events including stroke and transient ischemic attacks, catheter radiofrequency ablation (CA) has been demonstrated to effectively eliminate AF in majority of patients. During the peri-procedural CA of AF, dabigatran, a reversible direct thrombin inhibitor, has been proved as safe and efficacy as warfarin in the prevention of thromboembolic complication. However, for patients with CHADS₂ score ≥ 3 , sometimes dabigatran may not be an ideal substitute of warfarin. The current study presents delayed stroke occurred in a middle-aged AF patient with high CHADS₂ score who had undergone successful CA of AF being on dabigatran, trans esophageal echocardiogram (TEE) detected a clot in the left atrium appendage (LAA) and magnetic resonance image (MRI) indicated stroke of left basal ganglia, therefore anticoagulant was switched to warfarin with well controlled international normalization ratio (INR) ranging from 2.0-3.0 and the patient eventually recovered without any TE events during the subsequent follow-up.

Keywords: Atrial fibrillation, thromboembolic events, catheter radiofrequency ablation, dabigatran, left atrium appendage

Introduction

Atrial fibrillation (AF) is one of the most common arrhythmia in clinical practice, which could result in stroke and tachycardia induced heart failure [1], the risk of ischemic stroke of AF patient is 5-7 times greater than patient with sinus rhythm [2]. Warfarin, a traditional vitamin K antagonist, has been introduced to prevent ischemic stroke in AF patients for many decades [3], however, its interaction with many drugs and foods, as well as unpredictable anticoagulation effect largely limits its clinical application [4]. In recent 10 years, based on results of clinical trials, such as RE-LY [5], ROCKET [6], some novel oral anticoagulation drugs (NOACs) have been approved in the treatment of stroke prevention in AF patients in regarding to same safety and efficacy compared with warfarin. Dabigatran [7, 8], a reversible direct thrombin inhibitor, could exert its predictable anticoagulation effect without rou-

tinely monitoring blood; the advantage of simplicity facilitates its increased administration in clinic. Compared with anti-arrhythmia drugs (AADs), catheter radiofrequency ablation of AF has shown its superiority in long-term sinus rhythm maintenance and became the established methods for symptomatic paroxysmal AF [9]. Many studies and meta-analysis have confirmed the safety and efficacy of dabigatran for peri-procedural anticoagulation in catheter radiofrequency ablation of AF [10-12]. Whether it could effectively prevent ischemic stroke in AF patients at increased risk needs to be further investigated, presented herein is a 42-year-old male patient, who suffered from paroxysmal AF refractory to many AADs for two years, meanwhile, he was diagnosed as type 2 diabetes mellitus, hypertension and cardiac failure due to alcoholic cardiomyopathy which resulted in 3 of CHADS₂ score, no clot was detected by trans esophageal echocardiogram (TEE) before ablation, and 3 hours after procedure dabigatran

was initiated with the dose of 150 mg twice daily. However, he suddenly developed ischemic stroke 40 days after procedure which was confirmed by magnetic resonance scan, meanwhile, TEE revealed thrombus in the junction of left inferior pulmonary vein and left atrial appendage, subsequently dabigatran was replaced by warfarin and therapeutic INR was controlled between 2.0-3.0, the patient totally recovered in the following days.

Case report

A 42-year-old male patient, who previously underwent catheter radiofrequency ablation of AF, was re-hospitalized with chief complaint of sudden onset and gradual deteriorating paralysis with difficulty in speaking in Dec 2014. 40 days ago, he was firstly admitted in our hospital for the treatment of paroxysmal AF which frequently occurred in the past 2 years, in the past history he has been diagnosed as type 2 diabetes mellitus 4 years, primary hypertension class II 3 years and cardiac dysfunction (NYHA II) due to alcoholic cardiomyopathy 5 years respectively. ACEI, β -blocker, spironolactone, vasodilator and metformin were consistently administered before the first hospitalization. Holter monitoring revealed frequent episode of AF triggered by premature atrial contraction with rapid ventricular response which resulted in palpitation and shortness of breath, because PAF significantly impacted quality of life and could not be controlled by amiodarone and β -blocker, catheter ablation of PAF was recommended and informed consent was obtained, after ruling out the presence of thrombus by trans esophageal echocardiogram (TEE), he underwent circumferential pulmonary veins electrical isolation (CPVI) under the guidance of CARTO system in a fasting and conscious-sedated state.

Intracardiac electrograms were recorded using an electrophysiology system (Prucka CardioLabTM General Electric Health Care System Inc, USA). One decapolar mapping catheter (Biosense Webster, Diamond Bar, CA) was positioned in the coronary sinus (CS) through the right jugular vein access, using the standard Brockenbrough technique [13], atrial transseptal puncture was performed under fluoroscopic guidance and two L1-type Swartz sheaths (St Jude Medical, Minneapolis, MN) were transsep-

tally introduced into LA via right femoral vein. Intravenous unfractionated heparin 5000 U was administered immediately after atrial transseptal puncture and followed 1000 U/h to maintain an activated clotting time (ACT) of 300-350 s, the ACT level was monitored every 30 min. In addition, heparinized saline solution was continuously infused through the transseptal sheath (3 mL/min) to avoid formation of thrombi or air emboli. Selective PV venography was performed to identify all PV ostia. One decapolar circular mapping catheter (Lasso, Biosense Webster) was placed at the ostium of each PV to record PV potentials. A 3.5 mm saline-irrigated catheter (Navi-star, Thermocool, Biosense Webster) was transseptally advanced into LA via Swartz sheath, LA geometry was reconstructed and each PV ostium was tagged on it. Pulmonary vein antral isolation was performed 5 to 10 mm outside of the PV ostia. Ipsilateral pair of left and right PVs was isolated in one circumferential lesion. RF current was delivered point by point at a target temperature 43°C, maximum power of 35 W (Stocker generator, Biosense Webster Inc, Diamond Bar, CA, USA), and an infusion rate of 17 mL/min. The end point of CPVI was electrical isolation of PV potentials, which was confirmed by Lasso catheter mapping during sinus rhythm and isoproterenol infusion after 30 min. Dabigatran was initiated immediately 3 hours after the procedure with the dosage of 150 mg twice daily. Holter monitoring revealed no recurrence of AF during the follow-up and he continued all the medicines.

40 days after ablation, without specific precipitating factors he suddenly developed symptom of right limb hemiplegia and numbness with right mouth oblique, as well as unclear articulation. On admission, physical examination revealed positive right Babinski sign and muscle weakness in right upper as well as lower limbs of muscle force grade 3, the corners of the mouth to the right deviation with right nasolabial fold could be found. Laboratory test, including cardiac-specific enzymes, serum electrolytes, INR, D-dimer, were within normal limits except moderate increased aPTT (57.6 s) and PT (176.6 s), Pro-BNP (560 pg/ml) as well as HbA1c (7.5%). Surface 12-lead electrocardiogram and holter monitoring indicated sinus rhythm with occasional atrial and ventricular premature contraction without AF or AFL.

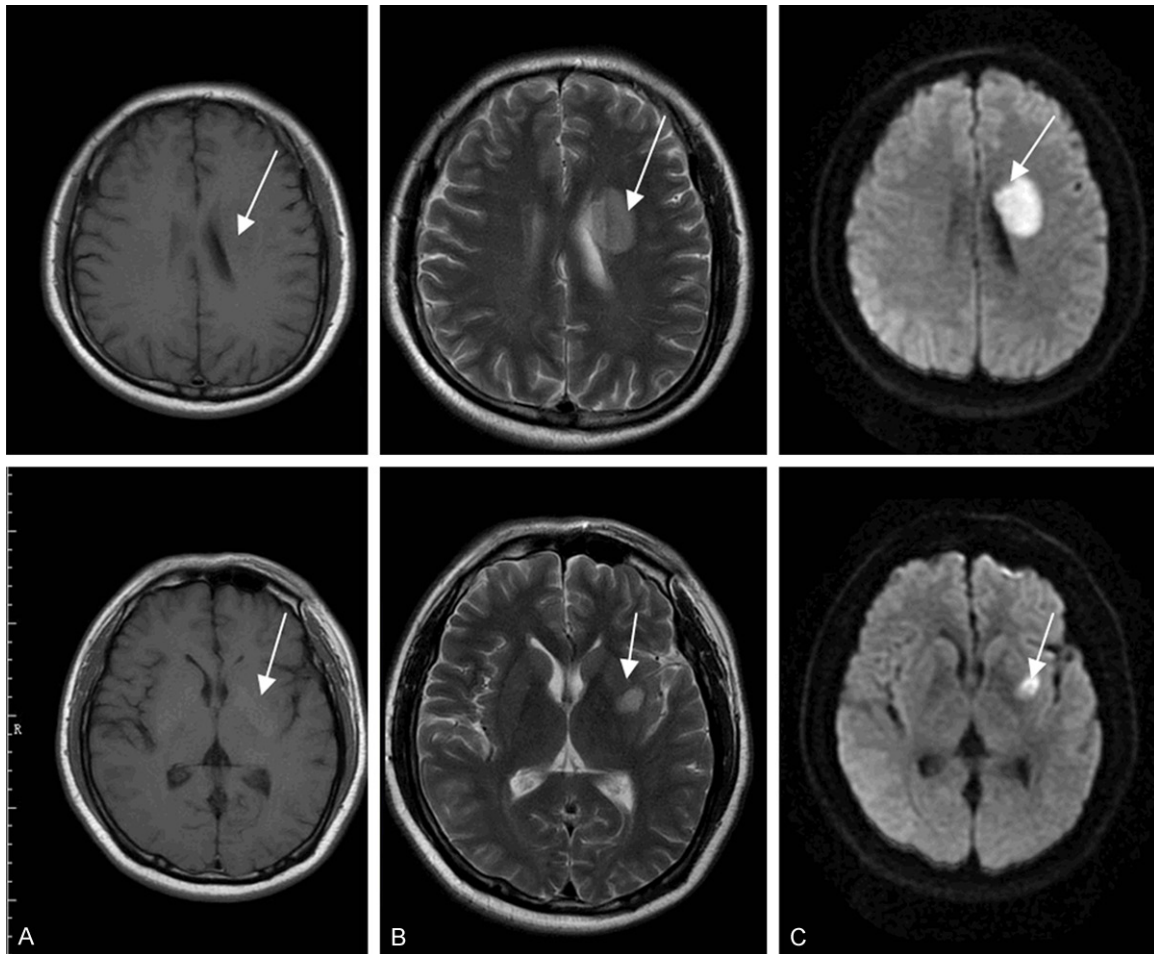


Figure 1. MRI slice scan showed damage (arrow indicated) in the area of left basal ganglia, A-C represented T1, T2 and diffused weighted image.

Trans-thoracic echocardiography (TTE) revealed enlargement of left ventricle (56 mm) with normal left ventricular ejection fraction (LVEF 60%) and left atrium (38 mm) in the parasternal echo view, a thrombus-like mass (5×10 mm) located in the LAA was detected by TEE.

After hospitalization, MRI including T1, T2 and diffuse weighted image, indicated acute ischemic stroke of left basal ganglia (**Figure 1**), subsequently dabigatran was discontinued to avoid hemorrhagic infarction and volume expansion therapy with dextran-40 as well as butylphthalide; edaravone for neurological recovery were initiated, blood pressure was strictly maintained at 150-170/80-95 mmHg with the purpose of increasing cerebral perfusion. One week later, warfarin was restored with the dosage of 3 mg/day and therapeutic range of INR was maintained at 2.0-3.0. After intensive treatment in combination with rehabilitation

therapy, the symptom of muscle weakness, sensation abnormality and difficulty in speaking significantly improved and fully resolved within 2 weeks. In the follow-up after discharge, he never suffered stroke or transient ischemic attack again in the presence of continuous warfarin administration.

Discussion

Catheter ablation (CA) for atrial fibrillation (AF) is an effective rhythm-control method for selected patients [14], Fiorenzo study [15] confirmed patients with AF undergoing transcatheter ablation have a low incidence of thromboembolic (TE) event as compared with general AF population. however, this procedure potentially increase the risk of TE due to ablation in the systemic circulation and conversion of AF to sinus rhythm [16], Jelena [17] found CA of AF could increase the levels of von Willebrand fac-

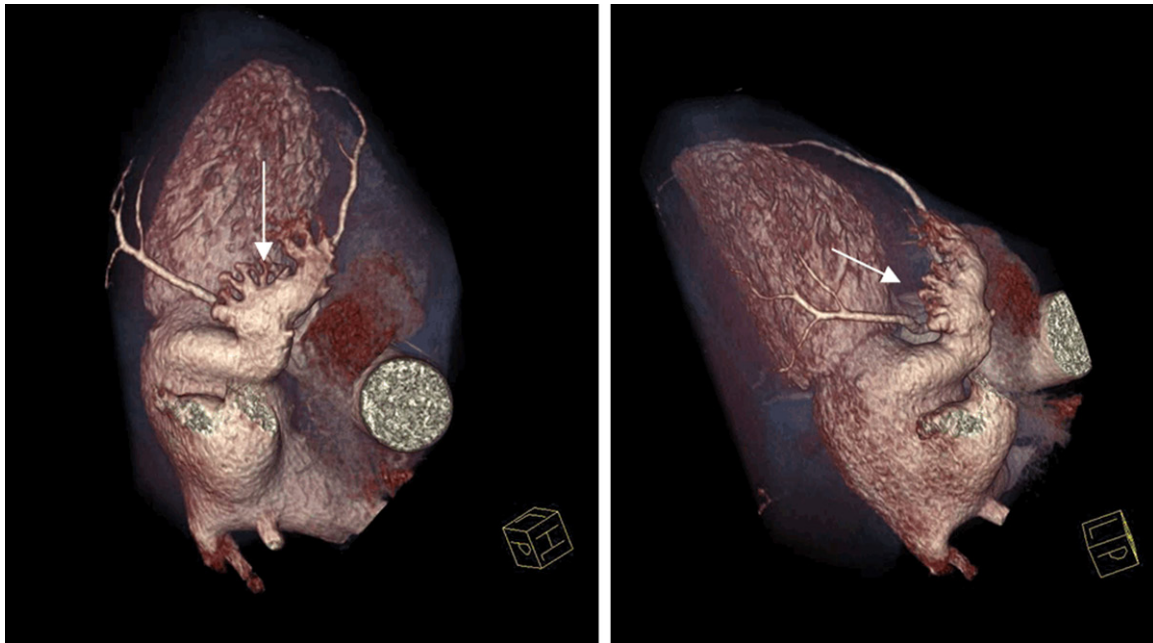


Figure 2. Reconstructed computer tomography showed cauliflower LAA morphology (arrow indicated).

tor and interleukin-6, leading to risk of TE event. Peri-procedural anticoagulation is particularly important to prevent TE complication. Previously warfarin was the only oral anticoagulant available for TE prevention, Pre-ablation uninterrupted warfarin therapy has been adopted as standard method by many electrophysiological centers because of low TE complication [18, 19], however, the time in therapeutic range (TTR) is not satisfactory in as many as 50% or more patients during the peri-procedure period, which consequently increase the risk of bleeding or stroke [20]. Based on result of RE-LY study, novel oral direct thrombin inhibitor dabigatran was approved for prevention of stroke in non-valvular AF, many studies have demonstrated that this drug is as safe and effective as warfarin in stroke prevention [21, 22], and increasing number of patients on dabigatran is proceeding to the stage of CA of AF, several published studies have demonstrated same safety and efficacy of dabigatran as warfarin, however other observational studies indicated controversial results that dabigatran could increase in both bleeding and TE complication [23, 24].

It was reported the incidence of TE was influenced by patient's characteristics, the value of aPTT during the procedure, the type of ablation catheter, ablation time, the size of left atrium,

left atrium appendage (LAA) flow and the delay to the restart of dabigatran [25, 26]. According to RE-LY trial, a dabigatran dose of 300 mg/day was superior to warfarin in regarding to stroke prevention in non-valvular AF, and 220 mg/day was not inferior to warfarin, meanwhile, the use of dabigatran for CA of AF could shorten the duration of hospital stay [27]. One advantage of dabigatran use is not necessary to routine monitor coagulation assays, however, it was reported that high aPTT value correlated with bleeding events [28]. The dose of dabigatran may need to be reduced in patients with advance age, smaller body weight and high aPTT value. Meta-analysis demonstrated one third of all strokes or TIAs were associated with suspension of dabigatran for >24 h before procedure, 50% of cases was related to a later timing (>12 h) for restarting the drug post procedure [29, 30]. In our study the patient was not treated with any anticoagulation regimens before procedure in the case of paroxysmal AF with no clot or strong spontaneous echo contrast detected in LAA by TEE, the timing of first dabigatran administration was 3 hours after the procedure with the dose of 300 mg daily and aPTT was measured as 65 s in the morning (trough time) 3 days after ablation. he was the one of high risk of stroke based on CHADS₂ score as 3 owing to co-morbidity of diabetes mellitus, hypertension and cardiac dysfunction,

the dose of 300 mg/day was selected due to normal eGFR (80 ml/min), relative young age and increased BMI (28 kg/m²) even simultaneous administration of potent permeability glycoprotein inhibitor amiodarone 200 mg daily, however, he suddenly developed stroke in the setting of continuous dabigatran administration, the characteristic of stroke was sudden onset and rapid deterioration in combination of infarction area perfused by middle cerebral artery, which supported the underlying mechanism was embolism of cardiac origin in the absence of carotid artery plaque, subsequent TEE examination confirmed a clot in the LAA.

It was reported that TE rate in patients treated with dabigatran during the peri-procedural period was very low (0.55-0.9%) [31], meanwhile relative lower but not significant difference in the arm of warfarin (0.17%) [32]. What is the real etiology responsible for stroke in the presence of dabigatran administration with maximum dose for this patient? Did he suffer from clinical and pharmacological resistance? dTT and ECT are believed to be golden index to monitor the anticoagulation effect of dabigatran because these assays focus predominantly on antithrombin activity [33], aPTT was recommended as an alternative index due to its convenience in clinic [34, 35], although it is commonly believed that blood test was not necessary for dabigatran. Compared with warfarin, there is no definite range of aPTT comparable to INR for anticoagulation management, although the risk of major bleeding increased as the value of aPTT greater than two times of normal upper limits, there are no lower limits to identify the patient at the risk of stroke. The efficacy of APTT in the assessment of TE risk for AF patients treated with dabigatran needs to be further investigated. Dabigatran is rapidly absorbed and anticoagulation occurs rapidly within 2-3 hours, the mean terminal half-life is 8 hours after a single dose and ranges from 12-14 hours after multiple doses [36, 37], in terms of periprocedural anticoagulation protocol, dabigatran was usually administrated before the procedure and discontinued 12-24 h before ablation, it was reported that dabigatran should be discontinued 12 h before ablation for patients at high risk of TE events [27], in our study, the patient's CHADS₂ score was 3, and no use of dabigatran before ablation could be attributable to development of stroke. However,

according to recommendation of many studies, discontinuation of dabigatran >12 h before ablation may exert little anticoagulation effects at the beginning of procedure, theoretically which was not great different with no drug administration in the absence of thrombus of LAA. Based on the results of meta-analysis, most of TE complications occurred a few days after procedure, however, the patient suffered from focal neurologic deficit 40 days later, what is the exact mechanism responsible for the delayed stroke? One possible explanation is that formation of thrombus in the LAA appeared in the early stage and embolism occurred several weeks later. Another reason could be insufficient anticoagulation of dabigatran during the follow-up in the absence of reliable coagulation monitoring, in laboratory test, PT-based factor assays, specifically factors II, V and X demonstrate significantly less dabigatran effect than aPTT-based factor measurement, therefore, aPTT is superior than PT in the assessment of coagulation effect of dabigatran. However, the result of aPTT sometimes is not reliable, which could lead to inappropriate interpretation and mismanagement [38]. Meanwhile, laboratory test of this patient including protein C, S, plasminogen and antithrombin III, ruled out other procoagulation states in the presence of normal range of above mentioned index. Another rare possible etiology of stroke could be dabigatran resistance which has been found in some selected patients [39] and the mechanism remains unclear.

CHADS₂ score is not only for AF patients, but also suitable to patients with sinus rhythm for TE risk stratification, which suggested patients need long-term anticoagulation even in the setting of sinus rhythm maintenance after procedure. Tina [40] reported that the prevalence of AF increases with increasing CHADS₂ or CHA₂DS₂-VASc score, in high scores, TE complication occurred irrespective of the presence of AF and anticoagulant therapy may be initiated irrespective of documented AF. Eduardo [41] reported very low risk of TE events in patients undergoing successful CA of AF with a CHADS₂ score ≤3 after oral anticoagulation, these clinical studies highly emphasized the relationship between stroke and CHADS₂ or CHA₂DS₂-VASc score. There have been several studies showing that maintenance of sinus rhythm is associated with low incidence of TE events after cath-

eter ablation [42], however, it could be not the case for patients with high CHADS₂ score.

Many studies [43-45] demonstrated the relationship between LAA morphology and stroke, based on the results of MRI and computed tomography (CT), LAA morphology was categorized as cactus, chicken wing, wind sock and cauliflower. In our study, the reconstructed CT revealed LAA morphology as type of cauliflower (**Figure 2**), Di Biase [46] found Patients with cauliflower LAA morphology were more likely to have an embolic event even after controlling for comorbidities and CHADS₂ score, these results suggested intensive anticoagulation protocol should be taken for patients with low CHADS₂ score in the presence of cauliflower LAA morphology.

Because the patient in our study suffered from stroke in the presence of dabigatran administration, the anticoagulation drug was transferred to warfarin with dose of 3 mg/day in regarding to suspected insufficient effect of dabigatran. Compared with dabigatran, there are some defects of warfarin, including many drugs and foods interaction, frequent laboratory monitoring and dose adjustment, as well as individualized therapy due to gene difference in relation with CYP4502CP and VKORC1 [47], however prevention of stroke could be guaranteed in well-controlled patients with INR of 2.0-3.0. Meta-analysis demonstrated no significant difference in incidence of TE event between dabigatran and warfarin for patients receiving CA of AF; however, there was a trend of low rate of stroke in warfarin group. On the other hand, clinical trials have confirmed dabigatran could not be applied to patients with valve-AF [48]; warfarin still plays a very important role in prevention of stroke for AF patients. In our study, the patient with high CHA₂DS₂ score may not well respond to dabigatran due to complicated mechanism, under this circumstance, warfarin is a well reliable alternative for long-term prevention of stroke; in the subsequent follow-up he never suffered TE events again.

Disclosure of conflict of interest

None.

Address correspondence to: Dr. Zhao-Liang Shan, Department of Cardiology, the General Hospital of

PLA, 28 Fu Xing Road, Beijing 100853, China. Tel: 8613910563704; E-mail: shanzl301@sina.com

References

- [1] European Heart Rhythm Association; European Association for Cardio-Thoracic Surgery, Camm AJ, Kirchhof P, Lip GY, Schotten U, Savelieva I, Ernst S, Van Gelder IC, Al-Attar N, Hindricks G, Prendergast B, Heidbuchel H, Alfieri O, Angelini A, Atar D, Colonna P, De Caterina R, De Sutter J, Goette A, Gorenek B, Heldal M, Hohloser SH, Kolh P, Le Heuzey JY, Ponikowski P, Rutten FH; ESC Committee for Practice Guidelines. Guidelines for the management of atrial fibrillation: the Task Force for the Management of Atrial Fibrillation of the European Society of Cardiology (ESC). *Europace* 2010; 12: 1360-420.
- [2] Singer DE, Albers GW, Dalen JE, Fang MC, Go AS, Halperin JL, Lip GY, Manning WJ; American College of Chest Physicians. Antithrombotic therapy in atrial fibrillation: American College of Chest Physicians Evidence-Based Clinical Practice Guidelines (8th Edition). *Chest* 2008; 133: 546S-92S.
- [3] Reynolds MW, Fahrbach K, Hauch O, Wygant G, Estok R, Cella C, Nalysnyk L. Warfarin anticoagulation and outcomes in patients with atrial fibrillation: a systematic review and metaanalysis. *Chest* 2004; 126: 1938-1945.
- [4] Teklay G, Shiferaw N, Legesse B, Bekele ML. Drug-drug interactions and risk of bleeding among inpatients on warfarin therapy: a prospective observational study. *Thromb J* 2014; 17: 12-20.
- [5] Camm AJ. The RE-LY study: Randomized Evaluation of Long-term anticoagulant therapy: dabigatran vs warfarin. *Eur Heart J* 2009; 30: 2554-2555.
- [6] ROCKET AF Study Investigators. Rivaroxaban-once daily, oral, direct factor Xa inhibition compared with vitamin K antagonism for prevention of stroke and Embolism Trial in Atrial Fibrillation: rationale and design of the ROCKET AF study. *Am Heart J* 2010; 159: 340-347.
- [7] Wallentin L, Yusuf S, Ezekowitz MD, Alings M, Flather M, Franzosi MG, Pais P, Dans A, Eikelboom J, Oldgren J, Pogue J, Reilly PA, Yang S, Connolly SJ; RE-LY investigators. Efficacy and safety of dabigatran compared with warfarin at different levels of international normalized ratio control for stroke prevention in atrial fibrillation: an analysis of the RE-LY trial. *Lancet* 2010; 376: 975-983.
- [8] Connolly SJ, Ezekowitz MD, Yusuf S, Eikelboom J, Oldgren J, Parekh A, Pogue J, Reilly PA, Themeles E, Varrone J, Wang S, Alings M,

- Xavier D, Zhu J, Diaz R, Lewis BS, Darius H, Diener HC, Joyner CD, Wallentin L; RE-LY Steering Committee and Investigators. Dabigatran versus warfarin in patients with atrial fibrillation. *N Engl J Med* 2009; 361: 1139-1151.
- [9] Natale A, Raviele A, Arentz T, Calkins H, Chen SA, Hai"ssaguerre M, Hindricks G, Ho Y, Kuck KH, Marchlinski F, Napolitano C, Packer D, Pappone C, Prystowsky EN, Schilling R, Shah D, Themistoclakis S, Verma A. Venice Chart international consensus document on atrial fibrillation ablation. *J Cardiovasc Electrophysiol* 2007; 18: 560-580.
- [10] Bin Abdulhak AA, Khan AR, Tleyjeh IM, Spertus JA, Sanders SU, Steigerwalt KE, Garbati MA, Bahmaid RA, Wimmer AP. Safety and efficacy of interrupted dabigatran for peri-procedural anticoagulation in catheter ablation of atrial fibrillation: a systematic review and meta-analysis. *Europace* 2013; 15: 1412-1420.
- [11] Providência R, Albenque JP, Combes S, Bouzeman A, Casteigt B, Combes N, Narayanan K, Marijon E, Boveda S. Safety and efficacy of dabigatran versus warfarin in patients undergoing catheter ablation of atrial fibrillation: a systemic review and meta-analysis. *Heart* 2014; 100: 324-335.
- [12] Lakkireddy D, Reddy YM, Di Biase L. Feasibility and safety of dabigatran versus warfarin for periprocedural anticoagulation in patients undergoing radiofrequency ablation for atrial fibrillation: results from a multicenter prospective registry. *J Am Coll Cardiol* 2012; 59: 1168-1174.
- [13] De Ponti R, Cappato R, Curnis A, Della Bella P, Padeletti L, Raviele A, Santini M, Salerno-Uriarte JA. Transseptal catheterization in the electrophysiology laboratory: data from a multicenter survey spanning 12 years. *J Am Coll Cardiol* 2006; 47: 1037-1042.
- [14] Kearney K, Stephenson R, Phan K, Chan WY, Huang MY, Yan TD. A systematic review of surgical ablation versus catheter ablation for atrial fibrillation. *Ann Cardiothorac Surg* 2014; 3: 15-29.
- [15] Gaita F, Sardi D, Battaglia A, Gallo C, Toso E, Michielon A, Caponi D, Garberoglio L, Castagno D, Scaglione M. Incidence of cerebral thromboembolic events during long-term follow-up in patients treated with transcatheter ablation for atrial fibrillation. *Europace* 2014; 16: 980-986.
- [16] Knight BP. Anticoagulation for atrial fibrillation ablation: what is the optimal strategy? *J Am Coll Cardiol* 2012; 59: 1175-1177.
- [17] Jelena K, Borislav D, Andrew D. Effects of radiofrequency catheter ablation of atrial fibrillation on soluble P-selectin, von Willebrand factor and IL-6 in the peripheral and cardiac circulation. *PLoS One* 2014; 9: e111760.
- [18] Hakalahti A, Uusimaa P, Ylitalo K, Raatikainen MJ. Catheter ablation of atrial fibrillation in patients with therapeutic oral anticoagulation treatment. *Europace* 2011; 13: 640-645.
- [19] Santangeli P, Di Biase L, Sanchez JE, Horton R, Natale A. Atrial fibrillation ablation without interruption of anticoagulation. *Cardiol Res Pract* 2011; 2011: 837-841.
- [20] Connolly SJ, Pogue J, Eikelboom J, Flaker G, Commerford P, Franzosi MG, Healey JS, Yusuf S; ACTIVE W Investigators. Benefit of oral anticoagulant over antiplatelet therapy in atrial fibrillation depends on the quality of international normalized ratio control achieved by centers and countries as measured by time in therapeutic range. *Circulation* 2008; 118: 2029-2037.
- [21] Wallentin L, Yusuf S, Ezekowitz MD, Alings M, Flather M, Franzosi MG, Pais P, Dans A, Eikelboom J, Oldgren J, Pogue J, Reilly PA, Yang S, Connolly SJ; RE-LY investigators. Efficacy and safety of dabigatran compared with warfarin at different levels of international normalized ratio control for stroke prevention in atrial fibrillation: an analysis of the RE-LY trial. *Lancet* 2010; 376: 975-983.
- [22] Connolly SJ, Ezekowitz MD, Yusuf S, Eikelboom J, Oldgren J, Parekh A, Pogue J, Reilly PA, Themeles E, Varrone J, Wang S, Alings M, Xavier D, Zhu J, Diaz R, Lewis BS, Darius H, Diener HC, Joyner CD, Wallentin L; RE-LY Steering Committee and Investigators. Dabigatran versus warfarin in patients with atrial fibrillation. *N Engl J Med* 2009; 361: 1139-1151.
- [23] Bassiouny M, Saliba W, Rickard J, Shao M, Sey A, Diab M, Martin DO, Hussein A, Khoury M, Abi-Saleh B, Alam S, Sengupta J, Borek PP, Baranowski B, Niebauer M, Callahan T, Varma N, Chung M, Tchou PJ, Kanj M, Dresing T, Lindsay BD, Wazni O. Use of dabigatran for peri-procedural anticoagulation in patients undergoing catheter ablation for atrial fibrillation. *Circ Arrhythm Electrophysiol* 2013; 6: 460-466.
- [24] Kim JS, She F, Jongnarangsin K, Chugh A, Latchamsetty R, Ghanbari H, Crawford T, Suwanagool A, Sinno M, Carrigan T, Kennedy R, Saint-Phard W, Yokokawa M, Good E, Bogun F, Pelosi F Jr, Morady F, Oral H. Dabigatran vs warfarin for radiofrequency catheter ablation of atrial fibrillation. *Heart Rhythm* 2013; 10: 483-489.
- [25] Scherr D, Sharma K, Dalal D. Incidence and predictors of periprocedural cerebrovascular accident in patients undergoing catheter ablation of atrial fibrillation. *J Cardiovasc Electrophysiol* 2009; 20: 1357-1363.

- [26] Abhishek F, Heist EK, Barrett C, Danik S, Blendea D, Correnti C, Khan Z, Ruskin JN, Mansour M. Effectiveness of a strategy to reduce major vascular complications from catheter ablation of atrial fibrillation. *J Interv Cardiac Electrophysiol* 2011; 30: 211-215.
- [27] Imamura K, Yoshida A, Takei A, Fukuzawa K, Kiuchi K, Takami K, Takami M, Itoh M, Fujiwara R, Suzuki A, Nakanishi T, Yamashita S, Matsumoto A, Hirata K. Dabigatran in the periprocedural period for radiofrequency ablation of atrial fibrillation: efficacy, safety, and impact on duration of hospital stay. *J Interv Card Electrophysiol* 2013; 37: 223-231.
- [28] Suzuki S, Otsuka T, Sagara K, Matsuno S, Funada R, Uejima T, Oikawa Y, Yajima J, Koike A, Nagashima K, Kirigaya H, Sawada H, Aizawa T, Yamashita T. Dabigatran in clinical practice for atrial fibrillation with special reference to activated partial thromboplastin time. *Circ J* 2012; 76: 755-757.
- [29] Haines DE, Mead-Salley M, Salazar M, Marchlinski FE, Zado E, Calkins H, Yarmohammadi H, Nademanee K, Amnueypol M, Skanes AC, Saklani P. Dabigatran versus warfarin anticoagulation before and after catheter ablation for the treatment of atrial fibrillation. *J Interv Card Electrophysiol* 2013; 37: 233-239.
- [30] Rowley CP, Bradford NS, Bernard ML. Complications of atrial fibrillation ablation in patients anticoagulated with dabigatran compared to warfarin. *Heart Rhythm* 2012; 9 Suppl 1: S201.
- [31] Piccini JP, Sinner MF, Greiner MA, Hammill BG, Fontes JD, Daubert JP, Ellinor PT, Hernandez AF, Walkey AJ, Heckbert SR, Benjamin EJ, Curtis LH. Outcomes of Medicare beneficiaries undergoing catheter ablation for atrial fibrillation. *Circulation* 2012; 126: 2200-2207.
- [32] Hussein AA, Martin DO, Saliba W, Patel D, Karim S, Batal O, Banna M, Williams-Andrews M, Sherman M, Kanj M, Bhargava M, Dresing T, Callahan T, Tchou P, Di Biase L, Beheiry S, Lindsay B, Natale A, Wazni O. Radiofrequency ablation of atrial fibrillation under therapeutic international normalized ratio: a safe and efficacious periprocedural anticoagulation strategy. *Heart Rhythm* 2009; 6: 1425-1429.
- [33] Clemens A, van Ryn J, Sennewald R, Yamamura N, Stangier J, Feuring M, Härtter S. Switching from enoxaparin to dabigatran etexilate: pharmacokinetics, pharmacodynamics, and safety profile. *Eur J Clin Pharmacol* 2012; 68: 607-616.
- [34] Favaloro EJ, Lippi G. The new oral anticoagulants and the future of haemostasis laboratory testing. *Biochem Med (Zagreb)* 2012; 22: 329-341.
- [35] Van Ryn J, Stangier J, Haertter S, Liesenfeld KH, Wienen W, Feuring M, Clemens A. Dabigatran etexilate-a novel, reversible, oral direct thrombin inhibitor: interpretation of coagulation assays and reversal of anticoagulant activity. *Thromb Haemost* 2010; 103: 1116-1127.
- [36] Redondo S, Martínez MP, Ramajo M, Navarro-Dorado J, Barez A, Tejerina T. Pharmacological basis and clinical evidence of dabigatran therapy. *J Hematol Oncol* 2011; 4: 53.
- [37] Hankey GJ, Eikelboom J. Dabigatran etexilate: a new oral thrombin inhibitor. *Circulation* 2011; 123: 1436-1450.
- [38] Adcock DM, Gosselin R, Kitchen S, Dwyre DM. The effect of dabigatran on select specialty coagulation assays. *Am J Clin Pathol* 2013; 139: 102-109.
- [39] Sargento-Freitas J, Silva F, Pego J, Duque C, Cordeiro G, Cunha L. Cardioembolic stroke in a patient taking Dabigatran Etexilate: the first case report of clinical and pharmacologic resistance. *J Neurol Sci* 2014; 346: 348-349.
- [40] Tischer Ts, Schneider R, Lauschke J, Nesselmann C, Klemm A, Diedrich D, Kundt G, Bänsch D. Prevalence of atrial fibrillation in patients with high CHADS2- and CHA2DS2VASc-scores: anticoagulate or monitor high-risk patients? *Pacing Clin Electrophysiol* 2014; 37: 1651-1657.
- [41] Saad EB, d'Avila A, Costa IP, Aryana A, Slater C, Costa RE, Inácio LA Jr, Maldonado P, Neto DM, Camiletti A, Camanho LE, Polanczyk CA. Very low risk of thromboembolic events in patients undergoing successful catheter ablation of atrial fibrillation with a CHADS2 score ≤ 3 : a long-term outcome study. *Circ Arrhythm Electrophysiol* 2011; 4: 615-621.
- [42] Yagishita A, Takahashi Y, Takahashi A, Fujii A, Kusa S, Fujino T, Nozato T, Kuwahara T, Hirao K, Isobe M. Incidence of late thromboembolic events after catheter ablation of atrial fibrillation. *Circ J* 2011; 75: 2343-2349.
- [43] Kosiuk J, Nedios S, Kornej J, Koutalas E, Bertagnolli L, Rolf S, Arya A, Sommer P, Husser D, Hindricks G, Bollmann A. Impact of left atrial appendage morphology on peri-interventional thromboembolic risk during catheter ablation of atrial fibrillation. *Heart Rhythm* 2014; 11: 1522-1527.
- [44] Kimura T, Takatsuki S, Inagawa K, Katsumata Y, Nishiyama T, Nishiyama N, Fukumoto K, Aizawa Y, Tanimoto Y, Tanimoto K, Jinzaki M, Fukuda K. Anatomical characteristics of the left atrial appendage in cardiogenic stroke with low CHADS2 scores. *Heart Rhythm* 2013; 10: 921-925.
- [45] Khurram IM, Dewire J, Mager M, Maqbool F, Zimmerman SL, Zipunnikov V, Beinart R,

- Marine JE, Spragg DD, Berger RD, Ashikaga H, Nazarian S, Calkins H. Relationship between left atrial appendage morphology and stroke in patients with atrial fibrillation. *Heart Rhythm* 2013; 10: 1843-1849.
- [46] Di Biase L, Santangeli P, Anselmino M, Mohanty P, Salvetti I, Gili S, Horton R, Sanchez JE, Bai R, Mohanty S, Pump A, Cereceda Brantes M, Gallighouse GJ, Burkhardt JD, Cesarani F, Scaglione M, Natale A, Gaita F. Does the left atrial appendage morphology correlate with the risk of stroke in patients with atrial fibrillation? Results from a multicenter study. *J Am Coll Cardiol* 2012; 60: 531-538.
- [47] Kawai VK, Cunningham A, Vear SI, Van Driest SL, Oginni A, Xu H, Jiang M, Li C, Denny JC, Shaffer C, Bowton E, Gage BF, Ray WA, Roden DM, Stein CM. Genotype and risk of major bleeding during warfarin treatment. *Pharmacogenomics* 2014; 15: 1973-1983.
- [48] Dalen JE. Should the newer oral anticoagulants be withheld from patients with valvular AF? *Chest* 2013; 144: 369-370.