

Case Report

Intracranial aneurysm disappeared after resection of a cardiac myxoma

Ying Huang¹, Jianping Chen³, Jun Wang²

Departments of ¹Neurology, ²Radiology, The First Affiliated Hospital, Gannan Medical University, Ganzhou, Jiangxi, China; ³Department of Surgery, Affiliated Ganzhou Hospital, Nanchang University, Ganzhou, Jiangxi, China

Received February 7, 2015; Accepted April 4, 2015; Epub May 15, 2015; Published May 30, 2015

Abstract: A 67-year-old male was diagnosed as myxoma-related cerebral aneurysm. Transthoracic echocardiogram showed a large mass in the left atrium and pathological analysis confirmed the diagnosis of myxoma. Cerebral magnetic resonance angiography revealed an aneurysm in the right internal carotid artery. However, the aneurysm was disappeared amazingly after successful resection of cardiac mass. There are a few similar case reports in the literature. Our case report illustrates that cerebral aneurysms may be associated with cardiac myxomas and that closely follow-up cerebral aneurysms after resection of myxoma is necessary.

Keywords: Cardiac myxoma, intracranial aneurysm, case report

Introduction

Myxoma is the most common primary benign tumour of the heart, which accounting for about 50% of cardiac tumors. Cardiac myxomas arise in the left atrium in about 75% of cases. Patients with cardiac myxomas usually present a variety of neurologic syndromes even in the absence of cardiac symptoms. The most common neurologic manifestations of cardiac myxomas is cerebral embolism [1]. However, myxoma-related cerebral aneurysm as a neurologic complication is rare.

Moreover, the clinical manifestations and imaging changes of myxomatous aneurysms was various. Here, we report a patient with myxomatous aneurysm, whose cerebral aneurysm disappeared after resection of cardiac myxomas.

Case report

A 67-year-old man was admitted to our hospital with a repetitive onset of dizzy and palpitation for 3 years. He was dyspnoeic on exertion, functional class NYHA II/III. Neurological examination was normal. A transthoracic echocardiogram showed a large mass in the left atrium (**Figure 1**). A magnetic resonance imaging (MRI)

scan of the brain showed local white matter ischemia in the left frontal lobe and magnetic resonance angiography (MRA) disclosed a aneurysm in the right internal carotid artery (**Figure 2**). The diagnosis of cardiac myxoma was made and the patient was referred for resection of the mass. This proceeded without complications and pathological analysis confirmed the diagnosis of myxoma. The management options of cerebral aneurysm were discussed with the department of neurosurgery and it was decided to treat him conservatively. A half a year of follow-up transthoracic echocardiogram showed no signs of recurrence of the myxoma. Cerebral MRA showed the aneurysm disappeared in the right internal carotid artery (**Figure 3**). Clinical and laboratory investigations including abdominal ultrasonography, chest radiography and vascular ultrasonography of the cervical and extremities did not reveal an aneurysm of the extracerebral arteries. The diagnosis myxoma-related cerebral aneurysm was made. Up till now he is doing relatively well.

Discussion

Myxoma-related cerebral aneurysm as a neurologic complication is rare. About 50 cases have been reported since the first reported case in

Myxoma-related cerebral aneurysm

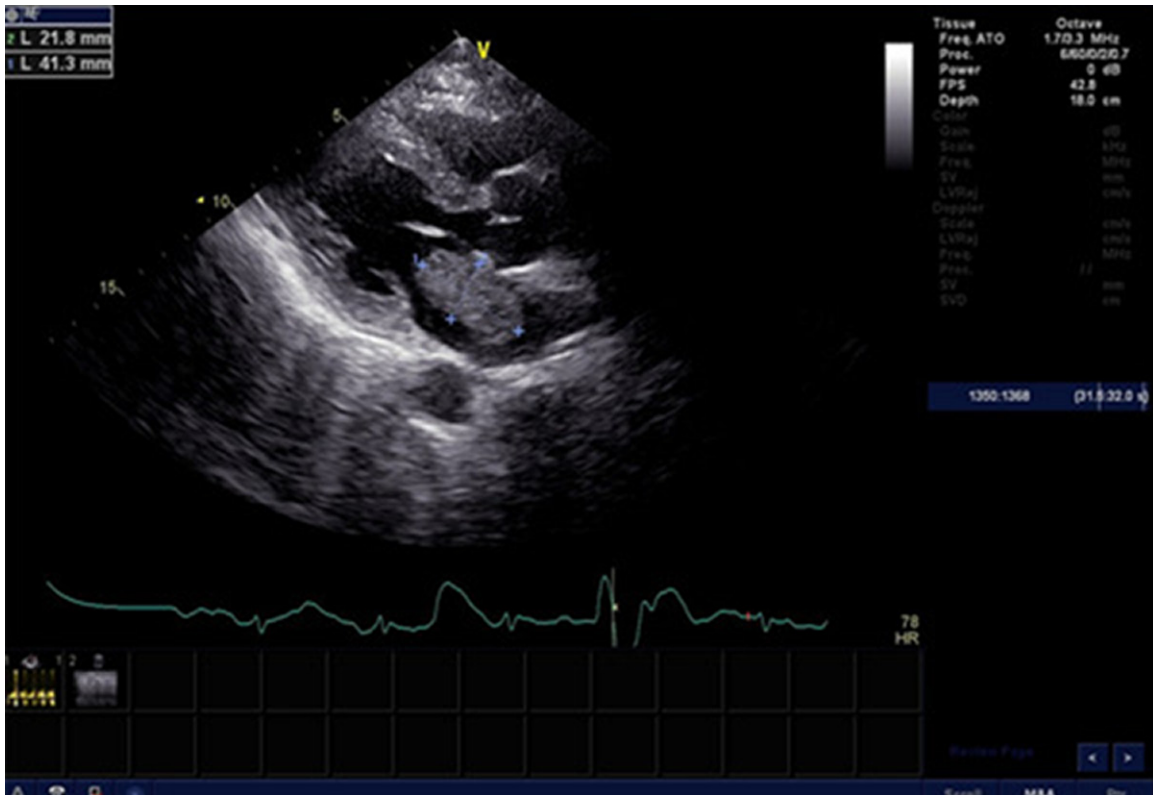


Figure 1. Transthoracic echocardiogram, parasternal long axis, showing a large mass (41.3 mm×21.8 mm) in the left atrium, with a little pedicle attached in the centre of interatrial septum, as slight swing during cardiac cycle in the left atrium.

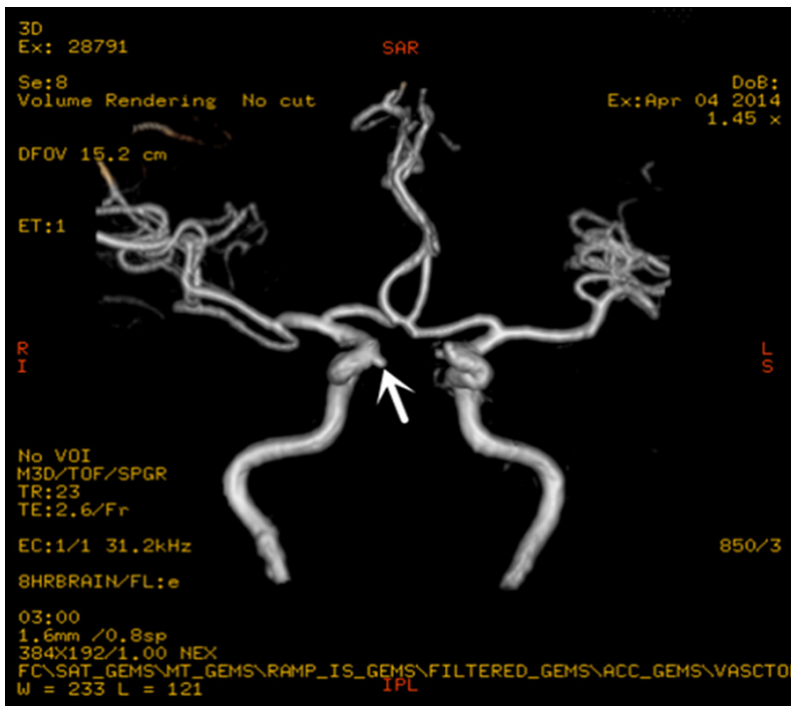


Figure 2. Cerebral magnetic resonance angiography (MRA) showing an aneurysm (D=3.5 mm) in the right internal carotid artery (arrow).

1966 [2]. In 2013, A. W. G. J. Oomen et al. described a case of delayed aneurysm formation one year after resection of cardiac myxoma [3]. However, cerebral aneurysm disappeared after resection of cardiac myxomas is rare. Only a few case reports are documented [4].

The pathogenesis of formation of myxoma-related aneurysms is not clear with two hypotheses accepted in the literature. The one hypothesis was vascular injury theory that tumor emboli always causing vascular endothelial damage, connective tissue proliferation, and an inflammatory reaction, leading to arterial wall thinning and expansion

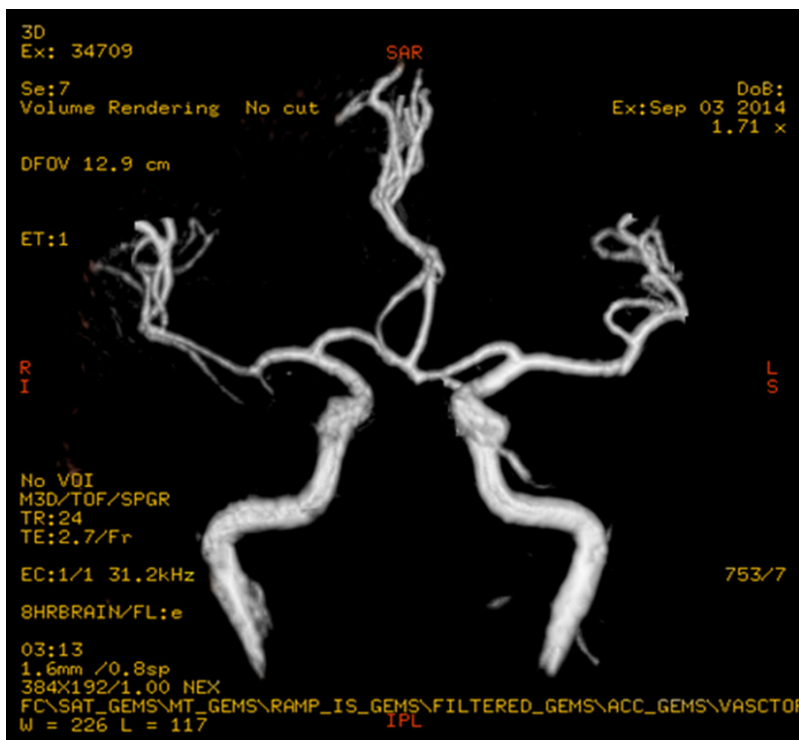


Figure 3. Cerebral MRA showed the aneurysm disappeared in the right internal carotid artery after resection of cardiac myxoma.

of the vessel [5]. Another hypothesis was tumor origin theory. Later was determined by histopathological studies, which showed active invasion of the vascular wall by viable tumor emboli [6]. According to current hypothesis, therefore, we assume that the pathological process of myxomatous cerebral aneurysms is a dynamic change, which may be continued to grow, or even bigger, may be ego recede. Exactly as Hayashi et al disclosed that a case of one of cerebral aneurysms become bigger, the other disappeared after resection of left atrial myxoma [4], even the one patient, the change of cerebral aneurysms is not consistent. While in our patient, the aneurysm was disappeared after resection of left atrial myxoma.

The natural history of myxomatous aneurysms is not well characterized. Josephson [7] reported one patient with myxomatous aneurysms that had been stable, with the patient remaining asymptomatic for 8 years. And our patient had no signs of intracranial bleeding and no component of the aneurysm was suitable for resection. No definite guidelines for therapy of the disease have been formulated. Resection of the cardiac myxoma is useful in eliminating

early neurologic symptoms [8], but cannot completely abolish the risk of delayed cerebral aneurysm formation [9]. Treatment with chemotherapy in combination with low-dose radiation has been suggested but further research is warranted [10].

In conclusion, we report on a case of cerebral myxomatous aneurysms disappeared after successful resection of a cardiac myxoma. It must be follow-up the cerebral aneurysms even years after successful resection of a myxoma. Moreover, due to various clinical manifestations and imaging changes of myxomatous aneurysms, it is necessary that performing the angiography, biopsy, and even autopsy for similar cases to prove the

pathogenesis of the disease and to guide the treatment.

Disclosure of conflict of interest

None.

Address correspondence to: Dr. Jianping Chen, Department of Surgery, Affiliated Ganzhou Hospital, Nanchang University, 17 Hongqi Road, Ganzhou 341000, Jiangxi, P. R. China. Tel: 0086-0797-8685557; 0086-15279797688; Fax: 0086-0797-8266013; E-mail: cjp0101@126.com

References

- [1] Pinede L, Duhaut P, Loire R. Clinical presentation of left atrial cardiac myxoma. A series of 112 consecutive cases. *Medicine (Baltimore)* 2001; 80: 159-172.
- [2] Stoane L, Allen JH Jr, Collins HA. Radiologic observations in cerebral embolization from left heart myxomas. *Radiology* 1966; 87: 262-266.
- [3] Oomen AW, Kuijpers SH. Cerebral aneurysms one year after resection of a cardiac myxoma. *Neth Heart J* 2013; 21: 307-309.
- [4] Hayashi S, Takahashi H, Shimura T, Nakazawa S. [A case of multiple cerebral aneurysm which showed rapid growth caused by left atrial myxoma]. *N Shinkei Geta* 1995; 23: 977-980.

Myxoma-related cerebral aneurysm

- [5] New PF, Price DL, Carter B. Cerebral angiography in cardiac myxoma, correlation of angiographic and histopathological findings. *Radiology* 1970; 96: 335-345.
- [6] Jean WC, Walski-Easton SM, Nussbaum ES. Multiple intracranial aneurysms as delayed complications of an atrial myxoma: case report. *Neurosurgery* 2001; 49: 200-202.
- [7] Josephson SA, Johnston SC. Multiple stable fusiform intracranial aneurysms following atrial myxoma. *Neurology* 2005; 64: 526.
- [8] Koo YH, Kim TG, Kim OJ, Oh SH. Multiple fusiform cerebral aneurysms and highly elevated serum interleukin-6 in cardiac myxoma. *J Korean Neurosurg Soc* 2009; 45: 394-396.
- [9] Sabolek M, Bachus-Banaschak K, Bachus R, Arnold G, Storch A. Multiple cerebral aneurysms as delayed complication of left cardiac myxoma: a case report and review. *Acta Neurol Scand* 2005; 111: 345-350.
- [10] Bernet F, Stulz PM, Carrel TP. Long term remission after resection, chemotherapy, and irradiation of a metastatic myxoma. *Ann Thorac Surg* 1998; 66: 1791-1792.