

Case Report

High-dose methotrexate plus temozolomide as a salvage treatment in metastatic central nervous system Lymphoma: two cases report and review of literature

Gaixiang Xu, Min Yang, Hongyan Tong, Liping Mao, Jie Jin

*Department of Hematology, The First Affiliated Hospital, College of Medicine, Zhejiang University Hangzhou, Zhejiang, People's Republic of China. *Equal contributors.*

Received February 14, 2015; Accepted April 23, 2015; Epub May 15, 2015; Published May 30, 2015

Abstract: Temozolomide (TMZ), an alkylating agent, is widely used for treating high-grade gliomas and has emerged as a treatment option for primary central nervous system lymphoma (PCNSL) because of its good penetration of the blood-brain barrier (BBB) and mild toxicity profile. To our knowledge, the role of temozolomide in the treatment of lymphoma was confined to PCNSL and its role in lymphoma central infiltration has not been reported yet. We describe our experience using a combination of high-dose methotrexate and temozolomide (MT) in two metastatic central nervous system Lymphoma (CNSL). As far as we know, this is the first case report about temozolomide in metastatic CNSL patients and no study to date has incorporated investigation of the biology of metastatic CNSL into the treatment protocol. Temozolomide may represent a promising new drug for the treatment of metastatic CNSL.

Keywords: Temozolomide, metastatic central nervous system Lymphoma, methotrexate

Case report

Case 1

A 61-year-old man was admitted to our Emergency Department with a short history of progressive left abdominal pain on 15 January, 2013. Ultrasonography showed Ruptured spleen and he experienced emergency splenectomy. The histopathological diagnosis of spleen was diffuse large B-cell lymphoma (non-GCB subtype) and clinical staging was stage IV. Postoperative staging assessment including PET-CT, CT and MRI, no signs indicated intracranial lymphoma infiltration. After surgery, the patient was treated with six courses of a standard RCHOP (rituximab, cyclophosphamide, doxorubicin, vincristine and prednisone) chemotherapy regimen every 21 days and additional two courses of rituximab monotherapy maintenance treatment from 30 Jan, 2013 to 23 Jul, 2013. After which the routine examination showed he got an excellent response (complete response) so chemotherapy was stopped for this patient and he entered into clinical follow-up stage since 23 Jul, 2013. For sure, four

times of cytarabine intrathecal injection were performed as central nervous system lymphoma prophylaxis after the diagnosis. The patient complained bad headache when he came to follow-up on 5 Nov, 2013. Unfortunately, Head MRI scan showed: In front of the left lateral ventricle horn and body beside rounds nodules, lymphoma infiltration was considered (**Figure 1A**). Afterwards the patient received two courses of high-dose methotrexate (MTX 5 g/square meter) mono-chemotherapy. Review of head MRI indicated disease progression (**Figure 1B**). So we chose high-dose methotrexate plus temozolomide (MT, MTX3 g/m² d1, 15, temozolomide 150 mg/m² from d7 to d11 in the course of 28 days) regimen for this patient and started the new chemotherapy on 23 Dec, 2013. Immediately after the first cycle a marked clinical and radiological improvement was demonstrated. No abnormal change in the whole brain was seen from the enhanced brain MRI (**Figure 1C**). Subsequently, the patient received additional three cycles of MT chemotherapy and the dosage of TMZ was increased to 200 mg/m² from second cycle. After two courses of temozolomide monotherapy maintenance the

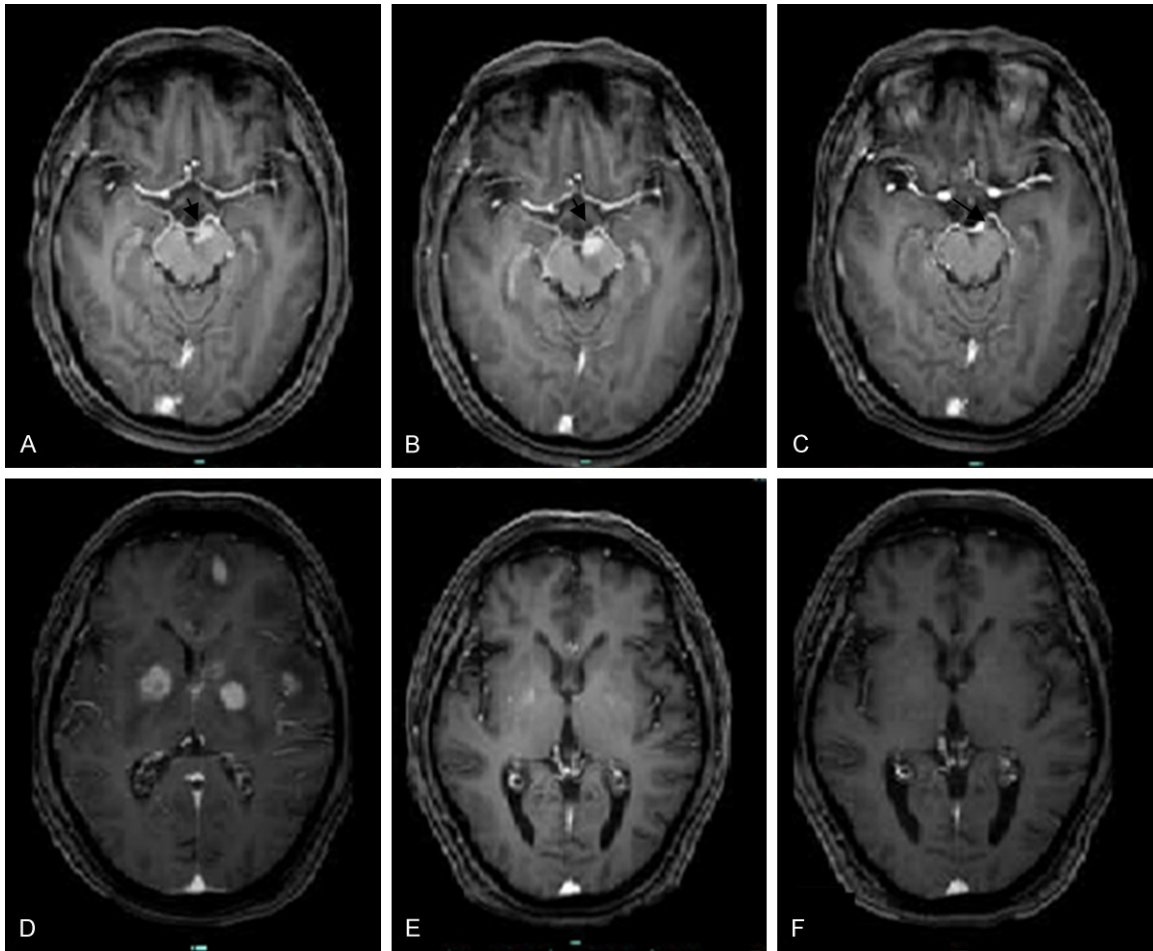


Figure 1. Seriated MRI analysis showing tumor progression and reduction over time in two patients: A: Exam performed on 4/11/2013 showing a large mass on the left lateral ventricle horn(case 1); B: MRI showed the tumor lesion was progression after two courses of MTX monotherapy 10/12/13 (case1); C: No abnormal change seen from the enhanced brain MRI after one course of MT regimen therapy performed on 2/2/14 (case1); D: MRI performed on 4/10/2014 showing multiple metastatic brain tumors (case 2); E: Exam performed on 10/11/2014, 1 week after the MT chemotherapy was administered , showing a significant tumor reduction (case 2); F: From the enhanced MRI performed on 7/1/2015, the original lesions was hardly seen after 3 courses of MT chemotherapy (case 2).

patient stopped chemotherapy due to economic reasons on 12 Jun, 2014. Until 3 Feb, 2015, the patient insisted bimonthly follow-up in our department. All examinations show the patient currently is at stable condition despite nearly 8 months has been passed since last chemotherapy.

Case 2

A 45-year-old man was received left subclavian lymph node biopsy excision under local anesthesia on 1 Aug, 2014 in our hospital due to multiple systemic lymphadenopathy based on physical examination. The diagnosis of Non-Hodgkin's lymphoma was established and subtype was peripheral T-cell at a clinical stage IV.

It is worth mentioning that all checks were not prompted central-Lymphoma-involved. As soon as the related examinations were done, we chose HyperCVAD (cyclophosphamide, dexamethasone, vincristine and doxorubicin) chemotherapy regimen for this patient. All the superficial lymph nodes were disappeared just one course of treatment, so we continue the original proposal to consolidate after the cytarabine intrathecal injection. Whereas, the patient went back to our ward with vision loss in left eye on 4 Oct, 2014. Brain MRI demonstrated: multiple metastatic brain tumors, considering the central lymphoma infiltration (**Figure 1D**). So the patient was administered MT chemotherapy. The quick and significant tumor

reduction was also seen in this patient. On the day of 15 of the first course the patient complained his vision began to improve. After one course of chemotherapy MRI showed the lesions in the brain were significantly reduced compared with before (**Figure 1E**). Until 3 Feb, 2015, the patient received a total of four times of MT chemotherapy, the lesions in the head nearly totally disappeared from the enhanced MRI (**Figure 1F**). Patient acuity and physical activity did not appear abnormal signs again.

Discussion

Temozolomide (TMZ) is an oral DNA alkylating agent used to treat high-grade gliomas such as glioblastoma multiform and anaplastic astrocytoma. It results in a depletion of the DNA repair enzyme O6-methylguanine-DNA methyltransferase (MGMT) [1]. And it was introduced to therapy of primary brain tumors in the 1990s due to its good penetration of the blood-brain barrier (BBB). This agent is generally regarded to be safe, with an acceptable safety profile [2]. Temozolomide is most often prescribed as a 5 of 28 days regimen at a dose of 150 to 200 mg/m² every 28 days. Alternatively, it can be also administered by extended daily dosing, resulting in an up to 210% higher dose density over a period of 28 days [3]. Its role in the therapy of lymphoma, continues to develop in the past decades although the role of mechanism is still not very clear. Most of all, it was confined to PCNSL [4, 5].

Treatment of CNS lymphoma remains a challenge for clinicians. Both primary and secondary (metastatic) CNS lymphoma are frequently resistant to commonly used chemotherapeutic agents. Chemotherapy, with or without radiotherapy, is the mainstay of treatment for these patients. High-dose methotrexate (MTX) is the most effective drug available to treat these lesions, and it is used in doses of 1 to 8 g/m² [2], either as a single agent or in combination with other drugs such as corticosteroid agents, cytarabine, procarbazine, vincristine, carmustine, lomustine, thiotepa, cyclophosphamide, temozolomide, and rituximab. To date, an overwhelming number of different regimens in which high-dose MTX is used have been reported. Given the lack of randomized trials, however, the optimal treatment remains controversial [6]. Salvage therapies include re-challenge with high-dose methotrexate (HD-MTX), whole brain

radiotherapy, temozolomide, topotecan and pemetrexed. Most of studies emphasized the indisputable role of high-dose methotrexate as backbone for any therapy regimen.

Herein, We describe our experience using a combination of high-dose methotrexate and temozolomide (MT) in two metastatic central nervous system Lymphoma. We detected grade-I and grade-II of neutrophils on the first patient and the second patient respectively during the first MT-chemotherapy course. Both of them experienced mild liver damage reflecting by mildly elevated alanine aminotransferase also in the first cycle of MT chemotherapy. The adverse events did not prolonged hospitalization of the two patients and affected their quality of life. Mokino K et al [7] 'study showed temozolomide resulted in a good response and was well tolerated without any major toxicity even in the patients of elderly and heavily pretreated. Wang XX's results also suggested that high-dose methotrexate plus temozolomide (MT) combination may be a simplified and effective regimen comparable to high-dose methotrexate plus cytarabine (MC) for newly diagnosed PCNSL [8]. Pulczynski EJ et al [9]'s phase 2 study showed that de-escalation of induction therapy in elderly primary central nervous system lymphoma patients followed by temozolomide maintenance treatment seems to be a promising treatment strategy. The MT regimen in our two cases have showed excellent effects and the adverse events were mild but the length of follow-up was insufficient to assess the true risk and further follow-up is needed.

Taking into consideration the good effect and acceptable toxicity profile, we conclude that temozolomide appears to be a good choice in the treatment of metastatic CNSL, perhaps in combination with MTX as initial treatment. Confirmation in a larger series of similar patients is required. Anyway, temozolomide may represent a promising new drug for the treatment of metastatic CNS lymphoma. Nevertheless, efforts in this area may ultimately affect treatment choices for these individual patients.

Acknowledgements

The work was supported by Zhejiang Provincial Education Department (Grant # Y201224159),

National Natural Science Fundation of China (Grant # 81101792) and Science Research Fundation of Chinese traditional medicine of Zhejiang Province (Grant # 2011ZB064).

Disclosure of conflict of interest

None.

Address correspondence to: Dr. Gaixiang Xu, Department of Hematology, The First Affiliated Hospital, College of Medicine, Zhejiang University Hangzhou, Qinchun Road 79, Hangzhou City, Zhejiang Province, China. Tel: 0086-1377772353; Fax: 0086-071-87236702; E-mail: 13777472353@163.com

References

- [1] Stupp R, Mason WP, van den Bent MJ, Weller M, Fisher B, Taphoorn MJ, Belanger K, Brandes AA, Marosi C, Bogdahn U, Curschmann J, Janzer RC, Ludwin SK, Gorlia T, Allgeier A, Lacombe D, Cairncross JG, Eisenhauer E, Mirimanoff RO. Radiotherapy plus concomitant and adjuvant temozolomide for glioblastoma. *N Engl J Med* 2005; 10: 987-96.
- [2] Mrugala MM, Adair J, Kiem HP. Temozolomide: Expanding its role in brain cancer. *Drugs Today (Barc)* 2010; 46: 833-46.
- [3] Wolfgang Wick, Michael Platten, and Michael Weller. New (alternative) temozolomide regimens for the treatment of glioma. *Neuro Oncol* 2009; 11: 69-79.
- [4] Poortmans PM, Kluin-Nelemans HC, Haaxma-Reiche H, Van't Veer M, Hansen M, Soubeyran P, Taphoorn M, Thomas J, Van den Bent M, Fickers M, Van Imhoff G, Rozewicz C, Teodorovic I, van Glabbeke M. High-dose methotrexate-based chemotherapy followed by consolidating radiotherapy in non-AIDS-related primary central nervous system lymphoma: European Organization for Research and Treatment of Cancer Lymphoma Group Phase II Trial 20962. *J Clin Oncol* 2003; 21: 4483-4488.
- [5] Gavrilovic IT, Hormigo A, Yahalom J, DeAngelis LM, Abrey LE. Long-term follow-up of high-dose methotrexate-based therapy with and without whole brain irradiation for newly diagnosed primary CNS lymphoma. *J Clin Oncol* 2006; 24: 4570-4574.
- [6] Omuro AM, Abrey LE. Chemotherapy for primary central nervous system lymphoma. *Neurosurg Focus* 2006; 21: E12.
- [7] Makino K, Nakamura H, Hide T, Kuratsu J. Salvage treatment with temozolomide in refractory or relapsed primary central nervous system lymphoma and assessment of the MGMT status. *J Neurooncol* 2012; 106: 155-160.
- [8] Wang XX, Huang HQ, Bai B, Cai QQ, Cai QC, Gao Y, Xia YF, Xia ZJ, Jiang WQ. Clinical outcomes of patients with newly diagnosed primary central nervous system lymphoma are comparable on treatment with high-dose methotrexate plus temozolomide and with high-dose methotrexate plus cytarabine: a single-institution experience. *Leuk Lymphoma* 2014; 55: 2497-2501.
- [9] Pulczynski EJ, Kuittinen O, Erlanson M, Hagberg H, Fosså A, Eriksson M, Nordstrøm M, Ostensstad B, Fluge O, Leppä S, Fiirgaard B, Bersvendsen H, Fagerli UM. Successful change of treatment strategy in elderly patients with primary central nervous system lymphoma by de-escalating induction and introducing temozolomide maintenance: results from a phase II study by the Nordic Lymphoma Group. *Haematologica* 2015; 100: 534-40.