

Original Article

Endovascular management of ruptured basilar superior cerebellar artery junction aneurysms: a series of three cases with review of literature

Mingchang Li¹, Wei Wang¹, Ning Lin², Junmin Wang¹, Yuefei Wang¹, Zhibiao Chen¹, Qianxue Chen¹

¹Department of Neurosurgery, Renmin Hospital of Wuhan University, Wuhan 430060, Hubei Province, P.R.C;

²Department of Neurosurgery, Cornell Hospital, New York University, New York, NY, USA

Received February 15, 2015; Accepted April 23, 2015; Epub May 15, 2015; Published May 30, 2015

Abstract: Aneurysms located on the basilar superior cerebellar artery (SCA) junction are very rare. Endovascular coiling is a safe and feasible treatment option for these challenging cases regardless of the narrow operative field, their intimate relationship to perforating vessels and cranial nerves, which results in high morbidity and mortality rates during clipping. From Jan. 2013 to Jan. 2014, we treated three patients (three women between the ages of 44 to 52 years) with ruptured basilar SCA junction aneurysms by endovascular embolization. All the three patients presented with rupture symptoms and were treated in the acute period. Informed and written high-risk consent was given by all patients prior to the treatment. Successful angiographic and clinical outcome was achieved in all three patients. Endovascular treatment of basilar SCA junction aneurysms with coils or combined with stent is an effective and safe option in the management of this rare aneurysm.

Keywords: Aneurysm, endovascular management, superior cerebellar artery

Introduction

Superior cerebellar aneurysms (SCA) are rare and account for 1.7% of all intracranial aneurysms, part of them are located at the junction of basilar artery and SCA [1]. In the present report, we describe our clinical experiences with three cases with basilar SCA junction aneurysm treated successfully with endovascular treatment.

Case reports

Case 1

A 44-year-old woman with no past significant medical illness presented with severe headache. CT scan showed subarachnoid hemorrhage (SAH) predominantly in the suprasellar cistern (**Figure 1A**). It was diagnosed as the left SCA aneurysms, the neck was relatively wide, riding across the original segment of left superior cerebellar artery, top pointed to the upper left by digital subtraction angiogram (DSA) (**Figure 1C**). Three-dimensional DSA confirmed

the diagnosis (**Figure 1B**). Sixteen hours after episode, endovascular treatment was performed under general anesthesia, and standard heparin protocol was followed and activated clotting time greater than 250 s was maintained during the procedure. A six-French (6F) Envoy (cordis) guiding catheter was placed in the distal vertebral artery. A combination of Rebar-18 microcatheter and SilverSpeed-14 microwire were used to access the P1 segment of the left posterior cerebral artery. Then a combination of Echelon-10 microcatheter and SilverSpeed-14 microwire were used to access the aneurysm. Axiom Helix (2 mm×8 cm) followed with another Axiom Helix (2 mm×2 cm) coils were used to occlude the aneurysm. Solitaire stent (4 mm×15 mm) was deployed using post-jailing technique. There were no intra- and periprocedural complications and the post-operative course was uneventful. The patient's neurological examination after 15 days was completely normal, showing Glasgow Outcome Scale (GOS) 5. Post-coiling angiogram showed complete exclusion of the aneurysm (**Figure 1D**). Control angiogram done after half

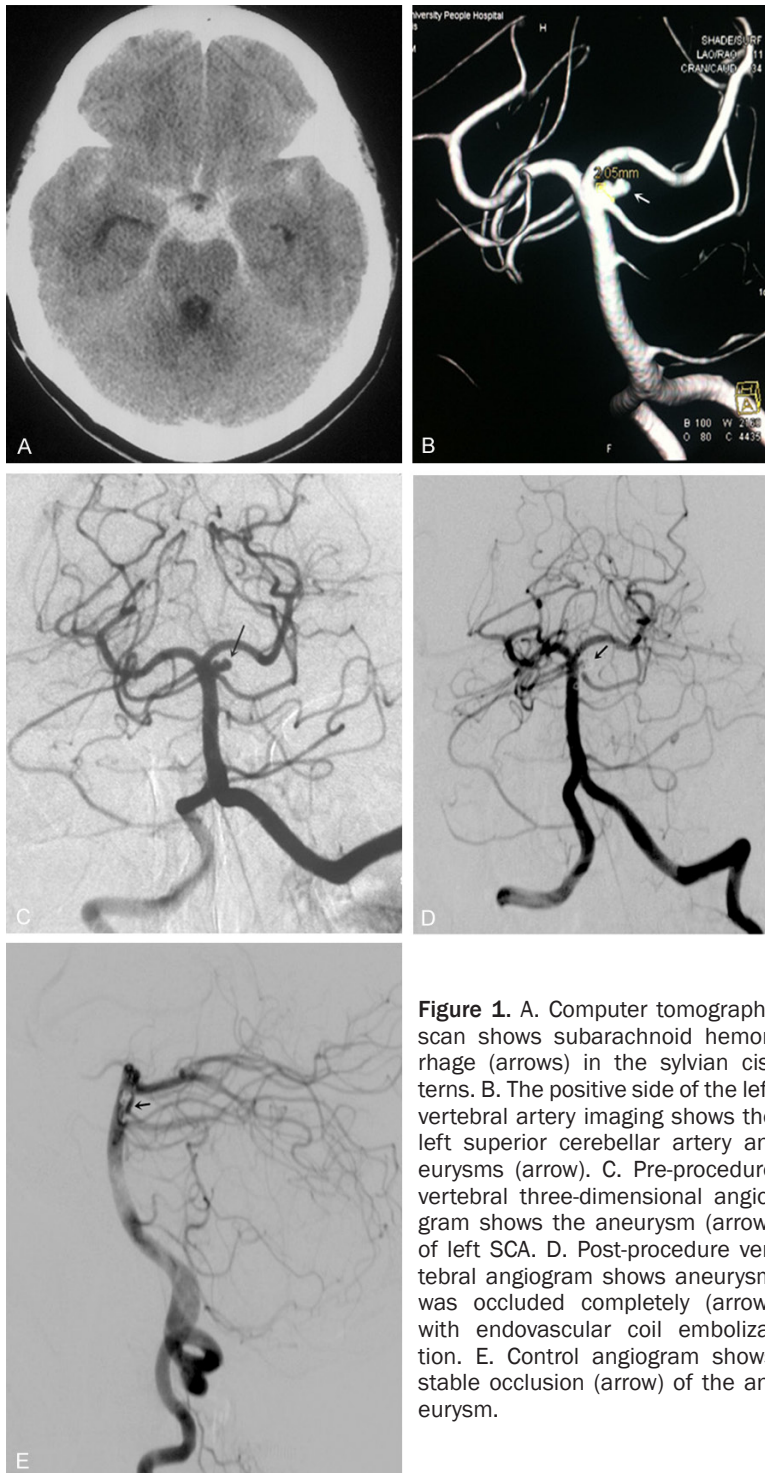


Figure 1. A. Computer tomography scan shows subarachnoid hemorrhage (arrows) in the sylvian cisterns. B. The positive side of the left vertebral artery imaging shows the left superior cerebellar artery aneurysms (arrow). C. Pre-procedure vertebral three-dimensional angiogram shows the aneurysm (arrow) of left SCA. D. Post-procedure vertebral angiogram shows aneurysm was occluded completely (arrow) with endovascular coil embolization. E. Control angiogram shows stable occlusion (arrow) of the aneurysm.

an year showed stable occlusion of the aneurysm with endovascular coil in place (**Figure 1E**).

Case 2

A 52-year-old lady with a history of hypertension, presented with severe headache and

vomit. CT scan showed subarachnoid hemorrhage (SAH) in the emergency room. DSA was done at admission revealed the left SCA aneurysm (**Figure 2A**). Twenty hours after episode, endovascular treatment was done under general anesthesia and standard heparin protocol was followed, then an activated clotting time greater than 250 s was maintained during the procedure. A 6F Envoy (cordis) guiding catheter was placed in the distal vertebral artery. Combined with the left side of the vertebral artery angiography and 3D reconstruction image showed the left SCA aneurysms. A combination of Rebar-18 microcatheter and SilverSpeed-14 microwire were placed into the basal artery, with the tip to P1 segment of the left posterior cerebral artery in case of using stent. Then a combination of Echelon-10 microcatheter and SilverSpeed-14 microwire were used to access the aneurysm. Axiom Helix (4 mm×8 cm, 2 mm×4 cm, 2 mm×2 cm) coils were used to occlude the aneurysm (**Figure 2B**). Post-coiling angiogram showed complete exclusion of the aneurysm (**Figure 2C**). The period of postoperative was uneventful. The patient's neurological examination done after 1 month was completely normal, showing Glasgow Outcome Scale (GOS) 5. Control angiogram done at the end of

6 months showed stable occlusion with no recanalization of the aneurysm (**Figure 2D**).

Case 3

A 50-year-old women, who had a history of hypertension for 3 years, presented with severe headache. CT scan showed SAH. DSA was done

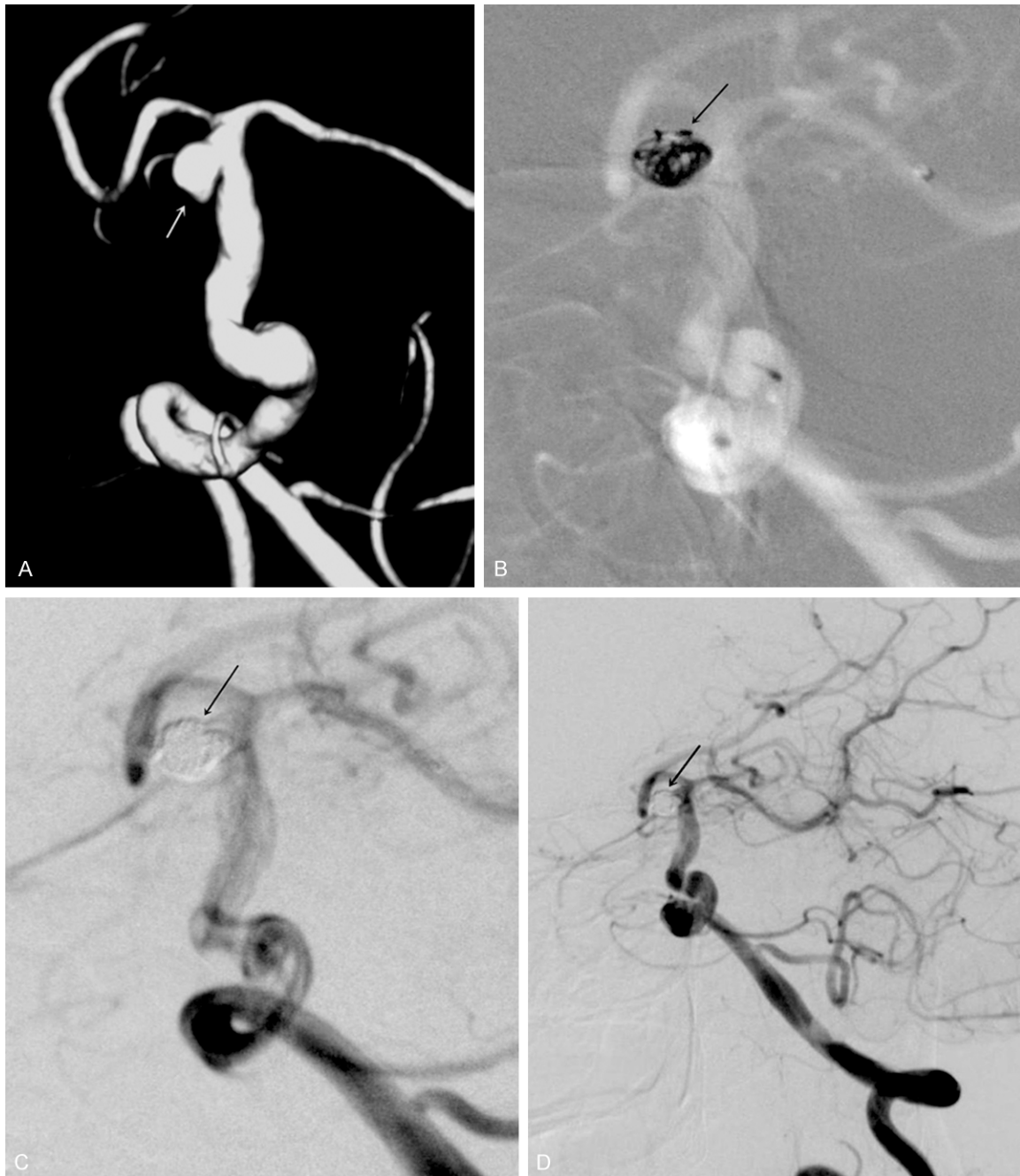

Figure 2. A. The positive side of the left vertebral artery and three-dimensional imaging shows the left superior cerebellar artery aneurysms. B. During procedure vertebral angiogram shows the aneurysm (arrow) of left SCA. C. Post-procedure vertebral angiogram shows aneurysm was occluded completely (arrow) with endovascular coil embolization. D. Control angiogram shows stable occlusion (arrow) of the aneurysm.

after admission showed an aneurysm of the SCA (Figure 3A and 3B). Twenty two hours after episode, endovascular embolization was performed. Standard heparin protocol was followed and an activated clotting time greater than 250 s was maintained during the procedure. A 6F Envoy (cordis) guiding catheter was

inserted in the distal vertebral artery. A combination of Rebar-18 microcatheter and SilverSpeed-14 microwire were used to access the P1 segment of the left posterior cerebral artery. Then a pre-shaping microcatheter (Echelon-10) in SilverSpeed-14 microwire was guided into the target aneurysm. Axium Helix (2

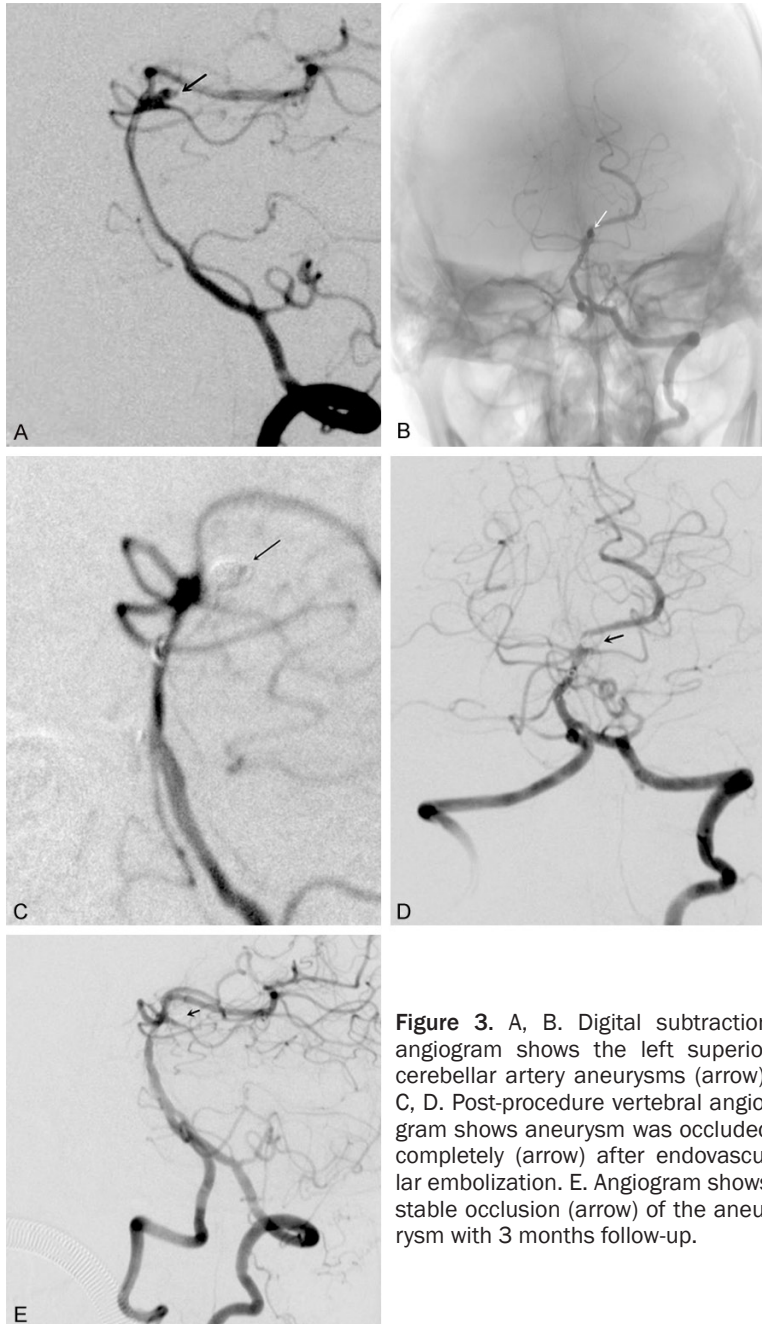


Figure 3. A, B. Digital subtraction angiogram shows the left superior cerebellar artery aneurysms (arrow). C, D. Post-procedure vertebral angiogram shows aneurysm was occluded completely (arrow) after endovascular embolization. E. Angiogram shows stable occlusion (arrow) of the aneurysm with 3 months follow-up.

mm×4 cm) followed with another Axiom Helix (1.5 mm×2 cm) coils were used to occlude the aneurysm. Solitaire stent (4 mm×15 mm) was deployed using post-jailing technique. Post-procedure angiogram showed complete exclusion of the aneurysm (**Figure 3C and 3D**). There were no bad events in the post-procedure hospital stay and patient was discharged after 7 days, showing Glasgow Outcome Scale (GOS) 5. No neurological deficit was seen after 1 month. Control angiogram carried out after 3 months

showed stable occlusion of the aneurysm (**Figure 3E**).

Discussion

Common symptoms of SCA include vertigo, nausea, vomiting and loss of balance, and headache after bleeding, while additional symptoms include ipsilateral Horner syndrome, ipsilateral intension tremor, nystagmus, contralateral hearing disturbance, contralateral loss of pain and temperature, and loss of emotional expression [2]. About two third of these aneurysms present with SAH [1, 3]. B. Atalay reported that these aneurysms can also present with ischemic symptoms [4]. In our present series, we report three cases of SCA aneurysms located at basilar SCA junction treated successfully by endovascular coiling technique. All of our three cases presented with SAH, and were treated in the acute phase to prevent the occurrence of untoward effects like re-bleed, vasospasm, and convulsions that may occur if there is delay in the treatment of these aneurysms.

Among those cases that reported of SCA aneurysm (**Table 1**), hemorrhage (SAH/cerebellar hematoma) was the most common clinical symptom, with one case of dizziness and headache.

Whether endovascular therapy or microsurgery, most of the results were satisfactory. Although surgical treatment of these aneurysms is associated with good results, requires an invasive route such as craniotomy via the pterional or subtemporal approach for clipping of the aneurysm. Surgical technique described for the treatment of these aneurysms include parent artery occlusion, trapping or body clipping, and wrapping [5]. Even for fusiform aneurysm in superior artery, surgical is a alternative option.

Therapy of SCA aneurysm

Table 1. Cases report of superior cerebellar artery aneurysms till now. SCA: superior cerebellar artery aneurysms. STA: Superficial temporal artery. GR: Good recovery. P: Poor outcome. D: Dead.

Author	Year	Cases	Clinical symptoms	Intracerebral aneurysm	Treatment	Follow-up	Out come
Alurkar [12]	2012	3	Hemorrhage (SAH/cerebellar hematoma)	Fusiform aneurysms of SCA	Endovascular	1 year	GR
Kang [2]	2012	1	Dizziness and headache	Distal SCA	Endovascular	4 months	GR
Lamis [5]	2014	1	Hemorrhage (SAH)	Fusiform aneurysms of SCA	STA-SCA bypass and trapping	1 week	GR
Jin [3]	2012	33	Hemorrhage (SAH/cerebellar hematoma)	SCA	Microsurgery (12) or Endovascular (21)	Unknown	GR (25) P (7) D (1)
Haruma [7]	2013	2	Hemorrhage (SAH)	SCA	Microsurgery (1) or Endovascular (1)	Unknown	GR
Kim [8]	2014	53	Hemorrhage (SAH/cerebellar hematoma)	SCA	Endovascular	25 months	GR (45) P (8)
Nussbaum [6]	2011	2	Diplopia	SCA	Clip reconstruction	Unknown	GR
Cognard [10]	2009	1	Headaches	Distal SCA	Endovascular occlusion with glue	3 months	GR

Eric S reported two cases of fusiform SCA aneurysms treated successfully by clip reconstruction [6]. We hold the opinion that care must be taken to prevent injury to the third and fourth cranial nerves during surgery owing to the proximity of these nerves to the SCA. Occlusion of the SCA is well tolerated because of the presence of the good collaterals between the SCA and both anterior inferior cerebellar artery and posterior inferior cerebellar artery through verian arcade and also with the paramedian branches and perforators of the basilar artery [3, 7].

On account of minimally invasive, endovascular transarterial embolization with coils is a good therapeutic option for the treatment of these aneurysms. Through the treatment of 53 patients, Kim found that embolization of SCA aneurysms was a safe treatment modality, enabling individualized procedural strategies to accommodate distinctive angio-anatomic configurations [8], similar to the study of Iizuka [9]. Cognard described intra-aneurysmal injection of glue via the flow guiding catheter for the occlusion of the distal cerebellar aneurysms [10]. Gjertsen came to a conclusion that there was no morbidity related to perforator injury, regardless of the treatment modality, and whether embolization or microsurgery was with relatively low procedural morbidity and mortality rates [11]. In all our three cases we were able to successfully negotiate the pre-shaped microcatheter to the target site of the aneurysm and completely occlude the aneurysm with coils, two of them assisted with stent, achieving complete exclusion of the aneurysm from the circulation. Treated with the endovascular coiling method, our three patients all got the successful outcome.

Conclusion

SCA aneurysms, which are rare and usually present with SAH, have peculiar characteristics, including a paucity of perforators, abundant collateral supplies and off the midline location. Early intervention of SCA can prevent further complications. The treatment strategy should be based on the specific circumstances of the aneurysm and conditions of the patient. Endovascular treatment of SCA aneurysms with coils is an effective and safe option in the management of this rare aneurysms. But a larger study has to be undertaken to prove the

safety and efficacy of the treatment procedure and its long term outcome.

Acknowledgements

This work was supported by grants from the National Natural Science Foundation of China (81171112, 81371272 to M.C.L., 81372683 to Q.X.C.) and grants from Leading talent project of Hubei province (Q.X.C.).

Disclosure of conflict of interest

None.

Address correspondence to: Dr. Mingchang Li, Department of Neurosurgery, Renmin Hospital of Wuhan University, Wuhan 430060, Hubei Province, P. R. China. Tel:+86-027-88041911-82237; Fax: +86-027-88041911-82237; E-mail: whulmc@126.com

References

- [1] Peluso JP, van Rooij WJ, Sluzewski M, Beute GN. Superior cerebellar artery aneurysms: incidence, clinical presentation and midterm outcome of endovascular treatment. *Neuroradiology* 2007; 49: 747-751.
- [2] Kang MC, Chae KS, Noh SJ, Choi HG, Ghang CG. Coil embolization of ruptured thrombosed distal superior cerebellar artery aneurysm: a case report. *J Cerebrovasc Endovasc Neurosurg* 2012; 14: 243-246.
- [3] Jin SC, Park ES, Kwon do H. Endovascular and microsurgical treatment of superior cerebellar artery aneurysms. *J Cerebrovasc Endovasc Neurosurg* 2012; 14: 29-36.
- [4] Atalay B, Altinors N, Yilmaz C, Caner H, Ozger O. Fusiform aneurysm of the superior cerebellar artery: short review article. *Acta Neurochir (Wien)* 2007; 149: 291-294.
- [5] Lamis FC, De Paiva Neto MA, Cavalheiro S. Fusiform superior cerebellar artery aneurysm treated with STA-SCA bypass and trapping. *Surg Neurol Int* 2014; 5: S139-142.
- [6] Nussbaum ES, Defillo A, Zelensky A, Stoller R, Nussbaum L. Dissecting peripheral superior cerebellar artery aneurysms: Report of two cases and review of the literature. *Surg Neurol Int* 2011; 2: 69.
- [7] Haruma J, Sugiu K, Shimazu Y, Michiue H, Tokunaga K, Date I. Surgical and endovascular treatment for superior cerebellar artery aneurysms: report of two cases. *No Shinkei Geka* 2013; 41: 45-51.
- [8] Kim CH, Cho YD, Jung SC. Endovascular treatment for superior cerebellar artery aneurysms:

Therapy of SCA aneurysm

- morphological features, technique, and outcome. *Neuroradiology* 2014; 56: 647-654.
- [9] Iizuka H, Miyachi S, Ohshima T, Izumi T, Tsurumi A, Yoshida J. Morphological study of aneurysms at the junction of the superior cerebellar artery. *Interv Neuroradiol* 2008; 14: 259-266.
- [10] Cognard C, Weill A, Tovi M, Castaings L, Rey A, Moret J. Treatment of distal aneurysms of the cerebellar arteries by intraaneurysmal injection of glue. *AJNR Am J Neuroradiol* 1999; 20: 780-784.
- [11] Gjertsen O, Nakstad PH, Pedersen HK, Josefsen R. Traumatic aneurysm of the superior cerebellar artery. *Interv Neuroradiol* 2007; 13: 167-171.
- [12] Alurkar A, Karanam LS, Nayak S, Oak S. Endovascular management of fusiform superior cerebellar artery aneurysms: a series of three cases with review of literature. *J Clin Imaging Sci* 2012; 2: 47.