

Original Article

Soft-tissue facial characteristics of attractive Chinese men compared to normal men

Feng Wu¹, Junfang Li², Hong He¹, Na Huang², Youchao Tang², Yuanqing Wang²

¹The State Key Laboratory Breeding Base of Basic Science of Stomatology (Hubei-MOST) & Key Laboratory of Oral Biomedicine Ministry of Education (KLOBM), School & Hospital of Stomatology, Wuhan University, Wuhan 430079, Hubei, People's Republic of China; ²Huizhou Hospital of Stomatology, Jinan University, Huizhou 516001, Guangdong, People's Republic of China

Received February 26, 2015; Accepted April 27, 2015; Epub May 15, 2015; Published May 30, 2015

Abstract: Objective: To compare the facial characteristics of attractive Chinese men with those of reference men. Materials and Methods: The three-dimensional coordinates of 50 facial landmarks were collected in 40 healthy reference men and in 40 "attractive" men, soft tissue facial angles, distances, areas, and volumes were computed and compared using analysis of variance. Results: When compared with reference men, attractive men shared several similar facial characteristics: relatively large forehead, reduced mandible, and rounded face. They had a more acute soft tissue profile, an increased upper facial width and middle facial depth, larger mouth, and more voluminous lips than reference men. Conclusions: Attractive men had several facial characteristics suggesting babyfacedness. Nonetheless, each group of men was characterized by a different development of these features. Esthetic reference values can be a useful tool for clinicians, but should always consider the characteristics of individual faces.

Keywords: Laser scan, attractiveness, soft tissues

Introduction

The face plays a key role in communication and interaction with the environment [1-3]. This part of the body has been extensively studied by scientists, clinicians, artists, and many who have tried to measure and reproduce some of the facial characteristics, not the least of which has been beauty [4, 5]. Esthetic criteria appear to have been defined in almost all cultures [2, 5-8], but the actual presence of codified facial dimensions, angles, and ratios in attractive people is still a matter of debate. Scientific research on the quantitative, measurable bases of facial attractiveness is, therefore, still in progress [2, 4, 9-13].

Attractiveness is also becoming a matter of concern during childhood. Currently, Facial appearance during function has a major impact on how a person is perceived in society. Children with a non-attractive face are considered less intelligent, and are more likely to be isolated and underscored than children with an attractive face, even by their peers [1, 14]. A

beautiful face is often considered the key to success, and patients look for medical modifications of non-attractive dento-facial physiognomies. Consequently, for individuals with facial functional or movement impairments, methods for analyzing these impairments are useful in diagnosis, treatment planning, and outcome assessment of surgical rehabilitative procedures.

Orthodontists, therefore, face an increasing demand for treatments mainly based on aesthetic requests [15], and should approach the problem with the most advanced instruments and methods for diagnosis and treatment planning. Indeed, while technology today offers very advanced methods for treatment, orthodontic diagnosis still remains an art, widely relying on subjective evaluations of the facial soft tissues. Conventional two-dimensional measurements based on photographs or on radiographic profile projections [16, 17] has been raised doubt on the validity of such measurements and should be supplemented by three-dimensional analyses [17-22].

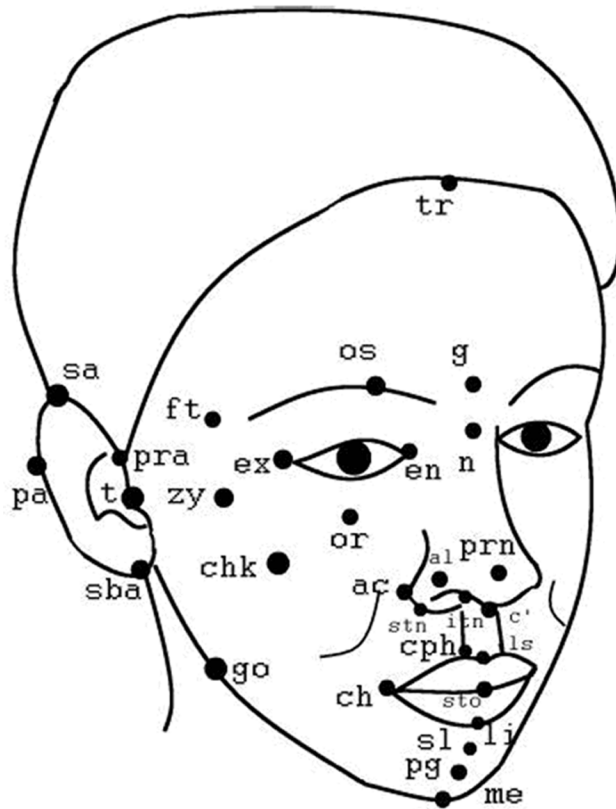


Figure 1. Digitized facial landmarks.

Facial three-dimensional imaging is a novel field for dentistry, and it is becoming a useful tool for both clinicians and researchers. As recently reviewed [16, 17], the development of different techniques for 3D reproduction of facial topography such as laser-based scanners or structured light-based scanners [23], significantly changed the process of diagnosis by providing a lot of facial anatomical details. Three-dimensional reconstruction, which has the potential to compensate for the inadequacies of a 2D image, has great potential for the diagnosis of patient abnormalities and for syndrome delineation.

The aim of this study was to identify possible aesthetic characteristics in facial size and shape of attractive Chinese man by laser-based scanners.

Materials and methods

Subjects

Ethical approval was obtained from the Ethics Committee of the stomatology hospital of the Wuhan University. All the analyzed men were

gave their informed consent to the experiment. All procedures were noninvasive, did not provoke damages, risks or discomfort to the subjects.

The sample size for each group was calculated based on an alpha significant level of 0.05 and a beta of 0.1 to achieve 90% power to detect a 1 mm/degree. The power analysis showed that 25 patients in each group were needed, and to compensate for dropouts during the trial, it was judged to enroll at least 40 patients.

At last, we selected 80 subjects divided into two groups: attractive group: 40 men were selected; reference group: the healthy, "reference" men included 40 men; they had normal dento-facial dimensions and proportions. All subjects had no previous cranio-facial trauma, orthodontics, surgery, or congenital anomalies.

Data collection and analysis

3D facial scans with a Konica/Minolta Vivid 910 laser scanner (Konica/Minolta Holdings, Tokyo, Japan) using a lens with a focal distance of 25 mm. With this lens, the scanner has a reported accuracy of 0.22 mm. A single experienced operator located and marked 50 soft-tissue landmarks by inspection and palpation (**Figure 1**; **Table 1**). For each child, this phase lasted less than 5 minutes.

During scanning, each patient sat on a revolving chair with the lips relaxed and head in a natural head position. Each patient was scanned from three different views simultaneously, and then the three images corresponding to these views were reconstructed into one 3D image using a registration process.

Three-dimensional coordinates of the facial landmarks were then obtained with a computerized electromagnetic digitizer (3Draw, Polhemus Inc, Colchester, Vt). Files of the three-dimensional coordinates were obtained, and computer programs were used for all subsequent off-line calculations.

Statistical calculations

The mean ages did not differ within each sex and age group. Descriptive statistics were com-

Table 1. Digitized facial landmarks and relevant definitions

Tr	trichion	on the hairline in the middle of the forehead
G	glabella	the most prominent midline point between the eyebrows
N	nasion	the innermost point between forehead and nose
Prn	pronasale	most protruded point of the nasal apex
C	columella	midpoint between the columella crests
Sn	subnasale	midpoint at the union of the lower border of the nasal septum and the upper lip
Ls	labiale superius	midpoint of the vermilion line of the upper lip
Sto	stomion	midpoint of the horizontal labial fissure
Li	labiale inferius	midpoint of the vermilion line of the lower lip
Sl	sublabiale	in the midline of the nasolabial sulcus
Pg	pogonion	most anterior point of the chin
Me	menton	lowest median point on the lower border of the mandible

Table 2. Soft-tissue facial linear distances measured in attractive and reference

	BOY BE		BOY RE		P
	Mean	SD	Mean	SD	
Exr-Exl	94.3	4.2	89.2	3.8	0.001
Tr-Tl	130.2	4.5	129.5	3.9	NS
Gor-Gol	98.9	3.2	97.8	4.1	NS
Chr-Chl	48.1	3.5	47.9	3.8	NS
Sn-Pg\N-Sn,%	100.3	3.1	103.4	4.5	NS
N-(Tr-Tl)	92.4	4.6	98.2	3.6	0.001
Sn-(Tr-Tl)	98.1	3.7	105.2	4.0	0.004
Pg-(Tr-Tl)	100.2	4.1	107.2	4.5	0.002
Pg-(Go-Go)	80.2	3.1	79.8	4.3	
Ls-(Prn-Pg)	3.5	1.8	1.2	1.6	0.001
Li-(Prn-Pg)	2.8	1.3	4.1	2.8	0.001

NS indicates not significant, $P>0.05$.

puted for each group and comparisons were performed within each sex and age group using independent Student's t-tests with two-tailed distributions. Significance was set at 5% ($P<0.05$).

Result

Attractive men had a wider upper (ex-ex) face than reference men; additionally, there was no difference between attractive men and reference men in wider middle (t-t) face and wider lower face (Go-Go). Facial height (Sn-Pg\N-Sn) was smaller in attractive men than in reference men, but the difference did not reach a significant level. Reduced upper (N-(Tr-Tl)) and middle facial depth (Sn-(Tr-Tl)), and lower facial depth (Pg-(Tr-Tl)) were observed in attractive men, see **Table 2**.

A different arrangement of facial thirds was observed in attractive men when compared with reference men. The forehead (facial upper third) occupied a significantly larger part of the face of attractive men. In contrast, the mandible (facial lower third) occupied a smaller part of the face of attractive men. The mandible- to-maxilla volume ratio was significantly reduced in all attractive men, see **Table 3**.

Differences in facial dimensions were coupled with differences in facial shape: attractive men had more acute soft tissue profiles than reference men, with smaller angles of facial convexity (n-prn-pg, li-sl-pg), see **Table 4**.

Finalist attractive men had larger lips than reference men. Attractive men had significantly larger noses than reference men.

Discussion

This study aimed to compare the three-dimension facial characteristics of attractive men with those of reference men. Although a number of studies have already evaluated the facial characteristics by using 2D images, the present study allowed new imaging techniques to record the three-dimension facial characteristics of Chinese attractive men.

The main goal of imaging is to replicate the anatomic truth to show the 3D anatomy. While classical cephalometric or photo assessments allow the two-dimensional measurement of soft tissue profile only [16], the new three-dimensional instruments produce numerical evaluations in all three spatial planes [17-21]. Now, it is still few investigations [7, 24] to

Table 3. Facial volumes estimated in attractive and reference

	G BE		G RE		P
	Mean	SD	Mean	SD	
Forehead Total, %	46.3	3.2	39.3	4.1	0.001
Maxilla Total, %	35.2	4.1	36.4	3.8	NS
Mandible Total, %	29.3	2.9	34.3	3.6	0.001
Mandible/Maxilla Total, %	83.2	6.3	94.2	7.1	0.001
Nose Total, mm ³	4.2	1.2	6.2	2.1	0.001
Upper Lip Total, mm ³	3.8	1.0	2.6	1.2	0.001
Lower Lip Total, mm ³	2.1	1.1	1.4	1.3	0.001

All values are mm³, except the mandibular to maxillary volume ratio (%). NS indicates not significant, P>0.05.

Table 4. Soft-tissue facial angles measured in attractive and reference

	BOY BE		BOY RE		P
	Mean	SD	Mean	SD	
n-prn-pg	150.2	5.2	159.3	5.0	0.001
go-pg-go	65.3	3.6	66.2	4.0	NS
sl-n-sn	10.3	2.4	9.9	2.8	NS
prn-sn-ls	129.8	4.2	130.2	4.8	NS
li-sl-pg	126.8	4.0	134.2	5.2	0.001
sn-ls-li	160.2	5.6	158.6	5.4	NS

assesse adult facial aesthetic characteristics in three dimensions and no men facial aesthetic characteristics were observed; other studies were limited to two-dimensional photographs or cephalometric films. It could be interesting to assess three-dimensionally the faces of attractive adult men, a topic that apparently was analyzed only by Farkas [25] for North American white men with data published more than 10 years ago. To our best of knowledge, this is the first study to assess three-dimensional aesthetic features of Chinese man.

Facial aesthetics is one of the principal concerns of orthodontists and maxillo-facial surgeons [4, 6, 13]. The clinician should therefore be provided with aesthetic guidelines referred to subjects of the same age, sex, and ethnic group of their patients. The guidelines should also be updated, considering the evolution of the aesthetic canons within a given society [6, 23]. These guidelines may offer useful indications for the best kind, timing, and goals of orthodontic treatment, with the best cost/benefit ratio. In the current investigation, all men were TV actors who are often believed to pos-

sess distinct aesthetic relationships, even if these do not seem to be a necessary condition for attractiveness. Therefore, they should represent what is currently considered “attractive”, “positive”, and “acceptable”.

Overall, the current results are in good agreement with previous findings on attractive white women [7]. Among the common characteristics was a relatively large forehead (facial upper third), with a relatively reduced mandible (facial lower third), and a rounded face, with a reduced surface to volume ratio. They had a more acute soft tissue profile, an increased upper facial width and middle facial depth, larger mouths, and more voluminous lips, than reference men.

Additionally, in the current Chinese men other characteristics in the facial middle third were observed, with significantly larger lip volumes (especially the upper lip), an aspect in good accord with literature references [11]. The mouth width was larger in attractive men than in reference men, as previously found in attractive women [7]. Farkas [4] also found a larger upper lip vermilion height in aesthetically pleasing women, and a larger upper vermilion arch with a more protruding upper lip in women, as compared to persons with non-attractive faces

Also, in the middle and lower third facial profile, other differences from the reference men were observed. The naso-labial angle was increased attractive men, the prominence of the soft-tissue profile, and of the maxilla relative to the mandible, were larger in attractive men. An increased facial convexity was also found in previous cephalometric studies [1, 12] for adolescents considered attractive, and preferred by patients and mothers [27].

The results on nasal volume are contrasting: Nasal volume was smaller in attractive subjects than in reference subjects, as previously found in adult women, 7 but in contrast with the patterns observed in attractive children [20]. The current finding seems to depend upon actual aesthetic preferences.

Nevertheless, some limitations should be addressed. Among the limitations of the current study is the analysis of only one of the cues that people are thought to use to determine facial attractiveness. A further limitation of the

present investigation is the assessment of only Chinese attractive men. In a different ethnic/social context, different kinds of attractive faces might be preferred, even if the good accord between the current findings and literature makes the selected facial patterns sufficiently trustworthy.

Conclusions

Attractive men had several facial characteristics that a relatively large forehead (facial upper third), with a relatively reduced mandible (facial lower third), and a rounded face, with a reduced surface to volume ratio.

Disclosure of conflict of interest

None.

Address correspondence to: Dr. Hong He, Department of Orthodontics, The State Key Laboratory Breeding Base of Basic Science of Stomatology (Hubei-MOST) & Key Laboratory of Oral Biomedicine Ministry of Education (KLOBM), School & Hospital of Stomatology, Wuhan University, Luoyu Road#237, Hongshan District, Wuhan 430079, People's Republic of China. Tel: +86-027-87686226; E-mail: drhehong@hotmail.com

References

- [1] Johnson N, Sandy J. An aesthetic index for evaluation of cleft repair. *Eur J Orthod* 2003; 25: 243-249.
- [2] Matoula S, Pancherz H. Skeletofacial morphology of attractive and nonattractive faces. *Angle Orthod* 2006; 76: 204-210.
- [3] Ferrario VF, Sforza C, Serrao G, Ciusa V, Dellavia C. Growth and aging of facial soft-tissues: a computerised three-dimensional mesh diagram analysis. *Clin Anat* 2003; 16: 420-433.
- [4] Farkas LG. Anthropometry of the attractive North American Caucasian face. In: Farkas LG, editor. *Anthropometry of the Head and Face*. 2nd edition. New York, NY: Raven Press; 1994. pp. 159-179.
- [5] Peck S, Peck L. Selected aspects of the art and science of facial esthetics. *Semin Orthod* 1995; 1: 105-126.
- [6] Auger TA, Turley PK. The female soft tissue profile as presented in fashion magazines during the 1900s: a photographic analysis. *Int J Adult Orthodon Orthognath Surg* 1999; 14: 7-18.
- [7] Ferrario VF, Sforza C, Poggio CE, Tartaglia G. Facial morphometry of television actresses compared with normal women. *J Oral Maxillofac Surg* 1995; 53: 1008-1014.
- [8] Isiksal E, Hazar S, Akyalcin S. Smile esthetics: perception and comparison of treated and untreated smiles. *Am J Orthod Dentofacial Orthop* 2006; 129: 8-16.
- [9] Mew J. Suggestions for forecasting and monitoring facial growth. *Am J Orthod Dentofacial Orthop* 1993; 104: 105-120.
- [10] Ricketts RM. Perspectives in the clinical application of cephalometrics. The first fifty years. *Angle Orthod* 1981; 51: 115-150.
- [11] Bisson M, Grobbelaar A. The esthetic properties of lips: a comparison of models and non-models. *Angle Orthod* 2004; 74: 162-166.
- [12] Edler R, Agarwal P, Wertheim D, Greenhill D. The use of anthropometric proportion indices in the measurement of facial attractiveness. *Eur J Orthod* 2006; 28: 274-281.
- [13] Kiekens RM, Maltha JC, van't Hof MA, Kuijpers-Jagtman AM. Objective measures as indicators for facial esthetics in white adolescents. *Angle Orthod* 2006; 76: 551-556.
- [14] Bascandziev I, Harris PL. In beauty we trust: children prefer information from more attractive informants. *Br J Dev Psychol* 2014; 32: 94-99.
- [15] Orsini MG, Huang GJ, Kiyak HA, Ramsay DS, Bollen AM, Anderson NK, Giddon DB. Methods to evaluate profile preferences for the antero-posterior position of the mandible. *Am J Orthod Dentofacial Orthop* 2006; 130: 283-291.
- [16] Bergman RT. Cephalometric soft tissue facial analysis. *Am J Orthod Dentofacial Orthop* 1999; 116: 373-389.
- [17] Todd SA, Hammond P, Hutton T, Cochrane S, Cunningham S. Perceptions of facial aesthetics in two and three dimensions. *Eur J Orthod* 2005; 27: 363-369.
- [18] Ferrario VF, Sforza C, Poggio CE, Cova M, Tartaglia G. Preliminary evaluation of an electromagnetic three-dimensional digitizer in facial anthropometry. *Cleft Palate Craniofac J* 1998; 35: 9-15.
- [19] Ferrario VF, Sforza C, Tartaglia GM, Sozzi D, Carù A. Three-dimensional lip morphometry in adults operated on for cleft lip and palate. *Plast Reconstr Surg* 2003; 111: 2149-2156.
- [20] Hajeer MY, Mao Z, Millett DT, Ayoub AF, Siebert JP. A new three-dimensional method of assessing facial volumetric changes after orthognathic treatment. *Cleft Palate Craniofac J* 2005; 42: 113-120.
- [21] Sforza C, Peretta R, Grandi G, Farronato G, Ferrario VF. Three-dimensional facial morphometry in patients with skeletal Class III malocclusion. A non-invasive study of soft-tissue changes before and after orthognathic

Characteristics of attractive Chinese men

- surgery. *Br J Oral Maxillofac Surg* 2007; 45: 138-44.
- [22] Soncul M, Bamber MA. Evaluation of facial soft tissue changes with optical surface scan after surgical correction of Class III deformities. *J Oral Maxillofac Surg* 2004; 62: 1331-1340.
- [23] Kau CH, Richmond S, Incrapera A, English J, Xia JJ. Threedimensional surface acquisition systems for the study of facial morphology and their application to maxillofacial surgery. *Int J Med Robot* 2007; 3: 97-110.
- [24] Ferrario VF, Sforza C, Poggio CE, Colombo A, Tartaglia G. The relationship between facial 3-D morphometry and the perception of attractiveness in children. *Int J Adult Orthodon Orthognath Surg* 1997; 12: 145-152.
- [25] Farkas LG. Anthropometry of the attractive North American Caucasian Face. In: Farkas LG, editor. *Anthropometry of the Head and Face*. 2nd edition. New York, NY: Raven Press; 1994. pp. 159-179.
- [26] Miner RM, Anderson NK, Evans CA, Giddon DB. The perception of children's computer-imaged facial profiles by patients, mothers and clinicians. *Angle Orthod* 2007; 77: 1034-1039.
- [27] Fink B, Grammer K, Mitteroecker P, Gunz P, Schaefer K, Bookstein FL, Manning JT. Second to fourth digit ratio and face shape. *Proc Biol Sci* 2005; 272: 1995-2001.