

Original Article

One stage laminoplasty and posterior herniotomy for the treatment of myelopathy caused by cervical stenosis with cervical disc herniation

Bin Yue, Bohua Chen, Xue-Xiao Ma, Yong-Ming Xi, Hong-Fei Xiang, You-Gu Hu, Guoqing Zhang

Department of Spine Surgery, The Affiliated Hospital of Medical College, Qingdao University, Qingdao, P. R. China

Received December 23, 2014; Accepted February 12, 2015; Epub June 15, 2015; Published June 30, 2015

Abstract: The aim of the study was to introduce a method of one stage laminoplasty and posterior herniotomy for myelopathy caused by cervical stenosis with cervical disc herniation and to evaluate the clinical efficacy of this surgery. From 1999 to 2008, 18 patients with myelopathy caused by cervical stenosis with cervical disc herniation who underwent this procedure were included. The average age was 63 years (range 48-74 years), and the average follow-up period was 46 months (range 3-108 months). Neurologic status was evaluated using the JOA scoring system. Neurological symptoms improvement was seen in all patients after surgery. The average JOA score was 14.22 ± 1.86 by final follow-up, which was higher than preoperative values ($P < 0.01$), and the average improvement in neurological function was 76.63%. Neurologic examination showed that excellent results had been obtained by 10 patients, good results by 8 patients, with no fair or poor results. 2 patients developed cerebrospinal fluid leakage after surgery and recovered during the follow-up period. One patient with cervical disc herniation developed postoperative C5 palsy on the axle side on the third day after surgery. She completely recovered by 1 month after surgery. No other patients experienced postoperative neurologic complications. Complete anterior and posterior decompression of the spinal cord was achieved after surgery. We concluded that one stage laminoplasty and posterior herniotomy is an effective, reliable, and safe procedure for the treatment of myelopathy caused by cervical stenosis with cervical disc herniation.

Keywords: Cervical disc herniation, cervical stenosis, myelopathy, laminoplasty, herniotomy

Introduction

Operative treatment of cervical spinal stenosis remains controversial [1]. Several options are commonly used, including anterior cervical corpectomy and fusion (ACCF) [2, 3], anterior cervical discectomy and fusion (ACDF) [4, 5], and posterior laminoplasty with or without internal fixation [6]. However, there are limitations with these options [7, 8]. On the other hand, posterior laminoplasty is a relatively simple operation, which could preserve cervical mobility with fewer postoperative complications; therefore, posterior laminoplasty has become one of the most effective approaches for multilevel cervical spinal stenosis.

ACDF introduced by Since Robinson and Smith [9] is a widely accepted surgical procedure for cervical disc herniation because it is technically relatively easy to perform and provides excellent surgical outcomes [10]. However, when

cervical spinal stenosis is accompanied by cervical disc herniation, nerve compression cannot be completely released regardless of whether anterior cervical discectomy or laminoplasty is performed. Complicated anterior and posterior procedures (one or phases) may decompress effectively, but it will inevitably increase the risk of surgical trauma and the burden of financial costs. The aim of our study was to introduce a method of one stage laminoplasty and posterior herniotomy for cervical spinal stenosis associated with cervical disc herniation and assess the clinical efficacy and safety of our surgical method.

Patients and methods

Patients

The study was approved by the ethics committee of the Affiliated Hospital of Medical College, Qingdao University, China, and written informed

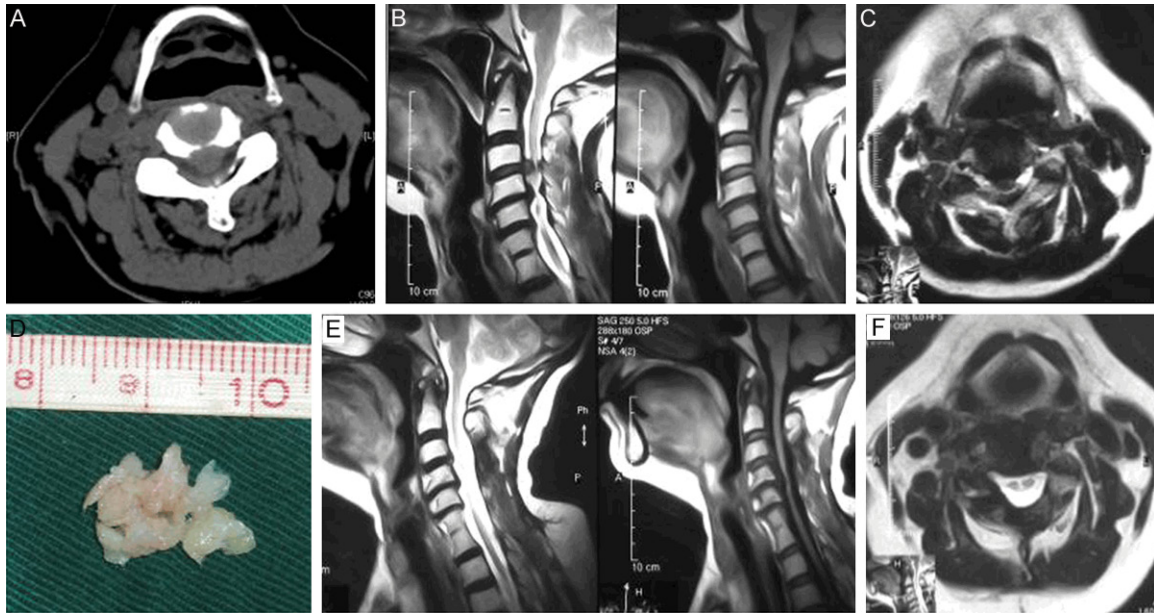


Figure 1. A: With CT image showing C3/4 disc herniation; B: MR image showing cervical stenosis associated with C3/4 disc herniation; C: MR scan showing C3/4 disc herniation; D: Posterior removed C3/4 disc fragments; E: MR scan showing complete anterior and posterior decompression of spinal cord after surgery; F: Postoperative MR image showing the complete removal of C3/4 protruded disc fragments.

consent was obtained from all subjects. From 1999 to January 2008, 18 patients with cervical spinal stenosis accompanied by cervical disc herniation who underwent one stage open-door laminoplasty and posterior herniotomy were included. The patients consisted of 7 males and 11 females. The average age was 63 years (range, 48-74 years). Of the 18 patients, 12 cases had central cervical disc herniation associated with cervical spinal stenosis, and 6 cases had paracentral cervical disc herniation associated with cervical spinal stenosis. Cervical disc herniation were observed at C3/4 (6 cases), C4/5 (4cases), C5/6 (7cases) and C6/7 (1case). CT scan and MR imaging showed interruption of subarachnoid cerebrospinal fluid and spinal cord compression (**Figures 1A-C** and **2A-C**). All patients had cervical spinal cord compression symptoms.

Surgical techniques

After endotracheal intubation and the induction of general anesthesia, the patient was placed in the prone position. Through a neck midline incision (C3-7), the paraspinal muscles are divided bilaterally, and then exposed spines are removed. Expansive (C3-C7) open door laminoplasty was carried out. Bleeding in epidural venous plexus was stopped by bipolar coagula-

tion and hemostatic cotton pads. Dural sac was gently retracted medially and prolapsed disc was observed on anterolateral side of dural sac. Herniated disc tissues were removed with nerve hook, microrongeur and small curet (**Figures 1D** and **2D**). Routine drainage was placed as. Use of somatosensory evoked potential monitoring improved surgical safety. In this operation, the key point of our surgical technique was to remove the prolapsed disc tissue without entering the intervertebral space.

Follow-up and medical evaluation

All patients were followed up for an average of 46 months, ranging from 3 to 108 months. During that follow up period, the evaluation of neurologic function was based on the JOA standard (17 score method). The recovery rate was calculated as follows: recovery rate (%) = (post-operative score - preoperative score)/(17 - preoperative score) × 100. Besides, MRI images were taken of some patients to measure the extent of decompression (**Figures 1E, 1F** and **2E, 2F**). Any possible complications such as neurovascular injury, infection, cerebrospinal fluid leakage, and palsy were all recorded at follow-up period.

Efficacy of one stage laminoplasty and posterior herniotomy for myelopathy

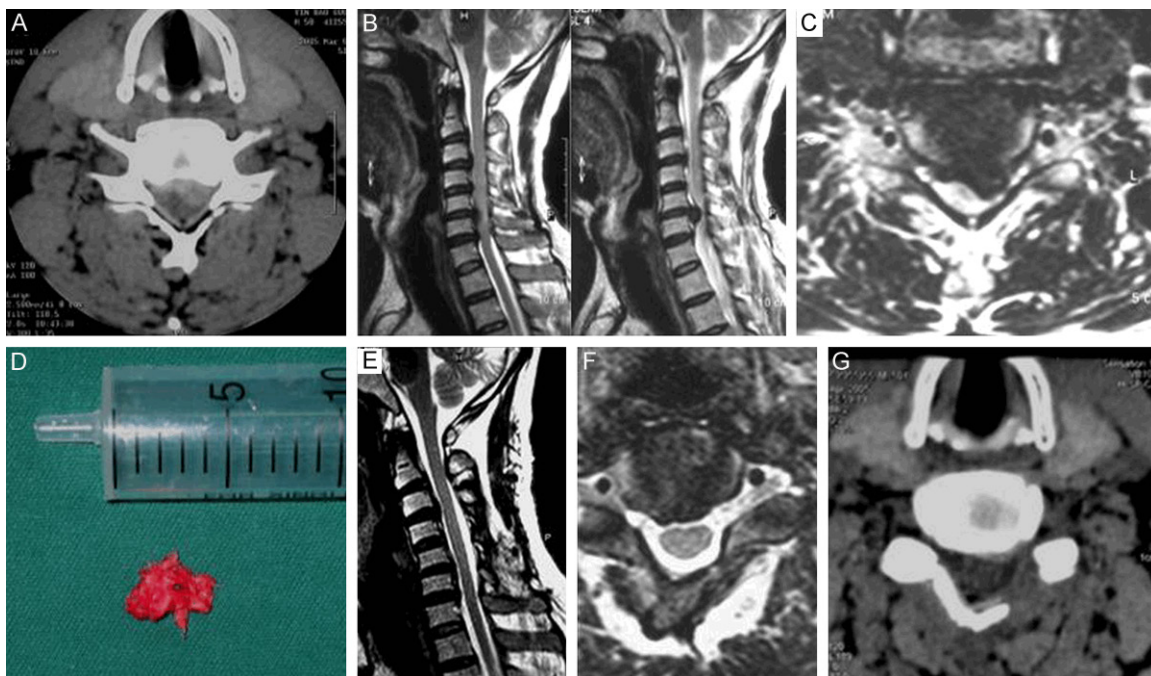


Figure 2. A: CT scan showing C5/6 disc herniation; B: MR image showing cervical stenosis associated with C5/6 disc herniation; C: MR image showing C5/6 disc herniation; D: Posterior removed C5/6 disc fragments; E: MR image showing complete anterior and posterior decompression of spinal cord after surgery; F: Postoperative MRI scan showing complete removal of C5/6 protruded disc fragment; G: Postoperative CT scan showing complete removal of C5/6 protruded disc fragments.

Statistical analysis

All analyses were performed using SPSS 13.0 software (SPSS, Chicago, IL, USA).

Data were expressed as means and standard deviations. Student's paired *t*-test was used for statistical comparison of the data, a *P*-value of less than 0.01 being considered to indicate statistical significance.

Results

Neurological symptoms improvement was seen in all patients after surgery. The average JOA score was 14.22 ± 1.86 by final follow-up, which was higher than preoperatively value (6.72 ± 2.42) ($P < 0.01$), and the average improvement in neurological function was 76.63%. Neurologic examination showed that excellent results had been obtained by 10 patients, good results by 8 patients, with no fair or poor results. 2 patients developed cerebrospinal fluid leakage after surgery and recovered on the postoperative 2 and 5 days, respectively. Only one patient with cervical disc herniation developed postoperative C5 palsy on the axle side; this complica-

tion developed on the third day after surgery. She completely recovered by 1 month after surgery. No other patients experienced postoperative neurologic complications. Postoperative MR images showed that satisfactory anterior and posterior decompression of the spinal cord was seen in all patients (**Figures 1E, 1F and 2E-G**).

Discussion

Cervical disc herniation is usually treated by anterior discectomy and fusion. Cervical spinal stenosis is often treated by laminoplasty. However, when multisegment cervical stenosis was complicated with cervical disc herniation, none of the single anterior or posterior surgery could decompress thoroughly. In this study, we introduced a new one stage laminoplasty and posterior herniotomy for myelopathy caused by cervical stenosis with cervical disc herniation evaluated the clinical efficacy of this procedure. At the time of final follow-up, all patients had complete release, and satisfactory decompression. Significant improvement in neurological function was seen in all patients after surgery. Furthermore, satisfactory three-dimensional

Efficacy of one stage laminoplasty and posterior herniotomy for myelopathy

CT and MR images were obtained from every patient. Finally, an uneventful recovery was seen in all patients, with few complications. The findings suggested that this procedure is a safe and effective alternative in the treatment of multisegment cervical stenosis with cervical disc herniation.

In this surgical method, exposure of the prolapsed disc brings a certain degree of technical difficulty and risk, especially for disc herniation located centrally. In contrast to the lumbar spine, the nerve root is shorter and runs more horizontally in the cervical spine. In the dural sac, there is the spinal cord rather than the cauda equina, which retracts gently. As far as this procedure was concerned, intraoperative spinal cord traction injury can be avoided completely [10-12]. Anterolateral dural venous plexus hemorrhage was another difficulty. Usually bipolar coagulation and cotton pad compression are helpful.

In our series, one patient with cervical disc herniation developed postoperative C5 palsy on the axile side and completely recovered by 1 month after surgery. In this patient, the disc herniation was well removed, and the C5 root was completely decompressed. This palsy occurred not immediately, but on the third postoperative day. Therefore, it is not considered that the C5 root was injured by technical problems during surgery. Anyway, the cause of this transient C5 palsy is unknown, and another mechanism of postoperative C5 palsy may be concealed. Cerebrospinal fluid leaks after lumbar spine surgery are among the most commonly reported complications. Many authors have mentioned the risk of meningitis, spinocutaneous fistula, or pseudomeningocele associated with cerebrospinal fluid leaks in the cervical spine [13-15]. In the literature, the incidence of cerebrospinal fluid leakage ranges from 5.7% to 31.8% [16-18]. In our series, postoperative cerebrospinal fluid leakage was observed in 2 patients, our incidence of 11% cerebrospinal fluid leakage is favorable compared with rates reported in the literature.

Short-term follow-up results showed no adjacent segment diseases [10-12]. In our cases, the adjacent segment disease was not observed within the 46 months of follow-up. Considering this surgery were non-fusion surgeries, compact on adjacent segments was little. However, long-term follow up study is still

needed. There may be a concern about the recurrence of disc herniation because only cervical disc herniation was removed without entering intervertebral space. In this study, no patient experienced recurrence of clinical symptoms or disc herniation as of the last follow-up, which was consistent with the previous reports [10-12]. Fager [19] performed a posterior discectomy for the treatment of a group of patients over 800 cases with lateral disc herniation, they found no recurrent disc herniation. This was because the cervical disc is smaller and there was little disc tissue remnants after the removal of prolapsed discs. The remaining tissue in vertebral space cannot develop prolapse again and compress the spinal cord or nerve roots.

Conclusion

Single laminoplasty with herniotomy is an effective, reliable, and safe operation for the treatment of cervical stenosis associated with cervical disc herniation. Further studies with a larger number of patients and a longer follow-up period are still needed to further support the efficacy of our technique.

Disclosure of conflict of interest

None.

Address correspondence to: Dr. Guoqing Zhang, Department of Spine Surgery, The Affiliated Hospital of Medical College, Qingdao University, Laoshan District, 59 Haier Road, Qingdao 266101, P. R. China. Tel: +86-18661808720; E-mail: zhangguoqing66@yeah.net

References

- [1] Xu ZW and Lun DX. Surgical management of multilevel cervical spinal stenosis and spinal cord injury complicated by cervical spine fracture. *J Orthop Surg Res* 2014; 9: 1-6.
- [2] Gao R, Yang L, Chen H, Liu Y, Liang L and Yuan W. Long term results of anterior corpectomy and fusion for cervical spondylotic myelopathy. *PLoS One* 2012; 7: e34811.
- [3] Li Z, Guo Z, Hou S, Zhao Y, Zhong H, Yu S and Hou T. Segmental anterior cervical corpectomy and fusion with preservation of middle vertebrae in the surgical management of 4-level cervical spondylotic myelopathy. *Eur Spine J* 2014; 23: 1472-1479.
- [4] Auffinger BM, Lall RR, Dahdaleh NS, Wong AP, Lam SK, Koski T, Fessler RG and Smith ZA.

Efficacy of one stage laminoplasty and posterior herniotomy for myelopathy

- Measuring surgical outcomes in cervical spondylotic myelopathy patients undergoing anterior cervical discectomy and fusion: assessment of minimum clinically important difference. *PLoS One* 2013; 8: e67408.
- [5] Song KJ, Lee KB and Song JH. Efficacy of multilevel anterior cervical discectomy and fusion versus corpectomy and fusion for multilevel cervical spondylotic myelopathy: a minimum 5-year follow-up study. *Eur Spine J* 2012; 21: 1551-1557.
- [6] Lu J, Wu X, Li Y and Kong X. Surgical results of anterior corpectomy in the aged patients with cervical myelopathy. *Eur Spine J* 2008; 17: 129-135.
- [7] Wada E, Suzuki S, Kanazawa A, Matsuoka T, Miyamoto S and Yonenobu K. Subtotal corpectomy versus laminoplasty for multilevel cervical spondylotic myelopathy: a long-term follow-up study over 10 years. *Spine* 2001; 26: 1443-1447.
- [8] Do Koh Y, Lim TH, You JW, Eck J and An HS. A biomechanical comparison of modern anterior and posterior plate fixation of the cervical spine. *Spine* 2001; 26: 15-21.
- [9] Robinson RA. Anterolateral cervical disc removal and interbody fusion for the cervical disc syndrome. *Bull John Hopkins Hosp* 1955; 96: 223-224.
- [10] Fujimoto Y, Baba I, Sumida T, Tanaka N, Oka S and Kawagoe H. Microsurgical transdural discectomy with laminoplasty: new treatment for paracentral and paracentroforaminal cervical disc herniation associated with spinal canal stenosis. *Spine* 2002; 27: 715-721.
- [11] Fager CA. Posterolateral approach to ruptured median and paramedian cervical disk. *Surg Neurol* 1983; 20: 443-452.
- [12] Sasai K, Saito T, Ohnari H, Yamamoto T, Kasuya T, Wakabayashi E, Akagi S and Iida H. Microsurgical posterior herniotomy with en bloc laminoplasty: alternative method for treating cervical disc herniation. *J Spinal Disord Tech* 2005; 18: 171-177.
- [13] Fountas KN, Kapsalaki EZ and Johnston KW. Cerebrospinal fluid fistula secondary to dural tear in anterior cervical discectomy and fusion: case report. *Spine* 2005; 30: E277-E280.
- [14] Narotam PK, José S, Nathoo N, Talyon C and Vora Y. Collagen matrix (DuraGen) in dural repair: analysis of a new modified technique. *Spine* 2004; 29: 2861-2867.
- [15] Cammisa FP Jr, Girardi FP, Sangani PK, Parvataneni HK, Cadag S and Sandhu HS. Incidental durotomy in spine surgery. *Spine* 2000; 25: 2663-2667.
- [16] Bednarík J, Kadanka Z, Vohánka S, Stejskal L, Vlach O and Schröder R. The value of somatosensory-and motor-evoked potentials in predicting and monitoring the effect of therapy in spondylotic cervical myelopathy: prospective randomized study. *Spine* 1999; 24: 1593.
- [17] Belanger TA, Roh JS, Hanks SE, Kang JD, Emery SE and Bohlman HH. Ossification of the posterior longitudinal ligament Results of anterior cervical decompression and arthrodesis in sixty-one North American patients. *J Bone Joint Surg* 2005; 87: 610-615.
- [18] Chen Y, Chen D, Wang X, Lu X, Guo Y, He Z and Tian H. Anterior corpectomy and fusion for severe ossification of posterior longitudinal ligament in the cervical spine. *Int Orthop* 2009; 33: 477-482.
- [19] Fager CA. Management of cervical disc lesions and spondylosis by posterior approaches. *Clin Neurosurg* 1976; 24: 488-507.