

## Case Report

# Hepatic sarcoidosis mimicking liver cancer

Kang-Kang Yu<sup>1</sup>, Han-Qiu Liu<sup>2</sup>, Zhong-Wen Zhou<sup>3</sup>, Ming-Quan Chen<sup>1</sup>

<sup>1</sup>Department of Infectious Diseases, Huashan Hospital, Fudan University, Shanghai, China; <sup>2</sup>Department of Radiology, Huashan Hospital, Fudan University, Shanghai, China; <sup>3</sup>Department of Pathology, Huashan Hospital, Fudan University, Shanghai, China

Received February 13, 2015; Accepted May 25, 2015; Epub June 15, 2015; Published June 30, 2015

**Abstract:** We present a case of a 50-year-old woman with multiple occupations in the liver. Liver cancer was strongly suspected initially according to the results of imaging examination. However, sarcoidosis was confirmed subsequently by liver biopsy, so methylprednisolone was then prescribed and the patient showed favorable therapeutic response. This case report suggests that hepatic mass in Chinese patients without any history of hepatitis virus infection should be carefully investigated before giving a diagnosis of liver cancer. The report also reminds us that the clinical presentation of sarcoidosis is complex and involvement of a single extra-pulmonary organ should not be ignored.

**Keywords:** Sarcoidosis, liver, cancer

### Introduction

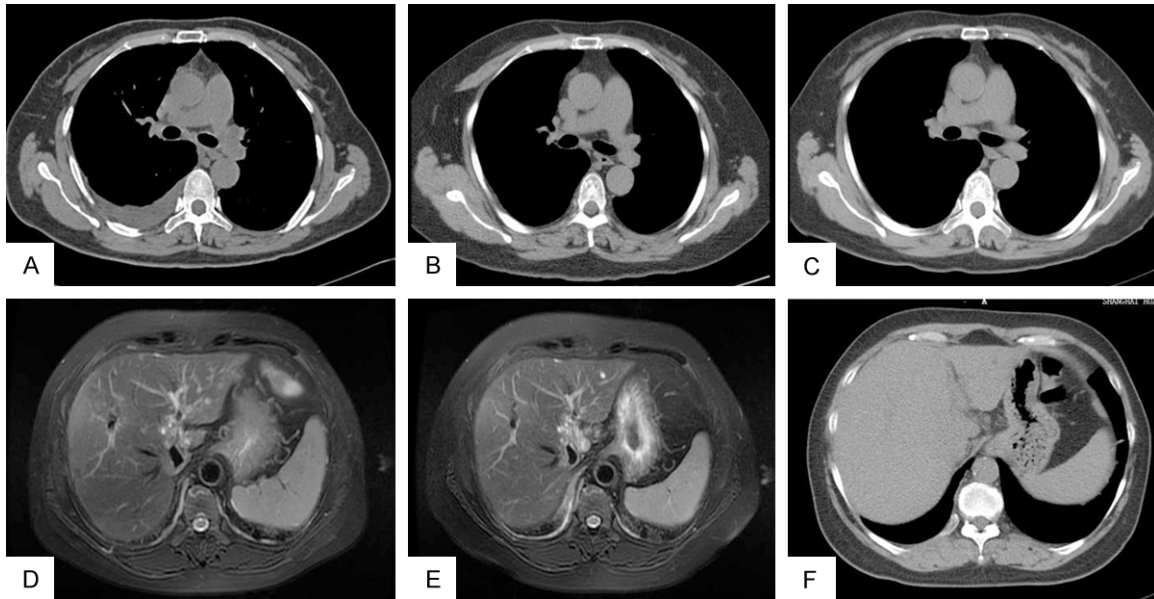
Sarcoidosis is a multisystem granulomatous disease with no identified causes and can affect any organ, especially the lung (up to 90% of cases) [1]. We describe a woman with sarcoidosis presented with involvement of the liver rather than the lung (**Figure 1**). Sarcoidosis is usually seen in young and middle aged adults and is more often observed in African-Americans and Scandinavians [1, 2]. Patients present mainly with non-productive cough, breathlessness, fatigue, skin erythema nodosum, and lymphadenopathy and so on [1].

### Case report

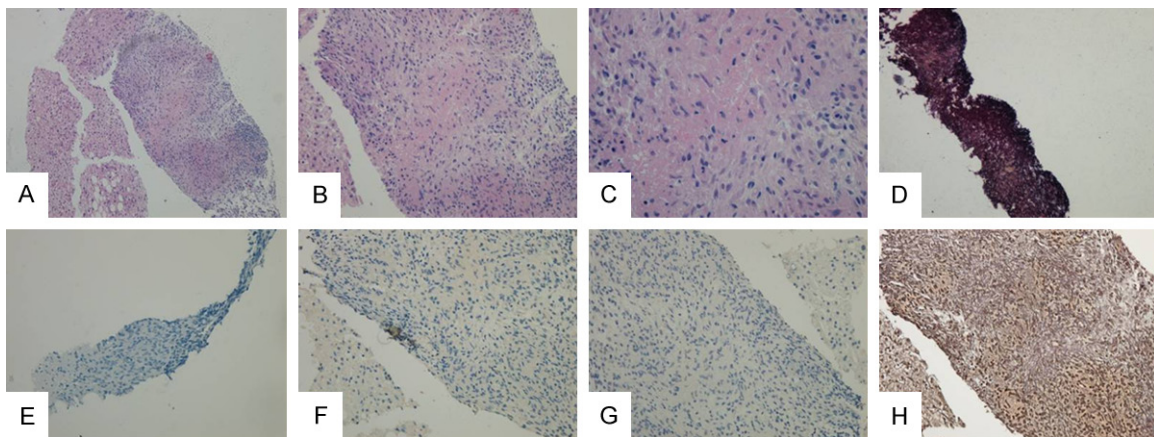
A 50-year-old woman visited our hospital for multiple occupations in the liver. The occupations were found accidentally by abdominal B type ultrasonography during routine medical check-up and the patient experienced a weight loss of 5 kg within 7 months. The patient had no underlying diseases other than Behcet's Disease, which was diagnosed when she was 21 and the disease had no sign of recurrence to date after therapy. The patient had a history of recurrent mild to moderate fever during the past 5 years, but had no known history of active

tuberculosis. Given these conditions, tests including TSPOT-TB, blood culture, hepatitis viruses, autoantibodies and tests for metabolic liver diseases were engaged when she presented at another facility 6 months earlier, but all the tests were negative. For laboratory studies, increased activity of angiotensin converting enzyme was detected. Tumor markers detection showed elevated CA125 and CA19-9 levels, while others, including AFP, were normal. Based on these findings, the possibilities of TB or AILD were almost ruled out, and malignancy became the focus. Magnetic resonance imaging (MRI) was then performed and indicated hepatic malignancies (**Figure 1D**). Therefore a preliminary diagnosis of liver cancer was made. To confirm the etiology, biopsies of the liver were taken. Histological investigation showed granulomatous inflammation (non-caseating granuloma), staining with Periodic acid-Schiff, Ziehl-Neelsen and Gomori Methenamine Silver revealed no acid-fast bacilli or fungi or other organisms (**Figure 2**). Based on above findings, the diagnosis of sarcoidosis was strongly favored. The patient was informed of the results and then commenced therapy on a dose of 24 mg oral methylprednisolone daily. Three weeks later, the repeated MRI revealed shrunken lesions (**Figure 1E**), thus methylprednisolone

## Sarcoidosis mimicking liver cancer



**Figure 1.** A-C: Chest CT scan on presentation, 3 weeks and 5 months after therapy. In addition to pleural effusion in the first examination, there was no significant lesion in the pulmonary or mediastinal and hilar lymphadenopathy. D-F: Synchronous liver magnetic resonance imaging (MRI) and abdominal CT scan were performed to better characterize the liver lesions. D: The liver magnetic resonance imaging on presentation demonstrated multiple hyperintensity lesions on T2-weighted images. E: 3 weeks after therapy revealed decreased size and number of the lesions. F: Abdominal CT scan on 5 months after therapy showed no obvious nodules.



**Figure 2.** Histological features of the hepatic nodules. A-C: Hematoxylin and eosin stain (H&E,  $\times 100$ ,  $\times 200$ , and  $\times 400$ ) showed non-caseating granuloma. D: Gomori methenamine silver stain (GMS,  $\times 200$ ) showed no evidence of fungi infection. E: Periodic acid-Schiff stain (PAS,  $\times 200$ ) showed carcinoma. F: Stain for HBsAg ( $\times 200$ ) showed negative. G: Stain for HBcAg ( $\times 200$ ) showed negative. H: Reticular fiber stain revealed no vascular channels.

was reduced to 16 mg per day. After 5 months of treatment, the lesions almost disappeared according to the results of abdominal CT (**Figure 1F**), so methylprednisolone was reduced to 8 mg per day for maintenance.

### Discussion

There is no cure for sarcoidosis and corticosteroids are the standard treatment [1, 2]. In addition,

there are no guidelines on whether, when, and how treatment should be started available [2]. No dose or duration of corticosteroids with optimal efficacy is available [1]. However, patients with sarcoidosis generally possess a favorable prognosis [1, 3]. All in all, this case study was intriguing for that sarcoidosis developed exclusively in liver is really rare. The patient was found only with the involvement of the liver, and without the most frequently

## Sarcoidosis mimicking liver cancer

involved lung and other organs or systems made it difficult to distinguish from hepatic tumor based on the results of MRI and computed tomography (CT). Sarcoidosis was finally diagnosed according to the results of liver biopsy, and our patient showed favorable response to treatment. Now the patient is well and still in follow-up with no evidence of recurrence.

In conclusion, this case highlights that the complicated presentation of sarcoidosis (such as a hepatic tumor-like presentation clinically) do bring difficulties to clinical diagnosis. However, due to the good prognosis of sarcoidosis, careful investigation therefore should be taken, thus an unnecessary nightmare could be avoided, as in this case.

### Acknowledgements

We acknowledge Wei-Wei Wang (MD) for her kindly assistance in image data collecting.

### Disclosure of conflict of interest

None.

**Address correspondence to:** Dr. Ming-Quan Chen, Department of Infectious Diseases, Huashan Hospital, Fudan University, 12 Middle Urumqi Road, Shanghai 200040, P. R. China. Tel: +86-21-52887965; Fax: +86-21-62480170; E-mail: mingquanchen@fudan.edu.cn

### References

- [1] Dempsey OJ, Paterson EW, Kerr KM and Denison AR. Sarcoidosis. *BMJ* 2009; 339: b3206.
- [2] Valeyre D, Prasse A, Nunes H, Uzunhan Y, Brillet PY and Muller-Quernheim J. Sarcoidosis. *Lancet* 2014; 383: 1155-1167.
- [3] Macfarlane JT. Prognosis in sarcoidosis. *Br Med J (Clin Res Ed)* 1984; 288: 1557-1558.