

Original Article

Pemetrexed induced a durable response in heavily pretreated metastatic extramammary Paget's disease

Chao Wu^{1*}, Hai-Tao Tao^{1*}, Fang-Fang Li², Shang-Wu Huang³, Wei-Wei Dong¹, Jin-Liang Wang¹, Yi Hu¹, Fang Li¹

¹Department of Oncology, Chinese PLA General Hospital, 28 Fuxing Road, Haidian District, Beijing 100853, China; ²Department of Health Academy, Chinese PLA General Hospital, 28 Fuxing Road; ³Department of Internal Medicine, No.1 Rongjun Hospital of Guangdong Province, Xingangxi Road, Haizhu District, Guangzhou, 510260, China. *Equal contributors.

Received March 13, 2015; Accepted May 20, 2015; Epub June 15, 2015; Published June 30, 2015

Abstract: Purpose: Extramammary Paget's disease (EMPD) is a rare neoplasm with only a limited number of cases reported in the literature. Little was known about the availability of systemic chemotherapy for metastatic EMPD. Methods: We report one case of heavily pretreated EMPD with multiple organ metastases and successfully treated by pemetrexed. Result: The tumor was progression after multi-line therapy including erlotinib, radiotherapy, combined chemotherapy and radioactive particles implantation. Pemetrexed monotherapy was applied and progression free survival of more than 5 months with partial remission (PR) response was achieved. Only 1 time of grade 3 neutropenia was observed during the pemetrexed chemotherapy. Conclusion: Due to the significant response and tolerability in the present case, pemetrexed monotherapy was recommended as a potent candidate for patients with advanced EMPD.

Keywords: Pemetrexed, extramammary paget's disease, cutaneous adenocarcinoma

Introduction

Extramammary Paget's disease (EMPD) is a rare cutaneous adenocarcinoma generally affecting the genital region [1]. The disease is usually diagnosed as carcinoma in situ, and only rarely invades into the dermis to be metastatic via the lymphatic system. Although local disease can be cured by wide local excision, the prognosis of patients with metastases is extremely poor. Because of the limited morbidity, little was known about the availability of systemic chemotherapy for advanced EMPD [2, 3]. Here, we present an unusual case of heavily pretreated EMPD with multiple organ metastases and was successfully treated by pemetrexed.

Case presentation

A 76-years old man had a six-month history of slowing growing vulvar rash and pruritus. He received biopsy on February 2010. The pathology showed a possible of Extramammary Paget's disease (EMPD), so resection of vulvar

mass was applied on March 2010. However, the resection was incomplete, three of the four resection margins were positive. The tumor nodule was 1.8 × 1.8 × 1.0 cm on a skin lesion of 6.0 × 8.0 cm and Paget cells was present in the dermis (**Figure 1A**). Immunohistochemical staining for carcinoembryonic antigen (CEA) and cytokeratin (CK) were strongly positive while S-100 protein, human melanoma black 45 (HMB 45) and Melan-A was negative. The human epidermal growth factor receptor-2 (HER2) was positive (3+ immunostaining intensity, **Figure 1B**). The immunohistochemistry (IHC) supported the diagnoses of Paget's disease. He received extended operation 2 weeks later, but didn't receive adjuvant chemotherapy or radiotherapy. The tumor was recurred 5 months after the surgery. Computed tomography (CT) of the pelvic showed multiple enlarged lymph nodes beside iliac artery and right inguinal, with hypermetabolism on Positron emission tomography (PET) scan. The serum CEA was up to 34 ng/ml (reference value: 0-5 ng/ml). He received radiotherapy with a dose of 50 Gy. Tumor mass was a little narrowed and CEA

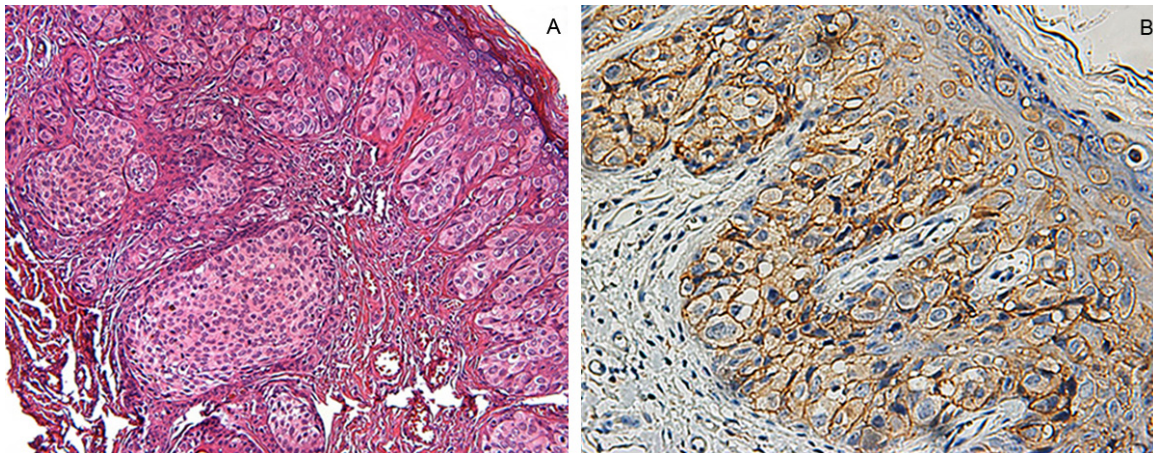


Figure 1. Histological and Immunohistochemical assessment of EMPD. A: H&E staining indicated Paget cells was present in the dermis (original magnification $\times 200$); B: The carcinoma showed 3+ immunostaining intensity for Her-2 (original magnification $\times 400$).

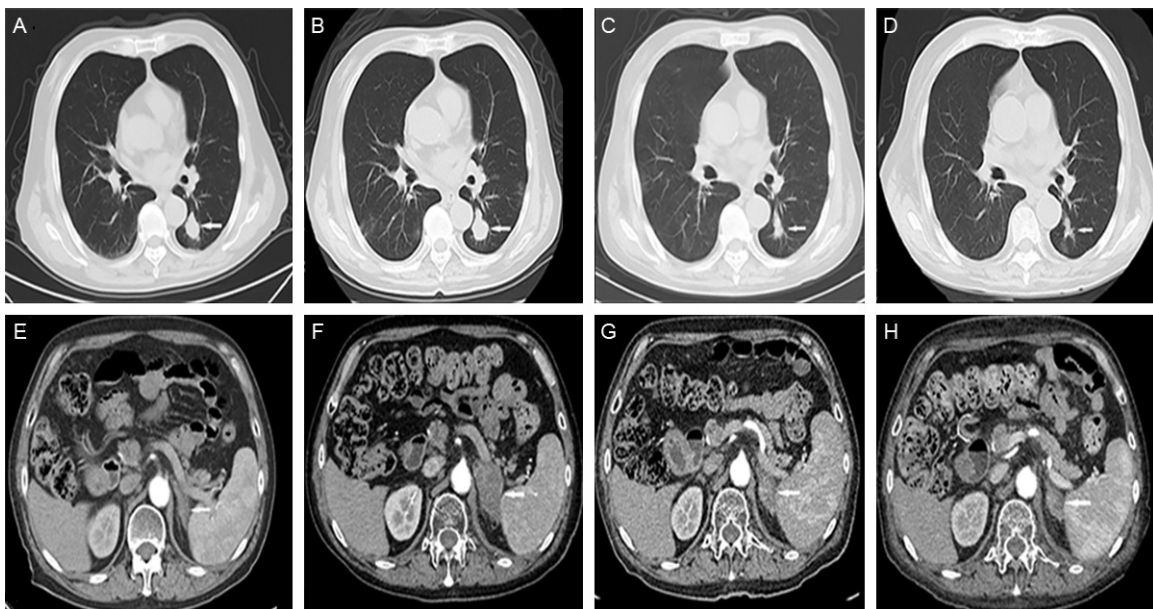


Figure 2. Response evaluation. A, E: Lung metastases and no adrenal gland metastases identified by CT on January 2014; B, F: Lung metastases progressed and left adrenal gland metastases newly identified on March 2014, before the pemetrexed treatment; C, G: After 2 cycles chemotherapy, both lesions were remission on April 2014; D, H: The tumor was still partial remission after 6 cycles chemotherapy.

was decreased (17 ng/ml) after the radiotherapy. But on June 2012, pelvic CT show the lymph nodes was enlarged again with increasing serum CEA (42 ng/ml). Elotinib was given for 3 months but with little effect, only a temporary decrease of CEA.

The patient was sent to our hospital for further treatment on October 2012. The pelvic CT showed lymph nodes was enlarged compared

with June and CEA increased to 68 ng/ml. From October 2012 to march 2013, a total of 6 cycles combined chemotherapy of docetaxel and S-1 were given. The clinical response evaluation was stable disease (SD) with a little narrowed. Then he received sequential radiotherapy of the visible Pelvic lymph node with a total dose of 60 Gy. After the chemoradiotherapy, the CEA decreased to 15.67 ng/ml on October 2013, but increased to 239.8 ng/ml 3 months

later. CT showed retroperitoneal enlarged lymph nodes was developed and merged with each other, forming several large lesions. The patients received radioactive particles implantation of the retroperitoneal tumor on November 2013. Two months later, the serum CEA increased to 417.6 ng/ml and three new metastases lesions was identified by the lung CT (max 2.52×2.07 cm, **Figure 2A**). However, the patient refused to further treatment because of the poor physical condition. He rested for 2 months, the tumor got progression again. The lung metastasis was enlarged (max 3.11×2.33 cm, **Figure 2B**) and new metastasis of left adrenal gland was identified (4.75×2.66 cm, **Figure 2E, 2F**), the serum CEA was 539.7 ng/ml. Since no standard treatment regimen was available, pemetrexed was given under the patient's informed consent. Pemetrexed (500 mg/m^2) was given through intravenous drip on day 1 of a 21-day cycle on 10th March and 3rd April 2014. Grade 3 neutropenia was observed in the first cycle and was managed by G-CSF successfully. The CEA decreased to 226.1 ng/ml after the first cycle chemotherapy. Two cycles later, the lung CT showed the metastasis tumor was decreased obviously (max: 1.7×1.1 cm **Figure 2C**), the abdominal CT show the same result, the metastasis of the left lung adrenal was decreased (max: 3.1×1.7 cm **Figure 2G**) and the retroperitoneal lymph nodes was decreased too. The response was partial remission (PR). So another 4 cycles chemotherapy was applied, the evaluation after 4 and 6 cycle chemotherapy was still PR (**Figure 2D, 2H**). No grade 3/4 toxicity was observed again. Up to the last follow-up on August 20th, the patient has got a progression free survival of 5 months with PR response.

Discussion

EMPD is a rare neoplasm that accounts for 6.5% of all cases of Paget's disease. It affects predominantly patients aged between 65 and 70 years, 90% of them being older than 50 years [4]. The primary treatment of EMPD is surgical excision, others including chemotherapy, radiotherapy, laser treatment and imiquimod cream are also used but only in a few cases [5, 6]. However, the invasion of the epidermis by EMPD often exceeds largely the visible limits of the lesions, accounting for the

difficulty in obtaining complete excision and the high frequency of recurrences [7, 8] reported that visceral metastasis occurred in 13 of 76 patients (17%), and that 10 of these 13 patients (77%) died of the disease [5, 8]. reported that 8 of 30 patients with radical surgery (26.7%) got recurrence within 3 years, and 4 of them exhibited distant metastasis. The prognosis of patients with metastases is extremely poor [5]. No recommended treatment was conducted to those patients with metastasis disease till now. The limited reports on successful chemotherapies for advanced EMPD have included docetaxel, low-dose 5-FU/cisplatin, and combination chemotherapy with mitomycin C, epirubicin, vincristine, cisplatin and 5-FU [2, 3, 9]. Little was known about the treatment after the tumor progression of the first-line chemotherapy.

In this case, the patients had received multi-line therapy including target therapy of erlotinib, 2 times of radiotherapy, 1 time of radioactive particles implantation and 6 cycles chemotherapy of combined docetaxel and S-1. Both docetaxel and S-1 was reported to be effective as monotherapy in EMPD [9, 10]. However, the tumor was continually progressing. Pemetrexed is a kind of folate antimetabolites and widely used in Pleural mesothelioma and non-small cell lung cancer. Pemetrexed was well tolerated even in long course of maintenance chemotherapy [11]. Considering the poor physical condition of the patient, we choose pemetrexed monotherapy as treatment regimen. The result was unexpected good, and only 1 time of grade 3 neutropenia was observed during the chemotherapy. Due to the significant response and tolerability in the present case, we recommend pemetrexed monotherapy as a potent candidate for patients with advanced EMPD.

HER-2 protein overexpression in EMPD is common. HER2 protein overexpression (3+ immunostaining intensity) was found in 52% (12/23) while HER2 gene amplification was found in 43% (10/23) of the lesions [12]. Research shows that HER2 signaling pathway is contributed to the pathogenesis and progression of some cases of EMPD [13]. The anti-HER2 monoclonal antibody trastuzumab was used in one patient combined with paclitaxel and showed good response [14]. In our case, HER2

protein overexpression was confirmed by IHC, trastuzumab may be a back-up option in the future.

Conclusion

EMPD is a rare neoplasm; optimal chemotherapy regimen is still unknown. Due to the significant response and tolerability in the present case, we recommend pemetrexed monotherapy as a potent candidate for patients with advanced EMPD. HER-2 gene amplification may be a potential therapeutic target.

Acknowledgements

The authors thank hongwei ma and youli lv for their kindly assistance on the pathology diagnosis.

Disclosure of conflict of interest

None.

Address correspondence to: Yi Hu and Fang Li, Department of Oncology, Chinese PLA General Hospital, Beijing 100853, China. Tel: +86 13718994934; Fax: +86 1066937292; E-mail: yihudoc@yeah.net

References

- [1] Wang X, Yang W, Yang J. Extramammary Paget's disease with the appearance of a nodule: a case report. *BMC Cancer* 2010; 10: 405.
- [2] Mochitomi Y, Sakamoto R, Gushi A, Hashiguchi T, Mera K, Matsushita S, Nishi M, Kanzaki T, Kanekura T. Extramammary Paget's disease/carcinoma successfully treated with a combination chemotherapy: report of two cases. *J Dermatol* 2005; 32: 632-637.
- [3] Tokuda Y, Arakura F, Uhara H. Combination chemotherapy of low-dose 5-fluorouracil and cisplatin for advanced extramammary Paget's disease. *Int J Clin Oncol* 2015; 20: 194-7.
- [4] Kaniakakis J. Mammary and extramammary Paget's disease. *J Eur Acad Dermatol Venereol* 2007; 21: 581-90.
- [5] Chen Q, Chen YB, Wang Z, Cai ZK, Peng YB, Zheng DC, Ma LM, Yao HJ, Zhou J. Penoscrotal extramammary Paget's disease: surgical techniques and follow-up experiences with thirty patients. *Asian J Androl* 2013; 15: 508-512.
- [6] Zhang N, Gong K, Zhang X, Yang Y, Na Y. Extramammary Paget's disease of scrotum—report of 25 cases and literature review. *Urol Oncol* 2010; 28:28-33.
- [7] Zollo JD, Zeitouni NC. The Roswell Park Cancer Institute experience with extramammary Paget's disease. *Br J Dermatol* 2000; 142: 59-65.
- [8] Hatta N, Yamada M, Hirano T, Fujimoto A, Morita R. Extramammary Paget's disease: treatment, prognostic factors and outcome in 76 patients. *Br J Dermatol* 2008; 158: 313-318.
- [9] Fujisawa Y, Umebayashi Y, Otsuka F. Metastatic extramammary Paget's disease successfully controlled with tumour dormancy therapy using docetaxel. *Br J Dermatol* 2006; 154: 375-376.
- [10] Mikoshiba Y, Uhara H, Kubo H, Okuyama R. S-1 induced a durable response in metastatic extramammary Paget's disease. *J Dermatol* 2013; 40: 664-665.
- [11] Scagliotti GV, Gridelli C, de Marinis F, Thomas M, Dediu M, Pujol JL, Manegold C, San Antonio B, Peterson PM, John W, Chouaki N, Visseren-Grul C, Paz-Ares LG. Efficacy and safety of maintenance pemetrexed in patients with advanced nonsquamous non-small cell lung cancer following pemetrexed plus cisplatin induction treatment: A cross-trial comparison of two phase III trials. *Lung cancer* 2014; 85: 408-14.
- [12] Tanskanen M, Jahkola T, Asko-Seljavaara S, Jalkanen J, Isola J. HER2 oncogene amplification in extramammary Paget's disease. *Histopathology* 2003; 42: 575-579.
- [13] Ogawa T, Nagashima Y, Wada H, Akimoto K, Chiba Y, Nagatani T, Inayama Y, Yao M, Aoki I, Ikezawa Z. Extramammary Paget's disease: analysis of growth signal pathway from the human epidermal growth factor receptor 2 protein. *Hum Pathol* 2005; 36: 1273-1280.
- [14] Hanawa F, Inozume T, Harada K, Kawamura T, Shibagaki N, Shimada S. A Case of Metastatic Extramammary Paget's Disease Responding to Trastuzumab plus Paclitaxel Combination Therapy. *Case Rep Dermatol* 2011; 3: 223-227.