

Original Article

The importance of the mesh shape in preventing recurrence after Nissen fundoplication

Yusuf Tanrikulu, Fatih Kar, Boran Yalcin, Gokhan Yilmaz, Volkan Temi, Mithat Cagsar

Department of General Surgery, Zonguldak Ataturk State Hospital, Zonguldak 67100, Turkey

Received March 17, 2015; Accepted June 3, 2015; Epub June 15, 2015; Published June 30, 2015

Abstract: Gastro esophageal reflux disease (GERD) is the most common gastrointestinal disorder and often is associated with hiatal hernia (HH). Nissen fundoplication is the most common surgical treatment method. Despite surgical treatment, recurrence rate is still high. In this study, we aimed to identify the importance of the mesh shape in preventing recurrence after Nissen fundoplication. A hundred twenty two patients who operated Nissen fundoplication owing to GERD and/or HH were evaluated. Nissen fundoplication was made all patients. Patients were divided into three groups according to hiatoplasty procedure; group 1 (V-shaped mesh), group 2 (V-shaped mesh + Fibrin glue), and group 3 (special designed mesh, Kar's mesh). Groups were compared regarding intraoperative, postoperative early- and long-term complications. Mean age was 42.75 years, and male to female ratio was 1:2.98. The mean follow-up period was 27 months. There was no mortality during follow-up. The most common presenting symptom was heartburn (93.4%). There wasn't difference between groups in terms of the intraoperative complications and postoperative early-term complications. The overall recurrences rate was 4.9% and dysphagia > 3 months rate was 1.6%. No recurrence was not observed in group 3, while recurrence was observed in 4 patients in group 1 (P = 0.030). Patients should be carefully selected for surgery because complication rate is high despite successful anti-reflux surgical treatment. In this study, we have used a special designed mesh. We believe that this special designed mesh can be used safely and effectively in anti-reflux surgery because recurrence and complications were not observed.

Keywords: Crural closure, fibrin glue, gastroesophageal reflux disease, Nissen fundoplication, mesh

Introduction

Gastro esophageal reflux disease (GERD) is the most common gastrointestinal disorder and caused by chronic exposure of the mucosa of esophagus from retrograde flow of gastric juice and/or duodenal contents due to the lower esophageal sphincter and diaphragmatic crus dysfunction. Its prevalence is 25 to 27% [1]. While there are reflux esophagitis half of the patients with hiatus hernia (HH) who usually associated with acid reflux, HH is accompanied in 84% of patients with esophagitis [2]. Typical symptoms of this disease are heartburn, regurgitation, and dysphagia [3].

Treatment of the disease is planned both depending on the presence HH and reflux disease. The main stay of treatment is acid suppression with proton pump inhibitors (PPIs), but about 10% to 40% of the patients with GERD

fail to respond to this treatment [4]. For patients with typical reflux symptoms and inadequate response to PPIs surgical treatment can be an effective procedure [5]. Remission rate is about 85% to 93.5% after surgical treatment, whereas recurrence rate is about 7 to 43% [6]. After surgery of this region that enjoys a quite dynamic anatomy, recurrence is one of the most important problems. Recurrences usually occur due to over-exertion of the patients in the early postoperative period and inadequacy of surgical techniques. While causes of recurrences due to inadequacy of surgical techniques include mediastinum migration of the stomach with fundoplication due to the opening of stitches crus, left crus elongation, receiving glass shape of the stomach, opening of stitches of fundoplication, cause of recurrence due to over-exertion is repetitive diaphragm stress due to the mechanics of respiration. Therefore,

Fundoplication and prevention of recurrence

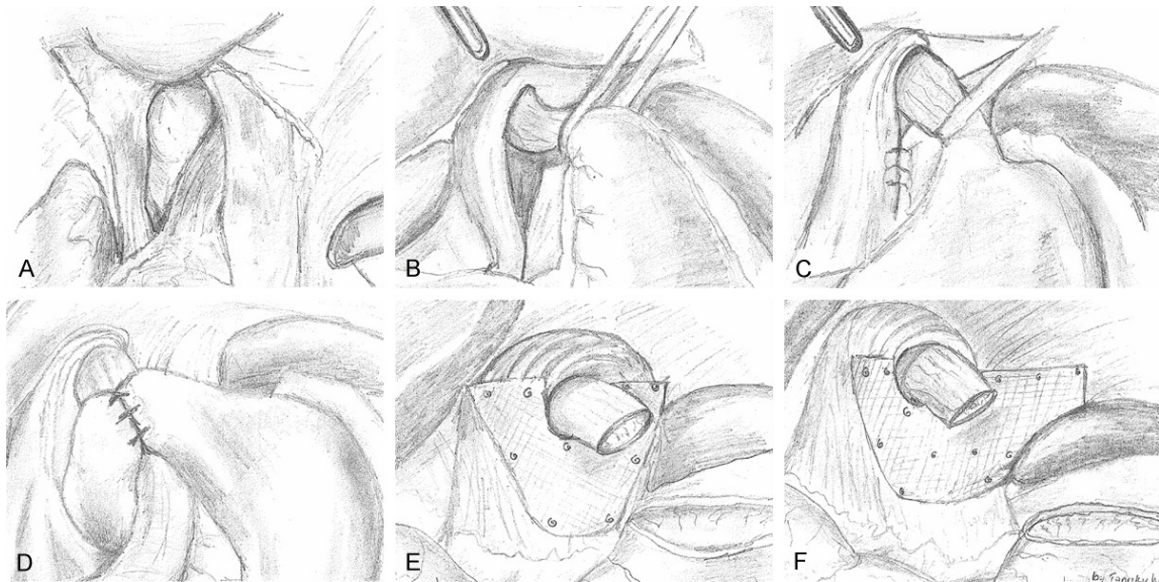


Figure 1. Surgical techniques and stages of the Nissen fundoplication. A. Preoperative view of hiatal hernia. B. Esophagus suspension and hiatal defect. C. Sutures closure of the crus. D. Nissen fundoplication. E. Reinforcement of crus with V-shaped mesh. F. Reinforcement of crus with Kar's designed mesh.

Table 1. Incidence of preoperative symptoms in groups

Symptoms	N (%)
Heartburn	114 (93.4%)
Regurgitation	53 (43.4%)
Dysphagia	5 (4.1%)
Chest/epigastric pain	106 (86.9%)
Nausea/vomiting	18 (14.8%)
Respiratory problems (e.g. asthma, dyspnea)	8 (6.6%)

Table 2. Distribution of preoperative endoscopic signs

Sign	N/%
Hiatal hernia	103 (84.4%)
Esophagitis	70 (57.4%)
Reflux	56 (45.9%)
Barrett's esophagitis	2 (1.6%)

to reduce the rate of recurrence various techniques such as supporting hiatus failure with prosthetic materials and using fibrin glue have been implemented in order to support cruroplasty [7].

In this study, we aimed to compare effects of only mesh, mesh + fibrin glue and special designed mesh (Kar's mesh) on recurrence postoperative in the patients with GERD + HH.

Material and methods

Patients

This study was retrospectively and cross sectional conducted on a single center basis after approved by the local ethical committee. A hundred twenty two patients were evaluated who operated Nissen fundoplication owing to GERD and/or HH at our hospital which is a district hospital, has a capacity of 600 beds, and 3500 surgeries per year are made between January 2009 and December 2013. The data of patients which obtained from archive records of patients and automation system after a long-term follow up were analyzed.

Preoperative evaluation and indications for surgery

GERH and HH related symptoms were evaluated preoperatively. The most common complaints of patients were heartburn, regurgitation, chest pain, abdominal pain, dysphagia, nausea, and vomiting. Oesophagogastroduodenoscopy was performed in all patients with complaints and anti-acid therapy was given. Oesophageal manometry was not done in any patients because of inaccessibility.

Indications for surgery: 1) unresponsiveness to medical therapy with PPIs for > 6 months; 2)

Fundoplication and prevention of recurrence

Table 3. The analysis of intraoperative complications between groups

Complications	Group 1 (V-shaped mesh) n = 42	Group 2 (V-shaped mesh + Fibrin glue) n = 37	Group 3 (Kar's mesh) n = 43	Overall n = 122	"p" value
Ischemia of spleen	4 (3.2%)	4 (3.2%)	2 (1.6%)	10 (8.1%)	0.562
Ischemia of liver	2 (1.6%)	1 (0.8%)	0	3 (2.4%)	0.364
Pneumothorax	1 (0.8%)	0	0	1 (0.8%)	0.383
Bleeding	0	1	0	1 (0.8%)	0.314

Table 4. The analysis of postoperative early-term complications between groups

Complications	Group 1 (V-shaped mesh) n = 42	Group 2 (V-shaped mesh + Fibrin glue) n = 37	Group 3 (Kar's mesh) n = 43	Overall n = 122	"p" value
Dysphagia < 3 months	0	1 (0.8%)	2 (1.6%)	3 (2.4%)	0.381
Dyspepsia < 3 months	3 (2.4%)	2 (1.6%)	8 (6.4%)	13 (10.6%)	0.107
Nausea/vomiting	0	0	1 (0.8%)	1 (0.8%)	0.396
Bleeding	2 (1.6%)	0	0	2 (1.6%)	0.144
Increased LVT	2 (1.6%)	1 (0.8%)	0	3 (2.4%)	0.364
Wound infection	2 (1.6%)	2 (1.6%)	0	4 (3.2%)	0.320
Respiratory complication (e.g. dyspnea, atelectasis) Emphysema	1 (0.8%)	1 (0.8%)	2 (1.6%)	4 (3.2%)	0.818
Pain score*	2.5 (0.5-8.2)	2 (0-7.2)	2.2 (0.4-7.5)	2.2 (0-8.2)	0.790

LVT: Liver function test. *Pain score was calculated using VAS (visual analog scale).

Table 5. The analysis of long-term follow-up complications between groups

Complications	Group 1 (V-shaped mesh) n = 42	Group 2 (V-shaped mesh + Fibrin glue) n = 37	Group 3 (Kar's mesh) n = 43	Overall n = 122	"p" value
Recurrence*	5 (4.1%)	1 (0.8%)	0	6 (4.9%)	0.030
Dysphagia ≥ 3 months	2 (1.6%)	0	0	2 (1.6%)	0.144
Dyspepsia ≥ 3 months	5 (4.1%)	3 (2.4%)	3 (2.4%)	11 (9%)	0.711

*Recurrences were identified according to DeMeers score, Visick score, and signs of endoscopic.

mismatch in continuation of medical treatment; 3) complications of GERD such as esophagitis, stricture, and ulcer; and 4) large HH associated with respiratory problems such as dyspnea, coughing or asthma.

Surgical procedure and study groups

Laparoscopic surgery was performed with general anesthesia using five trocars. First, all herniated structures were first repositioned (**Figure 1A**). Second, after opening lesser omentum and peritoneum on hiatus, the esophagus, the diaphragmatic crura, and the posterior vagus nerve by elevating the esophagus identified (**Figure 1B**). At least 3 cm of distal intra-abdominal portion of the esophagus was dissected. After complete mobilization of the hernia sac and the distal esophagus, the hiatus was nar-

rowed with two to three non-absorbable (**Figure 1C**). At this stage the patients were divided into three groups.

Group 1 (V-shaped mesh): After narrowed hiatus, V-shaped, 6 × 6 cm, light (35 g/m²), and polypropylene mesh (Surgimesh® Xlight, Aspide Medical, France) was used to strengthen the primary. The lower of the two arms of mesh was placed below the lower crus stitch, and fixed with staples (ProTack®, TycoUSS, Norwalk, CT). Later, the fundus of stomach was mobilized by cutting upper short gastric vessels and a Nissen fundoplication (360°C) was performed (**Figure 1D, 1E**).

Group 2 (V-shaped mesh + Fibrin Glue): After similar operations in Group 1, fibrin glue (Tisseel, Baxter International Inc., Westlake Village,

Fundoplication and prevention of recurrence

USA) was injected onto the mesh. Later, the fundus of stomach was mobilized by cutting upper short gastric vessels and a Nissen fundoplication (360°C) was performed (**Figure 1D, 1E**).

Group 3 (special designed mesh, √-shaped mesh, Kar's mesh): After narrowed hiatus, √-shaped 6 × 9 cm, light (35 g/m²), and polypropylene mesh which extending to the upper pole of the spleen was used to strengthen the primary and to prevent elongation of left crus (**Figure 1D, 1F**).

Postoperative evaluation

Follow-up time ranged 1 month to 5 years, with an average of 26 months. Period of hospitalization, symptoms, symptom duration, complication, postoperative endoscopic findings, and the results of all follow-up examinations were evaluated. Evaluations were made by direct examination in early stage, while were made by telephonic conversation in late stage. DeMeester and Visick scores were based on evaluation the failure of surgical treatment and patient satisfaction.

Statistical analysis

Statistical analyses were performed with SPSS 15.0 software (SPSS Inc., Chicago, IL, USA). Distribution of data was determined by Kolmogorov-Smirnov test. Categorical variables expressed as frequency and percent. Categorical variables were compared using Pearson's Chi-square test for two groups. A *p* value < 0.05 was considered statistically significant.

Results

A total of 122 patients who underwent laparoscopic Nissen fundoplication between January 2009 and December 2013 were evaluated. The patients divided into three groups according to their surgical procedures. General clinic results, preoperative symptoms, preoperative endoscopic signs, and intraoperative and postoperative early-term/long-term complications were evaluated. There was no mortality during follow-up. The numbers of patients in each group were 42, 37, and 43 patients, respectively. There were 37 male and 85 female, and

male to female ratio was 1:2.98. The mean age of patients in Group 1, Group 2, Groups 3, and overall were comparable, as 43.57 (17-72), 43.08 (18-64), 41.65 (20-65), and 42.75 (17-72) years, respectively. There wasn't statistically a difference between groups in terms of gender and mean age (*P* = 0.592 for mean age and *P* = 0.140 for gender).

Incidence of preoperative symptoms in groups was summarized in **Table 1**. The most common presenting symptoms were heartburn (93.4%) and chest pain (86.9%).

Preoperative endoscopic signs were depicted in **Table 2**. While the most common endoscopic sign was hiatal hernia (84.4%), the least common sign Barret's esophagitis (1.6%).

Surgery was completed laparoscopically in all patients. Intraoperative complications were given in **Table 3**. There wasn't difference between groups according to the complications. The total complication rate was 12.1%. The most common intraoperative complication was ischemia of the upper pole of the spleen occurred due to polar artery ligation (8.1% - 10 patients). Pneumothorax was observed in only one patient. All complications recovered spontaneously without any intervention.

Postoperative early-term complications were identified in **Table 4**. This complications include dysphagia and dyspepsia (< 3 months), nausea, bleeding, elevated liver function tests, wound infection, respiratory complications such as dyspnea, atelectasis, and pain score. Pain score was calculated in the first 24 hours postoperatively using visual analog scale (VAS). The most common complication was dyspepsia < 3 months (10.6%-13 patients). There wasn't a difference between groups in terms of these parameters.

All patients were followed postoperatively. The mean follow-up period was 27 months (14-40 months). After follow-up, patients were evaluated by telephone interview or face to face examination about their surgery. The overall recurrences rate was 5% (6 patients). While there wasn't a significant difference between Group 2 and Group 3 in terms of recurrences, the recurrence rate in Group 1 was higher than the other groups, and was statistically significant (*P* = 0.030). There wasn't statistically a dif-

Fundoplication and prevention of recurrence

ference between groups according to dysphagia and dyspepsia (≥ 3 months) (Table 5).

Discussion

GERD is one of the most common disorders of the gastrointestinal system and often associated with HH. The basic stay of treatment is acid suppression with PPIs. Surgical intervention requires in cases refractory to medical treatment. Currently, Nissen fundoplication is the most common performed surgery for the treatment GERD. But, the high recurrence rates after surgery has led to the use of different techniques and materials such as mesh, fibrin glue in during surgery. This study shows that special designed mesh prevents to recurrence after Nissen fundoplication.

Diagnosis of GERD includes many methods such as clinical diagnosis, endoscopy, histology, ambulatory pH monitoring, and manometry. In clinical diagnosis, symptoms of patients are very important. Typical symptoms of GERD are heartburn, regurgitation, and dysphagia while atypical symptoms are cough, hoarseness, laryngitis, and wheezing. Heartburn and regurgitation are characteristic symptom of GERD. Typical reflux symptoms can be diagnosed on the basis of characteristic symptoms without diagnostic testing [8]. Endoscopy is mandatory to establish a diagnosis of reflux esophagitis. But, it is positive in only about 40% of cases [9]. While there are reflux esophagitis half of the patients with HH who usually associated with acid reflux, HH is accompanied in 84% of patients with esophagitis. For endoscopic diagnosis of HH, gastroesophageal junction should be shifted to the mediastinal space at least 2 cm above of crus contraction [2]. Manometry is not mandatory for fundoplication in patient with typical symptoms but it is indicated patients with persistent reflux symptoms despite medical therapy and normal endoscopic signs [10, 11]. In our study, the most common symptoms are heartburn and chest pain. All patients were evaluated preoperatively by endoscopy. However, manometry was performed in any patient.

In treatment of GERD and HH, the most common procedure is Nissen fundoplication. The principal rules of this operation are to restore high-pressure zone and length of lower esophagus,

repair of the hiatal defect and complete/partial fundoplication [8]. The high complication rates have led to differences in surgical treatment.

While the enough lower esophageal length can be obtained with dissection of crura and esophagus suspension, in patients with large hiatal hernia, adequate length can be achieved by higher mediastinal dissection [12]. During higher mediastinal dissection, common complication is pneumothorax. Its rate is rare and spontaneously resolves. In our study, pneumothorax was observed in only 1 patient and it was spontaneously resolved.

During surgery, the repair of hiatal defect is the most important process to prevent recurrence. Despite high success rate reported in large series, important complications are related to the hiatoplasty. These complications are wrap migration and hiatal hernia recurrence. Before the development of mesh, primary suture of the crura with non-absorbable stitches was standard. However, high recurrence rates due to opening of stitches crus revealed that primary repair was just not enough. Nowadays, various prosthetic materials have been used to reinforcement the hiatoplasty. However, the use of mesh is not without complications. Complications associated with mesh include fibrosis, stricture, erosion, and diaphragm, aorta, and esophageal stenosis [13]. These complications have led to debate regarding the type of mesh material, shape, size, and fixation techniques. Types of prosthetic materials include polypropylene mesh, carbonate mesh, composite mesh, and biological mesh [14]. Mesh dimensions and shapes are altered. A small triangular piece of mesh, A, U, H, and O-shaped mesh are used. Mesh sizes can be adjusted individually by tailoring. Since hiatal defect is a hernia, small meshes does not comply with the principle of hernia surgery due to fibrotic tissue formed in the small mesh application has poor carrier property [15, 16]. For mesh fixation, various materials such as suture, fibrin glue, and staple are used [17]. Rantanen et al. [18] have found that fibrin glue is effective in the prevention of failure after Nissen fundoplication. Linke et al. [19] have identified that mesh-augmented hiatoplasty without fundoplication is feasible, safe and provides an anti-reflux effect. Similarly, Zhang et al. [20] found that the use of

composite mesh reduces recurrence. Stadlhuber et al. [13], in their study investigated the mesh complications, have identified that mesh erosion was not associated with different mesh material and different mesh configurations. Frantzides and Carlson [21], in their prospective study, had not any cases of migration or erosion of the prosthesis. Similarly, Brandalisa et al [22], in their study, observed no complications related to the prosthesis. As opposed to erosion, esophageal stricture occurs due to fibrosis with the prosthesis. To prevent fibrosis, Wassenaar [23] suggests that maintain a distance of 2-3 mm between the esophagus and mesh. In addition, Clement et al. [24] found that the use of absorbable biological mesh is safe, and has a low risk of side-effects and complications.

At our clinic, Nissen fundoplication is done for more than 10 years, and we are using the mesh and fibrin glue since 6-7 years. We used generally U-shaped mesh. Our recurrence rates significantly decreased with the use of mesh and fibrin glue. As the high cost of fibrin glue, opening of hiatoplasty and left crus elongation are cause of recurrence in the majority of cases we've changed the shape of the mesh to prevent recurrence. We've cut the mesh in a special shape, and extended to the upper pole of the spleen to prevent left crus elongation (**Figure 1F**). We've fixed the mesh with staple on crura and with sutures on diaphragm. In our cases with a long follow-up period, we found no complications, related to the use of a mesh.

After Nissen fundoplication, another important complication is dysphagia. In the first weeks after operation, it seems in up to 20-50% of patients. It is a mid- to long-term complication, and it seriously impairs the quality of life. Many patients were relieved from symptoms after a dietary counseling on soft meals [25]. Causes of dysphagia include inadequate mobilization of the gastric fundus, extreme narrowing hiatus, esophageal dysmotility, fibrosis caused mesh [26]. Singhal et al. [12] reported that dysphagia of varying degrees was observed in 11 patients (3.65%) at 3 months after surgery, and 8 patients had persistent dysphagia for solid food at nine months. Riberio et al. [27], in their study, found that severe persistent dysphagia rate was 7.27%. When esophageal dysmotility is encountered, complete fundoplication is pre-

ferred. In this cases, studies suggest the total fundoplication [28, 29]. In our study, transient dysphagia is showed in 3 patients, and this complication was not associated with mesh.

At the anti-reflux surgery, intraoperative bleeding, dyspepsia, wound infection, painful port-sites, wrap migration/ischemia, recurrent regurgitation/heartburn, ischemia liver/spleen are other complications, and rare. Complication rates in Singhal and colleagues' [12] studies involving 301 patients: respectively, intraoperative bleeding, painful port-sites and dyspepsia were 0.33%, wound infection was 1%, wrap migration/ischemia was 1%, recurrent regurgitation/heartburn 11%. In our study, dyspepsia was 10.6%, bleeding was 1.6%, wound infection was 3.2%, ischemia of spleen was 8.1%, and ischemia of liver 2.4%, and this results are consistent with the current literature.

Conclusion

GERD and HH are the most common disease of the upper gastrointestinal system. Nissen fundoplication is gold standard therapy in the surgical treatment of these diseases. Today, even despite recurrence rate is low due to the use of mesh it is still high. To reduce both recurrence rates and complications associated with the mesh, patients should be carefully selected. In this study, we have used a special designed mesh. We didn't detect any recurrence in patients in the group used special mesh. We didn't observe a serious complication associated with mesh. According to the results, we believe that this special designed mesh can be used safely and effectively in anti-reflux surgery.

Disclosure of conflict of interest

None.

Address correspondence to: Dr. Yusuf Tanrikulu, Zonguldak Atatürk Devlet Hastanesi Genel Cerrahi Kliniği, Zonguldak 67100, Turkey. Tel: +90505657-9709; Fax: +903722521900; E-mail: drtanrikulu@hotmail.com

References

- [1] Dent J, El-Serag HB, Wallander MA, Johansson S. Epidemiology of gastro-oesophageal reflux disease: a systematic review. *Gut* 2005; 54: 710-17.

Fundoplication and prevention of recurrence

- [2] Wright RA, Hurwitz AL. Relationship of hiatal hernia to endoscopically proved reflux esophagitis. *Dig Dis Sci* 1979; 24: 311-313.
- [3] Iqbal M, Batch AJ, Moorthy K, Cooper BT, Spychal RT. Outcome of surgical fundoplication for extra-oesophageal symptoms of reflux. *Surg Endosc* 2009; 23: 557-561.
- [4] Katz PO, Gerson LB, Vela MF. Guidelines for the diagnosis and management of gastroesophageal reflux disease. *Am J Gastroenterol* 2013; 108: 308-328.
- [5] Sifrim D, Zerbib F. Diagnosis and management of patients with reflux symptoms refractory to proton pump inhibitors. *Gut* 2012; 61: 1340-1354.
- [6] Kim WH, Park PW, Hahm KB, Hong SP. Endoscopic treatment of refractory gastroesophageal reflux disease. *Clin Endosc* 2013; 46: 230-234.
- [7] Herbella FA, Patti MG, Del Grande JC. Hiatal mesh repair- current status. *Surg Laparosc Endosc Percutan Tech* 2011; 21: 61-66.
- [8] Nwokediuko SC. Current trends in the management of gastroesophageal reflux disease: a review. *ISRN Gastroenterol* 2012; 2012: 391631.
- [9] Nwokediuko SC, Ijoma U, Obienu O, and Aguny-enwa C. Gastroesophageal reflux disease: a clinical and endoscopic study of Nigerian patients. *The Internet Journal of Gastroenterology* 2009; 8: 2.
- [10] Nagpal AP, Soni H, Haribhakti S. Is oesophageal manometry a must before laparoscopic fundoplication? Analysis of 46 consecutive patients treated without preoperative manometry. *J Minim Access Surg* 2010; 6: 66-69.
- [11] Waring JP, Hunter JG, Oddsdottir M, Wo J, Katz E. The preoperative evaluation of patients considered for laparoscopic antireflux surgery. *Am J Gastroenterol* 1995; 90: 35-38.
- [12] Singhal T, Balakrishnan S, Hussain A, Grandy-Smith S, Paix A, El-Hasani S. Management of complications after laparoscopic Nissen's fundoplication: a surgeon's perspective. *Ann Surg Innov Res* 2009; 3: 1.
- [13] Stadlhuber RJ, Sherif AE, Mittal SK, Fitzgibbons RJ Jr, Michael Brunt L, Hunter JG, Demeester TR, Swanstrom LL, Daniel Smith C, Filipi CJ. Mesh complications after prosthetic reinforcement of hiatal closure: a 28-case series. *Surg Endosc* 2009; 23: 1219-1226.
- [14] Frantzides CT, Carlson MA, Loizides S, Papafili A, Luu M, Roberts J, Zeni T, Frantzides A. Hiatal hernia repair with mesh: a survey of SAGES members. *Surg Endosc* 2010; 24: 1017-1024.
- [15] Turkcapar A, Kepenekçi İ, Mahmoud H, Tuzuner A. Laparoscopic fundoplication with prosthetic hiatal closure. *World J Surg* 2007; 31: 2168.
- [16] Lee E, Frisella MM, Matthews BD, Brunt LM. Evaluation of cellular human dermis reinforcement of the crural closure in patients with difficult hiatal hernias. *Surg Endosc* 2007; 21: 641-645.
- [17] Jenkins ED, Lerdsirisopon S, Costello KP, Melman L, Greco SC, Frisella MM, Matthews BD, Deeken CR. Laparoscopic fixation of biologic mesh at the hiatus with fibrin or polyethylene glycol sealant in a porcine model. *Surg Endosc* 2011; 25: 3405-3413.
- [18] Rantanen T, Neuvonen P, Iivonen M, Tomminen T, Oksala N. The impact of fibrin glue in the prevention of failure after Nissen fundoplication. *Scand J Surg* 2011; 100: 181-185.
- [19] Linke GR, Gehrig T, Hogg LV, Göhl A, Kenngott H, Schäfer F, Fischer L, Gutt CN, Müller-Stich BP. Laparoscopic mesh-augmented hiatoplasty without fundoplication as a method to treat large hiatal hernias. *Surg Today* 2014; 44: 820-826.
- [20] Zhang W, Tang W, Shan CX, Liu S, Jiang ZG, Jiang DZ, Zheng XM, Qiu M. Dual-sided composite mesh repair of hiatal hernia: our experience and a review of the Chinese literature. *World J Gastroenterol* 2013; 19: 5528-5533.
- [21] Frantzides CT, Madan AK, Carlson MA, Stavropoulos GP. A prospective, randomized trial of laparoscopic polytetrafluoroethylene (PTFE) patch repair vs. simple cruroplasty for large hiatal hernia. *Arch Surg* 2002; 137: 649-652.
- [22] Brandalise A, Aranha NC, Brandalise NA. The polypropylene mesh in the laparoscopic repair of large hiatal hernias: technical aspects. *Arq Bras Cir Dig* 2012; 25: 224-228.
- [23] Wassenaar EB, Mier F, Sinan H, Petersen RP, Martin AV, Pellegrini CA, Oelschläger BK. The safety of biologic mesh for laparoscopic repair of large, complicated hiatal hernia. *Surg Endosc* 2012; 26: 1390-1396.
- [24] Zackariah Clement, Phil Jeans. Laparoscopic Antireflux Surgery: A Comparative Study of Nissen Fundoplication and Hiatoplasty With and Without Absorbable Biological Mesh. *J Curr Surg* 2013; 3: 1-6.
- [25] Moraes-Filho JPP, Navarro-Rodriguez T, Barbuti R, Chinzon D, Bernardo W; The Brazilian GERD Consensus Group. Guidelines for the diagnosis and management of gastroesophageal reflux disease: an evidence-based consensus. *Arq Gastroenterol* 2010; 47: 99-115.
- [26] Hunter JG, Smith CD, Branum GD, Waring JP, Trus TL, Cornwell M, Galloway K. Laparoscopic fundoplication failures: patterns of failure and response to fundoplication revision. *Ann Surg* 1999; 230: 595-606.
- [27] Ribeiro MC, Terciotti-Júnior V, Souza-Neto JC, Lopes LR, Morais DJ, Andreollo NA. Identification of preoperative risk factors for persistent

Fundoplication and prevention of recurrence

- postoperative dysphagia after laparoscopic antireflux surgery. *Arq Bras Cir Dig* 2013; 26: 165-169.
- [28] Lindeboom MA, Ringers J, Straathof JW, van Rijn PJ, Neijenhuis P, Masclee AA. Effect of laparoscopic partial fundoplication on reflux mechanisms. *Am J Gastroenterol* 2003; 98: 29-34.
- [29] Patti MG, Robinson T, Galvani C, Gorodner MV, Fisichella PM, Way LW. Total fundoplication is superior to partial fundoplication even when esophageal peristalsis is weak. *J Am Coll Surg* 2004; 198: 863-870.