

Original Article

Protective effect of the ω -3 polyunsaturated fatty acids on the schistosomiasis liver fibrosis in mice

Yuan Wu^{1,2*}, Yu Liang^{1*}, Yi Zhu², Yongqiang Gao¹, Hu Chen², Yukuai Zhang¹, Weiguo Yin¹, Yingju Li¹, Kegeng Wang¹, Jianhua Xiao¹

¹Institute of Pathogenic Biology of Medical College, ²The Second Affiliated Hospital, University of South China, Hengyang 421001, Hunan, China. *Equal contributors.

Received March 30, 2015; Accepted May 31, 2015; Epub June 15, 2015; Published June 30, 2015

Abstract: This study aims to observe the effect of ω -3 polyunsaturated fatty acids on initiation and elimination of the schistosomiasis inflammatory response and liver fibrosis. The mice infected with the cercariae of *Schistosoma japonicum* (20 \pm cercariae per mice) were separated randomly into several groups. After 60 days, liver tissue samples of all mice were sectioned. Hematoxylin-eosin (HE) staining, Masson staining, the enzyme-linked immunosorbent assay (ELISA), and flow cytometry (FCM) were performed. Through HE and Masson staining, the size of egg (ovum) granuloma and the collagen deposited in mice's livers in ω -3 PUFAs and praziquantel mixed groups were less than that of model group and praziquantel treated group. The serum level of IL-13 and TNF- α were lower than that of model group and praziquantel treated group. The indicators of liver fibrosis, such as HA and LN in the group treated with ω -3 PUFAs and praziquantel before the release of soluble eggs antigen (SEA) into blood, were lower than that of model group and praziquantel treated group, respectively. The combined treatment of ω -3 polyunsaturated fatty acids and praziquantel conducted before the release of soluble eggs antigens into the blood decreases liver ovum granulomatous inflammation and fibrosis degree in the schistosomiasis. The mechanism of the ω -3 polyunsaturated fatty acid may be related to the adjustment of the anti-inflammatory and immune responses.

Keywords: *Schistosoma japonicum*, liver fibrosis, ω -3 polyunsaturated fatty acids, protective effect

Introduction

As one of the world's most prevalent parasitic diseases, schistosomiasis is a major health hazard to human. The main pathologic lesions of *Schistosoma japonicum*-induced diseases are the liver granuloma formation around schistosome eggs, and the liver fibrosis, of which the liver fibrosis triggers most of the inflammation and death [1]. When the schistosome eggs secrete soluble antigens that provoke the granulomatous inflammation, the lacking of the recruited endogenous inflammatory cells prolongs the inflammation reactions, which activates the proliferation of hepatic stellate cells (HSCs) to fibroblasts, with an increased production of types I and III collagens and other extracellular matrix (ECM). During the chronic stages of infection, the massive accumulation of ECM progressively replaced the fibrosis by fibrotic deposits, resulting in the portal hypertension, ascites, splenomegaly, and other clinical mani-

festations observed from hepatitis and cirrhosis [2-4]. Generally, hepatic fibrosis may be reversible at the early stage, whereas the cirrhosis seems to be irreversible [5]. Therefore, extensive attentions have been paid to the prophylaxis and treatment for this disease.

Known as the essential nutrient and source of energy, ω -3 polyunsaturated fatty acids (ω -3 PUFAs), including α -linolenic acid, eicosapentaenoic acid (EPA) and docosahexaenoic acid (DHA), have been shown to have an immunomodulating effect on immunocytes regulation, cytokines induction, and adverse inflammatory reactions attenuation. Numerous basic, clinical and epidemiological researches have confirmed that lipid emulsions loaded with ω -3 PUFAs from fish oil can serve as a therapeutic agent in sepsis, acute pancreatitis, malignant tumor, transplantation rejection, dementia and other kinds of diseases [6-11]. However, there is no report concerning the inhibitive effect of

Protective effect of the ω -3 PUFAs

ω -3 PUFAs on granulomas and hepatic fibrotic so far.

The aim of this study was therefore to evaluate the effects of ω -3 PUFAs on the induction and reduction of the inflammatory response stimulated by schistosomiasis through the *Schistosoma japonicum*-infected mice model. The observations on serum level of liver fibrosis, as well as the viable and prognostic states of liver cells were conducted, from which the results suggest that the ω -3 PUFAs may have a potential as a new clinic treatment for reducing fibrosis in schistosomiasis.

Materials and methods

Animals, parasites and reagents

Sixty 6-8 week old female Kunming mice (20 g each) were obtained from Experimental Animal Center, University of South China. Mice were housed in autoclaved microisolator cages and were provided with free access to food and sterile water. For infection, 24 *Oncomelania hupensis* snails, infected with cercariae of *S. japonicum*, were purchased from Hunan Institute of Parasitic Disease Control (Yueyang, China). All animal care and procedures were approved by the Institutional Animal Care and Use Committee, and mice were used in accordance with the ethical guidelines of University of South China.

The lipid emulsions with ω -3 PUFAs from fish oil (10%, 100 ml), eicosapentaenoic acid (EPA) and docosahexaenoic acid (DHA), were supplied by Fresenius Kabi Deutschland GmbH (Bad Homburg, Germany). Praziquantel (0.2 g) was purchased from Nanjing Pharmaceutical Factory Co. Ltd. (Nanjing, China).

The TNF- α , IL-13, and IFN- γ levels were measured by an enzyme-linked immunosorbent assay (ELISA) using a commercial kit (R&D, USA). Mice serum hyaluronic acid (HA) and the Laminin (LN) Radioimmunoassay Kits were obtained from Beijing North Institute of Biological Technology (Beijing, China), and examined via radioimmunoassay.

*Infection of mice with *S. japonicum* and treatment with ω -3 PUFAs*

Mice were anesthetized and percutaneously infected with cercariae of *S. japonicum*. The

recipient mice were randomly assigned to four groups according to their respective treatment: an infected model group (group A, n = 10), a praziquantel individual treated group (group B, n = 10), a ω -3 PUFAs and praziquantel mixed group (group C, n = 30), and a control group (group D, n = 10). The group C was further divided into three subgroups based on the cercariae infection stage. The group C₁ was injected with ω -3 PUFAs and praziquantel on day 12 post-infection, before the release of soluble eggs antigen (SEA) into blood. The group C₂ was treated with ω -3 PUFAs and praziquantel on day 35, during the SEA release. After the release, group C₃ was subsequently assigned on day 42. The ω -3 PUFA (2 ml/kg) was injected every day for one week, while the praziquantel (500 mg/kg) was injected every day for 2 days. All the mice were killed on day 60 and the ocular blood, liver, spleen were collected.

Histology and immunohistochemistry

Liver tissues were fixed in 10% buffered formalin with rehydration through graded ethanol solutions, and embedded in paraffin. Tissue sections (5 μ m) were affixed to slides, and stained with hematoxylin and eosin (HE) and Masson for collagen deposition.

Immunostaining for α -SMA was performed using the rabbit anti-mouse α -SMA polyclonal antibody and immunohistochemistry Kits were purchased from Auragene Bioscience Co. Ltd. Briefly, in order to inhibit endogenous peroxidase activity, sections were incubated with 3% H₂O₂ in methanol for 15 min at room temperature (RT). After washout with distilled water, sections were immersed in phosphate-buffered saline (PBS) for 15 min. Antigen retrieval was conducted with boiling at 100°C for 15 min. Sections were then washed again with PBS for three times after cooling down to RT. Followed the incubation for 10 min at RT, mouse plasma samples were added with rabbit anti-mouse α -SMA polyclonal antibody, and stayed overnight at 4°C. The washout with PBS lasted for 5 min and was repeated for three times and incubated with horseradish peroxidase (HRP)-conjugated anti-rabbit IgG at 37°C for 30 min. After washing with PBS and addition of HRP, samples were incubated at 37°C for 30 min again. The HRP activity was revealed by diaminobenzidine (DAB) after the final PBS wash. The percent positive staining for α -SMA was observed under microscope.

Protective effect of the ω -3 PUFAs

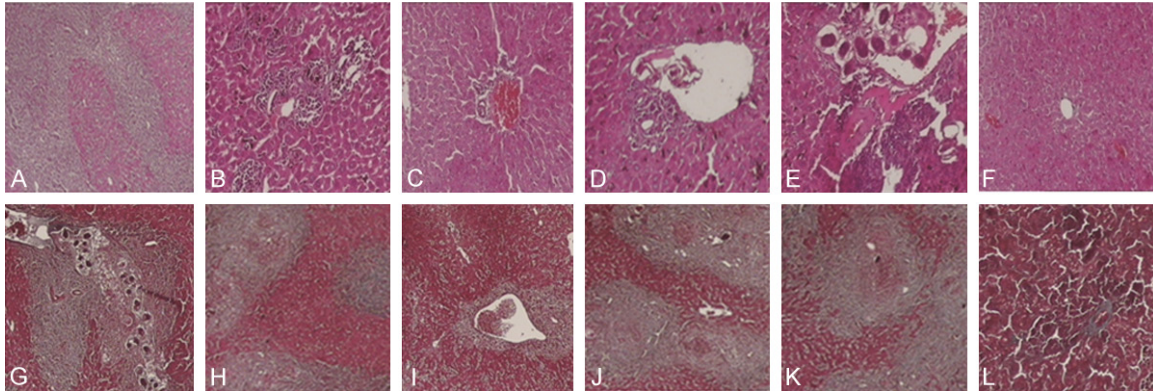


Figure 1. Histological findings for the liver tissue with HE staining and Masson staining. HE staining in (A-F), nucleus is stained with blue or purplish blue, while cytolymph, muscle fiber, and collagenous fiber are in various shades of red, respectively. Masson staining in (G-L), nucleus and collagen is stained with blue, while the cytolymph and muscle fiber are in red. Representative HE and Masson staining images for model group A (A, original magnification $\times 40$; G, original magnification $\times 100$), praziquantel group B (B and H, original magnification $\times 100$), ω -3 PUFAs and praziquantel mixed groups C₁, treated before SEA release (C and I, original magnification $\times 100$), C₂, treated during SEA release (D and J, original magnification $\times 100$), C₃, treated after SEA release (E and K, original magnification $\times 100$), and control group D (F and L, original magnification $\times 100$).

Flow cytometry

Spleen tissue was washed and dissolved with saline solution, then frozen and stored in liquid nitrogen. The following antibodies were used anti-mouse CD8a PE, anti-mouse CD4 APC and anti-mouse CD3e PerCP-Cy5.5. These antibodies were purchased from eBioscience (San Diego, USA).

Statistical analysis

SPSS version 13.0 was used for Student's unpaired t-test statistical analysis. Data were expressed as mean \pm SD. A value of $P < 0.05$ was considered to be significant.

Results

Fibrosis analysis by HE staining and Masson staining

To evaluate the effect of ω -3 PUFAs on schistosomiasis histopathologic features of granulomas and hepatic fibrotic, *S. japonicum*-infected mice model was constructed. The mice infected with the cercariae of *Schistosoma japonicum* ($20 \pm$ cercariae per mice) were separated randomly into three groups: *Schistosoma japonicum* model group (group A, 10 mice), praziquantel treatment group (group B, 10 mice), ω -3 polyunsaturated fatty acids and praziquantel combined treatment group (group C, 30 mice). Then, the group C were randomly divided

into three equal groups: group C₁ was treated before the soluble eggs antigen (SEA) released into blood, that is 12 days after infected with cercariae. The group C₂ and C₃ were treated after the SEA released into blood, that are respectively 35 days and 42 days after infected with cercariae. At the three different time, mice of group C were combined treatment with ω -3 polyunsaturated fatty acids and praziquantel (ω -3 polyunsaturated fatty acids 2 ml/kg per mouse per day, $V_i \times 7$ days, praziquantel 500 mg/kg per mouse per day, gavage $\times 2$ days). The group B was treated with praziquantel (500 mg/kg per mouse per day, gavage $\times 2$ days). At the same time, another 10 uninfected mice were chosen as control group (group D).

Mice in the infection model group had duller furs, lighter body weight and reduced activities than those in the control group. In general, conditions of the mice in praziquantel group, and ω -3 PUFAs and praziquantel mixed group, had a better improvement than the model group, and showed no apparent difference from the control group. Two mice in model group and one mouse in praziquantel group, ω -3 PUFAs and praziquantel mixed groups C₂ and C₃, were dead, while no death occurred in the ω -3 PUFAs and praziquantel mixed group C₁ and the control group after all analysis.

After 60 days, liver tissue samples of all mice were sectioned and stained with Hematoxylin-

Protective effect of the ω -3 PUFAs

Table 1. Granuloma formation, collagenous fiber accumulation, α -SMA expression, CD4⁺ T cells and CD8⁺ T cells in the groups

Groups	Granuloma formation (mm ²)	Collagenous fiber accumulation (%)	α -SMA (Absorbance value)	CD4 ⁺ T (%)	CD8 ⁺ T (%)	
Model (group A)	0.177 ± 0.004	27.67 ± 0.51	0.70 ± 0.03	10.99 ± 0.02	5.65 ± 0.03	
Praziquantel (group B)	0.146 ± 0.009	21.67 ± 0.41	0.57 ± 0.05	11.19 ± 0.05	5.71 ± 0.05	
ω -3 PUFAs and praziquantel mixed (group C)	Before SEA release (group C ₁)	0.096 ± 0.008 ^{*,*}	16.68 ± 0.44 ^{*,*}	0.41 ± 0.02	11.17 ± 0.04	5.80 ± 0.06
	During SEA release (group C ₂)	0.148 ± 0.013	21.67 ± 0.39	0.58 ± 0.04	11.08 ± 0.08	5.72 ± 0.02
	After SEA release (group C ₃)	0.144 ± 0.007	21.63 ± 0.49	0.60 ± 0.02	11.02 ± 0.05	5.67 ± 0.02
Control (group D)	0.000 ± 0.000	2.01 ± 0.13	0.01 ± 0.0009	14.45 ± 0.19	5.95 ± 0.03	

Note: #, P < 0.01, compared with the model group (group A); *, P < 0.01, compared with the praziquantel group (group B).

Table 2. Values of TNF- α , IL-13, IFN- γ , HA, and LN in the groups

Groups	TNF- α (pg/ μ l)	IL-13 (pg/ml)	IFN- γ (pg/ μ l)	HA (ng/ml)	LN (ng/ml)	
Model (group A)	0.67 ± 0.04	129.77 ± 8.34	0.17 ± 0.02	1735.85 ± 141.49	1871.83 ± 52.96	
Praziquantel (group B)	0.38 ± 0.03	90.41 ± 5.51	0.42 ± 0.02	1061.96 ± 144.68	1400.74 ± 32.24	
ω -3 PUFAs and praziquantel mixed (group C)	Before SEA release (group C ₁)	0.27 ± 0.02	71.08 ± 6.21	0.54 ± 0.03	822.35 ± 69.62 ^{*,*}	1233.1 ± 42.69
	During SEA release (group C ₂)	0.37 ± 0.02	86.65 ± 3.38	0.44 ± 0.02	996.79 ± 82.01	1334.98 ± 43.22
	After SEA release (group C ₃)	0.38 ± 0.02	88.87 ± 3.28	0.43 ± 0.02	1043.37 ± 150.78	1363.66 ± 42.04
Control (group D)	0.19 ± 0.03	0.000 ± 0.000	0.72 ± 0.03	518.2 ± 75.56	1031.21 ± 83.33	

Note: #, P < 0.01, compared with the model group (group A); *, P < 0.01, compared with the praziquantel group (group B).

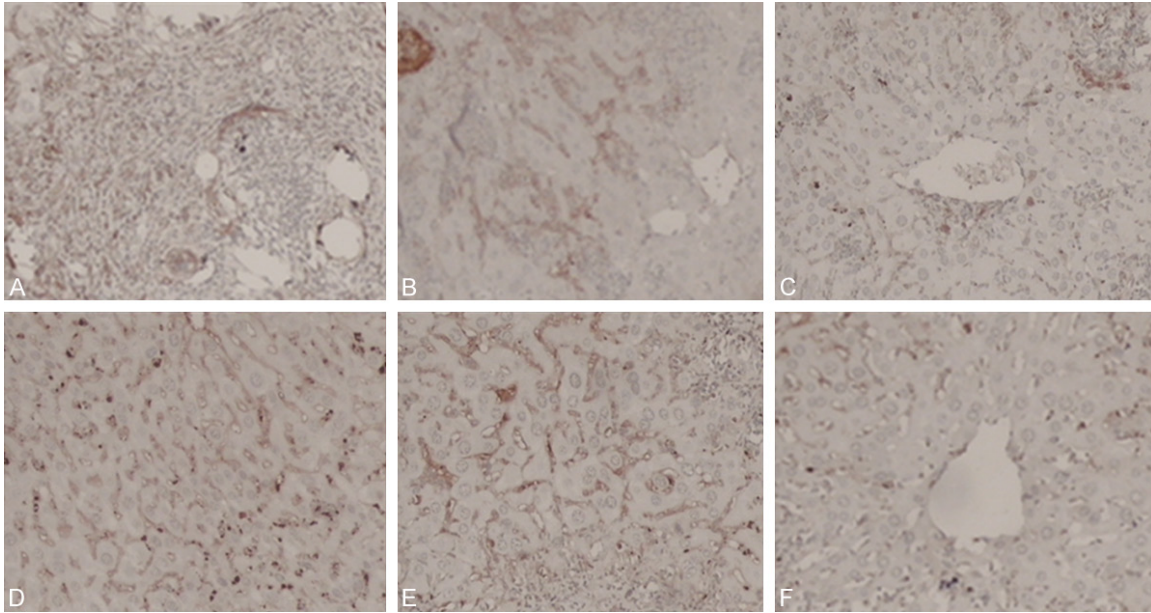


Figure 2. Positive staining for α -SMA. The liver tissues were fixed and stained with anti- α -SMA antibody. Collagen deposition and the α -SMA positive area were shown here and quantified in **Table 2**. Representative images (original magnification $\times 100$) for model group A (A), praziquantel group B (B), ω -3 PUFAs and praziquantel mixed groups C₁ (C), C₂ (D), C₃ (E), and control group D (F).

eosin (HE) (**Figure 1A-F**) and Masson (**Figure 1G-L**) to measure the size of egg (ovum) granuloma and assess the collagen deposited in mice's livers. In model group, the *S. japonicum* eggs deposited around the liver tissue was intensity and infiltrated with a great amount of inflammatory cells. Hepatocytes were arranged irregularly, showing fatty degeneration and acidophilic changes. Some debris and regenerating hepatocytes around granuloma were also visible. The associated sinusoids were infiltrative into inflammatory cells with pressure deformation and thickening walls. The granuloma formation, vascular dilatation, fibrous tissue and bile duct proliferation in the portal area caused the main line of fibrosis. The density and intensity in praziquantel group were relatively lower, and the infiltrative inflammatory cells, fatty and acidophilic degeneration, vascular dilatation, and connective tissue proliferation were also observed. Compared with the model group, the size and density of the *S. japonicum* eggs around the liver tissue were smaller in group C₁, which was treated with ω -3 PUFAs and praziquantel on day 12. Besides, more hepatic lobules, little infiltrative inflammatory cells, fatty degeneration and fibrosis were generally observed. The group C₂, treated with ω -3 PUFAs and praziquantel on day 35, together with the group C₃, treated on day 42,

showed no obvious difference to the praziquantel group. No pathologic changes were found in the liver tissue, lobule, hepatocyte, and portal area from the control group (**Figure 1A-F** and **Table 1**).

In model group, vascular dilatation appeared in the central portal vein and liver lobule tissue, with collagenous fiber accumulation and cicatrix formation. The sinusoidal deposition and capillarization was also observed in the thickened walls. In praziquantel group, the condition was reduced compared with model group. In group C₁, the liver fibrosis was mainly located in the portal, accompanied with casual collagenous fiber accumulation and less thickened lobule central vein. The groups C₂ and C₃ showed no obvious difference to group B. In the uninfected control, collagenous fiber was only found in the vascular walls of liver tissue, and not dispersed among the hepatocytes and in the sinusoidal (**Figure 1G-L** and **Table 1**). These results suggest that ω -3 polyunsaturated fatty acids can significantly reduce the inflammatory response and pathological damage caused by schistosomiasis.

Inflammatory cytokines levels

To assess the effect of ω -3 PUFAs on inflammatory cytokines, TNF- α and IL-13 levels were

Protective effect of the ω -3 PUFAs

examined by ELISA, respectively. The TNF- α and IL-13 levels in the ω -3 PUFAs and praziquantel treated group C₁ were lower compared with the model group and praziquantel group ($P < 0.05$), while the IFN- γ was relatively higher ($P < 0.05$) (Table 2). These results suggest that anti-inflammatory reactions stimulated by ω -3 PUFAs may be induced through inflammatory cytokine regulation, leading to the attenuation of granulomas and hepatic fibrotic.

Liver fibrosis

To measure the intervention effect of ω -3 PUFAs on hepatic fibrotic, HA and LN levels were examined via radioimmunoassay. Compared to the model group and praziquantel group, the levels of HA and LN in the ω -3 PUFAs and praziquantel treated group C₁ and C₂ were decreased ($P < 0.01$); while the group C₃ showed a significant lower level in both HA and LN than model group ($P < 0.05$), and no obvious difference from praziquantel group ($P > 0.05$) (Table 2). The decrease of HA and LN levels suggests that ω -3 PUFAs can inhibit the hepatic fibrotic caused by schistosomiasis.

Immunohistochemical analysis of α -SMA

To examine the HSCs proliferation induced by continuous stimulation of SEA and inflammatory cytokines, immunohistochemical analysis for HSCs specific proliferation maker α -SMA, was performed. In the infection model group, a great amount of α -SMA positive staining cells were present in liver portal, granuloma formed and collagenous fiber deposited space. An increased expression of α -SMA was observed in the liver sinusoidal. Compared with the model group, the presence and expression of α -SMA in praziquantel group were slightly decreased. A significant decrease in the amount and expression of α -SMA positive staining cells in the liver portal, granuloma surrounding and sinusoidal region was observed in the group C₁ ($P < 0.05$), treated with ω -3 PUFAs and praziquantel on day 12. The group C₂ and group C₃, treated with ω -3 PUFAs and praziquantel on day 35 and 42, respectively, showed no obvious difference to the praziquantel group. In the control group, little expression of α -SMA was detected in the liver vascular wall as well as the smooth muscle of the bile duct, and no α -SMA were found in liver portal and sinusoidal (Figure 2 and Table 1). The results

above suggest that ω -3 PUFAs can inhibit the HSCs proliferation stimulated by SEA and inflammatory cytokines.

Lymphocyte proliferation analysis by flow cytometry

To investigate the effect of ω -3 PUFAs on inflammatory response, lymphocyte proliferation level was determined by flow cytometry. The percentage of CD4⁺ T cells of the total number of the spleen cells in group C₁, treated with ω -3 PUFAs and praziquantel on day 12, showed no significant difference to model and praziquantel groups ($P > 0.05$), but was obviously reduced in comparison to the control ($P < 0.05$). However, no significant difference was observed in the percentage of CD8⁺ T cells among the total number of spleen cells among the four groups (Table 1). These results suggest that ω -3 PUFAs can attenuate the inflammatory response by inhibiting the CD4⁺ T cells proliferation, resulted in the reduction of granulomas and hepatic fibrotic.

Discussion

In this study, effects of the ω -3 PUFAs on the inflammatory response initiation and elimination induced by liver fibrosis were investigated through *S. japonicum* infected mice model. The survivor and prognosis of hepatocyte, as well as the T cell proliferation were also examined. This is the first evaluation concerning the protection effectiveness of ω -3 PUFAs on the *S. japonicum* caused granulomatous inflammation and liver fibrosis.

The results here show that ω -3 PUFAs have an advantageous effect on the anti-inflammatory response by regulating the TNF- α and IL-13, which led to the anti-granulomatous inflammation improvement. During the *S. japonicum* induced fibrosis, the activation and proliferation of HSC stimulated by the SEA was the pivotal process that resulted in progressive liver fibrosis. The α -SMA was regarded as the symbol for the HSC activation. All the ω -3 PUFAs treated groups showed a reduced HSC proliferation, which may be due to the HSC inactivation caused by the ω -3 PUFAs or some other existed relationship.

The level of LN and HA in the infected group were obviously higher than the control, while

the group treated only with praziquantel was relatively lower than these two groups. The group with the ω -3 PUFAs and praziquantel combined treatment showed significantly decrease in the LN and HA level, proving that the ω -3 PUFAs can reduce the liver fibrosis, accompanied with praziquantel.

The ω -PUFAs can inhibit the T cell proliferation by lipid rafts modification [12]. In the mice with high expression level of T cell receptor (TCR), ω -3 PUFAs can significantly reduce the hyperplastic reaction of specific antigen lymphocytes by 50% [13]. The results obtained in this study suggested that ω -PUFAs can reduce the granulomatous inflammation by inhibiting the CD4⁺ T proliferation. When the ω -3 PUFAs were provided before the SEA release, the treatment was most effective. Whereas the treatments during and after the release showed no obvious difference to the praziquantel provided group. Therefore, the time point for the ω -3 PUFAs supplement plays an important role during the therapy.

In conclusion, the *S. japonicum* infected model here has demonstrated that, the ω -3 PUFAs and praziquantel combined treatment conducted before the release of soluble eggs antigen into blood, can significantly reduce the granuloma and liver fibrosis. The ω -3 PUFAs application as the assistant pharmaceutical products for granuloma and liver fibrosis therapy could be prepared for further development.

Acknowledgements

This work was supported by the National Natural Science Foundation of China (No. 81101274 and 30972576), the Hunan Provincial Natural Science Foundation-Hengyang Joint Foundation of China (No. 10JJ2010), and the Hunan Provincial Natural Science Foundation of China (No. 2011JJ3104).

Disclosure of conflict of interest

None.

Address correspondence to: Jianhua Xiao, Institute of Pathogenic Biology of Medical College, University of South China, No. 28, Changsheng West Road, Hengyang 421001, Hunan, China. Tel: 86-1397-473-9966; Fax: 86-1397-473-9966; E-mail: jhxiao223@163.com

References

- [1] World Health Organisation. WHO fact sheet on Schistosomiasis. Geneva: WHO; 1996.
- [2] Chen W and Wen LY. Advances of the immunology and molecular biology of schistosomiasis. International Journal of Epidemiology and Infectious Disease 2007; 34: 425-9.
- [3] Cai W. The progress and treatment of schistosomiasis caused liver fibrosis. Beijing People's Health Publishing House 2006; 12: 35-9.
- [4] Iredale JP. Models of liver fibrosis: exploring the dynamic nature of inflammation and repair in a solid organ. Clin Invest 2007; 117: 539-48.
- [5] Okazaki I, Watanabe T, Hozawa S, Niioka M, Arai M and Maruyama K. Reversibility of hepatic fibrosis: from the first report of collagenase in the liver to the possibility of gene therapy for recovery. Keio J Med 2001; 50: S58.
- [6] Fierro IM and Serhan CN. Mechanisms in anti-inflammation and resolution: the role of lipoxins and aspirin-triggered lipoxins. Braz J Med Biol Res 2001; 34: 555-6.
- [7] Oz HS, Chen TS and Neuman M. Nutrition intervention: a strategy against systemic inflammatory syndrome. JPEN J Parenter Enteral Nutr 2009; 33: 380-389.
- [8] Long D, Yu L, Xu T and Zhang Y. Effect of total parenteral nutrition with omega-3 polyunsaturated fatty acids on inflammatory mediators in patients with acute pancreatitis. Journal of Practical Diagnosis and Therapy 2009; 23: 1028-9.
- [9] Wang ZY, Li RF, Liu XL, Liu X and Wang X. The effect of ω -3 polyunsaturated fatty acids on SOD, MDA and the proliferation of human liver cancer HepG2 cells. China Foreign Medical Treatment 2009; 21: 23-4.
- [10] Ogita K, Suita S, Taguchi T, Yamanouchi T, Nakamura M, Taguchi S, Nishimoto Y and Uesugi T. Effects of omega-3 fatty acids in rat allogenic small intestinal transplantation. Pediatr Surg Int 2003; 19: 157-61.
- [11] Kyle DJ, Schaefer E, Patton G and Beiser A. Low serum docosa-hexaenoic acid is a significant risk factor for Alzheimer's dementia. Lipids 1999; 34: S245.
- [12] Geyeregger R, Zeyda M, Zlabinger GJ, Waldhäusl W and Stulnig TM. Polyunsaturated fatty acids interfere with formation of the immunological synapse. J Leukoc Biol 2005; 77: 680-8.
- [13] Pompos LJ and Fritsche KL. Antigen-driven murine CD4⁺ T lymphocyte proliferation and interleukin-2 production are diminished by dietary (ω -3) polyunsaturated fatty acids. J Nutr 2002; 132: 3293-300.