

Original Article

Age-related changes of normal prostate: evaluation by MR diffusion tensor imaging

Ji Zhang^{1,2}, Wei-Zhong Tian², Chun-Hong Hu¹, Tian-Li Niu³, Xiu-Lan Wang², Xiao-Yun Chen²

¹Department of Radiology, The First Hospital Affiliated to Soochow University, Jiangsu Province, Suzhou 215006, China; ²Department of Radiology, Taizhou People's Hospital, Jiangsu Province, Taizhou 225300, China; ³Department of Urinary Surgery, Taizhou People's Hospital, Jiangsu Province, Taizhou 225300, China

Received May 4, 2015; Accepted July 12, 2015; Epub July 15, 2015; Published July 30, 2015

Abstract: In this study, fifty healthy normal volunteers were divided into 3 groups according to age: group A (15-30 years, n=14), group B (31-50 years, n=24), group C (>51 years, n=12). The FA and ADC values in PZ and CZ were measured, and difference between the PZ and CZ were assessed. The results indicated that no significant difference were found in the FA and ADC values between the left and right of PZ ($P>0.05$), but significant differences were observed in the FA and ADC values between PZ and CZ within each group ($P<0.05$). The FA values of PZ in three groups were 0.227 ± 0.052 , 0.202 ± 0.055 , and 0.145 ± 0.034 , respectively. The ADC values were found to be $1.439\pm 0.160\times 10^{-3}$, $1.652\pm 0.256\times 10^{-3}$, and $2.001\pm 0.266\times 10^{-3}$ mm²/s, accordingly. The FA and ADC values in PZ were significantly ($P<0.05$) different between groups. The FA values of CZ in different groups were found to be 0.291 ± 0.083 , 0.287 ± 0.045 , and 0.257 ± 0.059 , respectively; while the corresponding ADC values were $1.374\pm 0.171\times 10^{-3}$, $1.382\pm 0.178\times 10^{-3}$, and $1.415\pm 0.136\times 10^{-3}$ mm²/s, respectively. The FA and ADC values in CZ were not statistically ($P>0.05$) different between groups. *Pearson* correlation analysis results showed that the FA values in PZ havenegative correlation with age ($r=-0.498$, $P<0.05$), while the ADC values exhibited a positive correlation with age ($r=0.682$, $P<0.05$). No correlations between the changes of FA and ADC values and age were noted in CZ. In conclusion, the FA and ADC values in the normal prostatic PZ were age-dependent. FA decreases and ADC increases with age. In contrast, the FA and ADC values in the normal prostatic CZ were not significantly age-related.

Keywords: Prostate, magnetic resonance imaging, diffusion tensor imaging

Introduction

The diffusion tensor imaging (DTI) is a magnetic resonance imaging (MRI) technique that enables the measurement of the pathological conditions at the cellular and molecular levels [1]. Currently, the increasingly mature DTI technique was widely applied to the noninvasive assessment of the nervous and musculoskeletal systems [2, 3], but its potential use for diagnosis of prostate disease is still in the preliminary stage [4, 5]. In this study, DTI was applied to investigate the changes in normal prostate in different age groups. The fractional anisotropy (FA) and apparent diffusion coefficient (ADC) in normal prostate peripheral zone (PZ) and central zone (CZ) were quantified, and their correlations with age were also investigated in an attempt to discern the pathological changes in prostate and thus enable the early detection and diagnosis of prostate diseases.

Materials and methods

Study subjects

A total of 50 normal male volunteers, aged between 22 and 59 years (median age, 39.3 ± 10.6), were recruited for the study between June 2012 and December 2013. All the volunteers had neither major diseases nor clear signs and symptoms of urinary system diseases, and no abnormality in conventional T2-weighted images (T2WI) with fat suppression (T2WI-FS) scans were found. The research protocol in this study was approved by the medical ethics committee of our hospital. Written informed consent was obtained from all patients before commencement of the study.

The volunteers were divided into 3 groups: group A (15-30 years, n=14), group B (31-50 years, n=24), and group C (>51 years, n=12),

MRI for Age-related changes of normal prostate

Table 1. The FA and ADC values in the left and right side of PZ in normal prostate

Groups	cases	FA value		T value	P value	ADC value		t value	P value
		right	left			right	Left		
A group	14	0.236±0.063	0.216±0.046	2.161	0.05>0.05	1.452±0.182	1.425±0.164	0.745	0.726>0.05
B group	24	0.200±0.047	0.204±0.070	-0.347	0.732>0.05	1.622±0.238	1.684±0.308	-1.584	0.127>0.05
C group	12	0.150±0.045	0.141±0.030	0.872	0.402>0.05	1.964±0.244	2.042±0.303	-1.653	0.127>0.05

FA: fractional anisotropy; ADC: apparent diffusion coefficient.

Table 2. The FA and ADC values in PZ and CZ in normal prostate

Groups	cases	FA value		t value	P value	ADC value		t value	P value
		PZ	CZ			PZ	CZ		
A group	14	0.227±0.052	0.291±0.083	-3.346	0.005<0.05	1.439±0.160	1.325±0.187	2.203	0.046<0.05
B group	24	0.202±0.055	0.287±0.045	-7.510	0.000<0.05	1.652±0.256	1.382±0.178	5.080	0.000<0.05
C group	12	0.145±0.034	0.257±0.059	-8.252	0.000<0.05	2.001±0.266	1.415±0.136	7.031	0.000<0.05
F value		9.063	1.190			18.989	0.927		
P value		0.000<0.05	0.313>0.05			0.000<0.05	0.403>0.05		

PZ: peripheral zone; CZ: central zone; FA: fractional anisotropy; ADC: apparent diffusion coefficient.

based on the syllogism of prostate development in adult proposed by Xia et al [6].

Examination methods

All MRI examinations were performed on a clinical 3.0 T Siemens verio MRI scanner equipped with an 8-channel torso phased-array coil to reduce the interference caused by respiratory motion. Images of the prostate for all volunteers were acquired with T2WI-FS in the axial plane and DTI. The volunteers were instructed to keep moderate residual urine in bladder and breathe calmly during the inspection procedure.

The parameter details of the T2WI-FS protocol were: repetition time (TR), 3540 ms; echo time (TE), 124 ms; field of view (FOV), 300 mm×230 mm; matrix size, 230×288; number of slices, 20; slice thickness, 3.0 mm; no interslice gap; flip angle, 150°; signal noise ratio (SNR), 1; number of acquisitions, 3; and scan duration, 2.95 min. The DTI protocol was performed with the spin echo-echo planar imaging (SE-EPI) sequence towards the slice locations identical to T2WI-FS, using the following parameters: TR, 3000 ms; TE, 93 ms; FOV, 230 mm×230 mm; matrix size, 230×128; number of slices, 20; slice thickness, 3.0 mm; no interslice gap; *b* value=0 or 800 s/mm²; noise level, 30; SNR, 1; diffusion direction, 12; number of acquisitions, 6; and scan duration, 4.08 min.

Data analysis

After acquisition, data was transferred to the Siemens syngo workstation and analyzed using

the Neuro 3D software. An experienced observer drew the regions of interests (ROIs) with T2WI-FS maps used as anatomic regions. The FA and ADC values were then determined according to the selected ROIs. A total of six ROIs (8 pixels) were drawn on the maximum peripheral plane, including 2 on each side of the peripheral zone (avoiding peripheral nerve bundles) and 2 in the central zone (avoiding the urethra). The mean FA and ADC values were then calculated for statistical analysis, respectively.

Statistical analysis

All statistical analysis was performed with SPSS software (version 19.0, SPSS, Inc.). A paired *t* test was used to evaluate the differences in FA and ADC values between the left and right side of PZ, as well as the differences between PZ and CZ within groups. The differences in FA and ADC values of PZ and CZ between groups were determined by the one-way analysis of variance (ANOVA) and compared by least significant difference (LSD) algorithm. *Pearson* analysis was used to investigate the correlation between the FA, ADC values of prostate (PZ, CZ) and age, and differences were considered significant when *P*-values were less than 0.05.

Results

As shown in **Table 1**, the FA and ADC values between the left and right side of PZ in normal prostate were roughly similar within groups,

MRI for Age-related changes of normal prostate

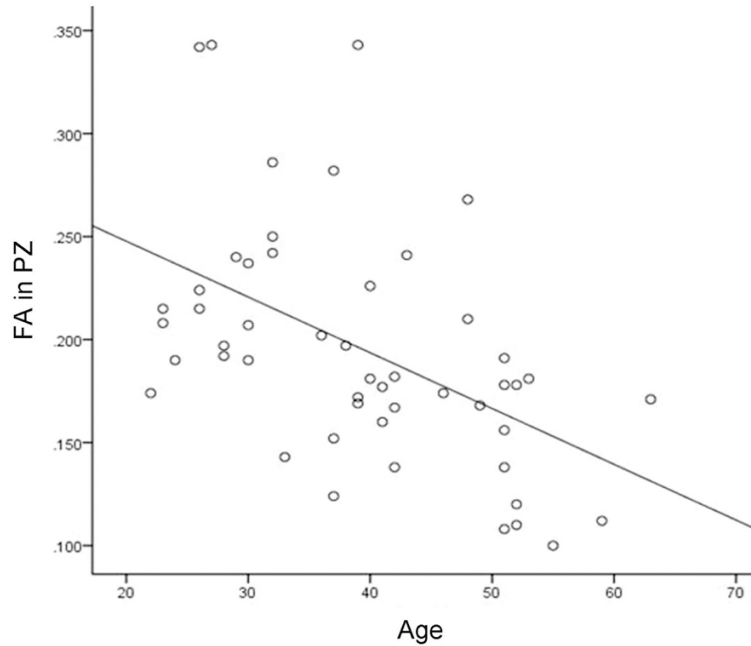


Figure 1. Pearson correlation analysis for the FA in PZ. The FA value was decreasing follows with the age increasing. FA: fractional anisotropy; PZ: peripheral zone.

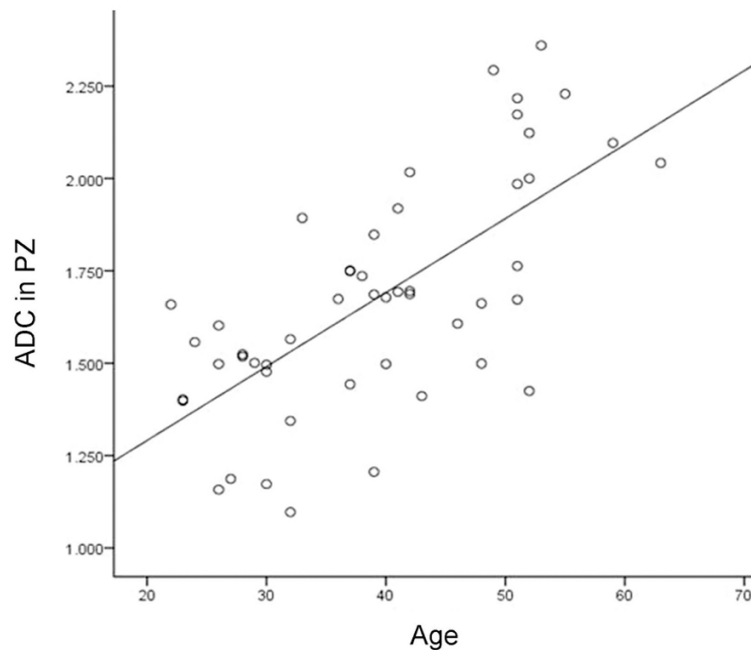


Figure 2. Pearson correlation analysis for the ADC in PZ. ADC value was increasing follows with the age increasing. ADC: apparent diffusion coefficient; PZ: peripheral zone.

and no significant difference were found ($P>0.05$).

Results in **Table 2** show that PZ had lower FA values but higher ADC values than that found in CZ within all groups, and significant differences were observed ($P<0.05$).

Results show that the ADC values increased with an increase in age while the FA values decreased in both PZ and CZ. The FA and ADC values in PZ were significantly ($P<0.05$) different between groups. In contrast, no statistical differences in CZ ($P>0.05$) were found between groups. The difference in FA values of PZ between group A and B were not significant ($P>0.05$); however, significant differences were noted between group A and C, as well as group B and C ($P<0.05$). The ADC values of PZ were statistically different between all groups ($P<0.05$).

Pearson correlation analysis results showed that the FA values in PZ have a negative correlation with age ($r=-0.498$, $P=0.000<0.05$) (**Figure 1**) and the ADC values exhibited a positive correlation with age ($r=0.682$, $P=0.000<0.05$) (**Figure 2**). No correlations between the changes of FA and ADC values and age were observed in CZ.

Discussion

DTI technology is a new MRI modality that developed on the basis of diffusion weighted imaging (DWI). It can provide accurate characterization and quantitative evaluation of the diffusion of water molecules in three-dimensional space, and enable the

assessment of the pathological and physiological changes of tissues at cellular and molecular

levels. Indices such as FA, ADC, anisotropy index (AI), and relative anisotropy (RA) are often used to study the anisotropy of white-matter tracts in DTI measurements. FA and ADC are the two most commonly used tensor measures in clinical analysis. The FA value (from zero to one) indicates the degree of water diffusion anisotropic motion. When FA approaches the value of one implies the anisotropic motion of water molecules, and when FA is zero indicates isotropic diffusion. The diffusion speed and extent of water molecular in different directions was expressed as an ADC value. A higher ADC value suggests a greater diffusion of water molecular, and vice versa [1, 7]. The ADC value characterizes primarily the diffusion of water molecular in prostate gland acinar tissues, and FA value depicts practically the motion trail of water molecular in the tissues of prostatic mesenchyme.

The normal adult prostate is composed of approximately 70% prostatic gland and 30% mesenchyme tissue which mainly consists of smooth muscle and elastic fibers. Both CZ and PZ were made up of smooth muscle fibers and the concomitant glands. The acinar tissues accounted for an estimated 30% in CZ but occupied about 70% in PZ and thus, the CZ possessed much less water compared with PZ. The smooth muscle fibers organized themselves closely in parallel in CZ and thereby, the water diffusion in CZ was greatly limited and the degree of anisotropic diffusion of water molecules was increased. PZ, on the contrary, had minor restriction on water diffusion due to the loose and cross arrangement of smooth muscle fibers [8]. Therefore, the anisotropic diffusion was relatively small in PZ. In this study, the CZ had higher FA values but lower ADC values than that found in PZ in all groups, which was resulted from the structural difference between CZ and PZ and increased with age. These results were consistent with the findings reported by Li et al. [4], Wang et al. [5] and Gürses et al. [9].

The internal structures of prostate were constantly changing due to aging and alterations in sex hormone. The prostate starts to develop and the lumen of the gland appears to be acinar shape from the beginning of adolescence. The lumen increases with age and tends to be vesicular-shaped. Meanwhile the secretion, synthesis, and storage of prostate fluid are also

increased. The lumen continuously expanding and eventually form glandular epithelial cysts as age increased. Moreover, the increased muscle content led to a decreased acinar emptying function as well as aggregated prostatic fluid and consequently, yielding the higher fluid content in PZ and the free diffusion of water molecular. Unlike PZ, in CZ it is the fibrous stromas content that chiefly increased with an increase in age [6, 10, 11].

The results of this study show that the ADC values were gradually increased while the FA values decreased in PZ and CZ as age increased. The changes between FA and ADC values in PZ were statistically significant, and this result was similar to the findings of Gong et al. [12], Zhang et al. [13] and Li et al. [14]. No significant differences between group A and B in FA values were found, which might be attributable to the maldistribution of age: 10 volunteers in group A were nearly age 30 years and 12 volunteers in group B were under age 40 years. Age-related change of FA and ADC values in CZ has not been reported so far. The results of this study suggested that the ADC values increased with age while the FA values decreased. However, there was no statistical difference between the changes, and this could be ascribed to small sample size and uneven distribution of samples. A larger sample size and optimized sample distribution is necessary in further study in order to clarify the age-related changes in CZ.

In conclusion, DTI allowed the measurement of tissue microstructure in normal prostate, and also indicated their age-related changes. There have been promising results of the application of DTI in the diagnosis of prostatic hyperplasia and prostatic cancer [4, 15, 16]. However, it is worth noting that the age difference may affect these DTI parameters. Therefore, taking into account the age effect is necessary during clinical diagnosis. Moreover, a comparative examination should be executed to guarantee the correctness of diagnosis of suspected disease at one side when there is no age-related development difference in left and right PZ.

Acknowledgements

This work was supported by Scientific research project of Jiangsu Provincial Health Department (H201262).

Disclosure of conflict of interest

None.

Address correspondence to: Chun-Hong Hu, Department of Radiology, The First Hospital Affiliated to Soochow University, Suzhou 215006, Jiangsu Province, China. E-mail: hch5305@yeah.net

References

- [1] Basser PJ, Mattiello, LeBihan D. MR diffusion tensor spectroscopy and imaging. *Biophys J* 1994; 66: 259-267.
- [2] Wang S, Kim SJ, Poptani H. Diagnostic utility of diffusion tensor imaging in differentiating glioblastomas from brain metastases. *AJNR Am J Neuroradiol* 2014; 35: 928-934.
- [3] Liang R, Wang X, Li M, Yang Y, Luo J, Mao Q, Liu Y. Potential role of fractional anisotropy derived from diffusion tensor imaging in differentiating high-grade gliomas from low-grade gliomas: a meta-analysis. *Int J Clin Exp Med* 2014; 7: 3647-3653.
- [4] Li C, Chen M, Li S. Diffusion tensor imaging of prostate at 3.0 Tesla. *Acta Radiol* 2011; 52: 813-817.
- [5] Wang XZ, Niu QL, Wang B. The study of normal prostate gland using diffusion tensor imaging. *Int J Med Radiol* 2010; 33: 348-350.
- [6] Xia TL, Kong XT, Su JX. A preliminary report of prostate growth in adult of China. *Chin J Urol* 1993; 14: 287-289.
- [7] Beaulieu C. The basis of anisotropic water diffusion in the nerve system-a technical review. *NMR Biomed* 2002; 15: 435-455.
- [8] Zhang XM, Liang CZ. The morphology and imageology study of normal prostate. *Chin J Urol* 2006; 27: 787-789.
- [9] Gürses B, Kabakci N, Kovanlikaya A, Firat Z, Bayram A, Ulug AM, Kovanlikaya I. Diffusion tensor imaging of the normal prostate at 3 Tesla. *EurRadiol* 2008; 18: 716-721.
- [10] Rahmouni, Yang A, Tempny CM, Frenkel T, Epstein J, Walsh P, Leichner PK, Ricci C, Zerhouni E. Accuracy of In-vivo Assessment of prostatic volume by MRI and Transrectal Ultrasonography. *J Comput Assist Tomogr* 1992; 16: 935-940.
- [11] Singh AK, Kruecker J, Xu S, Glossop N, Ullman K, Choyke PL, Wood BJ. Initial clinical experience with real-time transrectal ultrasonography-magnetic resonance imaging fusion-guided prostate biopsy. *BJU Int* 2008; 101: 841-845.
- [12] Gong T, Hu N, Wang GB. Age-related changes of prostate peripheral zone in normal adults: evaluation by DTI. *J PractRadiol* 2014; 30: 86-89.
- [13] Zhang B, Ren J, Zhang QX. Age-related Changes of Prostate Peripheral Zone in Normal Adults: Evaluation by MR T2 Signal Intensity and ADC Values. *J Pract Radiol* 2011; 27: 740-742.
- [14] Li FY, Wang XY, Xu YF. Age-related Changes of Prostate Peripheral Zone in Healthy Adults: Evaluation by Apparent Diffusion Coefficient. *J PractRadiol* 2006; 22: 1496-1499.
- [15] Gürses B, Tasdelen N, Yencilek F. Diagnostic utility of DTI in prostate cancer. *Eur J Radiol* 2011; 79: 172-176.
- [16] Park SY, Kim CK, Park BK, Ha SY, Kwon SY, Kim B. Diffusion-tensor MRI at 3 T: differentiation of central gland prostate cancer from benign prostatic hyperplasia. *AJR Am J Roentgenol* 2014; 202: W254-262.