

## Original Article

# Effects of high mobility group box 1 and nuclear factor $\kappa$ B on neointimal hyperplasia after common carotid artery balloon injury

Huadong Liu, Shaohong Dong, Wei Xiong, Qiyun Liu, Bihong Liao

*Department of Cardiovascular, Shenzhen People's Hospital, Shenzhen 518020, P. R. China*

Received March 13, 2015; Accepted August 3, 2015; Epub August 15, 2015; Published August 30, 2015

**Abstract:** This study is to investigate the effects of high mobility group box 1 (HMGB-1) and nuclear factor  $\kappa$ B (NF- $\kappa$ B) on intimal hyperplasia after carotid artery balloon injury. A total of 28 male SD rats were subjected to balloon catheter injury at left side carotid artery and this side was considered as experimental group. The right side was taken as control group. Common carotid arteries were harvested at 6 h, 3 d, 7 d and 14 d after balloon injury. The intimal thickness and lumen area were analyzed by HE staining and computerized method. HMGB-1 expression was tested by RT-PCR and NF- $\kappa$ B was detected by EMSA. Among the 28 rats, 4 were excluded due to failed modeling or death and the other 24 rats were included for analysis. Carotid endarterectomy, intimal hyperplasia and restenosis were found after balloon injury. Intimal hyperplasia appeared on 3 d and was significant on 14 d after injury. The ratio of intima/media in the experimental group increased significantly compared with the control group ( $P < 0.05$ ). HMGB-1 was scarcely expressed in control group. It increased 6 h and peaked on 14 d after injury, with significant difference compared with the control group ( $P < 0.01$ ). Similarly to HMGB-1, NF- $\kappa$ B was rarely expressed in control group, and its level increased since 6 h and peaked on 14 d after injury. Intimal hyperplasia after carotid artery balloon injury was found in rat model and this might be induced by enhanced expression of HMGB-1 and NF- $\kappa$ B.

**Keywords:** High mobility group box 1, nuclear factor  $\kappa$ B, balloon injury, intimal hyperplasia, rat

## Introduction

At present, interventional therapy is the main treatment method for coronary heart disease as it can significantly raise patients' life quality and improve the prognosis. For patients with acute myocardial infarction, interventional therapy is even more important because it can save the lives. However, there are still shortcomings in vascular interventional treatment, for instance, postoperative restenosis after interventional therapy affects the long-term results. And restenosis is the major subject remains to be solved in cardiovascular disease field currently. Restenosis is the imbalance result during the process of vascular interventional injury repair, intimal hyperplasia and vascular remodeling after intervention. It is a complex process mediated by a series of cytokines, chemokines and growth factor and it is documented that its core mechanism is inflammation and immune reaction [1].

Nuclear factor  $\kappa$ B (NF- $\kappa$ B), as a kind of transcription factor that playing a variety roles in regulating various genes, has been demonstrated to be involved in the pathological and physiological process of atherosclerosis, restenosis after angioplasty and other vascular proliferative lesion. High mobility group box-1 (HMGB-1), is a member of high mobility group chromosomal protein family secreted by monocytes and macrophages. HMGB-1 is an important inflammatory factor that can induce a variety of cell chemotaxis. It has been identified as a novel proinflammatory cytokine and has been paid more and more attention to [2].

The effects of NF- $\kappa$ B and HMGB-1 in restenosis after vascular injury and the relationship between them are not yet clear, in this study, we aimed to examine activity changes of NF- $\kappa$ B and HMGB-1 and investigate the relationships among these two factors and intimal hyperplasia and vascular remodeling.

## Materials and methods

### *Model preparation*

A total 28 male SD rats weighing 250-300 g were purchased from Guangzhou Medical Experimental Animal Center. About 12 h before model preparation, low molecular weight heparin with a dosage of 600 U/kg was applied to the rats by subcutaneous injection. After anaesthetized with 100 g/L chloral hydrate, the rats were fixed in the micro operation platform and the left external carotid artery was cleared.

External carotid artery distal, occipital artery, superior thyroid artery and ascending pharyngeal artery were separated and ligated, meanwhile, internal carotid artery and proximal part of the left common carotid artery were temporary ligated.

A 2.0  $\times$  20 mm balloon catheter (Medtronic, Minnesota, USA) was inserted into proximal cut of external carotid artery with a depth of about 2 cm. After maintaining a pressure of 3 atmospheric pressure for 30 s using a pressure pump, the catheter was slowly withdrawn back to the site of insertion and the pressure was dropped to zero, a total of three times. Once completed, the catheter was removed and the wound was washed with heparin saline. The ligation of external carotid artery proximal opening was carried and the temporary ligations of internal carotid artery and proximal part of the left common carotid artery were released. Then wound was closed and 200000 units of penicillin were applied to prevent infection. Daily subcutaneous injection of low molecular weight heparin was performed so as to prevent postoperative thrombosis.

### *Light microscope observation*

Carotid artery tissue was fixed in formaldehyde, embedded with paraffin and cut into sections. After routine HE staining, the morphological changes in the cross section of vessel segment were observed under light microscope. Each slice was arranged in the microscopic image analyzer, each specimen was measured continuously for 3 sections, and the average value was taken. The tissue between internal elastic membrane and internal surface was neointima and the tissue between external elastic membrane and internal elastic membrane was tuni-

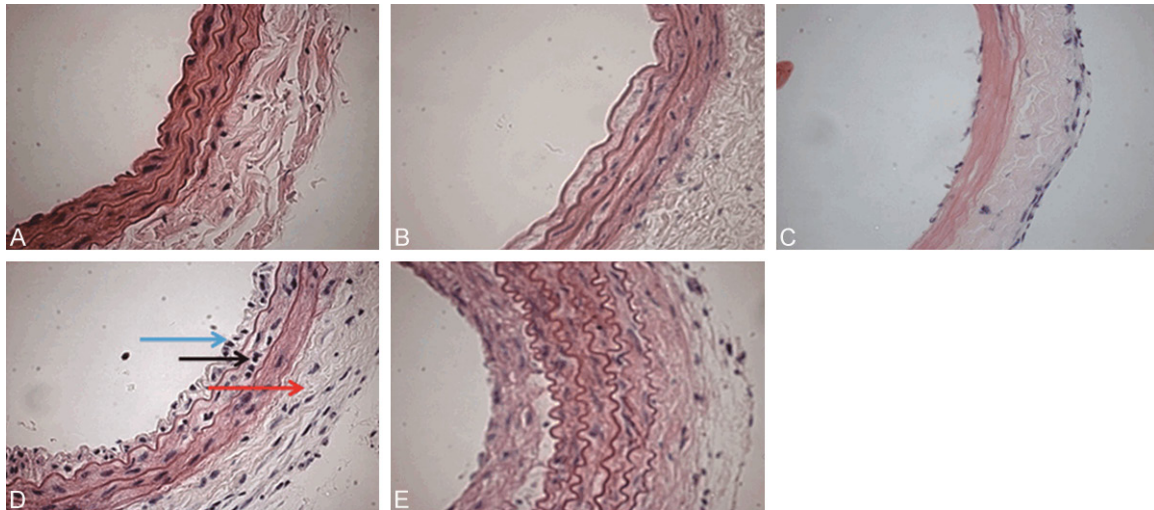
cae media. The areas of neointima and tunicae media were read directly with image analyzer, the ratio of neointima to tunicae media (I/M) was calculated for indicating the degree of intimal hyperplasia. The data were measured by single blind method, and the surveyors have nothing to do with the experiment.

### *RT-PCR detection*

Total RNA was extracted with commercial kit (Promega, Madison, USA) strictly according to the protocol provided by the company and 2  $\mu$ g total RNA was used for reverse transcription. The cDNA achieved was used for PCR of HMGB-1 and  $\beta$ -actin genes.  $\beta$ -actin was taken as internal reference. The forward and reverse primers for HMGB-1 and  $\beta$ -actin were 5'-GCA AAC CGT TCC CAC TCT TAC-3', 5'-TGA CTG ACT TGG ACT GTT GCT TT-3' and 5'-CCT GCT TGC TGA TCC-3', 5'-CTG ACC GAG CGT GGC TAC-3', respectively. High temperature starting method was used for real-time fluorescent quantitative PCR and standard internal reference coupled with control group was amplified for each sample. After quantitative PCR, relative quantitative RQ values were used for statistical analysis.

### *Electrophoretic mobility shift assay*

Rat arterial tissue was cut, pulverized in liquid nitrogen and suspended with 400  $\mu$ L Laemmli Sample Buffer (LA liquid) on ice for 15 min. The samples were then centrifuged at 20000 g for 5 min, the supernatant was discarded, and the sediment was suspended with 25-40  $\mu$ L Luria-Bertani (LB) liquid, stirred on ice for 20 min. The samples were then centrifuged again at 20000 g for 5 min and the supernatant was kept. After measured the protein concentrations, the samples were packed and stored at -80°C. The sequences of NF- $\kappa$ B (biotin labeled) probe were 5'-AGT TGA GGG GAC TTT CCC AGGC 3' and 3'-TCA ACT CCC CTG AAA GGG TCCG-5' respectively. The probes were mixed with 5  $\mu$ L nuclear protein extract into a 20  $\mu$ L buffer system. After binding at room temperature for 20 min, the samples were subjected to non denaturing polyacrylamide gel electrophoresis, transferred to Nylon membrane and fixed at 70°C for 1 h. Biotin labeled DNA was detected with chemiluminescence, the membrane was placed on a film cartridge, developed under X ray and finally analyzed using image analysis system BioSenSC300 (shanghai Bio-tech Co., Ltd, Shanghai, P. R. China).



**Figure 1.** Pathological changes of the common carotid artery (HE staining  $\times 10$ ). (A-E) Respectively represent the pathological changes of 6 h, 3 d, 7 d, 14 d after injury of normal carotid artery and carotid artery balloon (HE staining 10 times), the graph from left to right are intima and media and adventitia, as shown in (D) blue, black, red arrow referred to respectively of intima and media and adventitia.

**Table 1.** The ratio of intima to tunicae media (I/M) in each period after balloon injury ( $\bar{X} \pm s$ )

| Date | 6 h                | 3 d                | 7 d                | 14 d              |
|------|--------------------|--------------------|--------------------|-------------------|
|      | $0.14 \pm 0.004^*$ | $0.72 \pm 0.009^*$ | $3.67 \pm 0.014^*$ | $1.436 \pm 0.022$ |

Note: Compared to 14 d,  $^*P < 0.01$ .

### Statistical analysis

All the statistical analyses were performed using SPSS version 13.0 (SPSS Inc, Chicago, IL, USA) and the data were expressed as  $\bar{X} \pm s$ . Variance analysis was used to compare the differences between groups, and t test was used for comparison between groups.

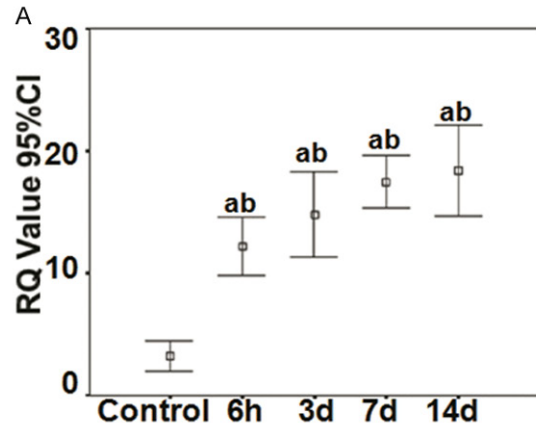
### Results

#### Animal modeling situations

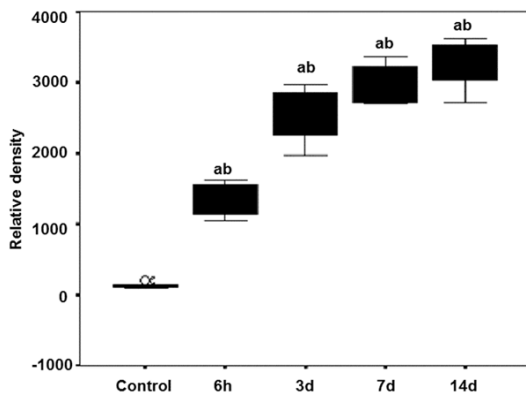
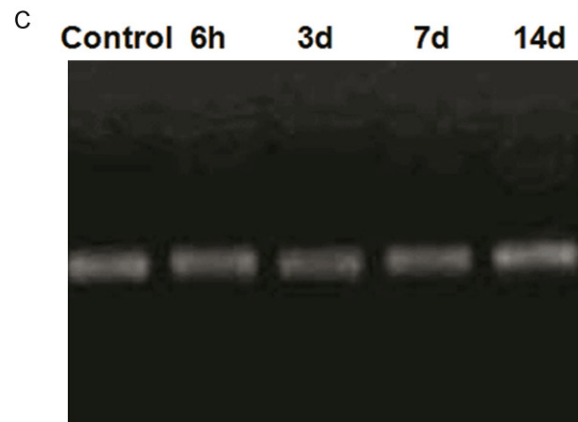
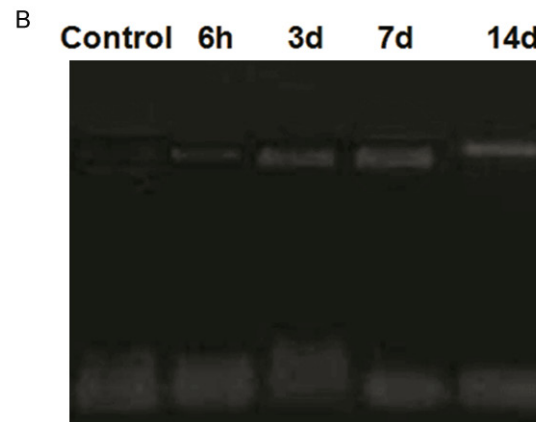
To imitate neointimal hyperplasia after injury, animal model was constructed using rats. There were 28 rats used for model building, 2 were died and 2 were with complications, finally, 24 rats were used for further study. The success rate of operation was 85.7%, the mortality rate was 7.1%, and the complications were mainly postoperative common carotid artery thrombosis, occlusion and contracture. The result indicated that we had created animal model successfully.

#### Pathological changes after balloon injury

To identify pathological changes in carotid artery after balloon injury, HE staining was carried out and the specimen was observed under light microscope. It was shown that in normal rat carotid artery, there was only mono-layer endothelial cell lining the intima without smooth muscle cell invasion. Tunicae media was made up by 3 to 5 layers of circular arranged elastic membrane and smooth muscle cells. However, after balloon injury, artery endothelial denudation appeared, and internal elastic lamina fracture with elasticity lost was seen in local area. Neointimal hyperplasia appeared 3 d after injury and was gradually clear from 7 d. The lumen was centripetal or eccentric stenosis and fusiform muscle cells of tunicae media arranged in disorder. Neointimal hyperplasia was most significant 14 d after injury and there were massive smooth muscle cells in neointima with increased fiber content. I/M increased 3 d after injury and peaked on 14 d (**Figure 1**). On 14 d, I/M was 6.5 times larger than that of 6 h ( $P < 0.01$ ) and was 1.7 times larger than that of 3 d ( $P < 0.01$ ) (**Table 1**). Together, HE staining showed that neointimal hyperplasia appeared after balloon injury in the damaged common carotid artery.



**Figure 2.** Expression of HMGB-1 in common carotid arteries at different times after balloon injury. (A) Control, 6 h, 3 d, 7 d, 14 d respectively represent HMGB-1 expression levels in the control group, 6 h, 3 d, 7 d and 14 d after carotid artery balloon injury. <sup>a</sup>Compared with the control group  $P < 0.05$ ; <sup>b</sup>Compared with the previous period,  $P < 0.05$ . Electrophoretic mobility shift assay of HMGB-1 (B) and  $\beta$ -actin (C) at different times after balloon injury.



**Figure 3.** Expression of NF- $\kappa$ B in common carotid arteries at different times after balloon injury. Control, 6 h, 3 d, 7 d, 14 d respectively represent NF- $\kappa$ B expression levels in the control group, 6 h, 3 d, 7 d and 14 d after carotid artery balloon injury. <sup>a</sup>Compared with the control group  $P < 0.05$ ; <sup>b</sup>Compared with the previous period,  $P < 0.05$ .

#### Expression of HMGB-1 in the vascular wall

To reveal the expression condition of HMGB-1 after balloon injury, RT-PCR was performed. In the control group, only a small amount of

HMGB-1 was expressed. However, HMGB-1 increased obviously 6 h after injury. This state continued and peaked on 14 d, with significant difference while compared to the control group (Figure 2). It is reasonable to assume that after balloon injury, HMGB-1 expression in vascular wall increases.

#### Activity changes of NF- $\kappa$ B in vascular wall

To understand the changes of NF- $\kappa$ B in vascular wall, nucleoprotein was extracted and EMSA was carried out. The result showed a rather low binding activity of NF- $\kappa$ B DNA in the control group and the binding activity greatly increased after injury. NF- $\kappa$ B increased 6 h after injury and maximized on 14 d (Figure 3), which is in consistent with the situation of neointimal hyperplasia and HMGB-1 expression. Together, the data clearly revealed that NF- $\kappa$ B increases in vascular wall after injury.

#### Discussion

Restenosis is a complex pathophysiological process involving multiple factors, and to date,



its occurrence mechanism has not been elucidated clearly. Recently, vascular endothelial cell injury, tunica media smooth muscle cell proliferation, migration and extracellular matrix accumulation induced intimal thickening and vascular remodeling are shown to be the major causes of restenosis. It has been implicated that endothelial cell injury and inflammatory reaction are the initiating factors and immune and inflammatory reactions are involved in the whole process of restenosis. The whole process of restenosis includes endothelial damage, smooth muscle cell proliferation and vascular remodeling [3, 4]. As a result, how to effectively inhibit the inflammatory reaction, reduce the migration and proliferation of smooth muscle cells, find out restenosis promoting inflammation mediators and perform intervention are the key to reduce restenosis. In the present study, rat common carotid artery balloon injury model was used to investigate the relationships among HMGB-1, NF- $\kappa$ B and neointimal hyperplasia. It was found that during the process of neointimal hyperplasia, HMGB-1 and NF- $\kappa$ B were rapidly activated and their expression levels increased continuously, in consistent with the increased degree of neointimal hyperplasia. This indicated that HMGB-1 and NF- $\kappa$ B might be involved in the process of vascular restenosis and remodeling.

High mobility group proteins (HMGs) are a kind of evolutionary highly conserved non histone chromosomal binding proteins, named after their small molecular weights and fast transfer rates in polyacrylamide gel electrophoresis. A recent study has showed that HMGB-1 is a novel advanced inflammatory mediator with more important meaning in the aspects of inflammation, tissue repair, angiogenesis and tumor metastasis while compared to early stage inflammatory mediators such as IL-1, IL-6 and TNF- $\alpha$ . It has been confirmed that HMGB-1 can be secreted by necrotic cells, meanwhile, it can be secreted to the extracellular by monocyte macrophages and dendritic cells in the form of active synthesis or secretion after stimulated by early stage inflammatory factors like LPS, IL-1 and TNF- $\alpha$ . Extracellular HMGB-1 can bind to receptor of advanced glycation end products (RAGE) or toll like receptor of the target cells such as immune cells. And then it can activate a number of signal transduction pathways such as mitogen activated protein kinase,

IL-1 receptor associated kinase 1, tumor necrosis factor receptor associated factor, as a result downstream NF- $\kappa$ B enters the nucleus and is activated, hence, mediates inflammatory and immune responses [5, 6].

NF- $\kappa$ B is one of the key factors regulating transcription of various genes in cell [7]. It is related to the production of a series of cytokines, inflammatory mediators and proteases, and it is connected to cell proliferation, extracellular matrix accumulation and cell apoptosis [8, 9]. Current studies suggest that when cells are in the resting state, NF- $\kappa$ B locates in the cytoplasm with its subunit P65 binding to NF- $\kappa$ B inhibitor protein (I $\kappa$ B) and covering nuclear localization signal P50 protein. This trimer is in an inactivated state in the cytoplasm. When the body is stimulated by external factors, with the participation of protein kinase and protein phosphatase, I $\kappa$ B is phosphorylated and dissociates from NF- $\kappa$ B/I $\kappa$ B dimer. As a result, nuclear localization signal P50 protein is exposed and NF- $\kappa$ B is activated. NF- $\kappa$ B then transfers into the nucleus and binds to specific DNA sites, starts gene transcription [10], participates related gene transcription and regulation in the process of inflammatory reaction, neointimal hyperplasia and smooth muscle cell proliferation.

In this study, the changes of HMGB-1 and NF- $\kappa$ B expression in the process of intimal hyperplasia after vascular injury was detected and it was found that in the control group only a small amount of HMGB-1 and NF- $\kappa$ B were expressed. However, in carotid artery stenosis rat model, these two factors increased during the process of vascular smooth muscle increasing, and enhanced as the time went on. It is reasonable to assume that HMGB-1 and NF- $\kappa$ B are involved in the process of vascular restenosis and NF- $\kappa$ B is the downstream transcription factor regulated by HMGB-1. HMGB-1 might play a role in vascular remodeling via NF- $\kappa$ B. Autieri et al. [11] confirmed that antisense oligonucleotide of NF- $\kappa$ B subunit P65 protein can inhibit adhesion and proliferation of vascular smooth muscle cells in vitro. It even can affect neointimal hyperplasia in rat common carotid artery balloon injury model, further indicating that NF- $\kappa$ B is closely related to restenosis after angioplasty, HMGB-1 and NF- $\kappa$ B might be targets for the prevention of restenosis [12-14]. In total, inhib-

iting the activities of HMGB-1 and NF- $\kappa$ B from different aspects might provide a new mean of prevention and treatment for restenosis.

## Acknowledgements

This study was supported by the 2012 Shenzhen Science and Technology Plan Project (No. 201203122).

## Disclosure of conflict of interest

None.

**Address correspondence to:** Huadong Liu, Department of Cardiovascular, Shenzhen People's Hospital, No. 1007, Dongmen North Road, Shenzhen 518020, P. R. China. Tel: +86-0755-25533018-3200; E-mail: lhd333@126.com

## References

- [1] Giordano A and Romano A. Inhibition of human in-stent restenosis: a molecular view. *Curr Opin Pharmacol* 2011; 11: 372-7.
- [2] Yang H and Tracey KJ. Targeting HMGB1 in inflammation. *Biochim Biophys Acta* 2010; 1799: 149-56.
- [3] Lipke EA and West JL. Localized delivery of nitric oxide from hydrogels inhibits neointima formation in a rat carotid balloon injury model. *Acta Biomater* 2005; 1: 597-606.
- [4] Niccoli G. Inflammation: a key mechanism of adverse reactions to coronary stent and a target for future therapies. *Curr Vasc Pharmacol* 2013; 11: 377-8.
- [5] Lee SA, Kwak MS, Kim S and Shin JS. The role of high mobility group box 1 in innate immunity. *Yonsei Med J* 2014; 55: 1165-76.
- [6] Yang Z, Deng Y, Su D, Tian J, Gao Y, He Z and Wang X. TLR4 as receptor for HMGB1-mediated acute lung injury after liver ischemia/reperfusion injury. *Lab Invest* 2013; 93: 792-800.
- [7] Dobrovolskaya MA and Kozlov SV. Inflammation and cancer: when NF- $\kappa$ B amalgamates the perilous partnership. *Curr Cancer Drug Targets* 2005; 5: 325-44.
- [8] Hoffmann A, Levchenko A, Scott ML and Baltimore D. The I $\kappa$ B-NF- $\kappa$ B signaling module: temporal control and selective gene activation. *Science* 2002; 298: 1241-5.
- [9] Saito T, Hasegawa Y, Ishigaki Y, Yamada T, Gao J, Imai J, Uno K, Kaneko K, Ogihara T, Shimosawa T, Asano T, Fujita T, Oka Y and Katagiri H. Importance of endothelial NF- $\kappa$ B signalling in vascular remodelling and aortic aneurysm formation. *Cardiovasc Res* 2013; 97: 106-14.
- [10] Medeiros MC, Frasnelli SC, Bastos Ade S, Orrico SR and Rossa C Jr. Modulation of cell proliferation, survival and gene expression by RAGE and TLR signaling in cells of the innate and adaptive immune response: role of p38 MAPK and NF- $\kappa$ B. *J Appl Oral Sci* 2014; 22: 185-93.
- [11] Autieri MV. Expression of anaphase promoting complex 5 in balloon angioplasty injured rat carotid arteries and norepinephrine stimulated human vascular smooth muscle cells. *Biochem Biophys Res Commun* 2001; 282: 723-8.
- [12] Peng Y, Gallagher SF, Haines K, Baksh K and Murr MM. Nuclear factor- $\kappa$ B mediates Kupffer cell apoptosis through transcriptional activation of Fas/FasL. *J Surg Res* 2006; 130: 58-65.
- [13] Tse AK, Wan CK, Zhu GY, Shen XL, Cheung HY, Yang M and Fong WF. Magnolol suppresses NF- $\kappa$ B activation and NF- $\kappa$ B regulated gene expression through inhibition of I $\kappa$ B kinase activation. *Mol Immunol* 2007; 44: 2647-58.
- [14] Musumeci D, Roviello GN and Montesarchio D. An overview on HMGB1 inhibitors as potential therapeutic agents in HMGB1-related pathologies. *Pharmacol Ther* 2014; 141: 347-57.