Int J Clin Exp Med 2015;8(8):11890-11895
www.ijcem.com /ISSN:1940-5901/IJCEM0010163

Review Article

Fusion of a supernumerary tooth to right mandibular second molar: a case report and literature review

Min Zhu[1*], Chao Liu[2*], Shuangshuang Ren[1], Zintong Lin[3], Leiying Miao[1], Weibin Sun[4]

[1]Department of Cariology and Endodontics, Nanjing Stomatological Hospital, Medical School of Nanjing University, Nanjing, P. R. China; [2]Department of Orthodontics, Nanjing Stomatological Hospital, Medical School of Nanjing University, Nanjing, P. R. China; [3]Department of Dentomaxillofacial Radiology, Nanjing Stomatological Hospital, Medical School of Nanjing University, Nanjing, P. R. China; [4]Department of Periodontology, Nanjing Stomatological Hospital, Medical School of Nanjing University, Nanjing, P. R. China. [*]Equal contributors.

Received May 12, 2015; Accepted June 26, 2015; Epub August 15, 2015; Published August 30, 2015

Abstract: Gemination or fusion is a rare occurrence in the mandibular posterior teeth. The aim of this article is to describe the problems encountered and the strategy employed in treating such cases. A 34 years old patient came with the complaint of spontaneous and radiating pain in the right mandibular posterior region. The tooth in concern was an anomalous 'double' second mandibular molar diagnosed as having necrotic pulp with chronic apical abscess of endodontic origin. The present case emphasizes the importance of identifying anatomical anomalies during treatment of fused teeth with supernumerary tooth, and the need for the use of advanced imaging modalities like CBCT which is a critical aid in the diagnosis of such cases. Fused teeth can be managed quite efficiently by an overall combined treatment including both endodontic and periodontal therapy.

Keywords: Fusion, cone-beam computed tomography, supernumerary teeth, endodontic treatment

Introduction

Fusion of teeth is a developmental anomaly, which stem from the union of two teeth originating both in primary and the permanent dentition [1]. They are not considered to be common, and have a frequency of occurrence ranging between 0.3% and 3.8% in the general population [2]. These teeth are identified mainly due to their unique position and form in the dental arch. According to their position, they are termed as distomolar, mesiodens, paramolars and mesiomolars [3]. They can be joined by enamel, dentine, and their pulp and the canals may either be connected or be apart based on the stage of development when the fusion occurred. The epithelial and mesenchymal germ layers are involved in this process, culminating in irregular tooth morphology [4]. The degree of fusion depends on the stage of tooth development, with the union of dentin being the main criterion [5]. Fused teeth are found predominantly in the anterior region, and the incisors of the deciduous dentition are the most frequently affected [6]. The union of two discrete tooth germs results in fusion, leading to the formation of a single tooth and these teeth are joined by the dental hard tissue but show separate pulp cavities [7]. Supernumerary tooth are a developmental anomaly and are defined as those tooth/teeth in addition to the normal series of deciduous or permanent dentition. Supernumerary tooth can be found in any part of the jaws, although its incidence is highest in the maxillary incisor. Supernumerary tooth can also be occasionally found fused to a normal tooth [8]. Fused teeth have an unknown etiology but the pressure or physical forces producing close contact between two developing teeth have a considerable influence in its formation and have been reported as one possible cause [9]. Other contributing factors could include hereditary and racial differences [10].

A common differential diagnosis for fusion is gemination but the latter causes crowding while fusion causes ectopic eruption more commonly [11]. Mader's "two tooth" rule is a popular way of identifying the difference between fusion and gemination [12].

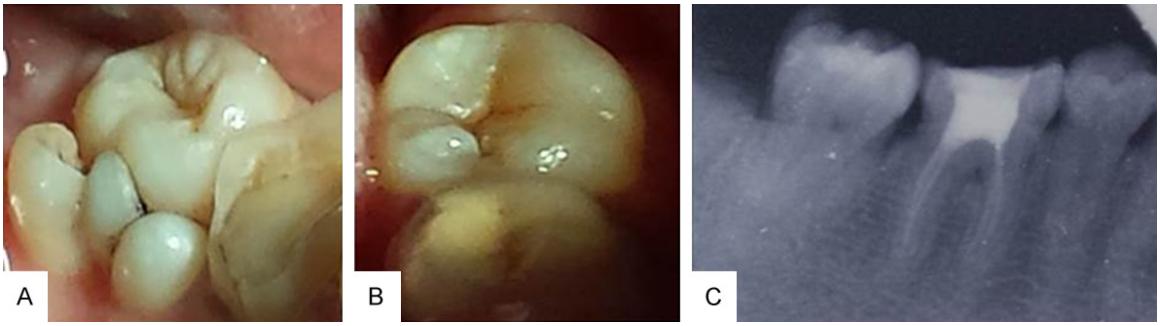

Figure 1. A, B. Pre-operative photograph: Intraoral clinical occlusal view. C. Pre-operative periapical radiograph: the right mandibular second molar.

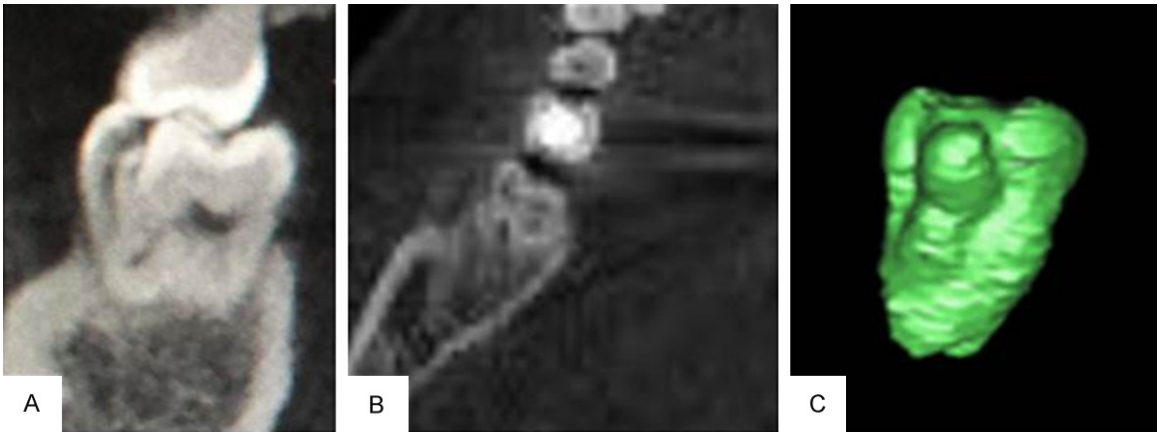

Figure 2. CBCT Images of the right mandibular second molar. A. Three dimensional reconstruction of the coronal position. B. Three dimensional reconstruction of the horizontal position. C. Three dimensional reconstruction of the tooth.

Fusion of permanent and supernumerary teeth usually occurs in the anterior region of the Maxilla. However, fusions involving molars are rarely reported. The purpose of this article is to report endodontic management and the periodontal therapy of a Mandibular second molar that appeared to have been fused with a supernumerary tooth and the importance of use of CBCT as a valuable diagnostic aid in the treatment of such complex cases.

Report of case

Clinical information

A 34-year-old female patient presented to the Department of Conservative Dentistry and Endodontics with a chief complaint of spontaneous and radiating pain in the right mandibular posterior region. The patient gave a history of pain for duration of one year and was increased in intensity to cold and hot stimulation.

Upon clinical intraoral examination (**Figure 1A**), three extra cusps were detected on the buccal aspect of the right mandibular second molar, and a carious lesion was noticed in the centre of the middle and distal abnormal cusps. Instrument probing caused pain, and obvious pain was elicited to hot and cold temperature testing. Percussing created an increase in the intensity of pain and mobility of the tooth was within physiologically normal limits. Periodontal probing showed 4 mm depth subgingivally in the disto-buccal aspect. The left mandibular second molar appeared to be normal in shape (**Figure 1B**).

Radiographic evaluation was unclear for 47 root canal morphology (**Figure 1C**). The CBCT images revealed a connection between the root canal of the mesial abnormal cusp and 47 mesiobuccal root (**Figure 2**).

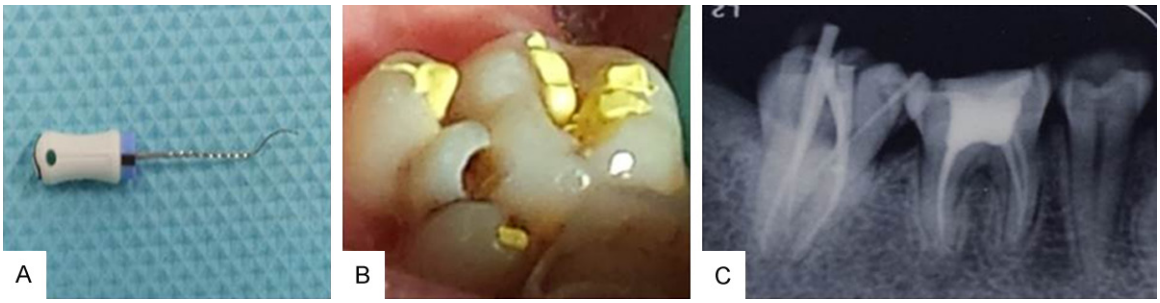

Figure 3. A. Three-dimensional bending of the instrument for the preparation of the mesiobuccal root. B. Operative photograph: Occlusal view. C. Working length determination.

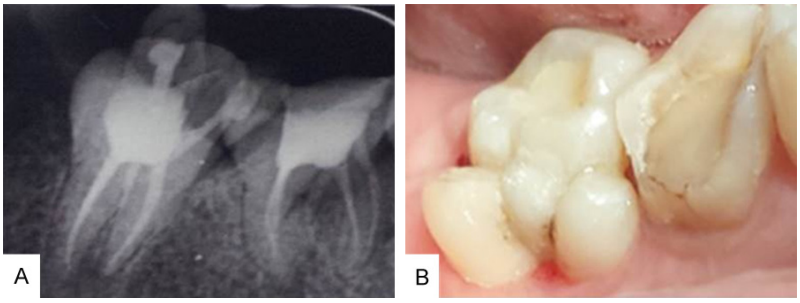

Figure 4. Postoperative photograph: A. Immediate postoperative radiograph. B. Clinical image of restored 46, 47.

Treatment plan

Treatment was planned after exhaustive communication with the patient. It was proposed to start initially with root canal treatment and continue with periodontal therapy. The treatment was planned in consensus with the patient after taking a written informed consent.

Therapeutic process

The pulp was exposed after administering local anesthesia. The canal orifices identified were mesiobuccal (MB), mesiolingual (ML), distal (D), mesial (M) of the abnormal cusps, but the middle cusp was not identified. MB was found to have a three dimensional bending (**Figure 3A**). The pulpal tissue was excavated. When the pulp was irrigated, the communication between the MB and the mesial abnormal cusp was confirmed, and CBCT also confirmed the same evidence. The canals of the tooth were prepared using hand files and M two nickel-titanium alloy file, and were enlarged to the size of a No. 20 file. The working lengths of MB, ML, D, were 15, 18.5, and 19 mm, and the mesial and distal buccal abnormal cusp lengths were 15 and 19 mm, respectively (**Figure 3B**, **3C**). The tooth was then subjected to a temporary filling.

The patient returned to the dental clinic for her second visit after 1 week and the tooth was asymptomatic. The canals were obturated and after completion of root canal treatment, the crown was restored with composite resins, with minimal occlusal correction (**Figure 4**). After 1-month follow-up, the treatment appeared to be successful and the patient's oral health was restored.

Discussion

Dental fusion is a morphological dental anomaly, characterized most commonly by the appearance of a clinically apparent wide tooth. Although a considerable number of cases have been reported in the literature, differential diagnosis of this condition usually lands up in confusion between fusion and gemination. A combination of careful case history recording and a thorough clinical and radiographic evaluation usually provides the necessary information for the appropriate diagnosis of such unusual cases. Fused teeth have distinct clinical symptoms and are more prevalent in primary dentition (0.5%) than in permanent dentition (0.1%). The occurrence of fusion in permanent posterior teeth is rare [13]. Fusion usually involves the incisors and canines. [14-17]. Fused teeth normally appear quite unaesthetic owing to their unusual and irregular tooth morphology. These abnormal teeth have a high affinity to dental caries, periodontal problems, and spacing between teeth can also be an

issue that needs to be addressed in such cases [18].

Fusion is usually the cause of reduced number of teeth in the dentition and this important fact helps to differentiate it from gemination. However, there can be exceptions, like the present case, where the fusion is seen to be occurring between a supernumerary tooth and a normal tooth. Radiographic examinations are vital for the diagnosis of such complex cases. Among the various radiological techniques, conventional intraoral periapical views have a limited use in diagnosis since they usually cause superimposition of 2-dimensional images of a 3-dimensional object. Although the conventional multidetector computed tomography (CT) imaging was introduced to dental practice in the early 1990s [19], it is more recently that a new diagnostic imaging modality, CBCT, started to be used in dentistry as a preferred mode of radiological investigation due to its low radiation dose and effective maxillofacial imaging. Matherne et al. reported that CBCT imaging is highly effective in identifying the root canal systems and morphology of teeth [20]. In our case, CBCT revealed pulp canals that were separated and crowns that were joined at the level of dentin. Hence, with the available data that were clinically recorded, we diagnosed this as a case of fusion. According to Song et al., teeth affected with gemination have a single pulp canal and root, whereas fused teeth have separate pulp canals with combined dentin [21]. Presence of fused teeth in the posterior permanent dentition is a rare condition, but nevertheless, they are dental anomalies of very high significance and can affect any tooth in the mouth. Fusion of teeth needs to be properly identified and a thorough radiographic examination is an absolute pre-requisite prior to therapy for a successful result. Many theories have been proposed for the etiology of fusion. These theories consider genetic factors, developmental and environmental factors, traumatic or inflammatory causes [22].

In this specific case, the anomalous tooth was visualized clinically and radiographically. 3D CBCT was used to confirm the diagnosis and to aid in its management. The treatment was problematic, owing to the diagnosis: Distal (D) and Mesial (M) of the extra cusps orifices could be identified but not the middle cusp. The communication between the MB and the mesial abnormal cusp was confirmed, with same working lengths, i.e. 15 mm. 47 MB was found to have a three dimensional bending.

In endodontic management, periapical radiographs are mandatory for diagnosis, treatment, and follow-up, but the conventional intraoral periapical views provide only a two-dimensional view of the object. CBCT was suggested for the complex bizarre anatomy of the root canals for its useful diagnostic value with three-dimensional imaging, as this technology can provide an excellent visualization of the fused teeth, and the shape and number of the root canal system. Also, it provides the clinician with guidance for diagnosis and presence of any tooth damage and is a highly useful aid for a successful endodontic treatment. Patience and utmost care is necessary for these types of procedures, and progress should be measured in steps, rather than in haste. The preparation of the root canals must be in proper shape, to avoid complications such as instrument separation and perforation.

Bicuspidization could be considered as one of treatment option for teeth fusion. Previously reported treatment options include bicuspidization upon completion of endodontic treatment for the fused tooth, orthodontic treatment for alignment, and extraction of the unwanted part [23, 24]. Due to the abnormal size and shape of crown and root as well as misalignment, both endodontic and esthetic issues should be addressed. This usually requires a multidisciplinary approach to the treatment [25-27].

In summary, a successful endodontic management of a fused mandibular second molar with a supernumerary tooth that has a bizarre anatomy needs deliberation at every step. The clinician should be cautious of every detail of the tooth morphology in order to improve the success rate. A multispecialty approach with dentists of various specialties teaming up for better treatment outcomes can result in a successful culmination of a complicated treatment plan.

Acknowledgements

This work was supported by grants from the National Natural Science Foundation (No: 81271155, 30830108, 81300852), Jiangsu Province Natural Science Foundation of China (BK20130079), Key Project of Science and

Technology Bureau of Jiangsu Province (No. BL2013002), the Youth Start Fund of Nanjing City, (No. 2011-19-198*); the Third Level Fund for the Young Talents in the Health Field of Nanjing City.

Disclosure of conflict of interest

None.

Address correspondence to: Dr. Leiying Miao, Department of Cariology and Endodontics, Nanjing Stomatological Hospital, Medical School of Nanjing University, 30 Zhongyang Road, Nanjing 210008, P. R. China. E-mail: mly0720@163.com; Dr. Weibin Sun, Department of Periodontology, Nanjing Stomatological Hospital, Medical School of Nanjing University, 30 Zhongyang Road, Nanjing 210008, P. R. China. E-mail: wbisun@126.com

References

[1] Neville BW, Damm DD, Allen CM and Bouquot J. Abnormalities of teeth. Oral and Maxillofacial Pathology. 3rd edition. Philadelphia: Saunders 1993; pp. 54-119.

[2] Yusof WZ. Non-syndromal multiple supernumerary teeth: Literature review. J Can Dent Assoc 1990; 56: 147-149.

[3] Rajab LD and Hamdan MA. Supernumerary teeth: Review of the literature and a survey of 152 cases. Int J Pediatr Dent 2002; 12: 244-254.

[4] Brook AH. Dental anomalies of number, form and size: Their prevalence in British school children. J Int Assoc Dent Child 1974; 5: 37-53.

[5] Rudagi K, Rudagi BM, Metgud S and Wagle R. Endodontic Management of Mandibular Second Molar Fused to a Supernumerary Tooth, Using Spiral Computed Tomography as a Diagnostic Aid: A Case Report. Case Rep Dent 2012; 2012: 614129.

[6] Duncan WK, Helpin ML. Bilateral fusion and gemination. A literature analysis and case report. Oral Surg Oral Med Oral Pathol 1987; 64: 82-87.

[7] Hernandez-Guisado JM, Torres-Lagares D, Infante-Cossio P and Gutierrez-Perez JL. Dental gemination: report of case. Med Oral 2002; 7: 231-236.

[8] Fan MW. Conservative Dentistry. Beijing: People's Medical Publishing House 2000; pp. 132.

[9] Shafer WG, Hine MK and Levy BM. A textbook of pathology. 4th edition. Philadelphia: WB Saunders Company; 1983.

[10] Tsesis I, Steinbock N, Rosenberg E and Kaufman AY. Endodontic treatment of developmental anomalies in posterior teeth: treatment of geminated/fused teeth-report of two cases. Int Endod J 2003; 36: 372-379.

[11] Gupta S, Singla S, Marwah N, Dutta S and Goel M. Synodontia between permanent maxillary lateral incisor and a supernumerary tooth: treatment prespective. J Oral Health Comm Dent 2007; 1: 52-55.

[12] Mader CI. Fusion of teeth. J Am Dent Assoc 1979; 98: 62-66.

[13] Sivolella S, Bressan E, Mirabal V, Stellini E, Berengo M. Extraoral endodontic treatment, odontotomy and intentional replantation of a double maxillary lateral permanent incisor: case report and 6-year follow-up. Int Endod J 2008; 41: 538-546.

[14] Maréchaux SC. The treatment of fusion of a maxillary central incisor and a supernumerary: report of a case. ASDC J Dent Child 1984; 51: 196-199.

[15] De Siqueira VC, Braga TL, Martins MA, Raitz R and Martins MD. Dental fusion and dens evaginatus in the permanent dentition: literature review and clinical case report with conservative treatment. J Dent Child (Chic) 2004; 71: 69-72.

[16] Karacay S, Guven G and Koymen R. Management of a fused central incisor in association with a macrodont lateral incisor: a case report. Pediatr Dent 2006; 28: 336-340.

[17] Cetinbas T, Halil S, Akcam MO, Sari S and Cetiner S. Hemisection of a fused tooth. Oral Surg Oral Med Oral Pathol Oral Radiol Endod 2007; 104: e120-124.

[18] Nunes E, deMoraes IG, de Novaes PM and de Sousa SM. Bilateral fusion of mandibular second molars with supernumerary teeth: case report. Brazilian Dent J 2002; 13: 137-141.

[19] Tachibana H and Matsumoto K. Applicability of X-ray computerized tomography in endodontics. Endod Dent Traumatol 1990; 6: 16-20.

[20] Matherne RP, Angelopoulos C, Kulild JC and Tira D. Use of cone-beam computed tomography to identify root canal systems in vitro. J Endod 2008; 34: 87-89.

[21] Song CK, Chang HS and Min KS. Endodontic management of supernumerary tooth fused with maxillary first molar by using cone-beam computed tomography. J Endod 2010; 36: 1901-1904.

[22] Hulsmann M, Bahr R and Grohmann U. Hemisection and vital treatment of a fused tooth-literature review and case report. Endod Dent Tranmatol 1997; 13: 253-258.

[23] Simratvir M, Prabhakar M. Clinical management of a unique case of fusion between supernumerary canine and maxillary first premolar. J Calif Dent Assoc 2011; 39: 885-889.

[24] Hülsmann M, Bahr R and Grohmann U. Hemisection and vital treatment of a fused tooth-literature review and case report. Endod Dent Traumatol 1997; 13: 253-258.

[25] Cetinbas T, Halil S, Akcam MO, Sari S and Cetiner S. Hemisection of a fused tooth. Oral Surg Oral Med Oral Pathol Oral Radiol Endod 2007; 104: e120-124.
[26] Gadimli C and Sari Z. Interdisciplinary treatment of a fused lower premolar with supernumerary tooth. Eur J Dent 2011; 5: 349-353.
[27] Ozden B, Gunduz K, Ozer S, Oz A and Ozden FO. The multidisciplinary management of a fused maxillary central incisor with a talon cusp. Aust Dent J 2012; 57: 98-102.