

Case Report

Restricted diffusion in the splenium of the corpus callosum in organophosphate induced delayed neuropathy: case report and review of literatures

Jie Wang¹, Yankun Shao¹, Kai Shi¹, Hong Yang¹, Miao Li²

¹Department of Neurology, The China-Japan Union Hospital of Jilin University, Changchun 130033, China; ²Department of Neurosurgery, The China-Japan Union Hospital of Jilin University, Changchun 130033, China

Received June 17, 2015; Accepted August 5, 2015; Epub August 15, 2015; Published August 30, 2015

Abstract: We described a 35 year-old female who developed organophosphate induced delayed neuropathy (OPIDN) with an unusual clinical manifestation and neuroradiological presentation. Case report: A 35-year-old woman came into contact with organophosphate pesticide by remissly inhalation. She got transient unconsciousness lasting for nearly 2 hours and developed transient hematuria and hyperhidrotic subsequently. She received atropine as treatment and got a satisfying recovery and was hospital discharged without any symptoms. But 20 days later the patient displayed symptoms including headache, vertigo, mental and memory decline, and was hospitalized again. Clinical manifestations, laboratorial findings, images data will be presented. The brain magnetic resonance imaging (MRI) showed an unusual neuroradiological presentation characterized by restricted diffusion in the splenium of the corpus callosum. The patient recovered satisfactorily after administration of corticosteroids and immunogloblin. Conclusion: OPIDN may develop in some susceptible individuals even by inhalation and sometimes with central nervous system involvement. Treatment with corticosteroids and intravenous immunogloblins was found to achieve good results.

Keywords: Organophosphate induced delayed neuropathy (OPIDN), organophosphate poisoning, degeneration of the corpus callosal splenium

Introduction

Organophosphate poisoning is one of a major cause of health problems in young adults in developing countries. After acute cholinergic crisis and intermediate stage, organophosphate induced delayed neuropathy (OPIDN) may develop in a part of patients [1]. Most of them develop peripheral neuropathy and sometimes with central nervous system involvement [2]. Here we report a patient who showed all three phases of organophosphorus poisoning including acute cholinergic effects, intermediate stage and OPIDP with an unusual clinical manifestation and neuroradiological presentation. The brain MRI showed restricted diffusion in the splenium of the corpus callosum and white matters lesions beside the ventricle. However, similar symptoms and imaging findings are not found in the literatures.

Case report

A 35-year-old female with symptoms including headache, vertigo, mental and memory decline

was admitted to our hospital in March 2015. She had a history of contact with organophosphate pesticide by remissly inhalation 20 days before. At the time she got transient unconsciousness lasting for nearly 2 hours and developed hyperhidrotic and hematuria subsequently. The patient showed miotic pupils and received atropine as treatment and got a satisfying recovery within 48 hours. Then she was hospital discharged without any uncomfortable. But 20 days after the first discharge the patient displayed symptoms including headache, vertigo, mental and memory decline, and was hospitalized to our hospital for further evaluation and therapy.

Physical examination: She had normal temperature and normal blood pressure and pulse, with normal size pupils. The general condition was fairly good. There was no skin rash and no lymphadenectasis. She was conscious, dysphoria, slight oriented obstacle, with an obviously memory decline. The patient was lags in response and forgetful. The ability of memory

was obviously decline as she could not repeat simple name or numbers after a short period of space. She could not do logic exercises such as completing the Clock Test correctly. The mini-mental state examination (MMSE) score is 22. The Montreal Cognitive Assessment (MoCA) score is 20. She had grade five muscle power in upper and lower limbs, without pyramidal tract and sensory symptoms.

Laboratory findings: Peripheral blood examinations: RBC $3.4 \times 10^{12}/L$, WBC $10.8 \times 10^9/L$, neutrophilic granulocyte 83.5%, lymphocyte 13.6%, hemoglobin (HG) 110.0 g/L. Blood glucose, renal and liver function was normal. Blood culture was negative. The intracranial pressure (ICP) was 95 mmH₂O (1 mmH₂O =0.98 kPa). Cerebrospinal fluid (CSF) examinations: Protein 0.32 g/L, WBC 0, Glucose 3.5 mmol/L, chloridum 122 mmol/L. The erythrocyte sedimentation rate was 20 mm/h. Antistreptolysin O, rheumatoid factor (RF), antinuclear antibody and anti-double-stranded DNA antibody was negative. Immunoglobulin IgG, IgA, IgM, C3, C4 were normal. The serum activity of acetylcholinesterase is normal. Serologies for human immunodeficiency virus, tubercle bacillus, rubella and Epstein-Barr virus were negative. AQP4 antibody, myelin basal protein (MBP) and oligoclonal bands detection was negative in serum and CSF.

Images: The brain magnetic resonance imaging (MRI) obtained 21 days after organophosphate poisoning showed restricted diffusion in the splenium of the corpus callosum and white matters lesions beside the ventricle (**Figure 1**).

Figure 1. Axial brain MRI images of DWI, ADC, FLAIR, T1, and T2 sequences obtained 21 days after organophosphate poisoning. A. DWI sequences showing an area of restricted diffusion in the splenium of the corpus callosum and bilateral white matters around the ventricle. B. ADC sequence, showing a corresponding dark signal area in the splenium of the corpus callosum and bilateral white matters around the ventricle. C. FLAIR sequences with bright signal intensity in the splenium of the corpus callosum with no white matters lesions. D. T1 sequences with decreased signal intensity in the splenium of the corpus callosum. E. T2 sequences with increased signal intensity in the splenium of the corpus callosum.

According to the history, clinical features and MRI we diagnosed OPIDN, while the corpus cal-

losal splenium and bilateral white matter lesions were more likely organophosphate poisoning induced central nervous system degeneration or demyelinating lesions. The patient had no history of demyelinating diseases such as multiple sclerosis, neuromyelitis optic or optic neuritis. The serum and cerebral spinal fluid detection including AQP4 antibody and the absence of oligoclonal bands didn't support primary central nervous system demyelinating diseases. After administration of methylprednisolone (500 mg/day) and immunoglobulin (0.4 g/kg) for five days, the patient recovered from headache and vertigo and felt fairly good, without dysphoria. The cognitive ability was improved as MMSE score is 28 and MoCA score is 27. She refused to take brain MRI scan again for economical reasons and was discharged at the 9th day in hospital. As 1 month following-up the woman recovered satisfactorily. She was able to go back to her job as while as complete her whole daily works.

Discussion

OPIDP may develop in a part of patients who had intake organophosphate poison. Most of them develop peripheral neuropathy and sometimes with central nervous system involvement [2]. Here we report a patient who showed all three phases of organophosphorus poisoning including acute cholinergic effects, intermediate stage and OPIDP with an unusual clinical manifestation and neuroradiological presentation. The brain MRI showed restricted diffusion in the splenium of the corpus callosum and white matters lesions beside the ventricle.

According to the radiological data, it was needed to exclude some possible diseases such as ischemia and multiple sclerosis. The brain MRI showed hyperintensity on diffusion weighted images (DWI) and hypointensity on apparent diffusion coefficient (ADC) maps (**Figure 1A, 1B**) which was suggestive of new lesions most likely ischemia. Several features argued against such possibilities as the lesions etiology in these facilities: 1) the patient had no history of vascular disease or autoimmune disease, serum and CSF examinations did not found any evidence supporting such diseases; 2) there was no "dated" plaques in white matters under cortical layer on T1, T2, and FLAIR sequences which indicated that lesions emerged after the contacting with organophosphate poison; 3)

Organophosphate induced delayed neuropathy

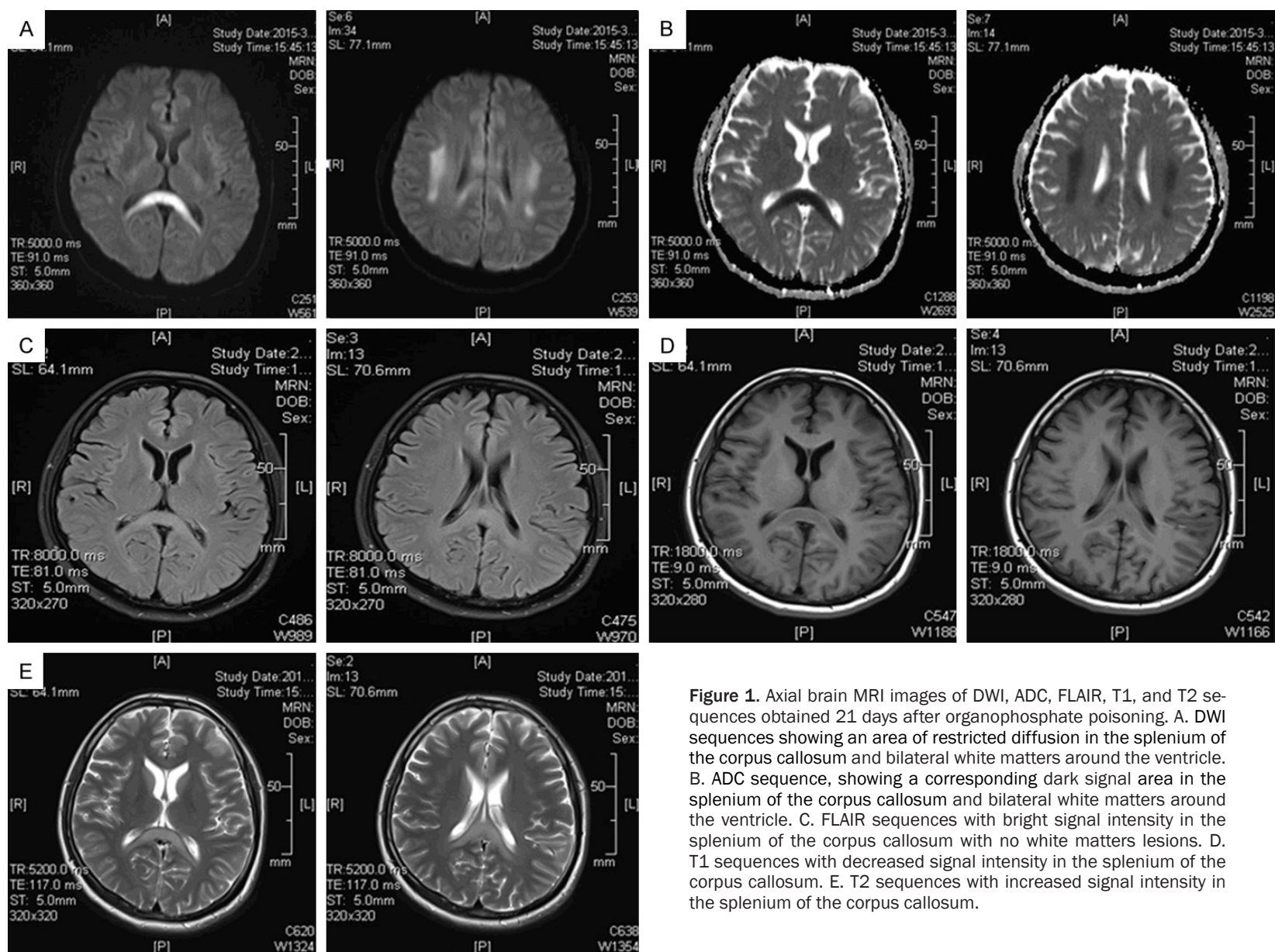


Figure 1. Axial brain MRI images of DWI, ADC, FLAIR, T1, and T2 sequences obtained 21 days after organophosphate poisoning. A. DWI sequences showing an area of restricted diffusion in the splenium of the corpus callosum and bilateral white matters around the ventricle. B. ADC sequence, showing a corresponding dark signal area in the splenium of the corpus callosum and bilateral white matters around the ventricle. C. FLAIR sequences with bright signal intensity in the splenium of the corpus callosum with no white matters lesions. D. T1 sequences with decreased signal intensity in the splenium of the corpus callosum. E. T2 sequences with increased signal intensity in the splenium of the corpus callosum.

bilateral lesions do not reflect a single vascular territories.

Although pathological data was not available in this case, we hypothesized that the splenium findings reflected early Wallerian degeneration from diffuse cortical neurons death. Early sub-acute changes reflecting Wallerian degeneration had been reported following brain ischemic, cardiac arrest, infection and poisoning [3-5]. Although organophosphate poisoning usually induced delayed Wallerian degeneration in the peripheral nervous system it can happen in the central nervous system in some patients. It was still unclear that why the splenium of the corpus callosum was susceptible. We hypothesized that the radiological signs of restricted diffusion may be most detectable where degenerating processes from these diffuse cortical neurons were most concentrated, in the splenium of the corpus callosum. The patient recovered satisfactorily after administration of corticosteroids and immunoglobulin which reflect it was more likely reversible early stage demyelinating lesions. Sharma B [6] reported a mild encephalitis with reversible lesion in the splenium is a clinicoradiological syndrome presenting as a solitary lesion in the central portion of the splenium of the corpus callosum with a radiological finding of restricted diffusion and low ADC values. Which was usually associated with normal CSF findings and an excellent prognosis even without corticosteroid therapy.

The mechanism of central neurological involvement in OPIDP is not very clear. The delayed neuronal destruction, which arises primarily in the cholinergic areas of the brain that contain dense accumulations of cholinergic neurons and the majority of cholinergic projection, could be largely responsible for persistent profound neuropsychiatric and neurological impairments such as memory, cognitive, mental, emotional, motor, and sensory deficits in the victims of organophosphate poisoning [7]. It is generally accepted that irreversible inhibition of AChE is the primary mechanism during the acute toxicity of organophosphate pesticides. However, the fact that the prevalence of the various signs of acute toxicity varies among different organophosphate compounds in humans and in animal models strongly suggests that direct interactions of these compounds with other molecular targets contribute to their acute toxicity [8]. Additional mechanisms that have been

proposed to contribute to the delayed toxicity of organophosphate compounds include exacerbated oxidative stress, imbalanced intracellular Ca²⁺ homeostasis, increased signaling mediated by inflammatory mediators, such as interleukins and cytokines, changes in cellular signaling mediated by neurotrophin receptors and protein kinases, and mitochondrial disruption [9].

OPIDN may develop in some susceptible individuals even by inhalation and sometimes with central nervous system involvement. The patient may displayed symptoms including headache, vertigo, mental and memory decline, with an unusual neuroradiological presentation characterized by restricted diffusion in the splenium of the corpus callosum. We hypothesized that the splenium findings reflected early Wallerian degeneration from diffuse cortical neurons death. Treatment with corticosteroids and intravenous immunoglobulins was found to achieve good results. To improve the hypothesis more observation and report will be needed.

Disclosure of conflict of interest

None.

Address correspondence to: Miao Li, Department of Neurosurgery, The China-Japan Union Hospital of Jilin University, Changchun 130033, China. E-mail: limiao@jlu.edu.cn

References

- [1] Shetye JV, Surkar SM, Karnik ND, Mehta AA. Delayed onset neuropathy along with recurrent laryngeal nerve palsy due to organophosphate poisoning and the role of physiotherapy rehabilitation. *Indian J Crit Care Med* 2014; 18: 102-4.
- [2] Banks CN, Lein PJ. A review of experimental evidence linking neurotoxic organophosphorus compounds and inflammation. *Neurotoxicology* 2012; 33: 575-84.
- [3] Shrot S, Tauber M, Shiyovich A, Milk N, Rosman Y, Eisenkraft A, Kadar T, Kassirer M, Cohen Y. Early brain magnetic resonance imaging can predict short and long-term outcomes after organophosphate poisoning in a rat model. *Neurotoxicology* 2015; 48: 206-16.
- [4] Bianchi MT, Sims JR. Restricted diffusion in the splenium of the corpus callosum after cardiac arrest. *Open Neuroimag J* 2008; 2: 1-4.
- [5] Oquist M, Farooq MU, Gorelick PB. Restricted diffusion of the splenium of the corpus callo-

Organophosphate induced delayed neuropathy

- sum in viral meningitis. *Neurohospitalist* 2014; 4: 109-10.
- [6] Sharma B, Handa R, Nagpal K, Prakash S, Panagariya A. Transient elevation of cerebrospinal fluid protein in a patient of mild encephalitis with reversible lesion in the splenium: a case report. *Malays J Med Sci* 2014; 21: 94-7.
- [7] Kaur S, Singh S, Chahal KS, Prakash A. Potential pharmacological strategies for the improved treatment of organophosphate induced neurotoxicity. *Can J Physiol Pharmacol* 2014, 92: 893-911.
- [8] Collombet JM. Nerve agent intoxication: recent neuropathophysiological findings and subsequent impact on medical management prospects. *Toxicol Appl Pharmacol* 2011; 255: 229-41.
- [9] Androutsopoulos VP, Hernandez AF, Liesivuori J, Tsatsakis AM. A mechanistic overview of health associated effects of low levels of organochlorine and organophosphorous pesticides. *Toxicology* 2013; 307: 89-94.