

## Original Article

# Expression of human papillomavirus and prognosis of juvenile laryngeal papilloma

Juan Li<sup>1</sup>, Tian-Yu Zhang<sup>2</sup>, Le-Tian Tan<sup>2</sup>, Shu-Yi Wang<sup>2</sup>, Yu-Ying Chen<sup>3</sup>, Jie-Yan Tian<sup>2</sup>, Wen-Ying Da<sup>2</sup>, Ping He<sup>1</sup>, Ya-Ming Zhao<sup>1</sup>

<sup>1</sup>Department of Otolaryngology, Tongren Hospital Affiliated to Shanghai Jiaotong University School of Medicine, Shanghai 200336, China; <sup>2</sup>Department of Otolaryngology, Eye Ear Nose & Throat Hospital of Fudan University, Shanghai 200031, China; <sup>3</sup>Institute of Biochemistry and Cell Biology of Medical College of Shanghai Jiaotong University, Shanghai 200025, China

Received March 27, 2015; Accepted August 3, 2015; Epub September 15, 2015; Published September 30, 2015

**Abstract:** The aim of this study was to evaluate the correlation between clinical behavior and expression of human papillomavirus (HPV) in patients with juvenile laryngeal papillomatosis, in an attempt to develop an effective molecular biological method to predict prognosis. We included 37 patients with juvenile laryngeal papillomatosis in the study group and 10 cases each of juvenile vocal cord polyps and juvenile normal laryngeal mucosa as the control group. We detected HPV by immunocytochemistry and in situ hybridization, identified the virus type, and measured HPV-DNA content using a computer-assisted, color pathological image-analysis system. Additionally, we conducted a retrospective study with regard to the patients' clinical history to evaluate the prognosis. The data of the 2 groups were compared and statistically analyzed, including a correlation with prognosis. In the study group, 67.3% (25/37) were positive for HPV-Ag by immunocytochemistry; whereas 53.2%, 45.8%, and 25.4% were positive for HPV6b-DNA, HPV11-DNA, and HPV6b+11-DNA, respectively, by in situ hybridization. HPV was not detected in the control group. There was a significant difference between two groups ( $P < 0.05$ ). Compared to HPV11-DNA-positive cases, those that were positive for HPV6b-DNA and HPV6b+11-DNA showed lower results on average, for age at first diagnosis and self-relief, number of surgeries, and interval between surgeries. Our findings suggest that immunocytochemistry and in situ hybridization are useful methods to evaluate the prognosis of juvenile laryngeal papilloma (JLP) and that HPV6b-positivity can be used as an index to predict the development and outcome of JLP.

**Keywords:** Laryngeal neoplasm, papillomavirus, human papilloma, DNA probes, human papillomavirus

## Introduction

Human papillomavirus (HPV) infection is causally associated with benign and malignant diseases of the upper airway, including respiratory papillomatosis and oropharyngeal cancer [1]. Low-risk HPV types 6 and 11 are the predominant causative agents of papillomatosis. HPV types 6 and 11 definitively satisfy both-molecular and epidemiological causal criteria-as carcinogenic or low-risk types in the upper airway. Recurrent respiratory papillomatosis (RRP) is the most common benign neoplasm affecting the larynx and upper respiratory tract in children. HPV has been implicated as the cause of RRP, most commonly types 6 and 11. The present study was undertaken to evaluate the occurrence of HPV types in a group of patients

with juvenile-onset RRP (JORRP) [2]. Juvenile laryngeal papilloma (JLP) is a disease of benign epithelial neoplasia of the upper airway in children and is characterized by recurrence, tendency of invasion, and self-relief [3]. Although HPV type 11 is most frequently associated with malignant change in RRP, HPV type 6 may also contribute equally in RRP carcinogenesis [4]. Pulmonary papillomatosis is an extremely rare variant of RRP, which is hard to treat, causes prolonged morbidity, and may transform into a malignant disorder in several cases [5]. It is a major cause of hoarseness and dyspnea in children and a difficult problem to deal with for otolaryngology doctors [6]. Ullman proposed the viral etiology of papilloma for the first time in 1923 and HPV was identified by electron microscopy in 1949. Rapid development of

molecular biology and molecular epidemiology has helped improve the understanding of the relationship of HPV6 and 11 with JLP. Although HPV type 11 is most frequently associated with malignant change in RRP, HPV type 6 may also contribute equally to RRP carcinogenesis. In this study, we conducted a retrospective analysis of 37 JLP cases and analyzed the correlation between JLP prognosis and HPV expression in order to develop an effective molecular biological method to predict JLP prognosis. In addition, recent advances in immunology have helped improve treatment modalities and prevention strategies. A new vaccine to prevent HPV infection in women is currently under trial where the strongest risk factor for juvenile RRP is a maternal history of genital warts (transmitted from mother to child during delivery). Better understanding of the etiology and knowledge of all available therapies are crucial for optimum management of patients with RRP [7-9].

### Methods

#### *Subjects*

The study group consisted of 37 patients who had histopathologically confirmed JLP and were treated at the Department of Otolaryngology, Eye and ENT Hospital, Shanghai, China, between June 2001 and May 2006. The control group consisted of 10 patients with juvenile vocal cord polyps and 10 children with normal laryngeal mucosa. This study was conducted in accordance with the declaration of Helsinki. This study was conducted with approval from the Ethics Committee of the Fifth Hospital of Fudan University. Written informed consent was obtained from all participants.

#### *Reagents*

The use of immunohistochemical Envision method an anti HPV antibody (Rabbit anti bovine BPV-1, polyclonal) and two anti Envision kit were purchased from America DAKO companies, the concentration of 1:100, blocking agent 0.3% PBS+0.2% Triton provided by Huamei Biological Engineering Company Ltd., China. In situ hybridization (ISH) of digoxin (Digitalin, Dig) was performed using oligonucleotide probe sequence primers. The sequences of the primers, synthesized by Sangon Biological Engineering Technology and Services Co., Shanghai, China, were as follows: HPV6b: 5'TCT

TAC TGT TTG GTA TAC AAT AAC ATA AAA3', HPV11: 5'CCT TAG TAT ATT ATG CAC AAT ACC CAC AAA3'. The digoxigenin detection kit (Anti-Digoxigenin-AP) was supplied by Boehringer Mannheim GmbH, Germany.

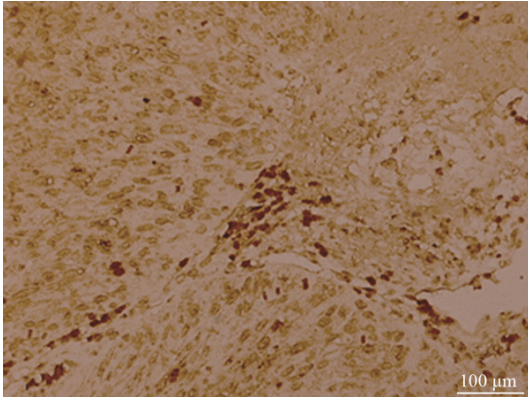
#### *Immunocytochemistry (ICC)*

Tissue samples were fixed in 4% paraformaldehyde for 24 hours, dehydrated sequentially in 20% and 30% glucose solutions for 24 hours respectively, embedded in paraffin (OCT), cut into 4- $\mu$ m sections and stained with hematoxylin-eosin (H&E). JLP was diagnosed on the basis of the presence of koilocytes, characterized by a basophilous nucleus with a perinuclear clearing.

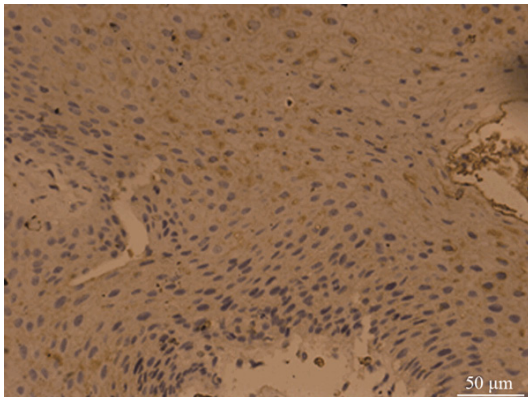
Sections were deparaffinized in xylene and sequentially rehydrated in ethanol, placed in sodium citrate solution (heated to 100°C), and then rinsed thoroughly in distilled water. Sections were then first treated with 3% H<sub>2</sub>O<sub>2</sub> for 30 min at 37°C in the dark to quench endogenous peroxidase and then rinsed. After incubation with bovine serum albumin (BSA) containing 0.3% PBS and 0.2% Triton for 20 min, quenched sections were incubated with 100  $\mu$ l primary antibody (BPV-1, DAKO) overnight. After rinsing to remove the primary antibody, sections were incubated for 30 min with Dako EnVisionCe peroxidase-conjugated, anti-rabbit or anti-mouse IgG-labeled dextran for 30 min. The stained sections were developed by incubation with freshly prepared diaminobenzidine (DAB) substrate for 10 min. They were then counterstained with hematoxylin and Richard Allen bluing reagent, dehydrated in a graded series of ethanol and xylene, and a covered with a glass slip. Slides were viewed under a light microscope. HPV-Ag expression in tissue was detected by CMIAS, based solely on the number of the ICC-stained cells (koilocytes) per 100 cells in one visual field under a light microscope (200X). The intensity was graded as: < 30%, weak positive (+); 30%-70%, positive (++); and > 70%, high positive (+++). To eliminate false-positive results, we used PBS as the primary antibody in a control set, where all slides were negative.

#### *In situ hybridization (ISH)*

Sections were incubated overnight at 60°C using pretreated slides and deparaffinized as



**Figure 1.** By ICC, HPV-Ag positive slides contained Koilocyte with brown or buffy particles in the nucleus. Koilocyte were mainly scattered in the surface and media layers of squamous epithelium (Envision method  $\times 100$ ).



**Figure 2.** JLP lesion showed papillary hyperplasia and formation of dull or sharp papilla (Envision method  $\times 200$ ).

described above. Sections were incubated with pepsin for 5-10 min at 37°C and then rinsed in PBS and 2  $\times$  SSC/DECP. Hybridization was carried out in a moist chamber where sections were incubated overnight with a mixture of HPV6b or HPV11 probe on Parafilm at 42°C. Post-hybridization, 4 washes were performed on a shaker in 2  $\times$  SSC for 30 min, 1  $\times$  SSC, 0.2  $\times$  SSC, and 0.1 M PBS (pH 7.4) at 37°C for 15 min each. Each section was consecutively incubated with 20  $\mu$ l 0.3% PBS+0.2% Triton at 37°C for 30 min, followed by 20  $\mu$ l anti-digoxigenin-AP at 37°C for 60 min. The sections were then rinsed 4 times with 0.5 M TBS (pH 7.6) for 5 min, incubated with SABC-AP for 30 min at 37°C, and then rinsed once with 0.1 M TBS (pH 9.0). The sections were then overlaid with 5-bromo-4-chloro-3-indoxyl phosphate (BCIP)

dye in the presence of nitro blue tetrazolium chloride (NBT) and incubated in the dark at 37°C for 30 min. The sections were then rinsed and counter-stained with nuclear fast red. Finally, the sections were mounted in a permanent mounting medium.

Slides were then viewed under a light microscope and those with amethyst particles in their nucleus were regarded positive for HPV-DNA. The positive slides were analyzed by IPP image analysis software to detect transmittance of the nuclei (A value), and the mean A value was considered as relative content of HPV. The lower the A value, the higher was the HPN-DNA content.

## Statistical analysis

For comparison of study and control groups, ANOVA, *t* test and correlation/regression analysis were conducted. A *P* value of  $< 0.05$  was considered significant.

## Results

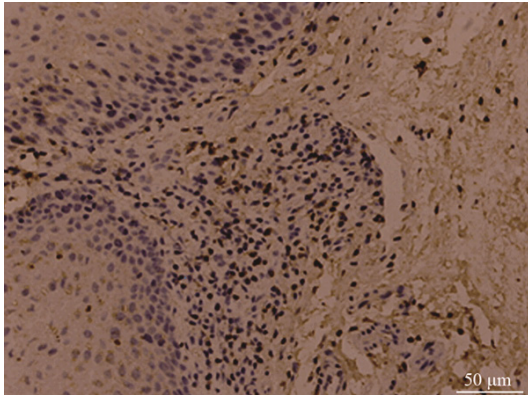
### Review of patient history

Among the 37 patients with JLP in the study group, 21 were male and 16 were female (the ratio of male versus female = 1.31:1). The age at first onset ranged from 2 months to 6.5 years (mean 2.4 years). The average number for surgeries performed was 4.5:1 time, 4 patient; 2 to 5 times, 19 patients; 6 to 10 times, 11 patients; and  $> 10$  times, 3 patients; 1 patient underwent 17 surgeries. The interval between 2 surgeries ranged from 24 days to 2.5 years (mean 11 months). Of all cases, lesions infringing the laryngeal aspect of the epiglottis, unilateral or bilateral vocal folds, false vocal folds and aryepiglottic folds, and subglottic tissue. Two patients underwent tracheotomy. Of the 37 patients in the study group, 32 were followed up for 0.4 to 5 years and 5 were lost to follow up. Patients with more than 3 recurrences after surgery or a lesion infringing the subglottic tissue were segregated into the invasive group (29 cases), and the rest were segregated into non-invasive group (8 cases), as per JLP classification by Doyle.

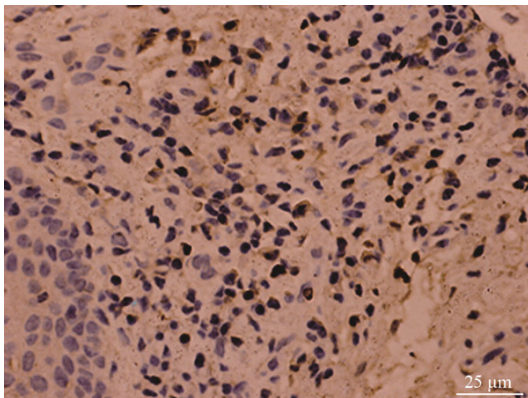
### ICC

HPV-Ag-positive sections were characterized by koilocytes with brown or buffy particles in the





**Figure 3.** By ISH, HPV-DNA positive cells, which scattered mainly from the superficial spinous layer to the surface layer (ISH  $\times 200$ ).



**Figure 4.** HPV6b/11-DNA positive cells were in the papillae with scattered, focal or platelike distribution (ISH  $\times 400$ ).

nucleus on ICC. Koilocytes were mainly scattered on the surface and medial layers of squamous epithelium (**Figure 1**) and seldom in the base cell layer. JLP lesions showed papillary hyperplasia and formation of dull or sharp papilla (**Figure 2**) under high-power light microscopy. Out of 37 patients in the study group, 25 (67.3%) were positive for HPV-Ag: 9 were weakly positive (+), 15 were positive (+), and 1 was highly positive (+++). Among the 25 positive patients, 14 were male, and 11 were female (the ratio of male versus female = 1.27:1); the average age at first onset was 2.1 years. Of the 12 negative patients, 7 were male and 5 were female (the ratio of male versus female = 1.4:1); the average age at first onset was 4.8 years. In the invasive group, 6 out of 29 patients (20.7%) showed mild-to-moderate squamous cell dysplasia. In the non-invasive group, dys-

**Table 1.** The number of HPV-DNA positive case and average content of HPV-DNA ( $\bar{x} \pm s$ )

Sample	Case	Positive cases (rate)	A value
HPV6b	20/37	53.2%	85.32 $\pm$ 4.75
HPV11	17/37	45.8%	96.17 $\pm$ 3.52
HPV6b+11	9/37	25.4%	90.61 $\pm$ 5.46

The two results were significantly positive correlated ( $r = 0.64$ ,  $P < 0.01$ ).

plasia was not present. There was a significant difference between the 2 groups ( $P < 0.05$ ). The control group was negative for HPV-Ag.

#### ISH

ISH revealed that HPV-DNA positive cells were scattered mainly from the superficial spinous layer to the surface layer (**Figure 3**) and contained hyacinthine particles in the nucleus. **Figure 4** shows HPV6b/11-DNA positive cells in the papillae with scattered, focal or platelike distribution. All patients were HPV-DNA-positive and all showed the same HPV type, irrespective of the time point, that is, before or after surgery or during relapse. Of the 37 patients in the study group, 20 (53.2%) were HPV6b-DNA-positive, 17 (45.8%) were HPV11-DNA-positive, and 9 were (25.4%) HPV6b+11-DNA-positive. Of HPV-DNA-positive cases, the ratio of male versus female was 1.15:1 and their age ranged from 2 to 4 years. The average age for negative cases was slightly higher. Of the 20 cases that were HPV6b-DNA-positive, 16 were of relapsed papilloma, while merely 5 were of HPV11-DNA-positive recurrence. The control group was negative for HPV-DNA ( $P < 0.05$ ). **Table 1** shows the number of HPV-DNA-positive cases and average content of HPV-DNA.

#### Discussion

JLP is one of the most common, benign laryngeal lesions and its prevalence in China is on the rise. Due to the recurrent and invasive nature of the infection, JLP causes severe hindrance to laryngeal development and damages the child's mental and physical health. During the last decade, it has been shown that infection with low-risk-type HPV (type 6 and 11) was the primary cause of JLP [10]. HPV6 and 11 infect the epithelium, enter base cells via micro wounds, and then infect squamous cells of the larynx and the peripheral tissue. After replicat-

ing in the nucleus, HPV virions can persist in the free state outside the chromosome and cause benign lesions [11]. HPV virions exist not only in the papilloma tissue but also in the peripheral normal epithelium. ICC studies have revealed the presence of a specific antigen in papilloma tissues [12]. ICC can indicate HPV infection, whose correlation with HPV-Ag positivity is 50% to 87% [13]. In this study, specimens positive for HPV-Ag were 67.3%, most of which were positive or weakly positive. Our data revealed that HPV-Ag expression has little to do with gender ( $r = 0.32$ ,  $P > 0.05$ ), but is more related with the age at first onset, lesion range, and recurrent frequency ( $r = 0.59$ ,  $P < 0.05$ ). These results suggest that, the lesser the age at first onset, the higher the HPV-Ag-positivity. With increase in recurrence, this level of positivity decreases. We suppose that, with an increase in age and recurrence, higher quantities of HPV antibodies are produced, which makes immunity indices such as IgG, IgA,  $CD_3^+$ , and  $CD_4^+$  levels gradually increase, and HPV infection is curtailed, leading to self-restricted regression. We observed 6 patients who presented with mild-to-moderate squamous cell dysplasia in the invasive group, while there were no such cases in the non-invasive group. This is mainly due to HPV infection and repeated surgical stimuli. None of the 37 patients in the study group developed malignant transformation. It seems that, combined with the examination of relative serum antibody titer, dynamic detection of HPV-Ag can be used as a prognostic index to predict the development and prognosis of JLP; thus, a similar prediction mechanism can be investigated further [14].

HPV is a non-enveloped virus with 7800- to 7900-bp long double-stranded DNA. HPV virions are icosahedral in shape, with a diameter of 55 nm [15]. The HPV genome contains 2 main regions-the early region (E region) and late region (L region)-and one URR. There are 6 open reading frames (ORFs): E1, E2, E3, E4, E5, E6, and E7 in the E region and 2 late ORFs (L1, L2) in the L region. The E region is responsible for regulating the replication of extrachromosomal DNA, while the L region encodes viral proteins. URR does not encode proteins but regulates transcription and controls the production of infectious viral particles. Rinaldo et al. [16] suggested that vigorous metabolism of epithelial cells in children is a possible patho-

genic mechanism of JLP. After entering the laryngeal mucosa, HPV duplicates rapidly by cell division and it may exist in the free state or integrate into cellular DNA, which can impact cell differentiation and cause disorders of the epithelial maturation process, finally causing JLP. In our study, ISH results showed that all HPV-DNA particles were within the nucleus, which resulted from integration of HPV-DNA and cell DNA. Among the 37 patients with JLP, positivity rate for HPV6b-DNA, HPV11 DNA, and HPV6b+11 DNA was 53.2%, 45.8%, and 25.4% respectively, while the control group was negative for HPV-DNA ( $P < 0.05$ ). This indicates that ISH is more sensitive than ICC to detect HPV expression and can reflect the location of HPV infection, so that ISH can be used in further investigations combined with morphological examinations [17]. Previous studies have pointed out that although tissues adjacent to JLP show normal morphology [18], they are in fact affected by HPV; in other words, tissues infected by HPV are much larger in size than the papillomatosis itself. Another finding is that the HPV type remains the same in recurrent papillomas. These facts suggest that latent HPV infection is the source of relapse [19]. All cases in our study were positive for HPV-DNA and all tissues showed the same HPV type, irrespective of the time point, that is, before or after the surgery or during relapse. In this study, the HPV-DNA-positive rate by ISH was not significant correlated to the patient's gender ( $r = 0.46$ ,  $P > 0.05$ ). Most of the positive patients were 2 to 4 years old and the age of negative patients was relatively higher, which suggests that HPV expression and the age at first onset are significantly correlated ( $r = 0.63$ ,  $P < 0.05$ ). This result concurs with that from ICC analysis. The morphometry method is based on tissue structure and has advantages such as accuracy and repeatability. The HPV-DNA positivity rate is related to DNA content in the tissue. We utilized the image analysis system to determine HPV-DNA content in all 37 patients in the study group. The result showed that samples with HPV6b-DNA-positivity showed the highest HPV-DNA content and HPV-DNA positive rate, whereas those with HPV11-DNA-positivity showed lowest values for both. Out of the 20 HPV6b-DNA-positive patients, 16 relapsed, whereas out of the 17 HPV11-DNA-positive patients, 5 relapsed, which indicates that cases with HPV6b-DNA-positivity have a higher chance of relapse.

Previous reports have suggested that HPV L1 can self-assemble into viral particles that promote neutralization antibody production in vivo, in order to prevent repeated infection [20]. The vaccine expressing HPV L1 protein is one of the most promising prophylactic vaccines at present. We believe that classifying patients with JLP by molecular methods is well-founded and needs to be further investigated. Additionally, vaccines based on genetic engineering can be used to prevent, diagnose, and treat JLP.

## Disclosure of conflict of interest

None.

**Address correspondence to:** Juan Li, Department of Otolaryngology, Tongren Hospital Affiliated to Shanghai Jiaotong University School of Medicine, No. 1111 Xianxia Road Changning District, Shanghai 200336, China. Tel: +86 21 62909911; E-mail: juanlicn@126.com

## References

- [1] Gillison ML, Alemany L, Snijders PJ, Chaturvedi A, Steinberg BM, Schwartz S and Castellsagué X. Human papillomavirus and diseases of the upper airway: head and neck cancer and respiratory papillomatosis. *Vaccine* 2012; 30: F34-54.
- [2] Rosenthal DW, DeVoti JA, Steinberg BM, Abramson AL and Bonagura VR. T(H)2-like chemokine patterns correlate with disease severity in patients with recurrent respiratory papillomatosis. *Mol Med* 2012; 18: 1338-1345.
- [3] Zainura A, Yalkun Y and Wu M. The different expression of human papilloma viral types 6 and 11 in Uyghur and Chinese juvenile recurrent respiratory papillomatosis in a large pediatric population in Xinjiang. *Lin Chung Er Bi Yan Hou Tou Jing Wai Ke Za Zhi* 2013; 27: 1205-1207.
- [4] Jeong WJ, Park SW, Shin M, Park SW, Shin M, Lee YJ, Jeon YK, Jung YH, Hah JH, Kwon TK, Song YS, Kim KH and Sung MW. Presence of HPV type 6 in dysplasia and carcinoma arising from recurrent respiratory papillomatosis. *Head Neck* 2009; 31: 1095-1101.
- [5] Martina D, Kurniawan A and Pitoyo CW. Pulmonary papillomatosis: a rare case of recurrent respiratory papillomatosis presenting with multiple nodular and cavitory lesions. *Acta Med Indones* 2014; 46: 238-243.
- [6] Draganov P, Todorov S, Todorov I, Karchev T and Kalvatchev Z. Identification of HPV DNA in patients with juvenile-onset recurrent respiratory papillomatosis using SYBR Green real-time PCR. *Head Neck* 2006; 70: 469-473.
- [7] Doyle DJ, Henderson LA, LeJeune FE Jr and Miller RH. Changes in human papillomavirus typing of recurrent respiratory papillomatosis progressing to malignant neoplasia. *Arch Otolaryngol Head Neck Surg* 1994; 120: 1273-1276.
- [8] Rodríguez H, Cuestas G and Sasson L. Eosinophilic esophagitis associated with laryngeal papillomatosis in a child. *Acta Otorrinolaringol Esp* 2014; 65: 383-384.
- [9] Stamatakis S, Nikolopoulos TP, Korres S, Felekis D, Tzangaroulakis A and Ferekidis E. Juvenile recurrent respiratory papillomatosis: still a mystery disease with difficult management. *Head Neck* 2007; 29: 155-162.
- [10] Fischer M. Investigation of a broad-spectrum PCR assay for human papillomaviruses in screening benign lesions of the upper aerodigestive tract. *ORL J Otorhinolaryngol Relat Spec* 2005; 67: 237-241.
- [11] Olszewski J, Latusiński J, Kita A, Pietkiewicz P, Starostecka B and Majak J. Comparative assessment of aluminum and lead concentrations in serum and tissue biopsies in patients with laryngeal papilloma or cancer. *B-ENT* 2006; 2: 47-49.
- [12] Huebbers CU, Preuss SF, Kolligs J, Vent J, Stenner M, Wieland U, Silling S, Drebber U, Speel EJ and Klusmann JP. Integration of HPV6 and downregulation of AKR1C3 expression mark malignant transformation in a patient with juvenile-onset laryngeal papillomatosis. *PLoS One* 2013; 8: e57207.
- [13] Ray BR, Sen IM and Prabhu V. Double lumen central venous catheter for pediatric airway management in laryngeal papillomatosis: caution is warranted. *Paediatr Anaesth* 2014; 24: 1020-1021.
- [14] Ilmarinen T, Nissilä H, Rihkanen H, Roine RP, Pietarinen-Runtti P, Pitkäranta A and Aaltonen LM. Clinical features, health-related quality of life, and adult voice in juvenile-onset recurrent respiratory papillomatosis. *Laryngoscope* 2011; 121: 846-851.
- [15] Bo L, Wang B and Shu SY. Anesthesia management in pediatric patients with laryngeal papillomatosis undergoing suspension laryngoscopic surgery and a review of the literature. *Int J Pediatr Otorhinolaryngol* 2011; 75: 1442-1445.
- [16] Rinaldo A, Ferlito A and Healy GB. Cancer of the larynx in children and adolescents: a neoplastic lesion with a different etiology. *Acta Otolaryngol* 2004; 124: 992-994.
- [17] Avelino MA, Zaiden TC and Gomes RO. Surgical treatment and adjuvant therapies of recurrent respiratory papillomatosis. *Braz J Otorhinolaryngol* 2013; 79: 636-642.
- [18] Shetty N, Prabhaskar K, Joshi A, Sayed SI, Sharma S, Noronha V, Deshmukh A, Chaukar

## Human papillomavirus in juvenile laryngeal papilloma

- D, Kane S, Gopal and D'cruz AK. Case of childhood laryngeal papillomatosis with metastatic carcinoma esophagus in adulthood. Indian J Med Paediatr Oncol 2013; 34: 34-37.
- [19] Vergeichik GI and Sitnikov BP. Papillomavirus infection of the upper respiratory tract and anogenital region in children. Transmission routes and possibilities for prevention. Vestn Otorinolaringol 2010; 74-78.
- [20] Harris AT, Atkinson H, Vaughan C and Knight LC. Presentation of laryngeal papilloma in childhood: the Leeds experience. Int J Clin Pract 2012; 66: 183-184.