

## Case Report

# Postoperative recurrence solitary fibrous tumor of the pelvic with malignant transformation

Chao Gao<sup>1,2\*</sup>, Yong Zhang<sup>2\*</sup>, Yu-Ying Li<sup>4</sup>, Yong-Hua Yu<sup>2</sup>, Wei Qu<sup>2</sup>, Yong-Sheng Gao<sup>3</sup>, Shuo Zhang<sup>1,2</sup>

<sup>1</sup>School of Medical and Life Sciences, Shandong Academy of Medical Sciences, Jinan University, Jinan, Shandong, China; <sup>2</sup>Radiation Oncology Ward 2, Shandong Cancer Hospital and Institute, Jinan, Shandong, China; <sup>3</sup>Department of Pathology, Shandong Cancer Hospital and Institute, Jinan, Shandong, China; <sup>4</sup>Oncology Ward 2, Zibo City The Fourth People's Hospital, Zibo, China. \*Equal contributors.

Received June 4, 2015; Accepted July 22, 2015; Epub September 15, 2015; Published September 30, 2015

**Abstract:** A 48-year-old man with a solitary fibrous tumor of the pelvic underwent resection, but recurrent tumor was found 4 years later. Recurrent solitary fibrous tumor of the pelvic with malignant progression is rare. Solitary fibrous tumor of the pelvic often has an indolent clinical course, so postoperative surveillance may necessitate long-term follow-up because of the potential adverse biological behavior of this tumor, which may lead to repeated recurrences and/or malignant transformation.

**Keywords:** Solitary fibrous tumor, neoplasm recurrence, malignant transformation, pelvic

## Introduction

Solitary fibrous tumor (SFT) usually originates from pleura, and accounts for about 2% of all soft tissue neoplasms, which only 30% SFTs originate from outside the chest organs. The SFT of pelvic is very rare [1, 2]. Previous study reported that 5 of 79 SFTs arose in the pelvis, excluding those of prostate and spermatic cord origin [3]. Most of the SFTs are benign tumors, malignant tumors only account for 12%-22% [4]. To our knowledge, reports (Table 1) of malignant transformation after recurrence of the SFT are much rarer [5-11]. Herein, we present a case with postoperative malignancy transformation after recurrent involving pelvic SFT which initially diagnosed as benign SFT and successful treatment. Hoping to be useful in the diagnosis and treatment of this disease.

## Case presentation

In April 2009, a 48-year-old Asian male was admitted to our hospital for finding a mass on the abdominal wall within the right groin. The mass was soft, active, painless and about 6.5 × 3.5 cm. Computed tomography (CT) showed irregular soft tissue density shadow in the pel-

vic cavity, 7.5 × 3.5 cm in maximum cross section. The lesions border was clear, and no obvious swelling lymph nodes in double side basin wall and inguinal region (Figure 1A). He received laparoscopic pelvic tumor resection. The tumor was removed completely and the postoperative course was uneventful. Pathologically, the tumor contained predominantly oval or spindle cells organized in a haphazard growth pattern (a so-called "patternless pattern") with a few mitoses observed in 10 high-power fields (Figure 2A and 2B). The Immunohistochemistry analysis showed positivity for CD34 (Figure 2C), Ki-67, Vimentin, and negativity for Desmin, NF, S-100, SMA, as well as CD117. We considered the tumor as solitary fibrous tumor with cystic degeneration. Since then, the patient rejected to receive further diagnosis and treatment.

In September, 2013, he accidentally hit a mass again in the right lower quadrant. The mass was hard, inactive, painless and about 8.0 × 5.3 cm. Pelvic CT showed pelvic mixed density showing multiple soft tissue mass, the largest 9.3 × 6.5 cm, with a solid saccate, leaf (Figure 1B). Therewith, he received pelvic tumor resection. In the process of the operation, there were severe adhesion among the tumor and the

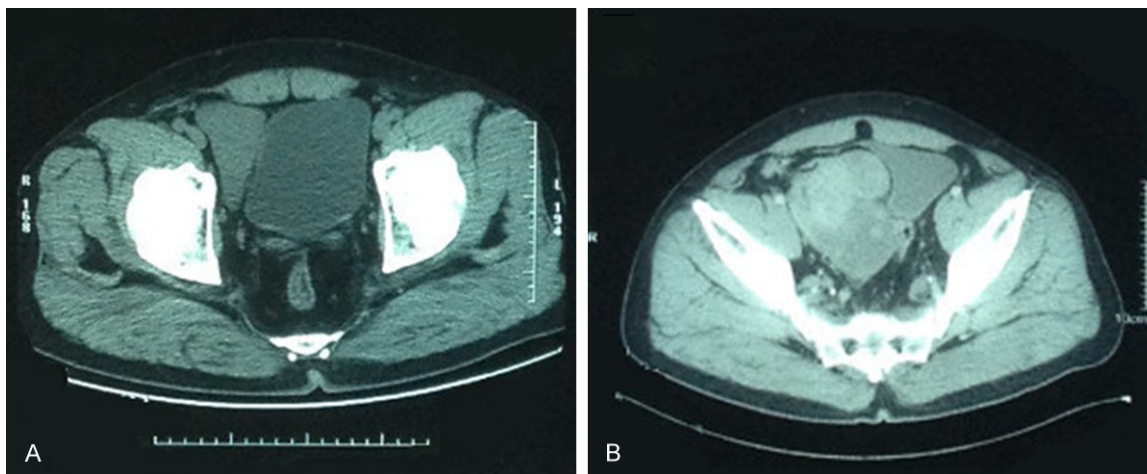
## Recurrence solitary fibrous tumor with malignant transformation

**Table 1.** Summary of malignant transformation of solitary fibrous tumors

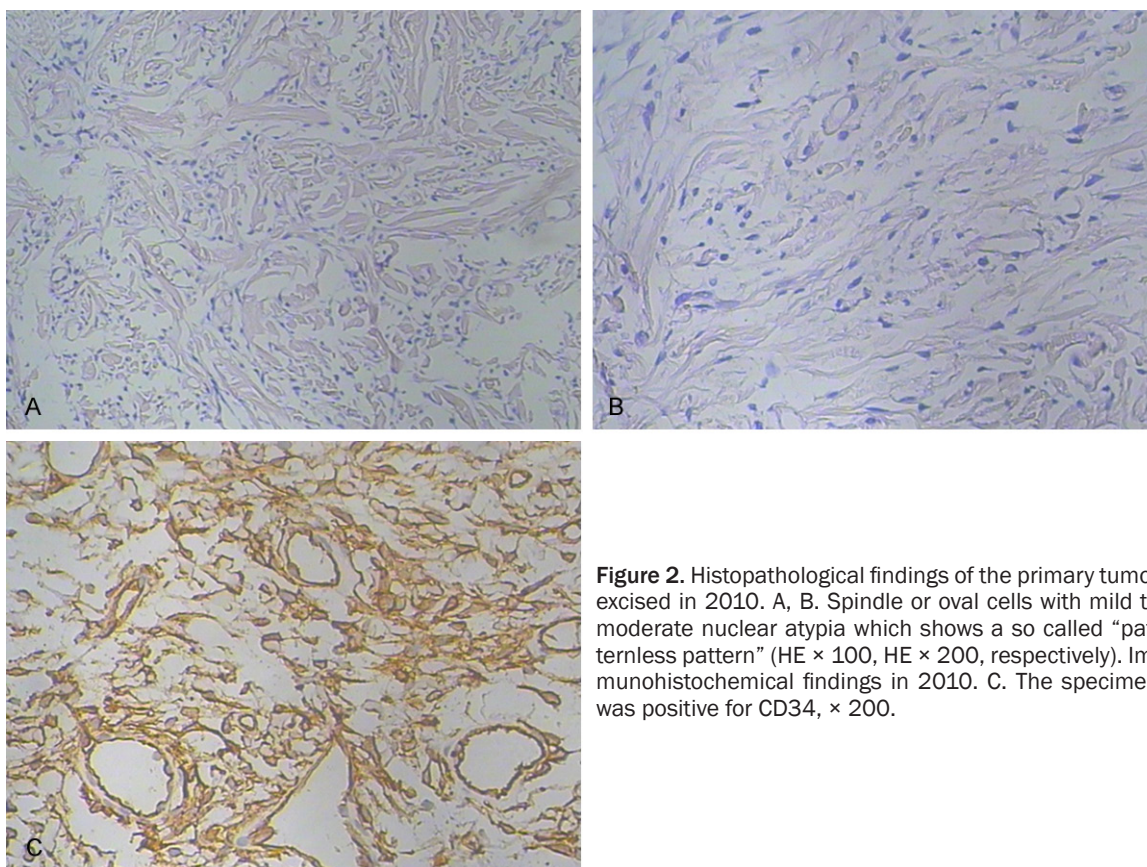
Case	Age/Sex	Site	Size (mm)	Symptom-s	Necrosis	Mitoses/10 HPF	CD34	Bcl-2	Margin	Treatment	Follow-up
Yokoi et al [5] 1998	54/M	Intrapelvic	150	Yes	Yes	2.7	+	No date	-	No date	NED 7 months
Yokoi et al [5] 1998	65/F	Pleura	130	No date	Yes	3.5	+	No date	+	No date	NED 2 Years
Krishnadas et al [6] 2005	76/F	Pleura	100	Yes	Yes	4	+	+	-	Chemo/radiot-herapy	No date
Gabriel et al [7] 2007	70/M	Liver	280	Yes	Yes	> 20	+	+	-	Resection	Recurrent at 9 months
Tominaga et al [8] 2012	41/M	Pleura	60	Yes	Yes	10	-	+	-	Resection	Recurrent at 8 Years
Wang et al [9] 2013	38/M	Orbital	5	Yes	No date	No date	+	+	No date	Resection	NED 18 months
Law et al [10] 2014	55/M	Pleura	170	No	No date	No date	+	+	-	Resection	No date
Kanthan et al [11] 2004	85/F	Pleura	No date	No	No date	10	-	No date	-	Resection	Recurrent at 9 Years
Present case	48/M	Pelvic	93	No	Yes	No date	+	-	-	Resection/Chemo/radiot-herapy	NED 19 months

HPF, high-power-field; NED, no evidence of disease.

## Recurrence solitary fibrous tumor with malignant transformation



**Figure 1.** CT findings of the tumor in 2010. A. CT showed a class triangle soft tissue density shadow in the pelvic cavity, maximum cross section was about  $7.5 \times 4.5$  cm. Lesions border was clear, its signal was well-distributed. Double side basin wall and inguinal region did not see obvious swelling lymph nodes. CT findings of the tumor at the second recurrence in 2014. B. CT showed a irregular soft tissue mass shadow in the pelvic cavity. Lesions border was not clear. Local and right side of the bladder wall had not clear boundaries. Lesions were significantly heterogeneous enhancement after enhancement CT, which saw patchy and nodular low density shadow. Basin wall on both sides saw multiple swollen lymph nodes.

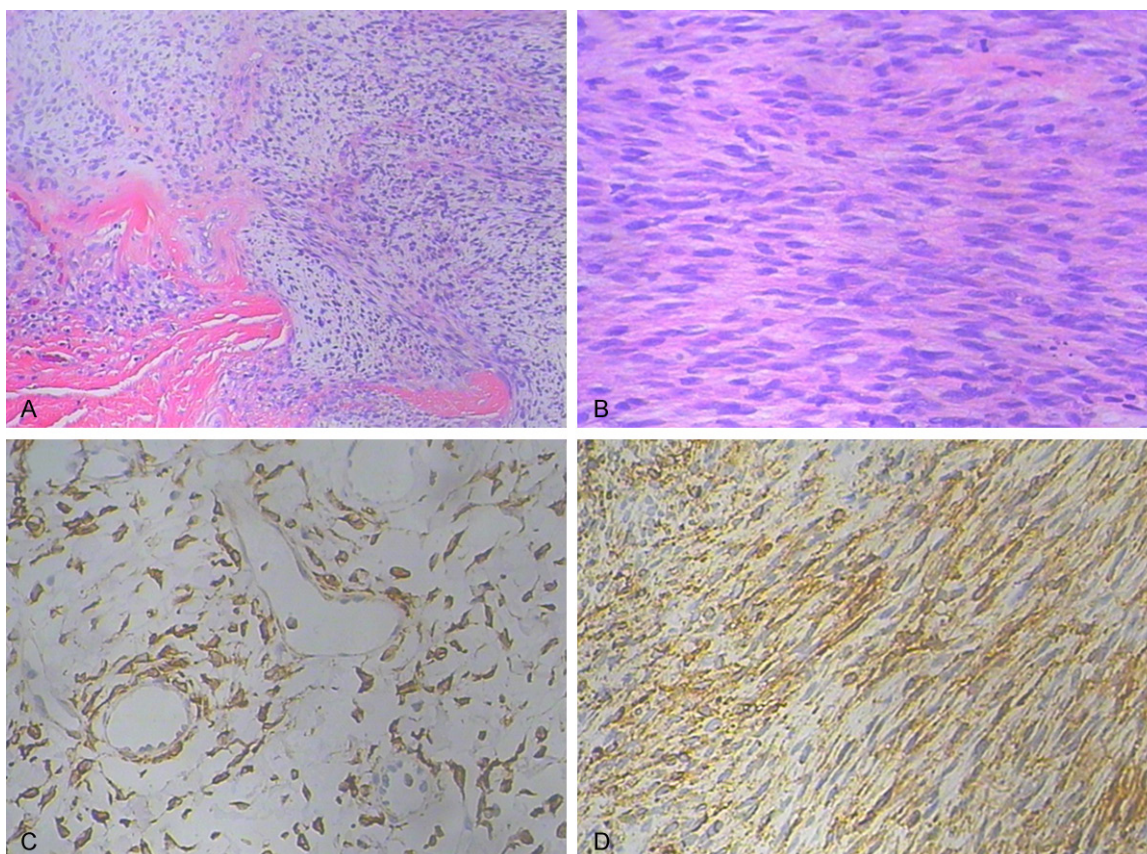


**Figure 2.** Histopathological findings of the primary tumor excised in 2010. A, B. Spindle or oval cells with mild to moderate nuclear atypia which shows a so called “patternless pattern” (HE  $\times 100$ , HE  $\times 200$ , respectively). Immunohistochemical findings in 2010. C. The specimen was positive for CD34,  $\times 200$ .

lower abdomen abdominal, the surrounding tissue and the right iliac artery. The size was  $13 \times$

10 cm. The patient underwent complete tumor resection, combined with resection of portions





**Figure 3.** Histopathological findings of the tumor at the second Recurrence in 2014. A, B. Histologic evidence to support malignant transformation in solitary fibrous tumor of pelvic includes high cellularity with pleomorphism and increased mitotic (HE  $\times$  100, HE  $\times$  200, respectively). Immunohistochemical findings in 2014. C. The specimen was positive for CD34,  $\times$  200. D. The specimen was positive for Bcl-2,  $\times$  200.

of the bladder. Resection proceeded and the postoperative course was uneventful. Post-operative pathology showed spindle cell tumor with hemorrhage and necrosis, and tumor cells had a certain degree of nuclear atypia, high mitotic activity (Figure 3A and 3B). Immunohistochemically, the specimen was positive for CD34 (Figure 3C), Bcl-2 (Figure 3D), CD99, vimentin, as well as Ki-67, but negative for NF, S-100, SMA, and CD117. Combining with the history to consider as a malignant solitary fibrous tumor.

In view of this study was to postoperative recurrence in patient with malignant transformation, and large size, incomplete capsule, as well as adhesion. The patient received postoperative intensity-modulated radiation therapy. Treatment plan was that CTV surrounded the pelvic tumor bed area and out-diffusion 5 mm for the PTV, 90% of measurement curve surrounded PTV, the right side of the femoral head average

22 Gy, bladder average 35 Gy, 2.0 Gy/fraction, one time/day, five times/week, Dt 60 Gy. Radiation therapy had been completed. In addition to the slight cystitis, no other obvious radiation reaction. The patient also received 4 cycles of chemotherapy, concrete plan was ifosfamide, adriamycin and dacarbazine. Bone marrow inhibition was 2 degrees, and gastrointestinal reaction was 1 degree. The patient was well tolerated. After actively symptomatic treatment, above-mentioned side effects took a turn for the better. The patient was to review a pelvic CT every 3 months after departure from our hospital. No recurrence has been detected 19 months after treatment.

## Discussion

SFT is a rare neoplasm that is thought to originate from submesothelial mesenchymal cells [12], with only approximately 800 cases having been reported to date [13]. SFT often arises in

the pleura, but has also been reported in various extrathoracic organs, including the upper respiratory tract, orbits, soft tissue, abdomen, and breast [14, 15]. Previous study reported that 6% of all SFTs originated from the pelvis [16]. The incidence is rare and is predominant in the sixth and seventh decades of life with no difference in gender distribution. Clinically, extrapleural lesions present with symptoms related to the tumor site. Systemic symptoms such as hypoglycemia, arthralgia, osteoarthritis, and clubbing have also been documented [17, 18]. These symptoms usually resolve upon removal of the tumor. As exhibited in our case, onset age was 48 years old, consisting with the previous report. The patient was referred to our hospital for finding a mass on the abdominal wall within the right groin when participating in an annual health check. And since the onset of the patient with loss of weight was about 7 kg, and without hypoglycemia and other complications. There are no specific symptoms for this disease, and not simply to consider the disease on the basis of symptoms.

The computed tomography (CT) scan of the pelvic is an available examination, which shows the size and location of the tumor more clearly and helps to formulate surgical planning. CT findings, SFTs have been described to demonstrate heterogeneous attenuation, approximately 20-30% of tumors demonstrate calcification on CT [19]. Those of a well-defined mass, showing soft tissue attenuation with areas of necrosis and cystic degeneration (low attenuation areas) are present in large tumors. Two thirds of the tumors enhance with contrast administration, suggesting a more vascular nature to the tumor [20]. In our case, pelvic CT showed irregular soft tissue density shadow in the first lesion, 7.5 × 3.5 cm in maximum cross section. But pelvic CT showed mixed density showing multiple soft tissue mass, the largest 9.3 × 6.5 cm in the recurrent lesion with malignant transformation. There were obvious differences between the two CT performances. Therefore, pelvic CT has clinical significance in distinguish benign and malignant SFT.

For the SFT contains mature fibrous tissue, MRI usually shows a low signal on T1W1 and T2W1, which helps to identify other pelvic tumors. Fibrous tissue of SFT has a low signal intensity on T1-weighted images. On T2-weighted images, however, mature fibrous tissue has a low

intensity, while malignant fibrous tissue tends to demonstrate a high signal intensity [21]. For this, MRI has certain guiding significance to identify benign and malignant SFT.

However, definitive diagnosis of SFT is based on the characteristic of histological and immunohistochemical features. Histologically, SFT is composed of spindly to ovoid cells, possibly of fibroblastic origin, which are arranged in a haphazard “patternless” pattern and intimately intertwined by collagen fibers of various thicknesses, and associated with numerous hemangiopericytoma-like dilated thin-walled blood vessels. Immunohistochemistry, According to the previous reports, tumor cells in SFT are characteristically immunoreactive for vimentin, CD34, BCL-2, CD99, Ki-67, and negative for a-SMA, desmin, pan-cytokeratin, and S-100 protein [22]. Among them, CD34 is one of the best markers for SFT to distinguish between most of the aforementioned differential diagnoses [23]. The immunophenotype in our case is mainly consistent with the previous reports. England [24] considered neoplasms to be malignant if one or more of the following histologic features are present; 1) high cellularity, 2) high mitotic activity (more than 4 mitoses per 10 high-power fields), 3) pleomorphism, 4) necrosis, and 5) hemorrhagic changes. The diagnosis of SFT was made in the present case according to these characteristic immunohistochemical findings and histological features.

The first-line treatment for SFTs is surgical resection. SFTs are usually localized, and complete resection is often curative. On the contrary, no standard therapy has been established for inoperable malignant SFT because of the rarity. Radiation therapy (RT) has been used in SFT cases on an anecdotal basis, postoperative radiotherapy was given due to the high-grade malignancy, narrow excision margins, large size and rapid growing, but there are no published series to substantiate its routine usefulness for this disease [25]. RT alone is considered when surgery is inappropriate or declined by the patient, it achieves rates of local control of 30-60% [26]. In addition, Macfarlane [27] reported that the combination of radiotherapy and toremifene therapy has proved dramatically effective in the case of an unresectable SFT.

The use of chemotherapy is reserved to symptomatic non-resectable SFTs, but there are no

standard chemotherapeutic indications or regimens. Also, patients underwent palliative chemotherapy in the cases of distant metastasis [28]. Even though SFTs are considered relatively chemoresistant, the most effective drugs seem to be anthracyclines and ifosfamide, followed by gemcitabine and dacarbazine, which are commonly used in soft tissue sarcomas [29]. Although the treatment methods of SFTs are varies, but there is no unified standard of treatment, with respect to the treatment of SFTs are also needed more research in the future.

SFT is usually a benign neoplasm, the reported incidence of malignant SFTs varies from 7% to 60%, the pelvis is a rare localization of SFT [30]. Although nearly all SFTs have low malignant potential, malignancy can occur, especially if they grow to a large size or in case of repeated recurrence [1, 24]. There are two forms of malignant transformation; one is malignant or high-grade SFT, and the other is de novo occurrence of malignant SFT [5]. The case we reported may be in accordance with the mechanism of the recurrence of previous tumor. Our investigation revealed the mass to be a malignant solitary fibrous tumor that having transformed from a benign to malignant state. Our patient initially was diagnosed as pelvic benign solitary fibrous tumor in April 2009. After radical surgery, he refused to receive the subsequent auxiliary anti-tumor treatment and did not regularly go to the hospital for reviewing. Currently, he had a relapse, the diagnosis was pelvic malignant SFT. So long-term follow-up is crucial in order to detect recurrent disease because of the unpredictable clinical course.

## Conclusion

Pelvic solitary fibrous tumors are rare and most often benign as described in other localizations. However, malignant transformation is possible and can be correlated with some histological criteria. Current treatment strategies of primary and relapse are clearly insufficient, but care must be maximized. Radiotherapy is a effective treatment for the above patients, but chemotherapy curative effect remains to be proved. Finally, a prolonged follow-up should be advisable for those patients who are at risk of relapsing.

## Acknowledgements

The study is supported by Shandong Province Science and technology development plan NO: 2014GSF118176.

## Disclosure of conflict of interest

None.

**Address correspondence to:** Yong-Hua Yu, Department of Radiation Oncology, Shandong Cancer Hospital and Institute, Jinan, Shandong, China. Tel: 86-0531-67626715; E-mail: sdyonghuayu@163.com

## References

- [1] Gold JS, Antonescu CR, Hajdu C, Ferrone CR, Hussain M, Lewis JJ, Brennan MF and Coit DG. Clinicopathologic correlates of solitary fibrous tumors. *Cancer* 2002; 94: 1057-1068.
- [2] Suster S, Fisher C and Moran CA. Expression of bcl-2 oncoprotein in benign and malignant spindle cell tumors of soft tissue, skin, serosal surfaces, and gastrointestinal tract. *Am J Surg Pathol* 1998; 22: 863-872.
- [3] Goodlad JR and Fletcher CD. Solitary fibrous tumour arising at unusual sites: analysis of a series. *Histopathology* 1991; 19: 515-522.
- [4] Sung SH, Chang JW, Kim J, Lee KS, Han J and Park SI. Solitary fibrous tumors of the pleura: surgical outcome and clinical course. *Ann Thorac Surg* 2005; 79: 303-307.
- [5] Yokoi T, Tsuzuki T, Yatabe Y, Suzuki M, Kurumaya H, Koshikawa T, Kuhara H, Kuroda M, Nakamura N, Nakatani Y and Kakudo K. Solitary fibrous tumour: significance of p53 and CD34 immunoreactivity in its malignant transformation. *Histopathology* 1998; 32: 423-432.
- [6] Krishnadas R, Froeschle PO and Berrisford RG. Recurrence and malignant transformation in solitary fibrous tumour of the pleura. *Thorac Cardiovasc Surg* 2006; 54: 65-67.
- [7] Chan G, Horton PJ, Thyssen S, Lamarche M, Nahal A, Hill DJ, Marliss EB and Metrakos P. Malignant transformation of a solitary fibrous tumor of the liver and intractable hypoglycemia. *J Hepatobiliary Pancreat Surg* 2007; 14: 595-599.
- [8] Tominaga N, Kawarasaki C, Kanemoto K, Yokochi A, Sugino K, Hatanaka K, Uekusa T, Fukuda I, Aiba M, Hizuka N and Uda S. Recurrent solitary fibrous tumor of the pleura with malignant transformation and non-islet cell tumor-induced hypoglycemia due to paraneoplastic overexpression and secretion of



## Recurrence solitary fibrous tumor with malignant transformation

- high-molecular-weight insulin-like growth factor II. *Intern Med* 2012; 51: 3267-3272.
- [9] Wang X, Qian J, Bi Y, Ping B and Zhang R. Malignant transformation of orbital solitary fibrous tumor. *Int Ophthalmol* 2013; 33: 299-303.
  - [10] Law MK, Tung YW and Jinc JS. Malignant transformation in solitary fibrous tumor of the pleura. *Asian Cardiovasc Thorac Ann* 2014; 22: 981-983.
  - [11] Kanthan R and Torkian B. Recurrent solitary fibrous tumor of the pleura with malignant transformation. *Arch Pathol Lab Med* 2004; 128: 460-462.
  - [12] Hu Y, Mahar TJ, Hicks DG, Raymond D, Jones C, Wandtke JC, Powers JM and Xu H. Malignant solitary fibrous tumor: report of 3 cases with unusual features. *Appl Immunohistochem Mol Morphol* 2009; 17: 451-457.
  - [13] de Perrot M, Fischer S, Brundler MA, Sekine Y and Keshavjee S. Solitary fibrous tumors of the pleura. *Ann Thorac Surg* 2002; 74: 285-293.
  - [14] Peng L, Liu Y, Ai Y, Liu Z, He Y and Liu Q. Skull base metastases from a malignant solitary fibrous tumor of the liver. A case report and literature review. *Diagn Pathol* 2011; 6: 127.
  - [15] Shanbhogue AK, Prasad SR, Takahashi N, Vikram R, Zaheer A and Sandrasegaran K. Somatic and visceral solitary fibrous tumors in the abdomen and pelvis: cross-sectional imaging spectrum. *Radiographics* 2011; 31: 393-408.
  - [16] Katsuno H, Maeda K, Hanai T, Sato H, Masumori K, Koide Y, Matsuoka H, Noro T, Takakuwa Y and Hanaoka R. Trans-sacral resection of a solitary fibrous tumor in the pelvis: report of a case. *Surg Today* 2011; 41: 1548-1551.
  - [17] Moran CA, Ishak KG and Goodman ZD. Solitary fibrous tumor of the liver: a clinicopathologic and immunohistochemical study of nine cases. *Ann Diagn Pathol* 1998; 2: 19-24.
  - [18] Hasegawa T, Matsuno Y, Shimoda T, Hasegawa F, Sano T and Hirohashi S. Extrathoracic solitary fibrous tumors: their histological variability and potentially aggressive behavior. *Hum Pathol* 1999; 30: 1464-1473.
  - [19] Robinson LA. Solitary fibrous tumor of the pleura. *Cancer Control* 2006; 13: 264-269.
  - [20] Foroulis CN, Rammos KS, Tsomkopoulos S, Sileli MN, Hatzibougias I and Papakonstantinou C. Fibrous tumor of the lung: diagnostic and therapeutic considerations apropos of two cases. *J BUON* 2008; 13: 117-121.
  - [21] Nagase T, Adachi I, Yamada T, Murakami N, Morita K, Yoshino Y, Katayanagi K and Kurumaya H. Solitary fibrous tumor in the pelvic cavity with hypoglycemia: report of a case. *Surg Today* 2005; 35: 181-184.
  - [22] Magro G, Bisceglia M, Michal M and Eusebi V. Spindle cell lipoma-like tumor, solitary fibrous tumor and myofibroblastoma of the breast: a clinico-pathological analysis of 13 cases in favor of a unifying histogenetic concept. *Virchows Arch* 2002; 440: 249-260.
  - [23] Kawamura S, Nakamura T, Oya T, Ishizawa S, Sakai Y, Tanaka T, Saito S and Fukuoka J. Advanced malignant solitary fibrous tumor in pelvis responding to radiation therapy. *Pathol Int* 2007; 57: 213-218.
  - [24] England DM, Hochholzer L and McCarthy MJ. Localized benign and malignant fibrous tumors of the pleura. A clinicopathologic review of 223 cases. *Am J Surg Pathol* 1989; 13: 640-658.
  - [25] Colletta AA, Wakefield LM, Howell FV, van Roozendaal KE, Danielpour D, Ebbs SR, Sporn MB and Baum M. Anti-oestrogens induce the secretion of active transforming growth factor beta from human fetal fibroblasts. *Br J Cancer* 1990; 62: 405-409.
  - [26] Tepper JE and Suit HD. Radiation therapy alone for sarcoma of soft tissue. *Cancer* 1985; 56: 475-479.
  - [27] Macfarlane RG, Galloway M, Plowman PN and Thomas DG. A highly vascular intracranial solitary fibrous tumor treated with radiotherapy and toremifene: case report. *Neurosurgery* 2005; 56: E1378; discussion E1378.
  - [28] Wignall OJ, Moskovic EC, Thway K and Thomas JM. Solitary fibrous tumors of the soft tissues: review of the imaging and clinical features with histopathologic correlation. *AJR Am J Roentgenol* 2010; 195: W55-62.
  - [29] Grobmyer SR, Maki RG, Demetri GD, Mazumdar M, Riedel E, Brennan MF and Singer S. Neoadjuvant chemotherapy for primary high-grade extremity soft tissue sarcoma. *Ann Oncol* 2004; 15: 1667-1672.
  - [30] Bugel H, Gobet F, Baron M, Pfister C, Sibert L and Grise P. [Solitary fibrous tumour of the kidney and other sites in the urogenital tract: morphological and immunohistochemical characteristics]. *Prog Urol* 2003; 13: 1397-1401.