

Case Report

Unestimated disease: epiploic appendagitis

Fatih Çiftçi

Vocational School of Health Services, Istanbul Gelisim University, Avcılar, Istanbul, Turkey

Received July 5, 2015; Accepted December 4, 2015; Epub January 15, 2016; Published January 30, 2016

Abstract: Epiploic appendagitis (EA) is an unusual cause of focal abdominal pain in otherwise healthy patients with mild or absent secondary signs of abdominal disorders. It is most frequently confused with acute appendicitis and diverticulitis. EA is very infrequently diagnosed, in part due to a low or absent awareness of this condition among general surgeons. We aim to draw attention to EA by presenting 13 cases of this relatively rare disorder with differential diagnoses of acute abdominal disease. A diagnosis of EA should be considered in patients with sharp, localised, acute abdominal pain unassociated with any other symptoms (such as vomiting, nausea, or fever) or unusual laboratory test results. Although infrequently diagnosed to date, EA may become more frequently detected in the future with the increasing use of abdominal computed tomography (CT) and ultrasound. Surgeons should be aware of this self-limiting disease because it mimics many other acute intra-abdominal diseases. When non-invasive techniques fail to diagnose EA, diagnostic laparoscopy or even laparotomy should be employed to rule out other acute abdominal disorders.

Keywords: Acute abdomen, appendagitis, laparoscopy

Introduction

Epiploic appendagitis (EA) presents a dilemma in establishing differential diagnoses and suitable treatment because of its non-specific signs and symptoms. The epiploic appendices are peritoneum-covered, pedunculated, fat-filled pouches that are attached to the wall of the colon. These appendices are more frequently encountered on the transverse and sigmoid colon. Approximately 50 to 100 epiploic appendices are found throughout the colon, but they are not present in the rectum. Because of their inadequate arterial perfusion and pedunculated and mobile nature, torsion and infarction can result. Epiploic appendices reportedly assist in the peristalsis of the colon and provide mechanic protection in a manner similar to that of the major omentum [1]. They are a part of the intraperitoneal defence system as well as the major omentum. Diseases involving the epiploic appendices may be primary or secondary. Primary EA (PEA) is an acute event resulting from torsion that leads to inflammation of the epiploic appendices and their surrounding tissues. When inflammation of the epiploic appendices occurs due to infec-

tion in other organs, the event is referred to as secondary EA (SEA). Depending on its location in the colon, PEA may mimic other surgical disorders such as appendicitis, diverticulitis, and cholecystitis. Secondary disorders are frequent. For example, the epiploic appendices may adhere to any region of intra-abdominal inflammation, limiting the spread of EA. Primary disorders may be symptomatic or asymptomatic. Symptomatic primary disorders of the epiploic appendices are very rare. The most frequent of these disorders is acute EA secondary to torsion, necrosis, and acute inflammation of the epiploic appendices [1-3]. We aim to draw attention to this rare disorder by presenting 13 cases of EA with differential diagnoses of acute abdominal disorders.

Patients and methods

Thirteen patients (10 male and 3 female) aged 20 to 80 years old (average, 41 years old) who presented with EA to the emergency department of Safa Hospital from November 2007 to October 2014 were included in this study. EA was diagnosed in patients presenting with abdominal pain. SPSS 16.0 for Windows (SPSS

Appendagitis

Table 1. Clinical and demographic findings of 13 patients with epiploic appendagitis

Variable	Medical treatment (n=11)	Laparoscopic surgery (n=2)
Age in years (range)	43.3±10.0 (20-80)	33.5 (20-80)
Sex, male/female	10/1	1/1
Fever of >37.5 °C	3 (23%)	2 (15%)
White blood cell count, ×10 ⁹ /L (range)	10±3 (5-15)	9±3 (5-17)
C-reactive protein level, mg/dL (range)	79±21 (55-151)	59±23 (42-110)

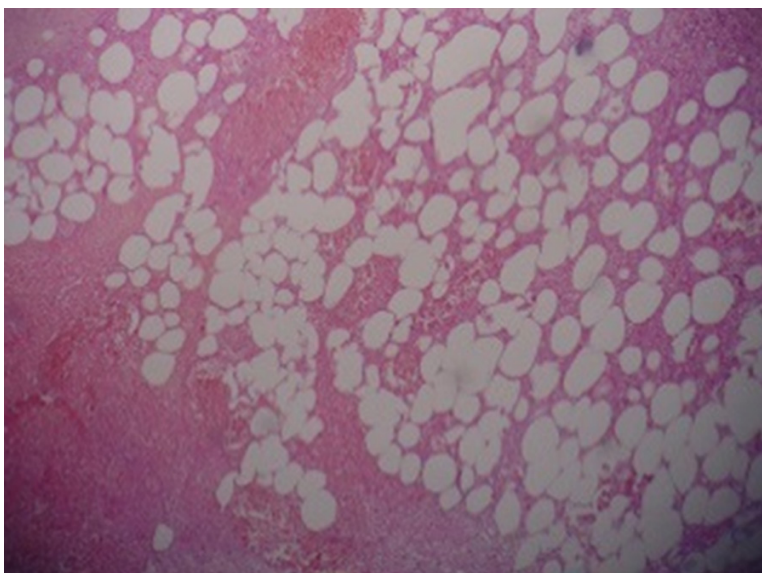


Figure 1. Photomicrograph of surgical specimen shows haemorrhage (H), fibrin (F), and fat necrosis (haematoxylin and eosin, ×10).

Table 2. Primary disorders of the epiploic appendices

1	Acute appendagitis (73%)
2	Incarceration in a hernia sac (18%)
3	Intestinal obstruction (18%)
4	Colonic invagination (>1%)
5	Diverticulum originating from an epiploic appendix (>1%)
6	Malignancy of an epiploic appendix (>1%)

Inc., Chicago, IL, USA) was used to analyse all data. In the definitive statistics, continuous variables are presented as mean ± standard deviation and categorical variables are presented as percentage and number of cases.

Results

Physical examination revealed well-localised tenderness in all patients (n=13); rebound tenderness and distension were also observed.

Blood test results were normal excluding three patients with leucocytosis. Five patients were fever of >37.5°C. Abdominal ultrasonography revealed oedema and possible necrosis on the colon wall in the pelvic region on two patients. Eleven patients were diagnosed with EA by abdominal computed tomography (CT). Two patients required laparoscopic surgical intervention, whereas the remaining patients did not. Clinical and demographic findings show 13 patients with epiploic appendagitis in (Table 1). Simple laparoscopic excision was performed on two patients. The patients were discharged from the hospital on the first postoperative day with an antibiotic prescription. A pathological view of the torsed epiploic appendix is shown in Figure 1.

Discussion

Epiploic appendices are prone to torsion due to their pedunculated nature, which allows for their mobility. They are also prone to infarction upon torsion because of the impaired perfusion they receive from the branches of the colic artery [4, 5]. PEA is a rare inflammatory disorder that may present with an abrupt onset of abdominal pain localised in a particular region. The disorder may be caused by torsion or spontaneous appendiceal venous thrombosis [3, 5]. The appendices of the sigmoid colon and caecum are more frequently involved, possibly because of their large size and elongated nature [1, 5, 9]. In this study, torsion affected the appendices of the sigmoid region.

PEA can occur in patients of almost all age groups. However, those in their second to fifth

Appendagitis

decades of life are more susceptible. Our patients aged 20 to 80 years (average, 41 years), respectively. The patients presented to the hospital with localised, abrupt-onset abdominal pain. Physical examination of patients with EA may reveal fever, and the laboratory results may include leucocytosis. For example, one of our patients was found to have frank leucocytosis and other tendencies toward leucocytosis. The actual incidence of PEA is unknown. Recently, however, increasing numbers of reports describing the diagnosis of PEA have been published due to the increasingly more widespread use of radiological imaging techniques for the diagnosis of patients presenting with acute abdominal manifestations [6, 7, 9, 10]. Epiploic appendiceal disorders exhibit various presentations (**Table 2**).

No consensus on the optimal treatment approach to PEA has yet been established. Some studies have advocated a conservative approach that includes oral antibiotics and anti-inflammatory drugs for patients with localised disease [11-14]. However, other authors advocate immediate surgery, and still others describe PEA as a disease that requires no surgical intervention at all. The approach to treatment may vary according to the patient's signs and symptoms [1, 10].

Misdiagnoses lead to unnecessary surgical interventions, medical treatments, and hospitalisations. For this reason, an early and correct diagnosis is of utmost importance. Appropriate diagnosis requires keeping PEA in mind while formulating a list of differential diagnoses. In the diagnostic work-up of a patient presenting with an acute abdominal disorder, CT and ultrasonography should be employed to identify typical PEA findings. Obtaining the correct diagnosis within a short time allowed for shorter hospitalisation duration and a decreased risk of morbidity and loss of manpower. Other acute abdominal disorders were ruled out. If imaging techniques remain inadequate for such a diagnosis, minimally invasive laparoscopic exploration, which allows for both diagnosis and treatment, should be performed. When these approaches remain insufficient, laparotomy is imminent [15, 16].

Conclusion

Correct early diagnosis of PEA is of great importance and allows PEA to be differentiated from

other acute abdominal disorders that may require more aggressive medical and surgical treatments. Incorrect diagnoses are thus reduced, leading to a reduction in unnecessary hospitalisations and medical/surgical treatments. A diagnosis of PEA in patients presenting with lower abdominal pain should always be considered along with other abdominal disorders. In cases that arouse suspicion for PEA, radiological techniques including CT should be employed. When non-invasive techniques provide unclear results, diagnostic laparoscopy or even laparotomy should be considered to rule out other acute abdominal disorders. Surgeons should be aware of this self-limiting disease, which mimics many other intra-abdominal acute diseases. Finally, we believe that there is a need for larger-scope studies to ascertain the diagnostic and treatment approaches for this disorder.

Acknowledgements

The authors express their gratitude to all of the participating patients and clinical staff.

Disclosure of conflict of interest

None.

Address correspondence to: Dr. Fatih Ciftci, Vocational School of Health Services, Istanbul Gelisim University, Avcilar, Basaksehir Mah, Erciyes Sok, No. 15, Daire 24, Basaksehir, Istanbul 34306, Istanbul, Turkey. Tel: 90 505 616 4248; Fax: 90 212 462 7056; E-mail: oprdrfatihciftci@gmail.com

References

- [1] Molla E, Ripolles T, Martinez MJ, Morote V, Rosello-Sastre E. Primary epiploic appendagitis: US and CT findings. *Eur Radiol* 1998; 8: 435-8.
- [2] Barbier C, Denny P, Pradoura JM, Bui P, Rieger A, Bazin C, Tortuyaux JM, Régent D. Radiologic aspects of infarction of the appendix epiploica. *J Radiol* 1998; 79: 1479-85.
- [3] Rioux M, Langis P. Primary epiploic appendagitis: clinical, US, and CT findings in 14 cases. *Radiology* 1994; 191: 5236.
- [4] Horton KM, Corl FM, Fishman EK. CT evaluation of the colon: inflammatory disease. *Radiographics* 2000; 20: 399-418.
- [5] Barbier C, Denny P, Pradoura JM, Bui P, Rieger A, Bazin C, Tortuyaux JM, Régent D. Radiologic aspects of infarction of the appendix epiploica. *J Radiol* 1998; 79: 1479-85.

Appendagitis

- [6] Ammar H, Looney SC, Malani A. Epiploic appendagitis. *Lancet* 2009; 373: 2054.
- [7] Vázquez-Frias JA, Castañeda P, Valencia S, Cueto J. Laparoscopic diagnosis and treatment of an acute epiploic appendagitis with torsion and necrosis causing an acute abdomen. *JSLs* 2000; 4: 247-50.
- [8] van Breda Vriesman AC, de Mol van Otterloo AJ, Puylaert JB. Epiploic appendagitis and omental infarction. *Eur J Surg* 2001; 167: 723-7.
- [9] Sand M, Gelos M, Bechara F, Sand D, Wiese TH, Steinstraesser L. Epiploic appendagitis: clinical characteristics of an uncommon surgical diagnosis. *BMC Surg* 2007; 1: 7-11.
- [10] Blinder E, Ledbetter S, Rybicki F. Primary epiploic appendagitis. *Emerg Radiol* 2002; 9: 231-3.
- [11] Leclercq P, Dorthu L. Epiploic appendagitis. *CMAJ* 2010; 182: 939.
- [12] Zenger MN, Zenger S, Pekuysal M, Sözen S. Primary epiploic appendagitis: a case report. *Ulus Travma Acil Cerrahi Derg* 2010; 16: 558-60.
- [13] Bonnefoy S, Corberand D, Sinayoko L, Harnois F, Menecier D, Thiolet C. Epiploic appendagitis: report of a case. *Gastroenterol Clin Biol* 2008; 32: 1092-4.
- [14] Schnedl WJ, Tillich M, Lipp RW. Image of the month. Primary epiploic appendagitis. *Clin Gastroenterol Hepatol* 2010; 8: A16.
- [15] Ünal E, Yankol Y, Sanal T, Haholu A, Buyukdogan V, Özdemir Y. Laparoscopic resection of a torsioned appendix epiploica in a previously appendectomized patient. *Surg Laparosc Endosc Percutan Tech* 2005; 15: 371-3.
- [16] Li L, Shen Z, Xu L, Guo G, Qin Y. Recurrent abdominal pain and fever as clinical manifestations: epiploic appendagitis. *Int J Clin Exp Med* 2014; 7: 4523-5.