

Original Article

Correlation between diffusion tensor imaging and pathology in rats with brain radiation injury

Xue-Jun Liu, Wei-Wei Fu, Guang-Wen Yang, Shi-En Liu, Ying Li, Chong-Feng Duan, Qing-Lan Sui, Wen-Jian Xu

Department of Radiology, The Affiliated Hospital of Qingdao University, Qingdao 266003, China

Received August 18, 2015; Accepted November 17, 2015; Epub January 15, 2016; Published January 30, 2016

Abstract: Objective: To research the change of Magnetic resonance diffusion tensor imaging (DTI) and pathology of radiation-induced brain injury and to investigate the apply value to early radiation-induced brain injury with DTI. Methods 30 rats were divided into 2 groups randomly: blank control and irradiation groups. The irradiation group rats were performed with MRI, DTI, HE staining, immunohistochemical staining of MBP and NF, electron microscopy on 1, 3, 6, 9, 12 months after radiation. Measure the FA. Results: 1. The differences of FA between any radiation groups and control group were statistical significant ($P < 0.05$). 2. The differences of MBP absorbance between any radiation groups and control group were statistical significant ($P < 0.05$). The differences of NF absorbance between any radiation groups in one months after radiation and control group were statistical significant ($P < 0.05$). 3. The FA positively correlated with the MBP ($r = 0.942$). The FA negatively correlated with NF ($r = -0.924$). Conclusion DTI can reflect the pathological changes of the white matter in radiation-induced brain injury at a micro level.

Keywords: Radiation-induced brain injury, diffusion tensor imaging (DTI), myelin basic protein (MBP), neurofilament (NF)

Introduction

Radiotherapy is one of the means for treating head and neck cancer, while brain radiation injury is the common complication after radiotherapy. Brain radiation injury leads to white matter damage [1, 2]. There are lesions found by conventional imaging, which shows that brain radiation injury becomes more severe disease. Therefore, detection diagnosis and early treatment are good for prognosis of brain radiation injury. Diffusion tensor imaging (DTI) is the only non-invasive method for reflecting water molecular motion of tissues in vivo, which reflects pathological changes of diseases [3]. We study on the DTI and pathologic change after radiotherapy for white matter, which provides clinical detection diagnosis with evidences.

Materials and methods

Establishment of brain radiation injury in rats

30 female Wistar rats, weighed 200 to 230 g, were obtained from Qingdao Medicine Institute

and randomly divided into control group, 1 month, 3 month, 6 month, 9 month and 12 month after radiation, 5 rats in each group. Rats were under intraperitoneal anesthesia with 10% chloral hydrate (0.35 ml/100 g), then were under single-whole-vertical brain irradiating with 6MeV electron beam from 23EX linear accelerator (Varian, USA), 300 Gy/min, 3.0 cm × 20 cm, 100 cm source-skin distance (SSD), and total dose of 20 Gy.

MRI scanning

Rats were under anesthesia, then placed within the coil with supine position and scanned with feet advancedly. Scanning sequence included T1WI, T2WI and DTI. Main parameters: T1WI TR = 400 ms, TE = 11 ms, FOV = 8 cm × 8 cm, matrix = 130 × 128, slice thickness = 2.0 mm, interlayer distance = 0 mm, flip angle = 90°, NEX = 2; T2WI TR = 3500 ms, TE = 110 ms, FOV = 8 cm × 8 cm, matrix = 130 × 128, slice thickness = 2.0 mm, interlayer distance = 0 mm, flip angle = 90°, NEX = 2. MR enhanced scan: TR = 1025 ms, TE = 24 ms, TI = 860 ms, FOV = 8 cm × 6 cm, slice thickness = 2.4 mm, interlayer distance = 0 mm.

Correlation between diffusion tensor imaging and pathology

Table 1. Comparison of FA between groups (one way anova), intra-groups (LSD-t test)

Groups	$\bar{x} \pm s$	Intra-group (vs. Control)			Between groups	
		Mean difference	Standard error	P	F	P
Control	0.321 ± 0.007					
1 month	0.303 ± 0.005	0.018	0.006	< 0.05		
3 month	0.257 ± 0.012	0.064	0.006	< 0.05		
6 month	0.235 ± 0.002	0.086	0.006	< 0.05		
9 month	0.226 ± 0.008	0.095	0.006	< 0.05		
12 month	0.199 ± 0.013	0.122	0.006	< 0.05	142.252	< 0.05

Comparing with control group, FA in each group decreased obviously as time went by. There were significant differences between each group and control group.

Table 2. MBP absorbance value and comparison between groups (one way anova), intra-groups (LSD-t test)

Groups	$\bar{x} \pm s$	Intra-group (vs. Control)			Between groups	
		Mean difference	Standard error	P	F	P
Control	0.934 ± 0.010					
1 month	0.890 ± 0.012	0.044	0.008	< 0.05		
3 month	0.832 ± 0.014	0.102	0.008	< 0.05		
6 month	0.776 ± 0.014	0.158	0.008	< 0.01		
9 month	0.666 ± 0.015	0.268	0.008	< 0.01		
12 month	0.576 ± 0.014	0.358	0.008	< 0.01	521.063	< 0.01

Comparing with control group, MBP absorbance value decreased obviously as time went by. There were significant differences between each group and control group.

Table 3. NF absorbance value and comparison between groups (one way anova), intra-groups (LSD-t test)

Groups	$\bar{x} \pm s$	Intra-group (vs. Control)			Between groups	
		Mean difference	Standard error	P	F	P
Control	0.148 ± 0.007					
1 month	0.176 ± 0.013	-0.028	0.012	> 0.05		
3 month	0.240 ± 0.027	-0.091	0.012	< 0.01		
6 month	0.384 ± 0.013	-0.236	0.012	< 0.01		
9 month	0.423 ± 0.010	-0.274	0.012	< 0.01		
12 month	0.461 ± 0.033	-0.313	0.012	< 0.01	238.225	< 0.01

Comparing with control group, NF absorbance value increased obviously as time went by. There were significant differences between each group and control group, except the 1 month group.

DTI was taken with spin echo-echo planar imaging (SE-EPI): TR = 4000 ms, TE = 114, slice thickness = 2.4 mm, without interval, FOV = 8 cm × 8 cm, NEX = 2, value of b = 0, 1000 s/mm².

Pathological examination

Rats were under magnetic resonance examination, then were under normal saline lavage, fixed with 4% paraformaldehyde. Brain tissues of rats were dehydrated in ascending series of ethanol, cleared in xylene and embedded in paraffin. Tissues were made into slices and under HE staining, MBP staining and NF staining. Vascular pattern were observed under microscope, while myelin sheath axons were observed under electron microscope.

Figures

Data were analyzed by Functool software. Corpus callosum was taken as ROI, with area of 0.9~1.1 mm² and examination of more than 3 times. Value of FA was shown as average value.

Absorbance values of MBP and NF were analyzed by Image-pro plus 5.0. Three visual fields were taken randomly and average value were obtained with three times of measurement.

Statistical analysis

Data were analyzed by SPSS 17.0. Values were shown as mean ± SDs. Comparison between groups were analyzed with one way anova. The measurement data were compared with LSD-t test, while the Dunnett and T3 test were used for variance non-homogeneity. A value of P < 0.05 considers significantly. Correlations between FA and MBP, FA and NF were reexamined with t test.

Results

Observation of rats condition after radiation

There were no unhairing, red swelling skin and so on after radiation, without notable loss of the body weigh, diet, drinking or movement. As

Correlation between diffusion tensor imaging and pathology

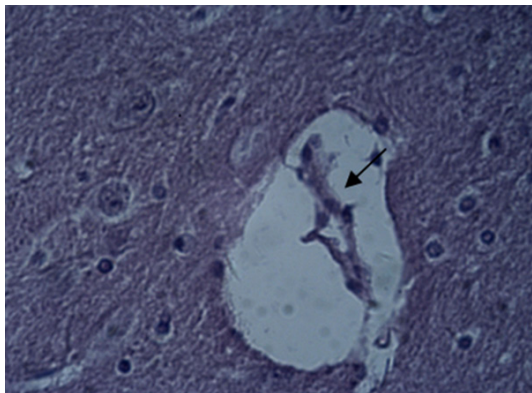


Figure 1. Vascular lumen became narrow or even block in rats' brain of 12 month group.

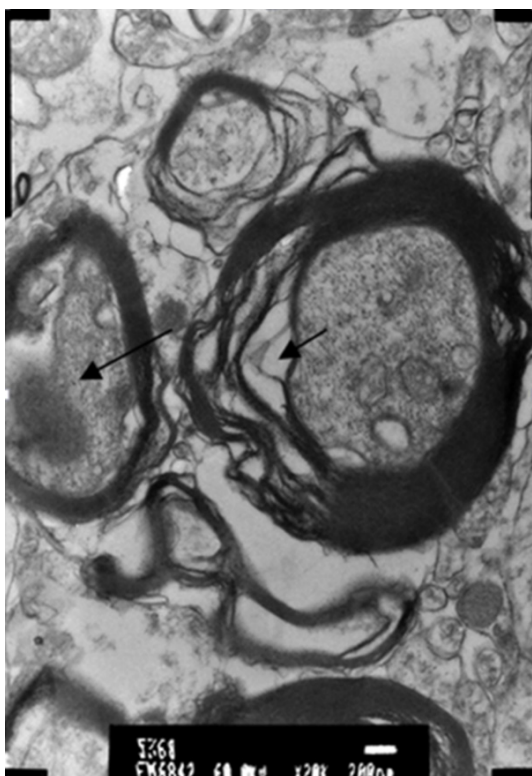


Figure 2. Structure of myelin sheath in rats changed, with loose and expanding gaps of myelin sheath and demyelination in some regions (short arrows); structure of axon was disorganized and unclear (long arrows).

time went by, most of the rats were had notable loss of movement, diet and drinking, with bad-response.

MRI detection

There were no abnormal signals after brain tissue detection of rats, and were without obvi-

ously abnormal-strengthen shadow by enhanced scanning.

Results of DTI

Comparing with control group, FA in each group decreased obviously as time went by. There were significant differences between each group and control group (**Table 1**).

Pathological examination

Comparing with control group, MBP absorbance value decreased obviously as time went by. There were significant differences between each group and control group (**Table 2**).

Comparing with control group, NF absorbance value increased obviously as time went by. There were significant differences between each group and control group, except the 1 month group (**Table 3**).

Under light microscope Vascular lumen in brain of rats became narrow after radiation by HE staining, as time went by (**Figure 1**).

Under electron microscope After 1 month treatment, the structure of myelin sheath became fuzzy. After 3 month treatment, the gap of myelin sheath loosened and enlarged, with distortion, separation, dissolution or even disappearance. The axons became swelling and not the same, with irregular morphology. The internal structure was unclear and disappearing (**Figure 2**).

Correlation between FA and MBP, FA and NF

Scatter diagram of correlation between FA and MBP, FA and NF (**Figures 3, 4**).

There were linear trend between FA and MBP, FA and NF from **Figures 3** and **4**. FA was positive correlated with MBP, which decreased as the value of MBP decreased; FA was negative correlated with NF, which decreased as the value of NF increased (**Table 4**).

Discussion

DTI detection index

DTI, as a non-invasive imaging method, is commonly used in the early research of radiation-induced brain injury. From multiple directions, diffusion sensitive gradient is used by DTI

Correlation between diffusion tensor imaging and pathology

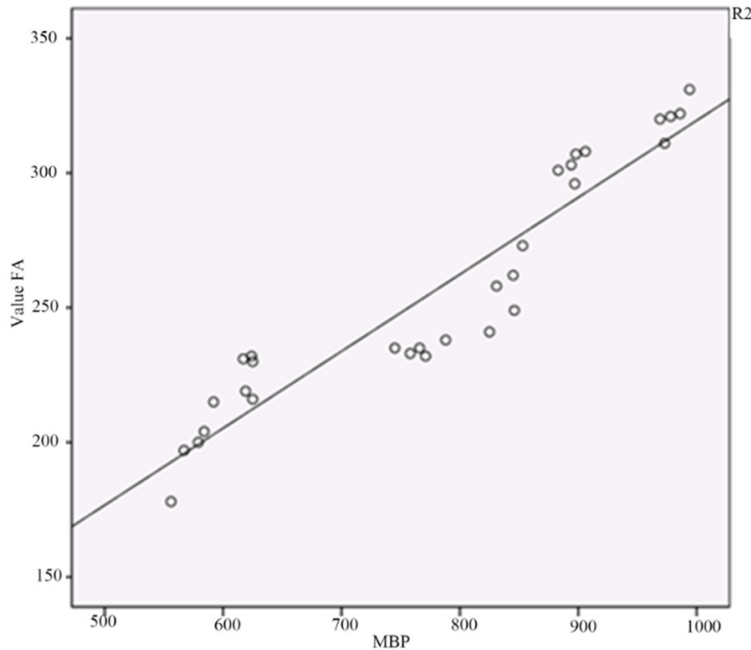


Figure 3. Correlation between FA and MBP in brain parenchyma of rats.

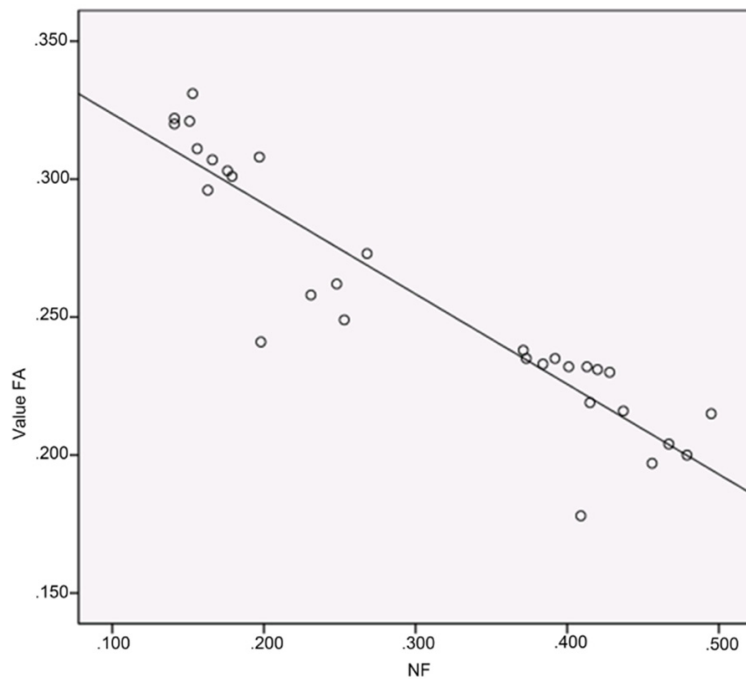


Figure 4. Correlation between FA and NF in brain parenchyma of rats.

to quantitatively evaluate the water diffusion, which could quantitatively reflect the tiny pathological change and physiological structure of tissues [4], whose usual parameters are fractional anisotropy (FA). FA is the ration of anisotropic compositions of diffusion tensor and the

whole diffusion tensor, which could reflect the exercise intensity of water on the main diffusion vector axis. The change of FA could quantitatively reflect the change of tissue tiny structure [5], while the main factors of influencing the anisotropic diffusion of white matter are myelin sheath and axons.

Nerve fibers are the highly differentiated nerve tissue, including myelinated nerve fiber and unmyelinated nerve fiber. Myelinated nerve fiber contain myelin sheath and axon. Nerve fibers are complete and ordered, with faster water diffusion paralleling to long axis direction and slower water diffusion being vertical to the direction. Because myelin sheath and axon could prevent water from diffusion on the vertical direction, so nerve tissues express fractional anisotropy of diffusion.

Pathological index

Radiation brain injury could induce changing of white matter [1, 2], such as demyelination and axonal injury. Myelin basic protein (MBP) is a kind of membrane protein, which is endemic to myelin sheath. MBP is synthesized from matrue oligodendrocyte, which plays an improtant role in sustaining the morphology and function of neurons, asons and myelin sheath. As an index of reflecting central nervous system material injury, especially the demyelination with more sensitive and specific [6], MBP increase when myelin sheath is

damaged. Neurofilament (NF) is the main component of nerve axon cytoskeleton, which is the important material base sustaining the structure of axon and stable function. NF is a specific index reflecting axonal injury [6]. When axon is damaged, NF decreases, so MBP and

Correlation between diffusion tensor imaging and pathology

Table 4. Correlation analysis between FA and MBP, FA and NF, and t test of value r

Correlation	r	t	P
FA and MBP	0.942	14.85	< 0.05
FA and NF	-0.924	-12.79	< 0.05

NF could accurately reflect the change of myelin sheath and axon induced by radiation brain injury.

Correlation between FA and MBP, FA and NF

Wang [7] et al. radiated the right parietal cortex of 20 Wister rats and took MRI sequences detection after 1, 2, 4 and 6 weeks, then they found that FA decreased from the 1st and reached the lowest at the 6th week after radiotherapy by DTI detection. Silun Wang [8] et al. radiated one side of the hemisphere of 19 Wister rats, aging 12-week, and took DTI detection, then they found that FA of white matter tracts didn't change significantly in 4 weeks after radiation, but decreased from the 4th to 48th week. Nagesh [9] et al. took DTI detection for 25 patients with brain glioma at prophase, metaphase and anaphase, then they found FA of normal brain white matter linear decreased, which reflected the process of gradual demyelination and degradation of axon structure after radiotherapy. Our results were consistent with those researches at home and abroad. After radiotherapy, FA of corpus callosum in rats decreased and the absorbance value of MBP decreased gradually, which showed the two were positively correlated. Absorbance value of NF increased gradually, which showed the FA and NF were negatively correlated. After 1 month of radiation, FA of corpus callosum in rats decreased. Under electron microscope, we found vascular dilatation, ply structure of myelin sheath became unclear and swelling, and the no obvious positive staining changes of MBP. After 3, 6, 9 and 12 month of radiation, FA of corpus callosum in rats decreased gradually and significantly. Under electron microscope, we found that the vascular endothelial injury, axons were damaged and aggravated gradually, vascular lumen became narrow gradually or even blocked, positive staining of MBP decreased gradually, while positive staining of NF increased gradually. We considered that the reason of FA decreased after 1 month of radiation included vascular dilatation, capillary permeability increasing, slightly swelling glial cells,

myelin sheath slight injury, gap between cells became narrow, which led to water diffusion decreasing. After 3, 6, 9 and 12 month, FA decreased because vessel and glial cells injury aggravated gradually, myelin sheath and axons were damaged gradually, structure of nerve fibers was disorganized and decreasing with tortuosity of running, and the ability of anisotropic diffusion decreased. Therefore, FA of white matter in radiation brain injury decreased because as the longer the time of radiation, myelin sheath and axons injury aggravated gradually, the integrity was damaged, the diffusibility of water along white matter fibers decreased gradually, and anisotropy decreased.

To draw a conclusion, white matter is damaged easily in radiation brain injury. DTI could reflect the pathologic changes, which helps to early detection of radiation brain injury and has an important role in clinical early diagnosis and therapy.

Acknowledgements

People's Livelihood Project in Science and Technology Development Plan of Qingdao (Grant No. 14-2-3-7-nsh). Science and Technology Development Plan of Qingdao (Grant No. 12-1-4-2-(10)-jch).

Disclosure of conflict of interest

None.

Address correspondence to: Drs. Qing-Lan Sui and Wen-Jian Xu, Department of Radiology, The Affiliated Hospital of Qingdao University, 16 Jiangsu Road, Qingdao 266003, China. Tel: -86 +0532-82911004; Fax: -86+0532-82911004; E-mail: suiq@163.com (QLS); cjr.xuwenjian@vip.163.com (WJX)

References

- [1] Valk PE and Dillon WP. Radiation injury of the brain. *AJNR Am J Neuroradiol* 1991; 12: 45-62.
- [2] Ball WS Jr, Prenger EC and Ballard ET. Neurotoxicity of radio/chemotherapy in children: pathologic and MR correlation. *AJNR Am J Neuroradiol* 1992; 13: 761-776.
- [3] Rovaris M, Agosta F, Pagani E and Filippi M. Diffusion tensor MR imaging. *Neuroimaging Clin North Am* 2009; 19: 37-43.
- [4] Feng HY, Wang FZ, Pan SN and Guo QY. A preliminary study of acute injury in rat skeletal muscle MRI-DTI squeeze. *Zhongguolinchuan-gyixueyingxiangzazhi* 2010; 21: 445-447.

Correlation between diffusion tensor imaging and pathology

- [5] Yamazaki Y, Yada K, Morii S, Kitahara T and Ohwada T. Diagnostic significance of serum neuron-specific enolase and myelin basic protein assay in patients with acute head injury. *Surg Neurol* 1995; 43: 267-271.
- [6] Hisanaga S, Gonada Y, Inagaki M, Ikai A and Hirokawa N. Effect of phosphorylation of the neurofilament protein on filamentous structures. *Cell Reg* 1990; 1: 237-248.
- [7] Wang Y. Preliminary study of early MRI brain radiation injury in rats. The PLA Postgraduate Medical School 2013.
- [8] Wang S, Qiu D, So KF, Wu EX, Leung LH, Gu J, Khong PL. Radiation induced brain injury: assessment of white matter tracts in a pre-clinical animal model using diffusion tensor MR imaging. *J Neurooncol* 2013; 112: 9-15.
- [9] Nagesh V, Tsien CI, Chenevert TL, Ross BD, Lawrence TS, Junick L and Cao Y. Radiation-induced changes in normal-appearing white matter in patients with cerebral tumors: a diffusion tensor imaging study. *Int J Radiat Oncol Biol Phys* 2008; 70: 1002.