

Case Report

The value of esophageal stenting for the treatment of benign tracheoesophageal fistulas: case report

Hai Xu, Jianqun Ma, Jun Wu, Changfa Qu, Fenglin Sun, Shidong Xu

Department of Thoracic Surgery, Harbin Medical University Cancer Hospital, Harbin 150086

Received August 26, 2015; Accepted December 11, 2015; Epub January 15, 2016; Published January 30, 2016

Abstract: We report the causes and characteristics of benign tracheoesophageal fistulas (TEF) in 14 cases and investigate the effects of different stenting methods in the treatment of TEF. Among the 14 cases, 2 cases resulted from inflammation, 8 cases from post-esophagectomy complications, 2 cases from complications of esophageal stenting for anastomotic strictures, and 2 cases from complications of chemoradiatio. Esophageal stenting was performed as the primary management in 7 cases and only one healed. Severe complications occurred in 6 cases, including 2 cases with esophageal stenosis and 4 cases with death from non-healing fistulas. Five patients were managed conservatively and 4 healed spontaneously. One patient received tracheal stenting but suffered from severe coughing. The other with gastric necrosis and a large fistula with mediastinitis underwent urgent surgical debridement and diversion procedures. Esophageal stenting for benign TEFs carries a high complication rate and mortality and therefore is not recommended.

Keywords: Tracheoesophageal fistula, esophageal stenting, tracheal stenting, post-operative complications, esophageal cancer

Introduction

Tracheoesophageal fistulas (TEFs) can be life threatening and difficult to manage. TEFs commonly occur as a complication of advanced esophageal cancer. Leakage of esophageal contents into the airway may cause life-threatening aspiration pneumonia. Placement of an esophageal stent is a common palliative approach to temporarily seal the fistula to relieve symptoms and prevent such catastrophe in patients with advanced esophageal cancer [1-3].

Benign TEFs are rare and usually the result of trauma or congenital malformation. Benign TEFs are typically managed surgically [4]. The TEF caused by Barrett's ulcer can heal spontaneously after surgical interventions are performed to control reflux [5]. Surgical treatment for TEFs is a major undertaking which often involves an esophagectomy with significant peri-operative complications and variable outcomes. Therefore, non-surgical treatment such as esophageal stenting is commonly employed. Long-term stenting for benign TEFs has its own

problems such as erosion and the need to change the stent. Choosing the right treatment can be difficult and needs to be based on individual cases. The objectives of the current study were to retrospectively review our experience in managing benign TEFs, analyze the causes, and evaluate the outcomes of different treatment options.

Case report

The medical records of these 14 benign TEFs were reviewed. The etiology of the benign TEFs is summarized in **Table 1**. There were 10 male and 4 female patients, with a mean age of 56 ± 2 years (ranged from 44 to 69 years).

Case #1 one was initially diagnosed with left pneumonia by CT-scan and managed with antibiotics. While the symptoms of fever and cough were not relieved and the tuberculosis was subsequently proved one month later by the bronchoscopy. The TEF in this case one was then confirmed with bronchoscopy and esophagoscopy after two weeks of the diagnosis of tuberculosis. The fistula on the esophageal side

Managing benign tracheoesophageal fistulas

Table 1. Etiology and management of benign tracheoesophageal fistulas

Case	Causes	Pathological staging	Treatment
Inflammation			
#1	Left main bronchus tuberculosis		esophageal stent
#2	Middle third thoracic esophageal diverticulum		conservative
Post-esophagectomy complications			
#3	Middle thoracic esophageal tuberculosis		esophageal stent + operation
#4	Middle third thoracic esophageal squamous cell carcinoma	T ₃ N ₀ M ₀ II _a	conservative
#5	Middle third thoracic esophageal squamous cell carcinoma	T ₃ N ₀ M ₀ II _a	conservative
#6	Lower third thoracic esophageal squamous cell carcinoma	T ₃ N ₁ M ₀ III	conservative
#7	Middle and lower third thoracic esophageal squamous cell carcinoma	T ₃ N ₁ M ₀ III	tracheal stent
#8	Middle third thoracic esophageal squamous cell carcinoma	T ₃ N ₁ M ₀ III	operation
#9	Middle third thoracic esophageal squamous cell carcinoma	T ₁ N ₀ M ₀ I	conservative
#10	Lower third thoracic esophageal squamous cell carcinoma	T ₂ N ₀ M ₀ II _a	esophageal stent
Complication of Esophageal stenting for post-operative anastomotic stricture			
#11	Middle third esophageal squamous cell carcinoma	T ₂ N ₀ M ₀ II _a	esophageal stent
#12	Middle third thoracic esophageal squamous cell carcinoma	T ₃ N ₁ M ₀ III	esophageal stent
Complication of Radiotherapy			
#13	Right middle lower lobe squamous cell carcinoma	T ₂ N ₂ M ₀ IIIA	esophageal stent
#14	Right middle lower lobe squamous cell carcinoma	T ₂ N ₂ M ₀ IIIA	esophageal stent

measured 6×6 mm at 26 cm from the incisor. The fistula on the tracheal side was located at the left main stem bronchus and measured as 4×5 mm. The patient tolerated an esophageal stent placement and a subsequent liquid diet. The fistula healed 2 weeks following stent placement as demonstrated on a repeat bronchoscopy and the patient was discharged home 1 week later. Eight months later, however, the patient developed dysphagia. Esophagoscopy showed severe hyperplasia and esophageal stricture below the stent (**Figure 1A**). The granulation tissues were cauterized and the stricture, dilated endoscopically (**Figure 1B** and **1C**). While the stricture came back after 1.5 months and the operation aimed to remove the hyperplasia was needed to make orally take in possible.

Case #2 was diagnosed with middle third thoracic esophageal diverticulum which eventually caused the tracheoesophageal fistula at 27 cm from the incisor. The fistula measured as 3×3 mm on esophagoscopy. This patient was managed conservatively with a jejunostomy and enteral feeding. The fistula healed 14 days and he tolerated a liquid diet.

The TEFs in cases #3 to #9 suffered from complications following surgical treatment for esophageal cancer (**Table 2**). The onset of TEFs ranged from 8 to 40 days (mean: 16.13 days) following surgery. Four cases were managed conservatively (Case #4, #5, #6, and #9). Case

#4 healed spontaneously in 36 days and case #5 in 83 days. The esophagoraphy confirmed the healing by the image of no contrast agent coming out from esophagus to the airway. Case #6 healed spontaneously in 76 day. The healing, however, the TEF at the anastomosis in case #9, never recovered before his death 9.4 months after surgery. The overall spontaneous healing rate was 75%. Two patients received esophageal stenting as the first line treatment (case #3 and #10). The fistula in case #10 healed on the 19th days after stent placement without further complications. However, case #3 developed severe hyperplasia and stenosis in 5.3 months after esophageal stent placement (**Figure 2A**), similar to case #1. The stenosis was dilated and a second esophageal stent was placed (**Figure 2B-D**). However, the fistula never healed and subsequent surgical repair was performed in 2.5 months after the second stenting failing. Part of the esophageal wall was used as the patch flap to close the tracheal defect and the operation was successfully performed. The patient recovered well but slowly, and began to take in liquid food one month later. No complication was found and the patient was discharged in 1.5 months after the surgery. A tracheal stent was placed in case #7 (**Figure 1D-F**) due to severe dyspnea caused by airway stenosis adjacent to the fistula. The fistula healed in 30 days as confirmed with esophagoscopy. However, the patient suffered from severe coughing due to the irritations by the

Managing benign tracheoesophageal fistulas

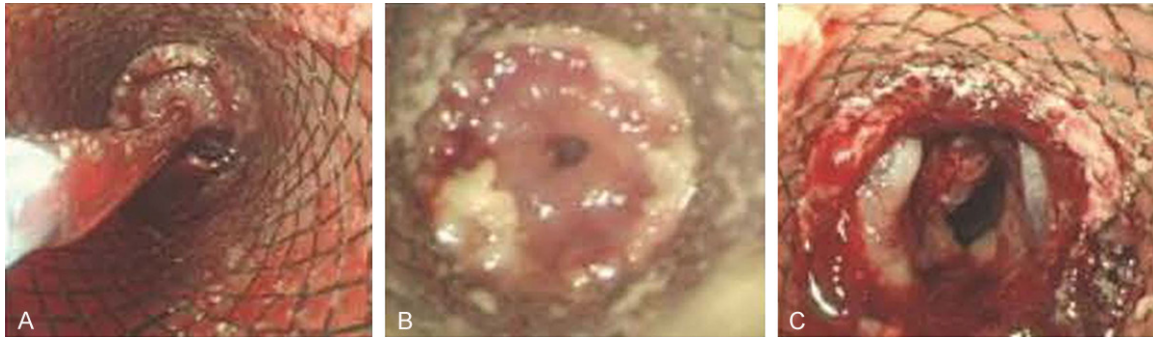


Figure 1. A. Stenosis below the esophageal stent; B. Cauterization of granulation tissues and dilatation of stenosis; C. Immediately after dilatation. The pictures of complications: D. Top of the tracheal stent; E. Distal extent of the tracheal stent; F. Hyperemia and edema of the tracheal mucosa at the distal end of the stent.

Table 2. Treatment and outcomes for post-esophagectomy fistulas

Case	Initial surgery	TEF onset (days)	Outcome	Survival time (months)
#3	Vats lesion resection	12	unhealed	9.6+
#4	Ivor levis	18	36 days healed	13.0+
#5	Ivor levis	40	83 days healed	4.6+
#6	left thoracotomy	8	76 days healed	4.7+
#7	Ivor levis	8	30 days healed	6.0+
#8	Ivor levis	14	healed	7.4+
#9	left thoracotomy	13	unhealed	9.4+
#10	left thoracotomy	150	healed	19.0+

tracheal stent. Lastly, case #8 developed partial necrosis of the stomach with a large 2×2 cm fistula between the stomach and the right main stem bronchus. Due to the gastric necrosis, severe infection and a large fistula, the patient underwent urgent debridement of the necrotic and infected tissues with an esophageal diversion in the neck and a right pneumonectomy. The patient tolerated the procedure well and opted not to have further reconstruction.

Case #11 and #12 who both underwent Ivor levis esophagectomy developed symptomatic anastomotic stenosis in 11 and 7 months after esophagectomy, respectively. They did not receive post-operative radiation, and failed endoscopic dilations. Therefore, esophageal stents were placed to make orally take-in possible. TEFs developed in 1.5 and 3.5 months later in cases #11 and 12, respectively. In case #11, the TEF was found at the lower end of the stent and a second esophageal stent was placed across the fistula. In case #12, the TEF was also found at the lower end of the stent but with the severe stricture and a second esopha-

geal stent was also placed across the fistula. The case #11 was relieved first and took in normally, but the cough and fever was still observe, on the contrary, worsened after two weeks and died 1.5 months later. Case #12 did not improve since the stenting implement and died in 12 days later due to infection and severe aspiration pneumonia.

Cases #13 and #14 who underwent right middle and lower lobectomies for lung cancers followed by chemoradiation therapy. The patients then developed a tracheoesophageal fistula 1.0 and 3.0 months after the completion of chemoradiation, respectively, with no evidence of tumor recurrence. Under the display of Diatrizoate imaging, TEF was found between the middle third esophagus and right main bronchus, Both fistulae were treated with an esophageal stent. The whole course was similar with #11 for the patients #13 and #14 who died 1.7 and 1.0-month later because of the serious lung infection caused by the failure of the stenting.

Discussion

Although surgical interventions were generally recommended for the treatment of TEFs [9-11], in our cancer center, surgical approach was usually not accepted because most of the patients with benign TEFs had received the open thoracotomy, they usually refused to undergo the second procedure and also it was difficult for the surgeons to choose the tough and complicated second operation with high

Managing benign tracheoesophageal fistulas

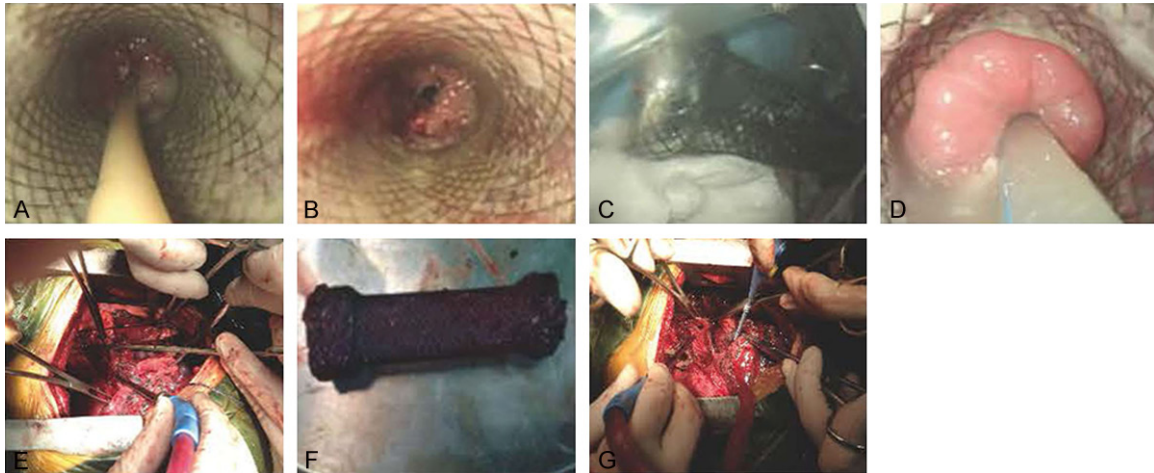


Figure 2. A. The first stent and jejunal feeding tube. B. Stenosis below the esophageal sent. C. Removed first stent. D. Gastric tube and the second stent implanted after first stent was removed. E. Unhealed TEF and the second placed stent. F. Removed stent. G. Part esophageal wall used to cover the TEF.

risk. Under this circumstance, whether the stenting was a good choice? Was stenting really a fast and effective intervention in treating TEF? In this series, we reviewed our experience of managing TEFs of various causes with surgical or non-surgical approaches.

One of our patients with a TEF caused by tuberculosis in the left main stem bronchus was initially treated with esophageal stenting. However, the fistula never healed and subsequent esophageal stricture necessitated surgical intervention. TEFs caused by perforation of esophageal diverticula are rare. Case reports in the literature suggested that surgical intervention was necessary for cure [6]. In our case, however, the fistula was rather small and we elected to manage it conservatively with NPO and nutritional support. The fistula healed spontaneously within two weeks. The management of such fistulas should be individualized depending on the size, inflammation, presence of infection, and tissue quality.

The application of biological agent may be considered to facilitate the closure of benign TEFs [7]. When there is gastric necrosis and large fistula with mediastinal infection, urgent surgical debridement and esophageal diversion are life-saving procedures. Our results with esophageal stenting were disappointing. Only 1 of the recorded 7 TEFs following esophageal stenting healed without complications. Endoluminal stenting may provide temporary relief of symptoms of aspiration or dysphagia, and is gener-

ally indicated as a palliative measure for advanced esophageal cancers that are non-surgical candidates. They are however not effective to treat benign TEFs [8, 9]. In our data, four of seven patients died 1.7, 1.5, 1.0 and 0.4 months after the stenting. In terms of the much high short-term mortality, we therefore generally do not recommend esophageal stenting. While, what caused the astonishing high short-term mortality and what happened after the stent was placed? It really forced us pondering. By analyzing the history, we found that the patients usually suffered from the fever and cough even after stenting, and the problem was that the symptoms even worsened gradually. We presumed that since the TEF was accompanied with the inflammation, the inflammatory exudate drained to both airway and esophagus, while by closing the fistula in the esophageal wall using the stent, the inflammatory exudate draining to the esophagus would be blocked and as accumulating, more and more inflammatory exudate were drained to the airway and led to urgent respiratory failure. On the other hand, the oppression of the stent may also restrain the blood supply for the TEF inflammatory lesion and thus impeding the healing of the TEF. For the two who suffered from stenosis caused by the long-term stimulation of the stent, the onset of the symptomatic stenosis was 5.3 and 8 months respectively indicated that the hyperplasia usually came up after a long-term stimulation, whether we could create the novel stent which would be removed even after long time placement or we remove the

Managing benign tracheoesophageal fistulas

stent shortly after the symptom and the condition of the patient getting stable was still needed to be studied.

As a result, in our experience, we think conservative management was still firstly considered when TEF confirmed. While, if the symptoms caused by the TEF such as aspiration, malnutrition worsened continuously, the surgical intervention was recommended. The TEFs can be repaired by esophageal reconstruction and esophageal wall in situ as replacement of the posterior membranous wall of the trachea as we did in case one.

Similarly, tracheal stenting may be a reasonable option for malignant tracheoesophageal fistulae [10] but not for benign lesions. Tracheal stenting causes severe airway irritation, formation of granulation tissues, and secondary strictures [11] as demonstrated in our experience.

Esophageal stenting is commonly used to treat refractory postoperative anastomotic strictures. The risk of developing TEFs are, however, high especially for those who have undergone chemoradiation therapy [12]. These fistulas can be successfully treated with surgery with a reported mortality of 3.4-8.3% [13]. The two cases in this series declined surgical intervention and therefore received esophageal stenting. Both patients died shortly after due to failed closure of the fistulae. We agree with the literature that esophageal stenting is not indicated for treating postoperative anastomotic strictures due to the high incidence of complications and mortality. Endoscopic dilation is considered the preferred choice with minimal risk [14]. Surgical management is reserved for those who have failed repeated dilations.

In conclusion, treatment for TEFs needs to be individualized. Careful assessment of the fistula and the associated problems is crucial to determine the possibility of conservative management with spontaneous healing of the fistula. Surgical treatment remains the mainstay for the management of benign TEFs whereas esophageal stenting carries high complication rates and should only be considered as a palliative measure. Further clinical study should be focused on how to create a novel stent to resolve the issue of blocked drainage leading to the high short term mortality and how to avoid the granulation tissue hyperplasia caused

by the long-term stimulating of the stent, otherwise, the application of the stent was not recommended.

Disclosure of conflict of interest

None.

Address correspondence to: Shidong Xu, Department of Thoracic Surgery, Harbin Medical University Cancer Hospital, Haping Road 150, Nan Gang District, Harbin 150086, China. Tel: +8645186298036; Fax: +8645186298666; E-mail: shidongxu@yeah.net

References

- [1] Lin SH and Wu TT. Medical image. Advanced oesophageal cancer complicated with tracheoesophageal fistula and aspiration pneumonia. *N Z Med J* 2007; 120: U2513.
- [2] Herth FJ, Peter S, Baty F, Eberhardt R, Leuppi JD and Chhajed PN. Combined airway and oesophageal stenting in malignant airway-oesophageal fistulas: a prospective study. *Eur Respir J* 2010; 36: 1370-1374.
- [3] Balazs A, Kupcsulik PK and Galambos Z. Esophagorespiratory fistulas of tumorous origin. Non-operative management of 264 cases in a 20-year period. *Eur J Cardiothorac Surg* 2008; 34: 1103-1107.
- [4] He J, Chen M, Shao W, Li S, Yin W, Gu Y, Wang D and Tucker S. Surgical Management Of 3 Cases With Huge Tracheoesophageal Fistula With Esophagus Segment in situ As Replacement Of The Posterior Membranous Wall Of The Trachea. *J Thorac Dis* 2009; 1: 39-45.
- [5] Diehl JT, Thomas L, Bloom MB, Dresdale AR, Harasimowicz P, Daly BD and Cleveland RJ. Tracheoesophageal fistula associated with Barrett's ulcer: the importance of reflux control. *Ann Thorac Surg* 1988; 45: 449-450.
- [6] De Giacomo T, Francioni F, Venuta F, Rendina EA and Ricci C. [Benign esophageal-respiratory fistulae. The surgical treatment and results of 10 cases]. *Minerva Chir* 1993; 48: 311-316.
- [7] Benko I, Molnar TF and Horvath OP. A case of fibrin sealant application for closing benign trachea-esophageal fistula (TEF). *Acta Chir Hung* 1997; 36: 25-26.
- [8] Muniappan A, Wain JC, Wright CD, Donahue DM, Gaissert H, Lanuti M and Mathisen DJ. Surgical treatment of nonmalignant tracheoesophageal fistula: a thirty-five year experience. *Ann Thorac Surg* 2013; 95: 1141-1146.
- [9] Eleftheriadis E and Kotzampassi K. Temporary stenting of acquired benign tracheoesophageal fistulas in critically ill ventilated patients. *Surg Endosc* 2005; 19: 811-815.

Managing benign tracheoesophageal fistulas

- [10] Albes JM, Schafers HJ, Gebel M and Ross UH. Tracheal stenting for malignant tracheoesophageal fistula. *Ann Thorac Surg* 1994; 57: 1263-1266.
- [11] Gaissert HA, Grillo HC, Wright CD, Donahue DM, Wain JC and Mathisen DJ. Complication of benign tracheobronchial strictures by self-expanding metal stents. *J Thorac Cardiovasc Surg* 2003; 126: 744-747.
- [12] Bick BL, Song LM, Buttar NS, Baron TH, Nichols FC, Maldonado F, Katzka DA, Enders FT and Topazian MD. Stent-associated esophago-respiratory fistulas: incidence and risk factors. *Gastrointest Endosc* 2013; 77: 181-189.
- [13] Shichinohe T, Okushiba S, Morikawa T, Kitashiro S, Manase H, Kawarada Y, Sekido M, Yamamoto Y and Kondo S. Salvage of a massive esophago-tracheal fistula resulting from a stenting treatment. *Dis Esophagus* 2006; 19: 299-304.
- [14] Cakmak M, Boybeyi O, Gollu G, Kucuk G, Bingol-Kologlu M, Yagmurlu A, Aktug T and Dindar H. Endoscopic balloon dilatation of benign esophageal strictures in childhood: a 15-year experience. *Dis Esophagus* 2014; [Epub ahead of print].