

Case Report

A case report of two mutations of the homogentisate 1,2-dioxygenase gene in a Chinese Alkaptonuria

Min Ma*, Shulin Luo*, Yanhui Wei*, Liangyu Lu*, Junfeng Cai, Feng Yin

*Department of Orthopedic Surgery, Shanghai East Hospital of Tongji University, Shanghai 200120, China. *Equal contributors and co-first authors.*

Received October 22, 2015; Accepted January 16, 2016; Epub October 15, 2016; Published October 30, 2016

Abstract: Alkaptonuria (AKU) is an autosomal recessive disorder resulting from the mutation of the homogentisate 1,2-dioxygenase (HGD) gene. In this paper, we report a case of AKU osteoarthritis of the knee. After the DNA was extracted from 5 ml blood samples of patient's cephalic vein, exons of the HGD gene were amplified by PCR. After positive colonies were verified for PCR, the sequence was analyzed. After multiple sequence alignment was performed, the mutation of GGA to TGA was found in exon 3 and CAA to CAT was found in exon 4 of HGD gene. Our findings of these mutations may further expand the spectrum of known HGD gene mutations and provide a basic for better prenatal molecular diagnosis of AKU.

Keywords: Osteoarthritis, ochronotic arthritis, Alkaptonuria, cartilage

Introduction

Alkaptonuria (AKU), as a rare autosomal recessive disorder, results from mutations in the homogentisate 1,2-dioxygenase (HGD) gene. It is characterized by the accumulation of homogentisic acid [1]. Abundant homogentisic acid is excreted by urine and turns black when exposed to the air. During In AKU patients, ochronotic pigment was deposited in the connective tissues, especially in cartilage. Ochronotic arthropathy is the most common complication of AKU, which results from the homogentisic acid deposition [2]. Mutations in the human HGD gene have been reported in many countries all over the world [3, 4]. The high incidence of HGD gene has been found in the areas of Slovakia and the Dominican Republic [5]. Most of these mutations, including missense mutations, splice sites, nonsense mutations and small insertions/deletions are mainly located in exons 6, 8, 10 and 13 [5]. However, the reports about HGD mutation in Asian population especially in Chinese are rare. A recent study reported that the splicing mutation of IVS7+1G>C, a donor splice site of exon 7, and a missense mutation of F329C in exon 12 were found in a Chinese AKU family [6]. In the present study, we reported novel HGD mutation points at exon 3

and 4 of the HGD gene in a Chinese case of ochronotic arthropathy.

Case report

A 57-year-old man, with a height of 165 cm and a weight of 53 kg, presented with a 6-month history of walking difficulty and was diagnosed as traumatic right knee arthritis. During the process of knee surface replacement operation, a characteristic black was found throughout the full-thickness of knee joint cartilage. Scattered pigmentation was shown in the tendons and meniscus, but was not in the subchondral bone (**Figure 1**). The patient was an only son of a consanguineous marriage family and had one 25-year-old child. His child was normal without pigment or lower back pain. The patient's urine turned black when exposed to air or added with ferric chloride. Besides, a high concentration of homogentisic acid was measured in the urine. He was diagnosed with AKU osteoarthritis of the knee ultimately [7]. Six months after total knee arthroplasty (TKA), significant improvement in knee pain and daily activities were found in the patient.

The genomic DNA was extracted from 5 ml blood samples of patient's cephalic vein by using QIAamp DNA Blood Mini Kits (Qiagen,

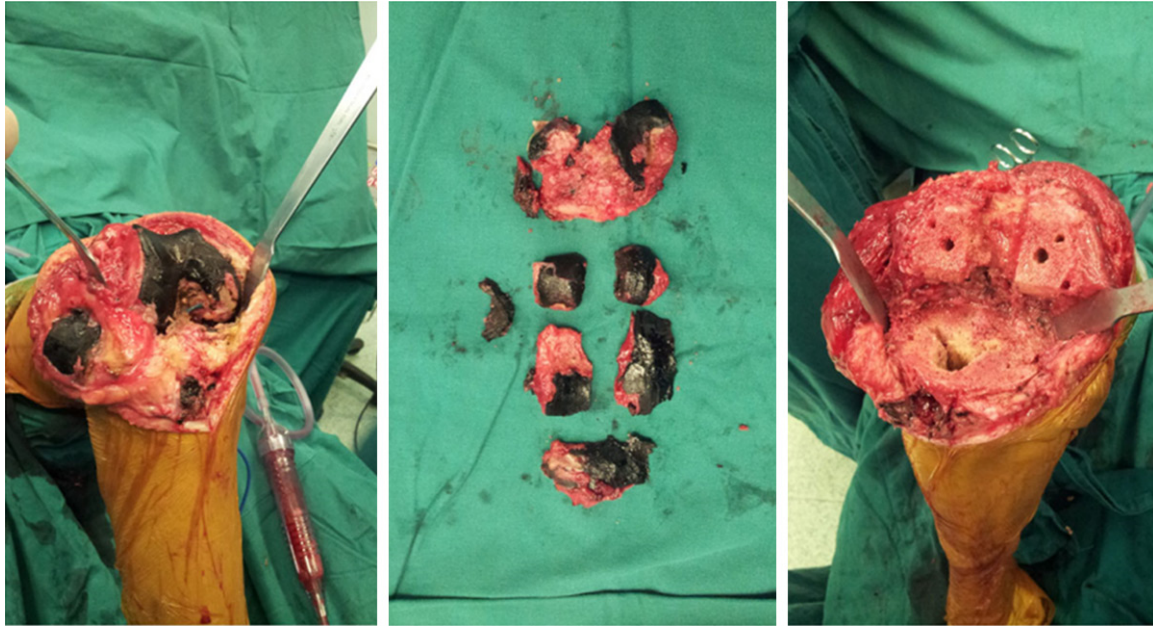


Figure 1. The color of the knee joint cartilage was carbon 155 black, involved in full-thickness of the cartilage just like “carbonize arachis hypogaea”. The tendon and meniscus pigment were also scattered, subchondral bone was normal.

Table 1. PCR primers for genomic amplification of the HGD exons

Exon	Forward	Reverse
1	5'-gtccctgtgtatgagtagaca-3'	5'-agagaaacgtgcatgtccgt-3'
2	5'-atgcaatatccagcactcttc-3'	5'-tgctgtgccaccaatccaa-3'
3	5'-ctggttgtagataatgggtg-3'	5'-cagtcacttggtgctagct-3'
4	5'-gtgatgctgtatcattgcttc-3'	5'-ccatgcagaactgtgagtc-3'
5	5'-tcacaagtagagcctcacag-3'	5'-gacatcagacatcaaagtgag-3'
6	5'-agaggctgcctggattcc-3'	5'-cattccagggtccatcct-3'
7	5'-acagggtcattacagtctgc-3'	5'-ccacatcagaaaggtccaga-3'
8	5'-ttccttgctggtgacca-3'	5'-gcttactcttcagcacatgg-3'
9	5'-agagggtagactagaattggc-3'	5'-agacacttggtctagagaaga-3'
10	5'-tgtggagtagctcttgacatg-3'	5'-gcacaaccttggagtcaga-3'
11	5'-tctgctcatgtgtgatcag-3'	5'-gtatctggcttcttccct-3'
12	5'-tggaagctacaattcaggatg-3'	5'-gtccagaaataaccaggca-3'
13	5'-tgtgttcttgaattctgcag-3'	5'-ccaggctgactccaagt-3'
14	5'-caggtctcaccagcttaca-3'	5'-ccacagaacaccagcaagt-3'

Hilden, Germany). Exons of the HGD gene were amplified by specific PCR primers (Table 1). The annealing temperature for all primers was 68°C. Then PCR products were separated on gels and purified with the QIAEXII gel extraction kit (Qiagen, Valencia, CA, USA). Then, the PCR products were linked to the destination vector and transferred into DH5α. The positive colonies were extracted for sequence analysis.

Multiple sequence alignment was carried out by using ClustalW [8].

There were two mutations in the HGD intron region. One mutation of GGA to TGA was in the exon 3 of the HGD, which led the Glycine at 46 to a termination codon. The other one of CAA to CAT was in the exon 4, which resulted in the replacement from Glutamine to Histidine (Figure 2). This mutation was a new mutation which was not found in the HGD mutation database (http://hgddatabase.cvtisr.sk/home.php?select_db=HGD) or AKU database (<http://www.alkaptonuria.cib.csic.es>).

This study was approved by ethical committee of East Hospital, Shanghai, and the patient had given the detailed informed consent before study.

Discussion

Ochronotic arthropathy is a musculoskeletal presentation of AUK, and is caused by a loss-of-function mutation on chromosome 3q, which results in deficiency of HGD [9]. Although at

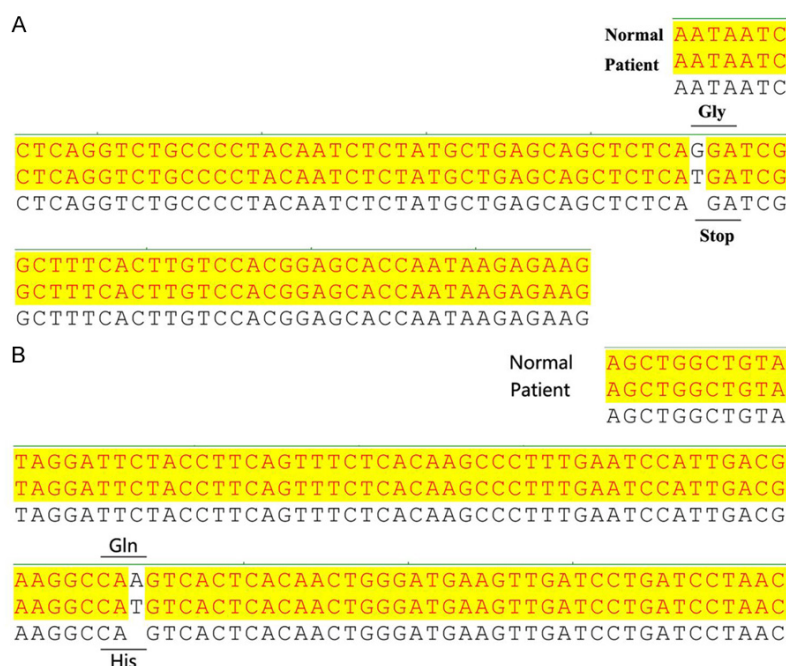


Figure 2. Sequence results revealed a point mutation of GGA to TGA in exon 3 (A) and CAA to CAT in exon 4 (B).

least 100 HGD mutations have been reported all over the world, the HGD mutation in Chinese is very rarely. Here, we reported a Chinese Ochronotic arthropathy patient with two AKU mutation point. One mutation was GGA to TGA in the exon 3 and the other mutation of CAA to CAT was in exon 4.

In our study, the parents of ochronotic arthropathy patients were consanguineous marriage (first cousins). AKU is reported to be relevant with consanguineous marriage [10]. A retrospective study of 96 French AKU patients from 81 different families has reported that the AKU patients presented with an autosomal recessive disorder [11]. It is more prevalent in females than males and shows a strong predominance of sibship with one affected case [11]. Additionally, the families were dispersed throughout French territory, corresponding to a low rate of consanguinity and the determination of mutations in the HGD gene, giving a disease incidence of approximately 1:680,000 [6].

In this study, we determined the two mutation points of the HGD gene in ochronotic arthropathy. The association between AKU and HGD gene mutations is very strong. A study of Dominican Republic reports that seven of the

eight AKU patients are determined to be homozygous for a c.527T→G substitution in exon 6 of the HGD gene, leading to a missense mutation of C120W, which leads to the replacement of a cysteine in position 120 with a tryptophan. The remaining one is homozygous for the G270R (c.975G→A) missense mutation [12]. In addition, a frame shift mutation of c.115delG in exon 3 of HGD gene with the splicing mutation of IVS5+3 A>C, and a donor splice site of the exon 5 have been found as two novel mutations in Chinese Han child with AKU [13]. The two novel mutations in the HGD gene suggests that it could have either recently arise nor

that it may be common but mutation identification of the HGD gene has not yet been extensively developed in this area. However, the functions of these two mutations have not been determined, and further studies are still needed to study their specific roles in the development of AKU.

In conclusion, we reported an AKU patient with two novel mutations at exon 3 and exon 4 of the HGD gene. Findings of these mutations may further expand the spectrum of known HGD gene mutations and provide a basis for better prenatal molecular diagnosis of AKU.

Disclosure of conflict of interest

None.

Address correspondence to: Drs. Feng Yin and Junfeng Cai, Department of Orthopedic Surgery, Shanghai East Hospital of Tongji University, No. 150, Jimo Road, Shanghai 200120, China. Tel: +8602138804518-12025; Fax: +86-021-61569-954; E-mail: fengyinfyyd@163.com

References

- [1] Zatková A, de Bernabé DBV, Poláková H, Zvarík M, Feráková E, Bošák V, Ferák V and de Córdoba SR. High Frequency of Alkaptonuria in

A case report of Alkaptonuria

- Slovakia: Evidence for the Appearance of Multiple Mutations in HGO Involving Different Mutational Hot Spots. *Am J Hum Genet* 2000; 67: 1333-1339.
- [2] Corra T, Zaccala M and Galante M. Ochronotic arthropathy: rapid destructive hip osteoarthritis associated with metabolic disease. *Clin Rheumatol* 1995; 14: 474-477.
 - [3] Sakthivel S, Zatkova A, Nemethova M, Surovy M, Kadasi L and Saravanan MP. Mutation Screening of the HGD Gene Identifies a Novel Alkaptonuria Mutation with Significant Founder Effect and High Prevalence. *Ann Hum Genet* 2014; 78: 155-164.
 - [4] Habbal MZ, Bou-Assi T, Zhu J, Owen R and Chehab FF. First Report of a Deletion Encompassing an Entire Exon in the Homogentisate 1, 2-Dioxygenase Gene Causing Alkaptonuria. *PLoS One* 2014; 9: e106948.
 - [5] Zatkova A. An update on molecular genetics of Alkaptonuria (AKU). *J Inher Metab Dis* 2011; 34: 1127-1136.
 - [6] Yang YJ, Guo JH, Chen WJ, Zhao R, Tang JS, Meng XH, Zhao L, Tu M, He XY and Wu LQ. First report of HGD mutations in a Chinese with alkaptonuria. *Gene* 2013; 518: 467-469.
 - [7] Yin F, Luo S, Cai J, Zhou W, Yuan F, Ma M and Wu Q. Knee Arthroplasty in Alkaptonuric Arthropathy: A Case Report. *J Bone Joint Surg* 2013; 3: e60 61-65.
 - [8] Chenna R, Sugawara H, Koike T, Lopez R, Gibson TJ, Higgins DG and Thompson JD. Multiple sequence alignment with the Clustal series of programs. *Nucleic Acids Res* 2003; 31: 3497-3500.
 - [9] Selvi E, Manganelli S, Mannoni A, Benucci M, Minacci C and Marcolongo R. Chronic ochronotic arthritis: clinical, arthroscopic, and pathologic findings. *J Rheumatol* 2000; 27: 2272-2274.
 - [10] Al-sbou M and Mwafi N. Nine cases of Alkaptonuria in one family in southern Jordan. *Rheumatol Int* 2012; 32: 621-625.
 - [11] Aquaron R. Alkaptonuria: a very rare metabolic disorder. *Indian J Biochem Biophys* 2013; 50: 339-344.
 - [12] De Jorge EG, Lorda I, Gallardo M, Perez B, De Ferran CP, Mendoza H and De Cordoba SR. Alkaptonuria in the Dominican Republic: identification of the founder AKU mutation and further evidence of mutation hot spots in the HGO gene. *J Med Genet* 2002; 39: e40-e40.
 - [13] Li H, Zhang K, Xu Q, Ma L, Lv X and Sun R. Two novel mutations in the homogentisate-1,2-dioxygenase gene identified in Chinese Han Child with Alkaptonuria. *J Pediatr Endocrinol Metab* 2015; 28: 453-6.