

Original Article

Primary huge histiocytic sarcoma of the stomach: a case report and systematic review

Yingchi Yang, Lan Jin, Jun Zhang, Jun Cai, Jie Yin, Zhigang Bai, Kangli Wang, Zhongtao Zhang

Department of General Surgery, Beijing Friendship Hospital, Capital Medical University, Beijing Key Laboratory of Cancer Invasion and Metastasis Research & National Clinical Research Center of Digestive Diseases, Beijing 100050, China

Received December 3, 2015; Accepted May 4, 2016; Epub October 15, 2016; Published October 30, 2016

Abstract: Histiocytic sarcoma (HS) is a very rare lympho hematopoietic malignant neoplasm. Up to date, only a small number of gastric histiocytic sarcoma has been reported. In the present study, we reported a case of a primary huge histiocytic sarcoma of stomach in a youth man of 20 years old. Imaging examinations showed a large mass in the lesser curvature and antrum of the stomach. Then a distal subtotal gastrectomy was performed and a huge tumor of 15 cm × 13 cm was resected and diagnosed as histiocytic sarcoma by histopathologic examination and immunohistochemical analyses. To investigate the clinical characteristics of the rare histiocytic sarcoma of stomach, we also performed a systematic review by searching relevant literature up to Aug 2015 in the databases of PubMed, ISI web of science, CNKI, and Wangfang. Finally, a total of 14 cases including ours were included. The average age of these patients was 57.9 years. They usually presented a long time abdominal pain before diagnosis. Only rare patients survived for a relative long time and the postoperative chemotherapy might be favorable.

Keywords: Histiocytic sarcoma, stomach, case report, literature review

Introduction

Histiocytic sarcoma (HS), also known as “true histiocytic lymphoma”, is a very rare lympho hematopoietic malignant neoplasm occurring mostly in the adult people and the tumor cells present with the morphologic and immunophenotypic features of mature histiocytes [1, 2]. The tumor cells of histiocytic sarcomas are positive for a histiocytic marker (CD68, CD163, or lysozyme), and negative for a Langerhans cell marker (CD1a or langerin). And they are typically negative for specific B-cell (PAX5 or CD19), T-cell (cytoplasmic CD3), and myeloid (myeloperoxidase) markers. HS usually presents in lymph nodes, skin, and a number of other extranodal sites, of which the intestinal tract sites are common [3]. Up to date, only a small number of gastric histiocytic sarcoma has been reported. In the present study, we reported a case of a primary huge histiocytic sarcoma in a youth man and performed an updated systematic review to summary the clinical characteristics of gastric histiocytic sarcoma.

Case report

A 20 years old man presented with intermittent melena for 3 months, weakness and dizziness for 2 months, and intermittent fever for 1 month before admittance to hospital. The patient reduced weight from 135 kg to 90 kg by exercise and diet for a half year before disease occurrence. And a shock occurred after a work-out. Laboratory examination showed that his white cell count was 32.8×10^9 g/L, hemoglobin was 60 g/L, albumin was 25.3 g/L, and occult blood for stool was positive. Bone marrow biopsy revealed an iron-deficiency anemia.

Gastroscopic examination suggested a large mass located in the front wall of the middle part and the lesser curvature of the stomach without obvious ulcer. And the stomach angle was involved partly (**Figure 1A**). Gastric biopsy suggested it might be a mesenchymal tumor. Pain CT scan of the chest showed a slight thickened side wall of the lesser curvature of the stomach and a shadow of low density in gastric antrum. PET/CT scans suggested an irregular increased

Primary huge histiocytic sarcoma of the stomach

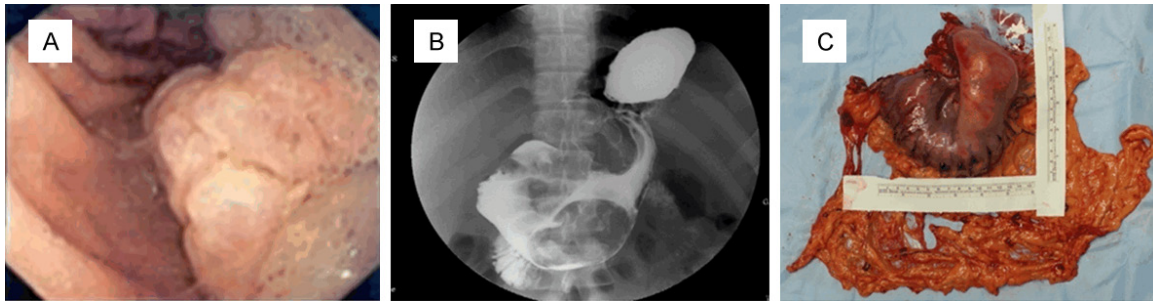


Figure 1. A. Gastroscopic examination revealed a large mass located in the front wall of the middle part and the lesser curvature of the bottom part of the stomach. B. The upper digestive pneumobarium double imaging demonstrated an irregular lesion around the antrum and lesser curvature of the stomach. C. Surgical specimen.

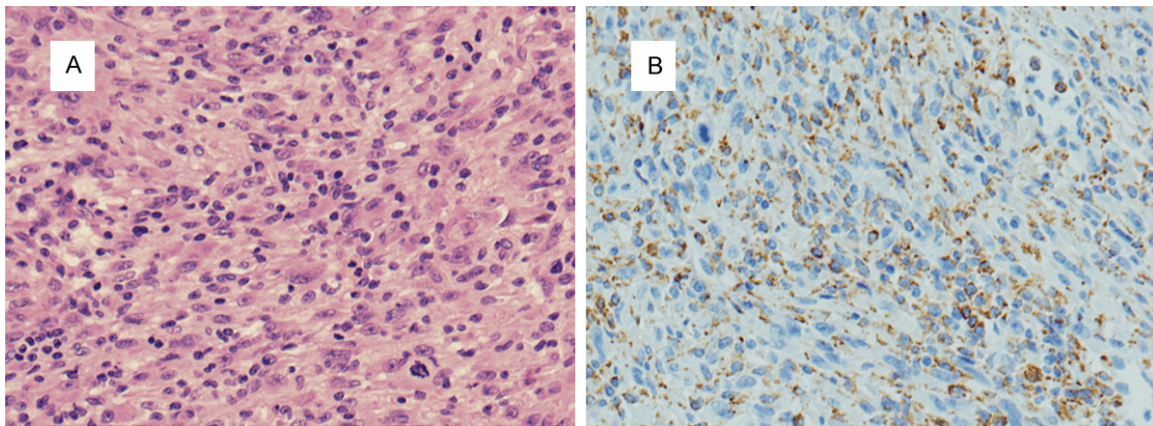


Figure 2. A. Histopathologic examination ($\times 600$). B. Immunohistochemical staining analysis by antibody CD68 ($\times 600$).

metabolism mass near the antrum of stomach with a metabolism increase in the bone marrow of the whole body. The peripheral bone marrow of the patient was accreted. The spleen became bigger and its metabolism increased. Several lymph nodes on the bilateral sides of the neck were enlarged slightly. The upper digestive pneumobarium double imaging demonstrated an irregular lesion around the antrum and lesser curvature of the stomach (**Figure 1B**).

The patient finally received a distal subtotal gastrectomy and a 15 cm \times 13 cm irregularly protruded tumor in the gastric curvature and antrum was found during the operation (**Figure 1C**).

The histopathologic examination of the surgical specimens indicated that there was no tumor metastasis in the perigastric lymph nodes. The tumor cells were monomorphic to pleomorphic with a spindle shape. The cytoplasm of the tumor cells was abundant and eosinophilic

(**Figure 2A**). The immunohistochemical analysis demonstrated that the tumor cells were positive for CD68, CD163, D2-40, CD3, and leukocyte common antigen (LCA), and negative for epithelial cell marker cytokeratin AE1/AE3, langerhans cell marker CD1 α , dendritic cell marker CD35, and other markers including CD20, follicular, smooth muscle actin (SMA), ALK, and S100 (**Figure 2B**). Based on the histological and immunohistochemical examinations, the malignant tumor of the stomach was diagnosed as histiocytic sarcoma.

After surgery, no additional therapy was performed and he suffered from local recurrence and liver metastasis at 6 months postoperation.

Discussion

Histiocytic sarcoma (HS) is a very rare lympho hematopoietic malignant neoplasm [1, 2]. The term “histiocytic sarcoma” was firstly induced

Primary huge histiocytic sarcoma of the stomach

Table 1. Clinical characteristics of previously reported cases of primary gastric histiocytic sarcoma

No.	Reference	Country	Language	Age (yr)	Sex	Presenting symptoms/signs	Therapy before surgery	Tumor location	Tumor size (cm)	Accompanying lesion	Regional LN involvement	Surgical treatment	Therapy after surgery	Local Recurrence	Treatment	Distant metastasis	Treatment	Survival
1	Alvaro et al, 1996	Spain	English	52	Female	Epigastric pain and bloody stools	N	Stomach	12	MALT lymphoma	N	Total gastrectomy	CHOP, 6 cycles	N	NA	N	NA	Alive without disease (18 mo)
2	Homick et al, 2004	USA	English	89	Male	Abdominal pain	N	Stomach and colon	12	N	Y	Gastrectomy	N	N	NA	Splenum, 4 mo	Resection	Died (5 mo)
3	Wang et al, 2009	China	Chinese	64	Female	dull pain in the upper abdomen, nausea, sour regurgitation, and melena for 4 mo	N	Stomach (L&B)	6	N	N	Subtotal gastrectomy	Chemotherapy	N	NA	N	NA	NA
4	Yoo et al, 2010	Korea	Korean	71	Male	Epigastric pain	N	Stomach (F&B)	3, 1 (2 distinct masses)	N	N	Total gastrectomy	N	N	NA	Spleen and intra-abdominal LNs	NA	Alive with disease (9 mo)
5	Tang et al, 2010	China	Chinese	57	Male	abdominal distension and sour regurgitation for one year	PF+CF	Stomach	4, 5 (2 distinct mass)	N	Y	Distal gastrectomy	PF+CF pre and post	N	N	N	NA	Alive remission (8 mo)
6	Cong-yang et al, 2011	China	English	62	Female	5-month pain and discomfort in the epigastric region	N	Stomach (B&A)	20	DLBCL	Y	Total gastrectomy	N	N	NA	N	NA	Died (7 mo)
7	Sunder-singh et al, 2012	India	English	28	Female	abdomen pain for 6 mo and melena for 3 mo	N	Stomach (A&P) and jejunum	9	N	Y	Distal gastrectomy and jejunal resection	CHOP, 4 cycles	N	NA	N	NA	Alive without disease (3 yr)
8	Feng et al, 2012	China	Chinese	75	Male	6 mo abdominal pain, stomach upset, and obvious weight loss	N	Stomach (L)	5	N	N	Subtotal gastrectomy	N	Y	NA	N	NA	Died because of recurrence (13 mo)
9	Guan et al, 2012	China	Chinese	74	Male	repeated dry mouth and polydipsia for ten years	N	Stomach (G) and pancreatic tail	1.5	N	Y	Total gastrectomy	N	Y	supportive therapy	N	NA	Died because of recurrence (13 mo)
10	Shen et al, 2013	China	English	52	Female	1-month progressive difficulty in feeding; 3-day dull pain in perigastric region	N	Stomach (F)	7	N	N	Total gastrectomy	Chemotherapy, 3 cycle	N	NA	N	NA	Alive without disease (4 mo)
11	Lee et al, 2014	Korea	English	45	Female	40-day epigastric pain	N	Stomach (A&P)	7.5	N	Y	Distal gastrectomy	N	N	NA	N	NA	Alive with residual disease (1 mo)

Primary huge histiocytic sarcoma of the stomach

12	Pakra- van et al, 2014	USA	English	46	Male	6 mo progressive abdominal pain, nausea, vomiting, and dysphagia; night sweats, palpitations, myalgias, and weight loss	N	Gastro- esopha- geal junction	NA	NA	NA	NA	NA	NA	NA	NA	NA	NA
13	Hanao- ka et al, 2015	Japan	English	75	Male	NA	N	Stom- ach, liver, and pancre- atic tail	NA	N	Y	Total gastrectomy and resec- tion of liver, pancreas and spleen	NA	N	NA	N	NA	Alive with- out disease (4 yr)
14	Current case	China	English	20	Male	intermittent melena for 3 months, weak and dizziness for 2 months, and intermittent fever for 1 month	N	Stomach (A&G)	15	N	N	Distal subtotal gastrectomy	N	N	NA	N	NA	Alive with- out disease (6 mo)

by Mathe in 1970 and now the WHO defines HS as a collection of malignant proliferation of cells that shows the morphologic and immunophenotypic features of mature tissue histiocytes [4]. So far, only a small number of histiocytic sarcoma in stomach has been reported. In the present study, we reported a case of a primary huge histiocytic sarcoma in a youth man. It was a 20 years old man presented with intermittent melena, weak, dizziness, and intermittent fever for a long time. Imaging examinations showed a large mass in the lesser curvature and antrum of the stomach. Then a distal subtotal gastrectomy was performed and a huge tumor of 15 cm × 13 cm was resected and the tumor was diagnosed as histiocytic sarcoma by histological and immunohistochemical analyses. And the patient suffered from local recurrence and liver metastasis at 6 months postoperation.

To investigate the clinical characteristics of the rare histiocytic sarcoma of stomach, we performed a systematic search and review up to Aug 2015 in the databases of PubMed, ISI web of science, CNKI, and Wangfang. The search terms were “stomach OR gastric” and “histiocytic sarcoma OR true histiocytic lymphoma”. Finally, 13 related articles containing 13 cases were included and the articles were published from 1996 to 2015 [3, 5-16]. Of which, one article published in Korean language was also included because its critical data could be obtained from Lee *et al*'s report and its abstract [7, 14]. The clinical characteristics of a total of 14 histiocytic sarcoma cases occurred in stomach including ours were summarized in the **Table 1**. Out of the 14 patients, two were American [3, 15], seven were Chinese [6, 8, 9, 11-13], two were Korean [7, 14], one was Spain [5], one was Indian [10], and one was Japanese [16]. Eight patients were male and six were female. Their age ranged from 20 to 89 years with a mean value of 57.9. Twelve patients were over 45 years indicating gastric histiocytic sarcoma mostly occurred in middle age or elder. Nine patients presented a long time abdominal pain for 40 days to one year. The other main symptoms were melena (3 cases), nausea (2 cases), sour regurgitation (2 cases), and weight loss (2 cases). Only one patient received PF+CF chemotherapy before surgery [8]. And one patient died rapidly after diagnosis [15]. The tumors were involved in multiple sites (colon,

jejunum, esophageal, pancreas, and liver) for five cases [3, 10, 12, 15, 16] and the rest cases presented with only gastric mass. Two distinct mass were found in two patients, respectively [7, 8]. The tumor size ranged from 1.5 to 20 cm and the tumor size of 9 out of 12 cases was over 5 cm. 13 of 14 patient underwent gastrectomy except one who died after diagnosis rapidly. Regional lymph node metastases were found in 10 of 13 patients during the operation. 4 of 13 patients were treated with chemotherapy after surgery. 5 of 13 patients had local recurrence or distant metastasis during the follow up, indicating local recurrence/distant metastasis should be drew more attention at the same time. 4 of 12 patients died due to the disease during the follow up with a survival time from 7 to 13 months. 8 of 12 patients remained alive at the last follow-up time whereas the follow up periods were relative short and only two cases showed a relative long survival (3 years and 4 years, respectively) [10, 16]. Histiocytic sarcoma is aggressive and usually shows poor response to chemotherapy [3]. However, after reviewing the previously reports, we found that two patients survived for a relative long time (18 months and 3 years) after surgery and postoperative chemotherapy [5, 10]. It suggested that postoperative chemotherapy might be helpful to prolong the patient survival.

Conclusions

In summary, we reported a primary huge gastric histiocytic sarcoma in a Chinese young man and performed a systematic review of the previously reported cases of histiocytic sarcoma of stomach. The average age of these patients was 57.9 years. They usually presented a long time abdominal pain before diagnosis. Only rare patients survived for a relative long time and the postoperative chemotherapy might be favorable.

Disclosure of conflict of interest

None.

Authors' contribution

Yang Y. and Zhang Z.: study concept and design; Zhang J., Cai J., and Yin J.: acquisition of data; Yang Y., Zhang Z., and Wang K.: drafting of the manuscript.

Address correspondence to: Zhongtao Zhang, Department of General Surgery, Beijing Friendship Hospital, Capital Medical University, Beijing Key Laboratory of Cancer Invasion and Metastasis Research & National Clinical Research Center of Digestive Diseases, No. 95, Yong'an Road, Xi-Cheng District, Beijing 100050, China. Tel: +86-15810152032; E-mail: zhangzhty@163.com

References

- [1] Sethi S, Wrona C, Eschberger K, Lobbins P, Cai X and Murphy TF. Inflammatory profile of new bacterial strain exacerbations of chronic obstructive pulmonary disease. *Am J Respir Crit Care Med* 2008; 177: 491-497.
- [2] Grogan T, Pileri S, Chan J, Weiss L and Fletcher C. Histiocytic sarcoma. In: Swerdlow SH, Campo E, Harris NL, Jaffe ES, Pileri SA, Stain H, editors. *WHO Classification of Tumours of Haematopoietic and Lymphoid Tissues*. Lyon: IARC; 2008.
- [3] Hornick JL, Jaffe ES and Fletcher CD. Extranodal histiocytic sarcoma: clinicopathologic analysis of 14 cases of a rare epithelioid malignancy. *Am J Surg Pathol* 2004; 28: 1133-1144.
- [4] Vos JA, Abbondanzo SL, Barekman CL, Andriko JW, Miettinen M and Aguilera NS. Histiocytic sarcoma: a study of five cases including the histiocyte marker CD163. *Mod Pathol* 2005; 18: 693-704.
- [5] Alvaro T, Bosch R, Salvado MT and Piris MA. True histiocytic lymphoma of the stomach associated with low-grade B-cell mucosa-associated lymphoid tissue (MALT)-type lymphoma. *Am J Surg Pathol* 1996; 20: 1406-1411.
- [6] Wang C and Qi X. Primary gastric histiocytic sarcoma: a case report. *J Diag Pathol* 2009; 16: 134-135.
- [7] Yoo KD, Han DS, Chung SM, Kim SM, Bae JH, Eun CS, Paik SS and Oh YH. [A case of extranodal histiocytic sarcoma of stomach mimicking gastric adenocarcinoma]. *Korean J Gastroenterol* 2010; 55: 127-132.
- [8] Tang X, Xu J, Wang Y and Ye M. Clinical pathological analysis of two cases of histiocytic sarcoma. *J Clin Exp Pathol* 2010; 26: 373-375.
- [9] Congyang L, Xinggui W, Hao L and Weihua H. Synchronous histiocytic sarcoma and diffuse large B cell lymphoma involving the stomach: a case report and review of the literature. *Int J Hematol* 2011; 93: 247-252.
- [10] Sundersingh S, Majhi U, Seshadri RA and Tenali GS. Multifocal histiocytic sarcoma of the gastrointestinal tract. *Indian J Pathol Microbiol* 2012; 55: 233-235.
- [11] Feng T, He MX, Gu WY, Bai CG, Ma DL, Zheng JM and Zhu MH. [Histiocytic sarcoma of stomach: report of a case]. *Zhonghua Bing Li Xue Za Zhi* 2012; 41: 130-131.
- [12] Guan ZY, Feng YF and Hou YY. [Primary signet-ring cell-like histiocytic sarcoma arising in stomach: report of a case]. *Zhonghua Bing Li Xue Za Zhi* 2012; 41: 772-773.
- [13] Shen XZ, Liu F, Ni RJ and Wang BY. Primary histiocytic sarcoma of the stomach: a case report with imaging findings. *World J Gastroenterol* 2013; 19: 422-425.
- [14] Lee D, Kim YB, Chung SH, Lee SR, Byun CS, Han SU and Han JH. Primary gastric histiocytic sarcoma reminiscent of inflammatory pseudotumor: a case report with review of the literature. *Korean J Pathol* 2014; 48: 258-262.
- [15] Pakravan A, Bhatia R, Oshima K, Chen G, Fesler M, Prather C and Taylor JR. Histiocytic sarcoma: the first reported case of primary esophageal involvement. *Am J Gastroenterol* 2014; 109: 291-292.
- [16] Hanaoka T, Jingu K, Tochigi T, Hoshino I, Uematsu T and Matsubara H. A case of g-csf-producing histiocytic sarcoma of the stomach. *Int Surg* 2015; 100: 568-573.