

## Original Article

# Combined rehabilitation with scalp cluster acupuncture and constraint-induced movement therapy significantly improved functional recovery in patients with acute ischemic stroke

Yancheng Song, Liqing Kang, Honghuan Dong, Yong Chen

*Cangzhou Central Hospital, 16 West Xinhua Road, Yunhe District, Cangzhou 061001, Hebei, China*

Received March 29, 2016; Accepted August 19, 2016; Epub October 15, 2016; Published October 30, 2016

**Abstract:** Background and purpose: Scalp cluster acupuncture and constraint-induced movement therapy (CIMT) have been shown to improve functional recovery in patients with acute stroke. However, stroke rehabilitation usually requires a multidisciplinary care which combining different therapeutic approaches. The combined effects of scalp cluster acupuncture and CIMT were unknown. Methods: A prospective randomized clinical trial was performed to compare the functional recovery in acute ischemic stroke patients received either combined therapy of scalp cluster acupuncture and CIMT (experimental group) or body acupuncture and traditional rehabilitation therapy (control group). Patients with first time unilateral cerebral infarction in internal carotid artery system, onset within 3 days, and muscle strength of the affected upper limb less than grade III without obvious sensory disturbance and speech disorder were enrolled. Patients' functional recovery, as evaluated by Fugl-Meyer assessment (FMA) scale and blood oxygenation level dependent functional magnetic resonance imaging (BOLD-fMRI), was recorded and compared after two weeks' interventions. Results: FMA scale and BOLD-fMRI showed statistically significant improvements after intervention rehabilitations in both groups. This improvement was more prominent in the experimental group. Conclusions: A novel therapy which combined scalp cluster acupuncture and CIMT could significantly improve functional recovery in patients with acute ischemic stroke.

**Keywords:** Stroke, rehabilitation, scalp cluster acupuncture, constrained-induced movement therapy, magnetic resonance imaging

## Introduction

Global burden of stroke has increased significantly in the past two decades [1]. Functional disability caused by stroke has become a major social, medical, and economic concern [2]. Rehabilitation after an acute stroke has shown to improve patients' functionalities and enhance their quality of life. Research on rehabilitation interventions to maximize the functional recovery is always an important part in stroke study.

Different therapeutic interventions have been proposed for stroke rehabilitation and recovery. Constraint-induced movement therapy (CIMT), by increasing the use of the affected upper extremity, has been shown to improve motor

outcomes after stroke [3]. Acupuncture, as an alternative and complementary therapy for stroke patients, has also been shown to facilitate stroke recovery [4, 5]. Compared to body acupuncture, scalp cluster acupuncture could enhance cerebral blood reperfusion and improve aphasia [6]. Stroke rehabilitation usually requires a multidisciplinary care which combining different therapeutic interventions [7]. The effect of combination therapy with acupuncture and CIMT was rarely reported.

In the current manuscript, we reported our pilot exploratory study to investigate functional recovery in acute ischemic stroke patients undergoing a novel therapy which combined CIMT and scalp cluster acupuncture. We compared its effects with conventional body acu-

puncture and rehabilitation therapy. Our results would lay the foundation for a future multi-center study to investigate the long term effects of this novel combination therapy, with the ultimate goal to improve the care for stroke patient.

## Materials and methods

### *Study design*

Current study was a prospective randomized clinical trial which was conducted between May and December 2013 in an urban hospital in China. The study protocol was approved by the hospital ethics committee. All study participants signed informed consent.

The inclusion criteria were: 1) first attack of unilateral cerebral infarction in internal carotid artery system confirmed by diffusion weighted magnetic resonance imaging without lesions in contralateral somatosensory motor cortex area; 2) within 3 days of disease onset; 3) muscle strength of the affected upper limb was less than grade III without obvious sensory disturbance and speech disorder; 4) consciousness, cooperative, and without obvious joint or mirror movement; 5) right-handed, and not engaged in the music playing or keyboard typing before. Exclusion criteria were: 1), rapid progression of stroke symptoms; 2), hemorrhage change or new lesions in brain imaging during study period; 3), treatment involves intracranial intravascular stent placement.

### *Study protocol*

Patients were approached and screened according to above mentioned selection criteria. Eligible patients were randomized into two study groups, experimental group and control group.

Patients in the experimental group received CIMT and scalp cluster acupuncture as soon as possible once they were enrolled into the study. Methods for CIMT and scalp cluster acupuncture were described before [6, 8]. Scalp cluster acupuncture was performed at parietal and anterior parietal regions according to the Yu's areal division, and 3-5 needles were used for each region. Needles were inserted into 3 cm-5 cm under the epicranial aponeurosis and then twisted one minute at a speed of 200 times/min. The needles were twisted 2-3 times and retained for about 6 hours. CIMT was per-

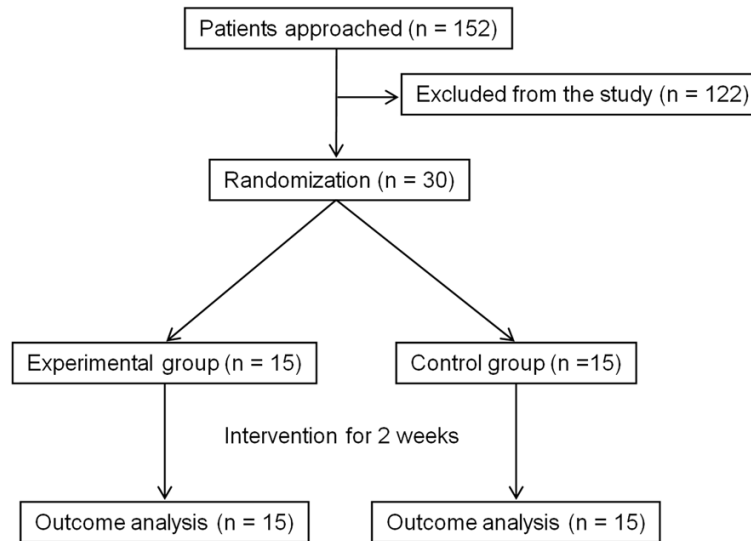
formed for 5-6 hours daily and 6 days a week. Immobilization of the non-paretic upper limb was ensured by fixating the arm to the side of the body with a sling and a splint. The paretic upper limb received directional behavior training according to different degree of functional damage, and the training was set to just more than patient's capacity. The difficulty of training increased according to patients' recovery after intensive training. The treatment lasted for two weeks.

Patients in the control group received traditional rehabilitative treatment and body acupuncture after they were enrolled in the study [9, 10]. The treatment lasted for two weeks. Body acupuncture performed once a day at contralateral Jianliao (SJ 14), Quchi (LI 11), Shousanli (LI 10), Waiguan (SJ 5), Hegu (LI 4), Laogong (P 8), Zhongzhu (Sj 30), Biguan (St 31), Futu (St 32), Liangqiu (St 34), Zusanli (St 36), Yanglingquan (GB 34), Sanyinjiao (Sp 6), Taixi (K 3), Jiexi (St 41), and Taichong (Liv 3). Needles were inserted into the skin and manipulated until a de-qi sensation was obtained, and then was retained for 30 min. Rehabilitative treatment included a combination of muscle tonus decompression, strength enhancement and balance training, and was performed once or twice a day, no less than 20 min one time.

### *Outcome measurements*

The primary outcome was the upper extremity motor functions as evaluated with the Fugl-Meyer assessment (FMA) scale. The secondary outcome was brain activity and blood flow as detected by blood oxygenation level dependent functional magnetic resonance imaging (BOLD-fMRI). Both outcomes were measurements before and after rehabilitation interventions.

For BOLD-fMRI, the experiments were arranged in block design. Dummy scan was carried out before the experiment. After 24 seconds of rest, patients received a block of passive digital opposition in the paralytic hand with a frequency of 1 Hz (once per sec) for 20 second, and then a rest block for 20 second. This procedure was repeated 6 times, and the whole experiment lasted for about 264 second. Patients were asked to keep the eyes closed and maintain consciousness with the body as relax as possible during the study. All MRI data were acquired on a 3.0T MR scanner, Structural



**Figure 1.** CONSORT diagram.

images were obtained using a T1-weighted 3D gradient echo sequence (3D BRAVO, TR 8.2 ms, TE 3.2 ms, slice thickness 1.2 mm, 132 axial slices without gap, FOV 240 mm×240 mm, in-plane matrix 256×256). BOLD-fMRI data was acquired using a GE-EPI sequence (TR 2000 ms, TE 35 ms, slice thickness 4 mm, 36 axial slices without gap, FOV 240 mm×240 mm, in-plane matrix 64×64). The fMRI data were analyzed with Statistical Parametric Mapping (SPM) software (SPM5, <http://www.fil.ion.ucl.ac.uk/spm/>).

In order to identify the region of interest in BOLD-fMRI, fifteen healthy adult volunteers were chosen to perform the same passive digital opposition. Their activated brain areas were recorded and compared to stroke patients. Altogether, bilateral CER, PMA, SMA, PPC, and PCC were evaluated in both stroke patients and healthy volunteers. It was found that contralateral SMC (sensorimotor cortex) had the most pronounced activation after passive digital opposition in both healthy volunteers and stroke patients, which was consistent with the previous studies [11, 12]. Thus, the contralateral SMC was used as the region of interest in the current BOLD-fMRI study.

## Statistical analysis

Data were presented as mean ± standard deviation or median, interquartile range. Either student t-test or Mann-Whitney-U test was used to

compare the outcome measurements before and after treatment, as well as between two study groups. SPSS 16.0 was used and  $P < 0.05$  was considered statistically significantly different.

## Results

Altogether, 30 patients were enrolled into the study, with 15 of them in each study group. The CONSORT diagram is shown in **Figure 1**. No patients dropped out the study. Their baseline characteristics were listed in **Table 1**. There were no statistically significant differences between two groups.

Before treatment interventions, there was no statistically significant difference between FMA scales and BOLD-fMRI activated volume and intensity in contralateral SMC between experimental and control groups. After two weeks' intervention, both experimental group and control group had statistically significant improved FMA scales and BOLD-fMRI results. The improvement of FMA scale and BOLD-fMRI activated volume and intensity was statistically more prominent in the experimental group when compared to the control group, as is shown in **Figure 2**. Patients with more significant improvement in FMA scales had more improved SMC activated volume and intensity.

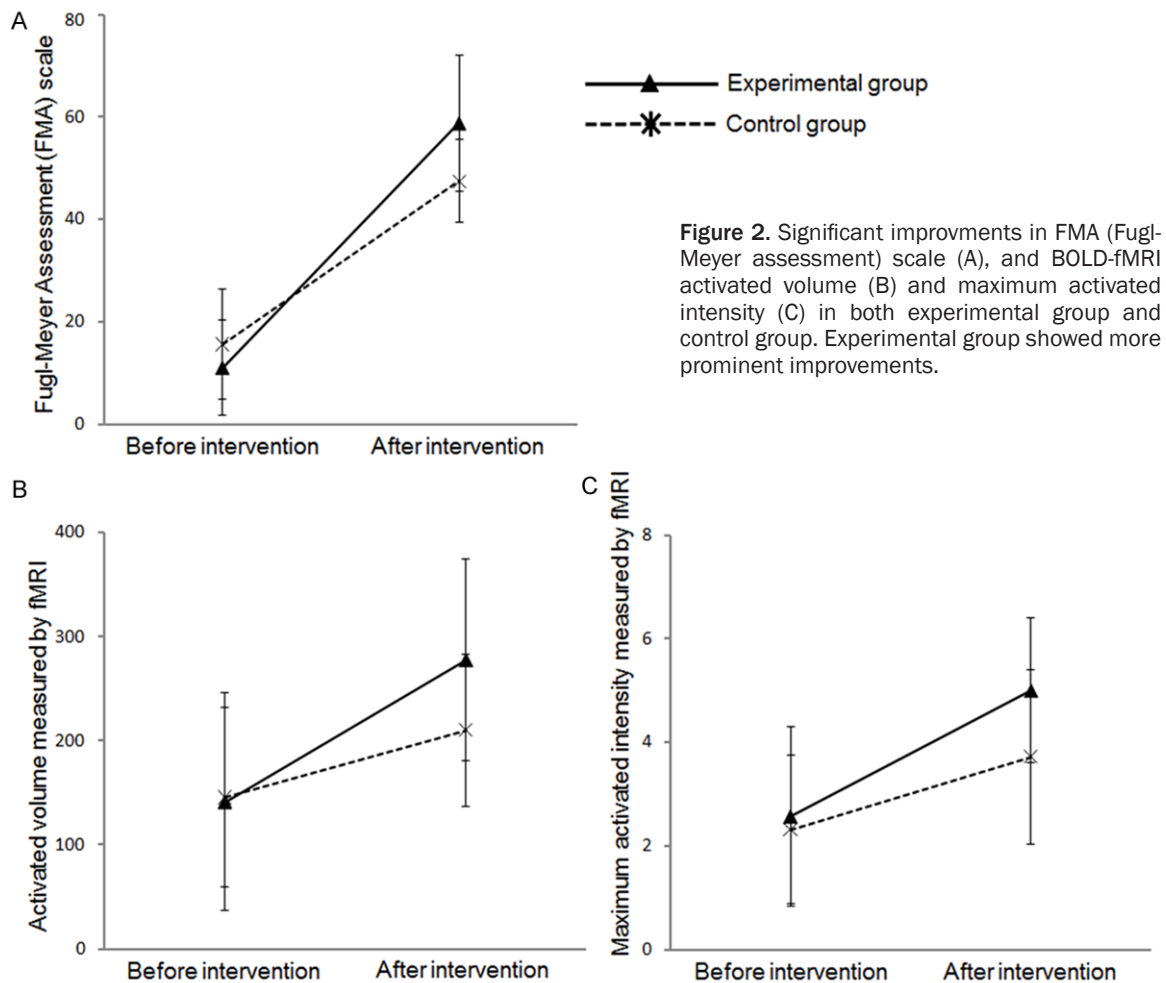
## Discussion

FMA scale was commonly used to evaluate motor recovery after stroke. BOLD-fMRI detects brain blood flow which correlates with brain activities. It was also used to access the effects of rehabilitation after stroke. We selected SMC as the region of interest in the current study, since SMC showed most pronounced activation after passive digital opposition in both healthy volunteers and stroke patients. We have observed motor improvement in both FMA scales and SMC activities by BOLD-fMRI in both groups of patients after two weeks' rehabilitations. Patients with more significant improvement in FMA scales had more improved activities in SMC activities. Patients received the novel combination rehabilitation interventions, which

**Table 1.** Baseline characteristics between two groups†

	Experimental group	Control group
Age, year, mean $\pm$ SD	53.9 $\pm$ 11.1	54.2 $\pm$ 12.3
Time from symptom onsets to rehabilitation, day, mean $\pm$ SD	1.7 $\pm$ 0.6	2.1 $\pm$ 0.8
Fugl-Meyer assessment (FMA) scale	11.0 $\pm$ 9.3	15.6 $\pm$ 10.7
BOLD-fMRI		
Activated volume	141.3 $\pm$ 104.6	145.6 $\pm$ 85.8
Maximum activated intensity	2.57 $\pm$ 1.74	2.32 $\pm$ 1.43

† No statistically significant differences between two groups.



combined CIMT and scalp cluster acupuncture, had better improvements compared to patients received traditional treatments.

The novel rehabilitation interventions combined CIMT with scalp cluster acupuncture. CIMT, which enforces rehabilitative training in the paretic limb by restraining the non-paretic limb, has been shown to improve motor func-

tion in patients with stroke. It has been used widely and its effects were significantly better than traditional rehabilitation methods. It has been reported that acupuncture could reduce platelet aggregation and viscosity of erythrocyte, as well as promote the repair and regeneration of blood vessels to increase cerebral blood flow [13, 14]. Compared to body acupuncture, scalp acupuncture could activate

somatosensory association cortex, postcentral gyrus, and parietal lobe more significantly [15]. Scalp acupuncture can also facilitate the activation of neural stem cells in the subependymal area, and promote the proliferation, migration, and the replacement of the missing neurons [16]. Animal studies also showed that scalp acupuncture could alleviate the damages from the reperfusion after cerebral ischemia by lowering Caspase-3 expression, reducing neuron apoptosis, and decreasing matrix metalloproteinases-9 synthesis and secretion [17, 18]. It is hypothesized that scalp cluster acupuncture can make acupoints on the top of the head to form a three-dimensional needle field, and with strong needle sensation exerted on these acupoints, to release the disturbance of hemodynamics in the acute phase of cerebral infarction, promote the opening of the collateral circulation, thus restore blood flow to ischemic penumbra [19].

Previous studies have shown significant differences in brain functions and SMC activation between left and right handedness [20, 21]. In the current pilot study, we only tested right-handed patients in order to avoid the effects of the differences caused by handedness on the experimental results [22]. By comparing to healthy volunteer, we found that contralateral SMC had the most pronounced activation after passive digital opposition. We selected contralateral SMC as our region of interest in the current BOLD-fMRI study. In the future study, whether the novel rehabilitation improves motor function in left handed stroke patients and whether there is difference between right and left handed patients need to be investigated.

Limitations of the current study included single center research, small sample size, and short interventional period. In this pilot study, we studied compare the effects of combination therapy with traditional therapy, but not with these two therapies individually. In the future multi-center study, we will enroll large number of patients to see if the combination therapy is better than individual therapy.

In conclusion, our current pilot study has shown that a novel rehabilitation intervention which combined CIMT and scalp cluster acupuncture could significantly improve functional recovery

in patients with acute ischemic stroke. Future multi-center study is warranted.

## Disclosure of conflict of interest

None.

**Address correspondence to:** Dr. Liqing Kang, Cangzhou Central Hospital, 16 West Xinhua Road, Yunhe District, Cangzhou 061001, Hebei, China. Tel: 011-86-13333367921; E-mail: 1513203473@qq.com

## References

- [1] Feigin VL, Forouzanfar MH, Krishnamurthi R, Mensah GA, Connor M, Bennett DA, Moran AE, Sacco RL, Anderson L, Truelsen T, O'Donnell M, Venketasubramanian N, Barker-Collo S, Lawes CM, Wang W, Shinohara Y, Witt E, Ezzati M, Naghavi M, Murray C; Global Burden of Diseases, Injuries, and Risk Factors Study 2010 (GBD 2010) and the GBD Stroke Experts Group. Global and regional burden of stroke during 1990-2010: findings from the Global Burden of Disease Study 2010. *Lancet* 2014; 383: 245-254.
- [2] Kim AS, Johnston SC. Temporal and geographic trends in the global stroke epidemic. *Stroke* 2013; 44: S123-S125.
- [3] Reiss AP, Wolf SL, Hammel EA, McLeod EL, Williams EA. Constraint-Induced Movement Therapy (CIMT): Current Perspectives and Future Directions. *Stroke Res Treat* 2012; 2012: 159391.
- [4] Shiflett SC. Does acupuncture work for stroke rehabilitation: what do recent clinical trials really show? *Top Stroke Rehabil* 2007; 14: 40-58.
- [5] Wu P, Mills E, Moher D, Seely D. Acupuncture in poststroke rehabilitation: a systematic review and meta-analysis of randomized trials. *Stroke* 2010; 41: e171-e179.
- [6] Li H, Hou ZW, Bai YL, Gu SZ. [Comparative study on curative effects of stroke treated with acupuncture by NIRS]. *Zhongguo Zhen Jiu* 2011; 31: 998-1002.
- [7] Brewer L, Horgan F, Hickey A, Williams D. Stroke rehabilitation: recent advances and future therapies. *QJM* 2013; 106: 11-25.
- [8] Stark A, Meiner Z, Lefkowitz R, Levin N. Plasticity in cortical motor upper-limb representation following stroke and rehabilitation: two longitudinal multi-joint fMRI case-studies. *Brain Topogr* 2012; 25: 205-219.
- [9] Xing YL, Guan Y, Wei TH. Optimization of acupuncture and rehabilitation strategy in patients with hemiplegia from ischemic stroke. *J Clin Acupunct and Moxibust* 2008; 24: 10-12.

- [10] Li J. Clinical observation of acupuncture with rehabilitation training in 35 patients with stroke sequelae. *Chin J Integr Med on Cardio-/Cerebrovasc Dis* 2012; 10: 697-698.
- [11] Mattay VS, Callicott JH, Bertolino A, Santha AK, Van Horn JD, Tallent KA, Frank JA, Weinberger DR. Hemispheric control of motor function: a whole brain echo planar fMRI study. *Psychiatry Res* 1998; 83: 7-22.
- [12] Farrell DF, Burbank N, Lettich E, Ojemann GA. Individual variation in human motor-sensory (rolandic) cortex. *J Clin Neurophysiol* 2007; 24: 286-293.
- [13] Jiang H, Wang M, Guo J, Li Z. The midnight-noon ebb-flow point selection for 30 cases of acute ischemic cerebrovascular diseases. *J Tradit Chin Med* 2008; 28: 193-197.
- [14] Hsieh CL, Chang QY, Lin IH, Lin JG, Liu CH, Tang NY, Lane HY. The study of electroacupuncture on cerebral blood flow in rats with and without cerebral ischemia. *Am J Chin Med* 2006; 34: 351-361.
- [15] Park SU, Shin AS, Jahng GH, Moon SK, Park JM. Effects of scalp acupuncture versus upper and lower limb acupuncture on signal activation of blood oxygen level dependent (BOLD) fMRI of the brain and somatosensory cortex. *J Altern Complement Med* 2009; 15: 1193-1200.
- [16] Huang Y, Li Y, Chen J, Zhou H, Tan S. Electrical Stimulation Elicits Neural Stem Cells Activation: New Perspectives in CNS Repair. *Front Hum Neurosci* 2015; 9: 586.
- [17] Qi YC, Xiao XJ, Duan RS, Yue YH, Zhang XL, Li JT, Li YZ. Effect of acupuncture on inflammatory cytokines expression of spastic cerebral palsy rats. *Asian Pac J Trop Med* 2014; 7: 492-495.
- [18] Xu H, Zhang Y, Sun H, Chen S, Wang F. Effects of acupuncture at GV20 and ST36 on the expression of matrix metalloproteinase 2, aquaporin 4, and aquaporin 9 in rats subjected to cerebral ischemia/reperfusion injury. *PLoS One* 2014; 9: e97488.
- [19] Fang Z, Ning J, Xiong C, Shulin Y. Effects of Electroacupuncture at Head Points on the Function of Cerebral Motor Areas in Stroke Patients: A PET Study. *Evid Based Complement Alternat Med* 2012; 2012: 902413.
- [20] Solodkin A, Hlustik P, Noll DC, Small SL. Lateralization of motor circuits and handedness during finger movements. *Eur J Neurol* 2001; 8: 425-434.
- [21] Herve PY, Mazoyer B, Crivello F, Perchey G, Tzourio-Mazoyer N. Finger tapping, handedness and grey matter amount in the Rolando's genu area. *Neuroimage* 2005; 25: 1133-1145.
- [22] Pulman J, Buckley E. Assessing the efficacy of different upper limb hemiparesis interventions on improving health-related quality of life in stroke patients: a systematic review. *Top Stroke Rehabil* 2013; 20: 171-188.