

Original Article

A retrospective analysis of 38 carotid cavernous fistula patients treated with balloon-assisted endovascular fistula embolization through simultaneous transarterial and transvenous approaches

Bin Du^{1*}, Meng Zhang^{2*}, Yunyan Wang^{2*}, Qingmin Li³, Fangshu Chen⁴

¹Department of Neurosurgery, Jinan Central Hospital Affiliated to Shandong University, Shangdong, China;

²Department of Neurosurgery, Qilu Hospital, Shandong University, Shangdong, China; ³Department of Neurosurgery, The Central Hospital of Taian, Taian 271000, China; ⁴Department of Neurosurgery, The People's Hospital of Zhangqiu, Jinan 250200, China. *Equal contributors.

Received June 7, 2016; Accepted August 4, 2016; Epub October 15, 2016; Published October 30, 2016

Abstract: Objective: Routine embolization is not completely effective for patients with complicated traumatic carotid cavernous fistula. The aim of this study is to evaluate the clinical outcomes and factors affecting the complications in balloon-assisted Onyx 18 embolization implemented through transarterial and transvenous approaches. Methods: 38 patients who were not suitable for detachable balloon embolization or underwent the embolization but were not cured or relapsed were selected for the study. They were treated by injecting Onyx 18 through two micro-catheters inserted cavernous sinus through transarterial and transvenous approaches. Results: Angiograms taken immediately after the embolization showed that the arteriovenous fistulas disappeared completely in all the patients. Internal carotid artery occlusion was observed in one patient due to Onyx diffusion into the carotid artery. In another patient, small amount of Onyx was washed to the M4 segment of middle cerebral artery by the blood. In other two patients, the glue floated on the arterial wall of internal carotid. After surgery, five (23.7%) patients showed new symptoms of oculomotor nerve damage. During the follow-up period, 77.3% of the patients had normal oculomotor nerve function, and the recovery speed was found not related to the injection dose or oculomotor nerve injury prior to the operation. Conclusion: Simultaneous transarterial and transvenous approach is effective and safe for TCCF patients who are not suitable for detachable balloon embolization or are difficult to treat with the embolization. During the surgical procedure, micro-catheters should be precisely positioned with minimal injection of Onyx 18 to reduce complications.

Keywords: Traumatic carotid cavernous fistula, simultaneous transarterial and transvenous approaches, embolization, oculomotor nerve

Introduction

Carotid cavernous fistula is an abnormal arteriovenous communication formed between carotid artery or its branches and cavernous sinus due to external factors or spontaneously, leading to steal and high venous pressure, and a series of clinical symptoms [1-3]. The cause of fistula is etiologically spontaneous and mostly traumatic (75%). The preferred treatment for traumatic carotid cavernous fistula (TCCF) is to embolize the fistula with detachable balloon [4]. However, most TCCF patients are associated with skull base fracture, the detachable bal-

loon embolization at their acute stage may cause fracture displacement or balloon rupture due to being punctured by fracture fragments. Therefore, the therapy has high risk of intraoperative bleeding and post-operative recurrence. If the tear on the internal carotid artery is too small, or is located in the lower segment of cavernous sinus, the balloon might not be able to enter the fistula point to complete the embolization. Transvenous embolization has been the preferred method for CCF using Onyx [5]. Often, one operation can complete the embolization with less long-term complications. However, when used for TCCF. It often causes cavernous

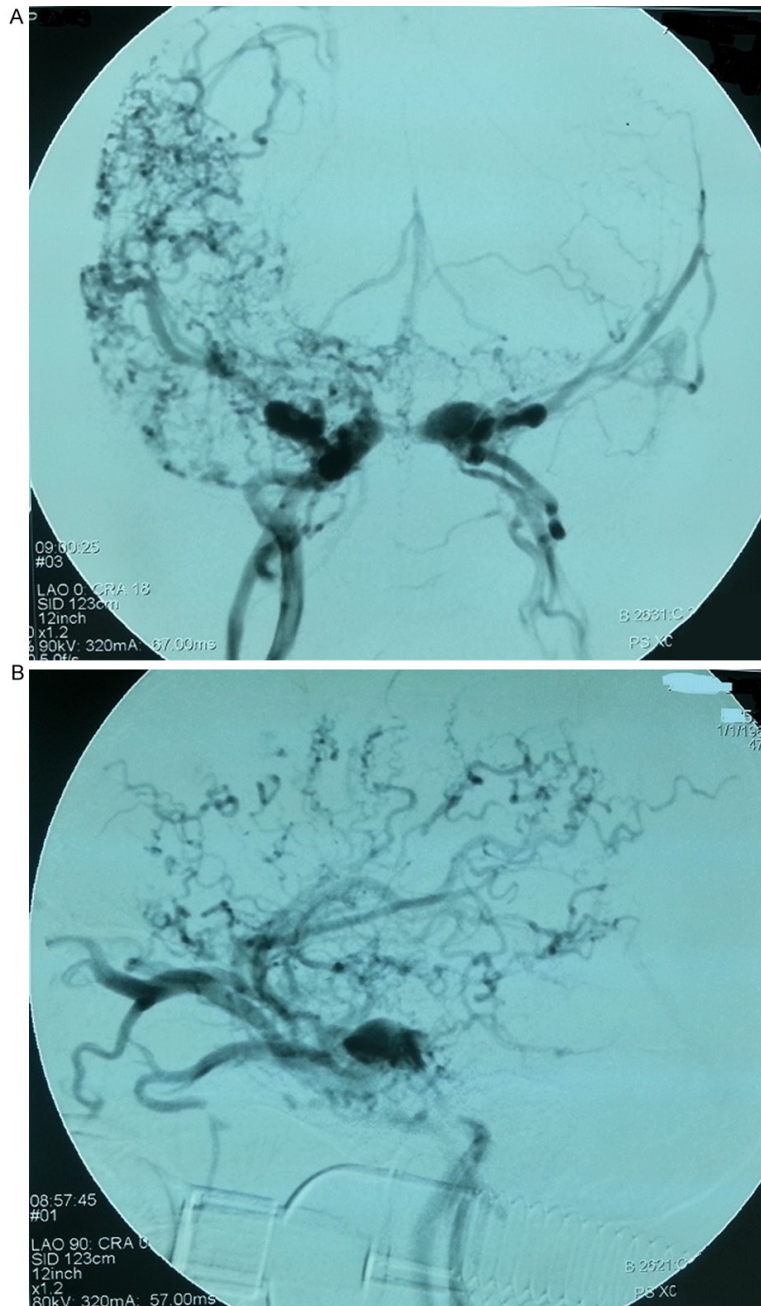


Figure 1. Traumatic carotid cavernous fistula with delayed intracranial hemorrhage showing extensive reverse drainage in cortical veins. A. Arterial phase image of bilateral cavernous sinus; B. Image of eye vein and inferior petrosal sinus with slight enhancement of intracranial artery.

sinus syndromes, due to high volume of the steal blood in TCCF with remarkable expansion of cavernous sinus and consequently high dose of Onyx. During injection, Onyx is easy to flow back to the internal carotid artery leading to its occlusion. Sometimes the Onyx is difficult to diffuse into all venous pathways, resulting in

declined curative rate. On the hand, when Onyx is injected transarterially to the cavernous sinus using micro-catheters, the carotid artery is blocked by the balloon to prevent the glue from flowing back to the artery with small amount of the glue. However, since the catheter tip was inserted shallowly into fistula, the glue may flow back into internal carotid artery when injected too fast or too hard, causing the artery to occlude. This method is also considerably risky when retrieving the micro-catheters. Therefore, neither transvenous nor transarterial embolization is ideal. To address this issue, our hospital has been investigating simultaneous transvenous and transarterial approach to treat complicated TCCF patients since January, 2010. The outcomes are relatively satisfactory. This paper is to present clinical manifestations, operational experience, surgical efficacy and complications observed, developed or obtained from these patients.

Methods

Patients

38 patients were admitted between January, 2010 and January to April, 2014, who were not suitable for detachable balloon embolization or difficult to treat with the embolization, including 17 in post-trauma acute phase (< 2

weeks), 7 who were recurrent after treatment with detachable balloon embolization, 9 whose detachable balloons were not able to enter the fistula point, and 5 who were treated with the embolization because there was obvious drainage to the fistula as revealed by cerebral angiography. Among the patients, 29 were male

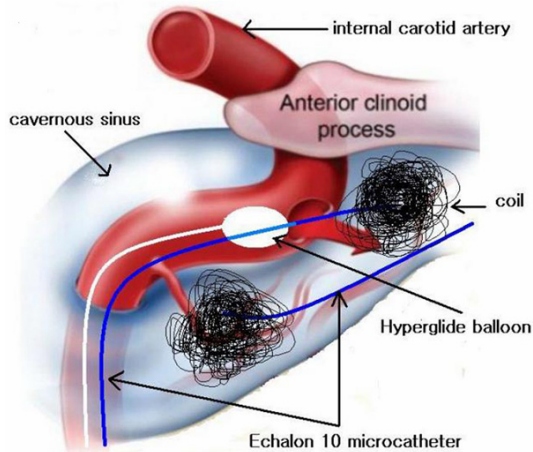


Figure 2. Borrow A-type TCCF resulted from a traumatic tear of internal carotid artery and direct communication with cavernous sinus. Blue lines show two micro-catheters entering the cavernous sinus via femoral vein and femoral artery, respectively. One of them is inserted to the anterior cavernous sinus into the inferior petrosal sinus and used to transport and deposit the micro-coils. The other enters the posterior part of the cavernous sinus via the incision on internal carotid artery and is used to transport and deposit the micro-coils. While line shows the temporarily inflated balloon to block the fistula point. Onyx 18 is slowly injected through the two micro-catheters.

and 9 were female with a mean age of 37 years (17-65 years). All patients had a history of craniofacial trauma with a median injury time of 17 days (3 days-4 years). 33 patients had known history of forehead trauma, 19 patients were found to loss vision on the injured side immediately after injury. CT showed that 30 patients had clear fractures at the bottoms of anterior and middle cranial fossae, 3 had delayed sub-cortical hemorrhage (1 in temporal lobe, 2 in the basal ganglia). 27 cases had unilateral proptosis and 11 had bilateral proptosis. 15 cases had conjunctival edema and pterygium. 17 patients had oculomotor dysfunctions or eyeball fixation on affected side. Intracranial murmur was heard in 36 cases. 3 patients had disorder of consciousness, and 2 were hemiplegic. Informed consents were signed by the attending surgeons and the patients. The treatment protocol was approved by the Ethic Committee of Qilu Hospital.

Imaging examination

CT examinations were performed for all patients and showed that all patients had widen cavernous sinus; 36 of them had the dilation on eye

veins. Cerebral angiography was performed on all patients to confirm the diagnosis. One patient was found to have bilateral carotid cavernous fistula. His cavernous sinus was inserted micro-catheter through the left internal jugular vein. 27 patients were drained from bilateral cavernous sinus, 10 from unilateral cavernous sinus, and one drained to the other side through intercavernous sinus. Subpetrosal angiography was conducted in 32 patients, among them, 9 had obvious drainage in the cortical veins (**Figure 1**).

Surgical procedure

The right femoral artery was punctured with 8F sheath to insert 8F guiding catheter into the affected internal carotid artery and left femoral vein was punched with 6F sheath to insert 6F guiding catheter into the internal carotid vein, respectively. Cerebral angiography was carried out with 5F universal catheter to locate TCCF and venous drainage. For the 38 patients, after general anesthesia, 9 patients were attempted to embolize with detachable balloons (Balt Company, France). Among them, five patients were given 1-3 detachable balloons. However, the balloons were unable to enter the fistula point, these patients were treated with the simultaneous arteriovenous approach as described below. The 8F or 6F guiding catheters (Envoy, DePuy) were inserted into the internal carotid artery, and the hyperglide balloon (4 mm*20 mm) was placed into the cavernous segment of the fistula via the catheter. The micro catheter Echalon 10 was bent to right-angle to fit for PT2 micro-guiding wire to advance the head tip of the microcatheter to the medial part and the posterior part of the cavernous sinus through the arterial guiding catheter. The 6F chamberon guiding catheter was advanced through the femoral vein sheath to internal jugular vein on the affected side, and then the inner wire of the guiding catheter was inserted into inferior petrosal sinus or fixed in the opening of inferior petrosal sinus over an ultra-election super-slip guide wire. With the inner microwire remained not retrieved, the tip of a 45 degree-shaped microcatheter Echalon 10 was inverted over PT2 micro-guiding wire to the cavernous sinus through inferior petrosal sinus and then placed the micro-guiding catheter tip near the anterior part of the cav-

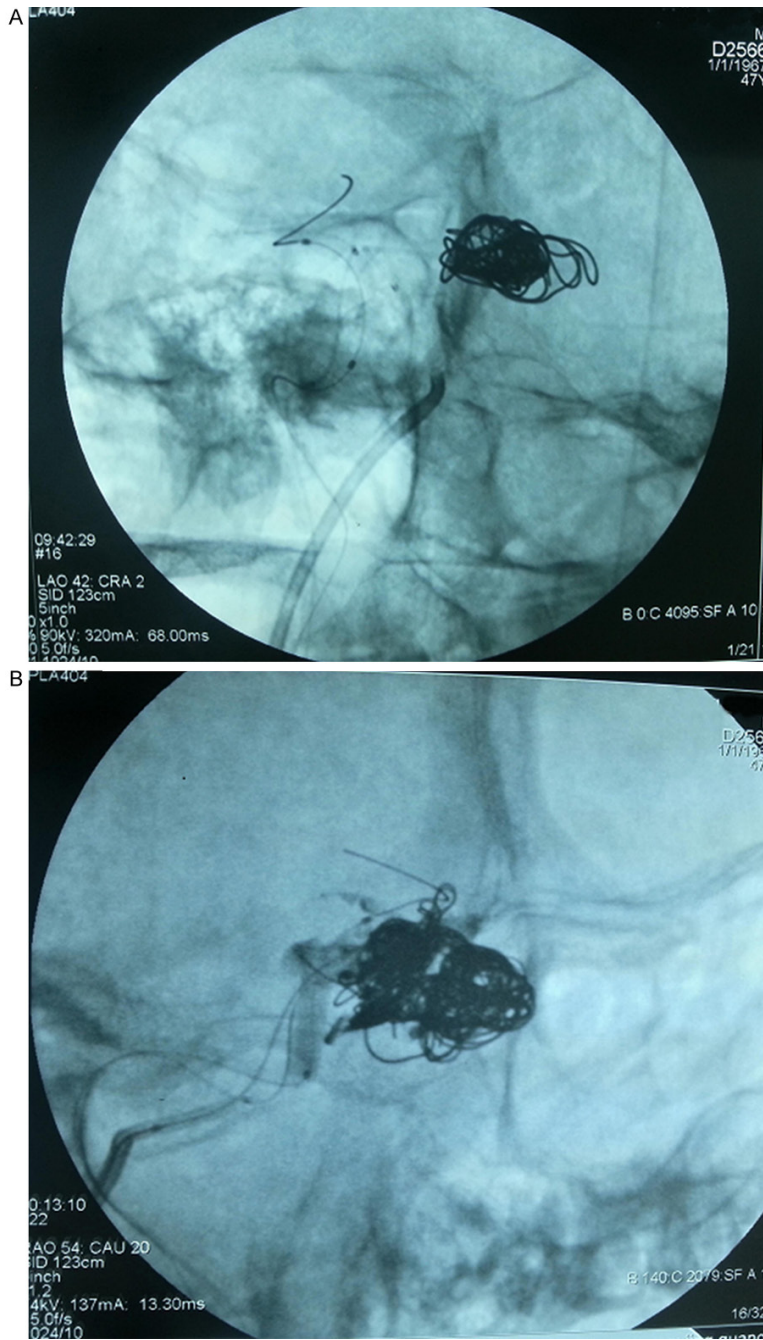


Figure 3. Angiographs showing internal carotid vein and artery during operation. A. Two micro catheters are inserted into the cavernous sinus over a ultra-election *super-slip* guide wire, one reaching near the anterior part of the cavernous sinus from the inferior petrosal sinus for micro-coil transportation and placement, the other to the posterior part of the cavernous sinus via the incision of the vein to fill with the coils. B. The balloon is temporally inflated to block the fistula. Onyx 18 is slowly injected through the two micro-catheters.

cavernous sinus, which is close to the eye vein (Figure 2).

According to the expansion of cavernous sinus, 2 to 4 detachable coils with a diameter of 8 to

14 mm were filled in through the arterial and venous micro-catheters (Figure 3). After the placement of coils, the tip of micro-catheter was retracted a little bit to approach the internal carotid artery incision. If micro-catheter tip was too close to the tear, the tip needed to advance a little deep over the micro-guiding wire. After washed with normal saline and DMSO, Onyx 18 was first injected slowly through the venous micro-catheter to block the cavernous sinus drainage through the eye vein, and then the glue was injected slowing through the arterial micro-catheter to block the cavernous sinus drainages to the pterygoid plexus, inferior petrosal sinus, superior petrosal sinus and inferior petrosal sinus. At this point, Onyx might diffuse to the internal carotid artery. The balloon was then inflated for five minutes to block the artery. When angiography showed that the internal carotid artery was completely blocked, more glue was injected slowly through arterial micro-catheters to allow it diffuse slowly to the balloon position. The balloon was deflated and checked for TCCF block by angiography. In general, there might be some arteriovenous steals, but the flow would have been significantly reduced. The intracranial segment of internal carotid artery could be imaged for confirmation. The balloon could be re-inflated to inject slowly the glue from venous microcatheter. For each injection, the

amount should not be more than 0.1 mL. This angiography and injection procedure might be repeated as needed. If the glue was seen not having reached the artery, more was injected. For complete and final embolization of the fis-

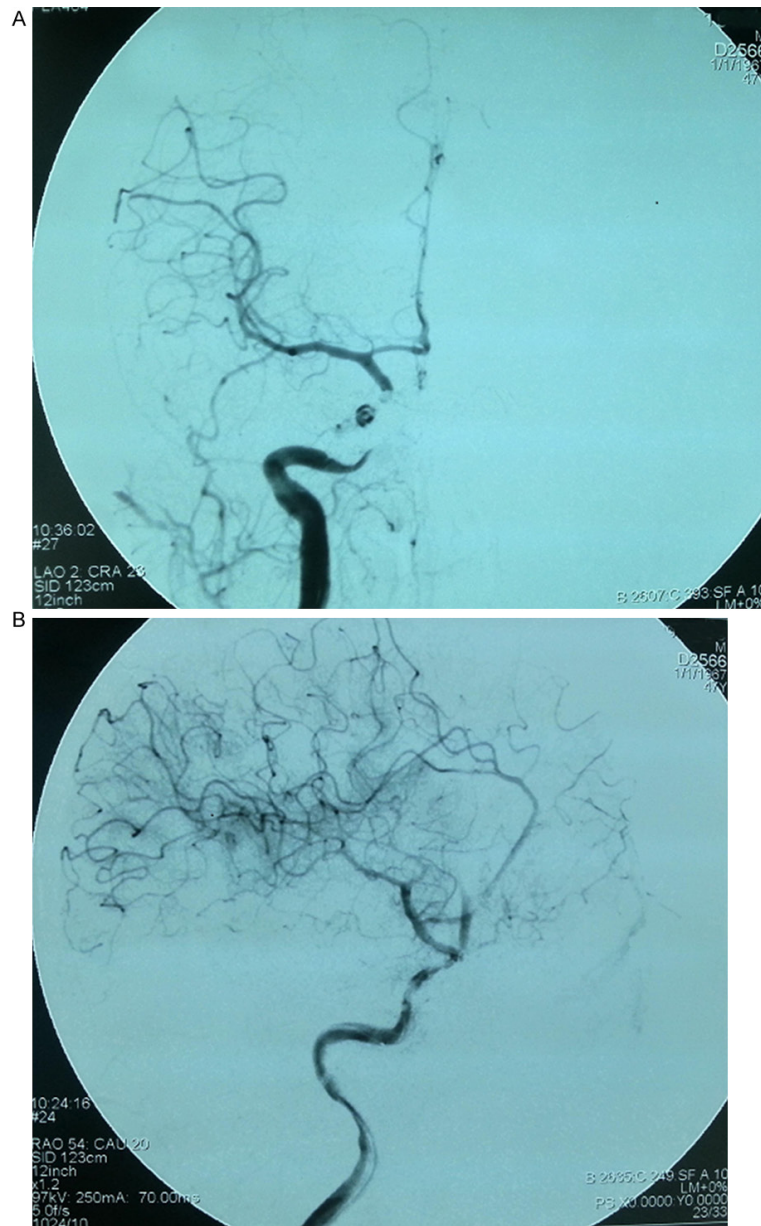


Figure 4. The internal carotid vein and artery after retrieve of micro-catheters and balloons after the surgery. A. Anteroposterior and B. Lateral views showing that TCCF is completely embolized and blood is flowing well in the internal carotid vein and artery.

tula, the glue needs to be injected from vein. This was mainly to prevent the gel from flowing back to the internal carotid artery even under protection of the balloon. In general, 0.5-2.4 mL glue may be injected via the artery and 0.8-3.5 mL from the vein. The total amount of Onyx was 1.5 to 5.7 mL with a median of 3.1 mL. The post-operative complications were examined by ophthalmologists. The patients were followed up with monthly visit for 6 months to 4

years, and examined with digital subtraction angiography after 6 months. The analyses were based on 2-sided tests with values of $P < 0.5$ considered significant with the Fisher's exact test when appropriate.

Results

Imaging results

Immediately after the surgery, angiography showed that the arteriovenous fistulas of all patients disappeared completely (**Figure 4**). One patient (2.6%) had Onyx diffused to the internal carotid artery, resulting in occlusion of the artery. However, the communication compensation of the anterior and posterior parts was excellent and no symptoms were seen. In another patient, small amount of Onyx was washed to the M4 segment of middle cerebral artery by the blood, which was given postoperative anticoagulation and had no symptoms. In other two patients (5.2%), the glue floated on the arterial wall of internal carotid. They were implanted with stents to push the glue back the arterial wall.

Clinical outcomes

After operation, intracranial murmur disappeared and conjunctival edema and proptosis were reduced in all patients. 5 patients (29.4%) who had no eye movement disorders before operation had the disorder. Analysis showed that this is related to the amount of Onyx injected (**Table 1**). In 19 patients who did not loss vision, 16 (84.2%) had improved vision.

Follow-up results

Among 22 patients who experienced eye movement dysfunction after embolization, 17

Onyx 18 embolization of traumatic carotid-cavernous fistula

Table 1. Relationship between oculomotor nerve injury and amount of Onyx injected for TCCF Embolization

Patient without oculomotor nerve symptoms before operation	Cases	Amount of Onyx injected		Fisher's exact test
		< 3.1 mL	≥ 3.1 mL	
No symptom after operation	16	14	2	$P = 0.01$
With oculomotor nerve symptom after operation	5	1	4	
Total	21	15	6	

Table 2. Relationship between recovery time of oculomotor nerve symptom and amount of Onyx injected for TCCF Embolization

Recovery time	Cases	Amount of Onyx injected		Fisher's exact test
		< 3.1 mL	≥ 3.1 mL	
< 37 days	12	4	8	$P > 0.05$
≥ 37 days	5	1	4	
Do not restore	5	2	3	
Total	22	7	15	

Table 3. Relationship between preoperative oculomotor nerve injury and oculomotor recovery time after TCCF Embolization

Recovery time	Cases	Preoperative oculomotor nerve injury		Fisher's exact test
		Yes	No	
< 37 days	12	10	2	$P > 0.05$
≥ 37 days	5	2	3	
Do not restore	5	5	0	
Total	22	17	4	

(77.3%) were recovered for the movement function within 5 to 75 days, with the median time of 37 days. The recovery speed was found not associated with the amount of Onyx injected (Table 2, $P > 0.05$), nor with existence of the disorders before the surgery (Table 3, $P > 0.05$). 5 patients were followed up for more than 6 months, and their eye movement function were still not restored. The five patients had eye movement disorders before operation. Another 5 patients whose eye movement disorders were caused by the embolization therapy restored the function within the follow-up periods.

Three patients with cerebral hemorrhage were given symptomatic treatments and their hematoma disappeared. Among them, two patients had reduced limb muscle strength before the

surgery and the strength was basically restored after operation. No pseudoaneurysm formation was observed in the treated patients.

All the data were grouped by median. Difference between the groups were compared using the Fisher's exact test with values of $P < 0.5$ considered significant.

Discussion

TCCF is a most common arteriovenous communication formed between carotid artery or its branches and cavernous sinus due to external factors such as car accidents. It can rapidly occur with a few days or weeks after the trauma, and accounts for 75% of carotid cavernous fistula [6, 7]. In 1985, Barrow classified TCCF into four types: Type A fistulas are direct, high-flow shunts between the internal carotid artery and the cavernous sinus, which usually occur after trauma or the rupture of a carotid cavernous aneurysm; Type B are dural shunts between meningeal branches of the internal carotid artery and the cavernous sinus; Type C are dural shunts between meningeal branches of the external carotid artery and the cavernous sinus; and Type D are dural shunts between meningeal branches of both the internal carotid artery and external carotid artery and the cavernous sinus [8]. This classification is very useful for treatment planning. In type A TCCF, the fracture is often a single, large rupture with most of the diameter being < 5 mm with average of 3 mm. It may form two fistulas proximal and distal to the fracture. For these patients, floating balloon embolization is a favorable option [9, 10]. However, for patient with a large rupture, floating balloon will block the internal carotid artery. In Onyx embolization via artery, even the artery is protected by the balloon, the glue is very easy to flow back to the internal carotid artery, resulting in occlusion of internal carotid artery [11, 12]. This type of patients are mostly simultaneous with serious fracture of

skull base. If balloon embolization is used in acute period of trauma, it can lead to the displacement of skull base fracture, leading to a risk of acute hemorrhage [13]. Therefore, for patients who had early symptoms after trauma, or had difficulty to float the balloon into the fistula point or may have internal carotid artery occlusion once the balloon is inflated, we have used the simultaneous arteriovenous approach [14, 15]. Type B patients often have several fistulous openings with low flow, whose blood supply is from the middle meningeal artery of the external carotid artery branch or ascending pharyngeal artery. For them, arterial embolization is often difficult and easy to relapse. However, they can be treated successfully by micro-coil embolization of cavernous sinus through intravenous approach [16].

Once diagnosed, TCCF should be treated with the goals to protect the eye vision to prevent further deterioration, protect or restore the eye movement, to treat exophthalmos, to eliminate intracranial murmur, and to prevent cerebral hemorrhage or cerebral ischemia to ensure the blood supply in cerebral tissue [17, 18]. Removable coils and Onyx 18 are proven and effective methods for embolization of TCCF [19, 20]. In this study, Hyperglide balloon was used as an auxiliary measure to temporally block the blood flow in internal carotid artery, and removable coil was used to reduce the blood flow from the orificium fistulae, followed by injection of Onyx 18 to complete block the fistula. The balloon can facilitate diffusion of Onyx 18, prevent intraoperative displacement of coils and occlusion of internal carotid artery by Onyx glue.

The cavernous sinus is a complete and trabecular venous channel. Because of the trabeculae, cavernous sinus is separated into many cavities, and the interventional micro-catheter need to be placed into or near the responsible cavities to achieve the best effect [21]. The orificiums of superior petrosal sinus and inferior petrosal sinus, and basilar venous plexus are located in the posterior chamber of cavernous sinus and the ophthalmic veins enter from anterior chamber of cavernous sinus. This anatomical relationship between the cavernous sinus and vein drain provides the anatomical basis for venous drain direction of CCF [22]. The choice of TCCF approach has been well

agreed. Most researchers agree to approach direct fistula from artery and indirect fistula from vein. For direct fistula with especial narrow, tortuous and broken artery, venous approach is also considered to be effective [23]. For most patients anyone of the approaches can achieve satisfactory outcomes. In our study, we used a simultaneous arteriovenous approach, where micro-coils were delivered and Onyx was injected through two micro-catheters, respectively. This way, at least one or even two micro-catheters are ensured to be in or near the “responsible cavity”. The intravenous micro-catheter tip is placed in the anterior chamber to easily block the reflux of eye venous blood, and the arterial micro-catheter is placed in posterior chamber to effective to block the reflux to cortical venous pathway and reduce the risk of cortical venous hypertension and hemorrhage. At the same time, the fistula is completely embolized with Onyx injected from intravenous micro-catheter. This would most effectively prevent glue from flowing back into the internal carotid artery and thus prevent internal carotid artery from being blocked. The intimal purpose of this method is to avoid the setbacks from either arterial or venous approach to ensure effective treatment of TCCF with minimal amount of Onyx injection for less cavernous sinus symptoms. In this group of patients, only 1 patient (2.6%) had internal carotid artery occlusion, much lower than 12.5% reported in the literature [24].

Because of the connective trabecular tissue in cavernous sinus, use of only micro-coil may be sometimes difficult to achieve a tight embolization or multiple micro-coils may be needed, which may increase the risk of cranial nerve palsy [25]. Onyx 18 as liquid embolic agent has an advantage to compensate the drawbacks from the micro-coils. Different from solid, it is dispersible and can reaches the cavity space that is not reachable by the coil. On the other hand, micro-coil can change the hemodynamics in cavernous sinus to prevent excessive dispersion of Onyx 18, and reduce the adverse consequences of distal embolization caused by Onyx 18 [6, 26]. In this group of patients, we find that new onset of oculomotor nerve symptoms is related to the amount of Onyx 18 injected, suggesting that by using the simultaneous approach, the amount of Onyx 18 injected can be reduced to minimize the complications.

Conclusion

Our study has shown that the simultaneous transarterial and transvenous approach for TCCF treatment can not only increase the success rate of one-time operation, but also reduce the amount of embolic materials used, especially the amount of glue. Although there is a tendency to prove that the patients who use less amount of Onyx would have a quicker oculomotor nerve recovery, the number of cases in this group are not enough to show statistical difference, and more clinical validations are still needed.

Acknowledgements

This work was supported by the National Natural Sciences Foundation of China (NO. 81141088), the Research Fund for Excellent Young and Middle-aged Scientists of Shandong Province (NO. 2004BS02010).

Disclosure of conflict of interest

None.

Address correspondence to: Dr. Yunyan Wang, Department of Neurosurgery, Qilu Hospital, Shandong University, 107 Wenhua Xi Road, Jinan 250012, China. Tel: 86-531-82166615; Fax: 86-531-82166615; E-mail: wangyy2015mm@126.com

References

- [1] Bonnin N, Bacin F, Gabrillargues J and Chiambaretta F. [Carotid-cavernous fistula: comparison of clinical and neuroradiologic features pre- and post-embolization]. *J Fr Ophtalmol* 2013; 36: 862-867.
- [2] Chi CT, Nguyen D, Duc VT, Chau HH and Son VT. Direct traumatic carotid cavernous fistula: angiographic classification and treatment strategies. Study of 172 cases. *Interv Neuroradiol* 2014; 20: 461-475.
- [3] Zanaty M, Chalouhi N, Tjoumakaris SI, Hasan D, Rosenwasser RH and Jabbour P. Endovascular treatment of carotid-cavernous fistulas. *Neurosurg Clin N Am* 2014; 25: 551-563.
- [4] El-Hindy N, Kalantzis G, Patankar T, Georgalas I, Jyothi S, Goddard T and Chang B. Difficult indirect carotid-cavernous fistulas—alternative techniques to gaining access for treatment. *Clin Interv Aging* 2014; 9: 1687-1690.
- [5] Chalouhi N, Dumont AS, Tjoumakaris S, Gonzalez LF, Bilyk JR, Randazzo C, Hasan D, Dalyai RT, Rosenwasser R and Jabbour P. The superior ophthalmic vein approach for the treatment of carotid-cavernous fistulas: a novel technique using Onyx. *Neurosurg Focus* 2012; 32: E13.
- [6] Morton RP, Tariq F, Levitt MR, Nerva JD, Mossa-Basha M, Sekhar LN, Kim LJ, Hallam DK and Ghodke BV. Radiographic and clinical outcomes in cavernous carotid fistula with special focus on alternative transvenous access techniques. *J Clin Neurosci* 2015; 22: 859-864.
- [7] Pashapour A, Mohammadian R, Salehpour F, Sharifipour E, Mansourizade R, Mahdavi-fard A, Salehi M, Mirzaei F, Sariaslani P, Ardalani GF and Altafi D. Long-Term Endovascular Treatment Outcome of 46 Patients with Cavernous Sinus Dural Arteriovenous Fistulas Presenting with Ophthalmic Symptoms. A Non-Controlled Trial with Clinical and Angiographic Follow-up. *Neuroradiol J* 2014; 27: 461-470.
- [8] Gandhi D, Ansari SA and Cornblath WT. Successful transarterial embolization of a Barrow type D dural carotid-cavernous fistula with ethylene vinyl alcohol copolymer (Onyx). *J Neuroophthalmol* 2009; 29: 9-12.
- [9] Samaniego EA, Martinez-Galdamez M and Abdo G. Treatment of direct carotid-cavernous fistulas with a double lumen balloon. *J Neurointerv Surg* 2015; 8: 531-5.
- [10] Bilbin-Bukowska A, Stepień A, Brzozowski K, Piasecki P and Skrobowska E. [Diagnostic and therapeutic problems of bilateral carotid-cavernous sinus fistula]. *Pol Merkur Lekarski* 2014; 36: 345-347.
- [11] Ramalingaiah AH, Prasad C, Sabharwal PS, Saini J and Pandey P. Transarterial treatment of direct carotico-cavernous fistulas with coils and Onyx. *Neuroradiology* 2013; 55: 1213-1220.
- [12] Santos-Franco JA, Lee A, Zenteno M, Gil-Ortiz C and Vega-Montesinos S. Carotid-cavernous fistula treatment with ethylene vinyl alcohol (onyx) exclusively through anterior venous approach. *Vasc Endovascular Surg* 2012; 46: 332-337.
- [13] Inui T, Okuno S, Hashimoto H and Fujimoto K. [Successful surgical treatment of an extra-sinusal dural arteriovenous fistula located in the lateral wall of the cavernous sinus: a case report]. *No Shinkei Geka* 2014; 42: 53-57.
- [14] Baharvahdat H, Shabestari MM, Zabihiyan S, Etemadrasaei H, Blanc R and Pötin M. Transvenous embolization of a carotid cavernous fistula complicated by a hematoma at the tentorial edge. *Interv Neuroradiol* 2014; 20: 301-303.
- [15] Briganti F, Caranci F, Leone G, Napoli M, Cicala D, Briganti G, Tranfa F and Bonavolonta G. Endovascular occlusion of dural cavernous fis-

- tulas through a superior ophthalmic vein approach. *Neuroradiol J* 2013; 26: 565-572.
- [16] Harrison JF, Vega RA, Machinis TG and Reavey-Cantwell JF. Multiple unilateral traumatic carotid-cavernous sphenoid sinus fistulas with associated massive epistaxis: a consequence of parkour. *Ochsner J* 2015; 15: 92-96.
 - [17] Schutz P, Bosnjakovic P, Abulhasan YB and Al-Sheikh T. Traumatic carotid-cavernous fistula in a multiple facial fractures patient: case report and literature review. *Dent Traumatol* 2014; 30: 488-492.
 - [18] Zenteno M, Jorge SF, Rafael MS, Raphael AH, Gabriel AC and Angel L. Contralateral transvenous approach and embolization with 360 degrees guglielmi detachable coils for the treatment of cavernous sinus dural fistula. *Asian J Neurosurg* 2015; 10: 55.
 - [19] Zheng C, Shu H, Tang K, Zeng S and Mao C. [Factors affecting oculomotor nerve function recovery time following balloon embolization for oculomotor nerve palsy caused by traumatic carotid cavernous sinus fistula]. *Nan Fang Yi Ke Da Xue Xue Bao* 2015; 35: 244-247.
 - [20] de Dompablo E, Diez-Alvarez L, Ruiz-Casas D, Sanchez-Gutierrez V, Ciancas E and Gonzalez-Lopez JJ. Recurrent neurosensory macular detachment in carotid-cavernous fistula. *Arch Soc Esp Oftalmol* 2014; 90: 331-4.
 - [21] Dos Santos D, Monsignore LM, Nakiri GS, Cruz AA, Colli BO and Abud DG. Imaging diagnosis of dural and direct cavernous carotid fistulae. *Radiol Bras* 2014; 47: 251-255.
 - [22] Kashiwazaki D, Kuwayama N, Akioka N and Kuroda S. Delayed abducens nerve palsy after transvenous coil embolization for cavernous sinus dural arteriovenous fistulae. *Acta Neurochir (Wien)* 2014; 156: 97-101.
 - [23] Thiex R, Gross BA, Gupta R, Wyers MC, Frerichs KU and Thomas AJ. Transvenous approach to carotid-cavernous fistula via facial vein cut down. *J Clin Neurosci* 2014; 21: 1238-1240.
 - [24] Fattahi TT, Brandt MT, Jenkins WS and Steinberg B. Traumatic carotid-cavernous fistula: pathophysiology and treatment. *J Craniofac Surg* 2003; 14: 240-246.
 - [25] Wu Z, Zhang Y and Wang C. Treatment of traumatic carotid-cavernous fistula. *Interv Neuroradiol* 2000; 6: 277-302.
 - [26] Zaidi HA, Kalani MY, Spetzler RF, McDougall CG and Albuquerque FC. Multimodal treatment strategies for complex pediatric cerebral arteriovenous fistulas: contemporary case series at Barrow Neurological Institute. *J Neurosurg Pediatr* 2015; 15: 615-24.