

Case Report

Radiotherapy of hepatocellular carcinoma with hepatic artery/hepatic vein fistula: a case report

Lijuan Ding^{1*}, Wei Hou^{1*}, Shudong Wang², Xinsen Wang³, Xue Hou¹, Lihua Dong¹

Departments of ¹Radiation Oncology, ²Cardiovascular Center, ³Interventional Radiology, The First Hospital of Jilin University, Changchun, China. *Equal contributors.

Received May 3, 2016; Accepted July 26, 2016; Epub November 15, 2016; Published November 30, 2016

Abstract: A case of hepatocellular carcinoma (HCC) with hepatic artery/hepatic vein fistula (HAHVF) is presented in this report. The patients developed a disease of a large mass with hepatic artery/hepatic vein fistula demonstrated by computed tomography (CT) scans as well as hepatic artery angiography, which had missed the chance for resection or liver transplantation. Little improvement was made after 1 time of transcatheter arterial chemoembolization (TACE) based on CT criteria. Then he was treated with radiation therapy, by which the fistula had been completely obliterated and the tumor volume reduced significantly on CT 1 Month after radiotherapy. AFP backed to nearly normal. Then TACE was performed for the second time. The hepatic artery/hepatic vein fistula was occlusion showed by hepatic artery angiography and the tumor had almost been inactivated. Now he can be the candidate for resection or transplantation.

Keywords: Radiotherapy, hepatic artery/hepatic vein fistula, liver cancer

Introduction

Hepatocellular carcinoma (HCC) is one of the most common solid tumors in the world [1]. Patients with early stage HCC are candidates for curative treatments such as surgical resection and liver transplantation, but most patients are not initially diagnosed until present with locally advanced or unresectable disease on the basis of local vascular invasion or inadequate baseline hepatobiliary function [1]. Arteriovenous shunting (AVS) has been frequently reported in HCC, even treated with transcatheter arterial chemoembolization (TACE), the effect is not satisfactory [2]. Despite the historically limited role of radiotherapy in the management of HCC, modern advances in treatment design and delivery have renewed enthusiasm for radiation as a potentially curative treatment modality [3]. Here, we present a case of HCC with a large mass and hepatic artery/hepatic vein fistula (HAHVF). After treated with radiation, the fistula had been completely obliterated and the tumor had almost been inactivated.

Case report

In September 2014 a 53-year-old Asian man, with a history of hepatitis B virus infection, presented to hospital with abdominal pain for 2 days. Underwent a CT which revealed a large mass (11.3 cm × 7.2 cm in diameter) in the right hepatic lobe and hepatic artery/hepatic vein fistula (**Figure 1A, 1B**). Laboratory results showed mildly elevated transaminases (AST-49IU, ALT54IU, and GGT, 831 IU, TBI 33.8 μmol/L). α-fetoprotein (AFP) was 51.51 ng/ml. Based on his medical history, typical images and serum AFP level, the patient was diagnosed as HCC, unfortunately, had lost the chance for resection or transplantation. The patient was performed TACE in September 2014. Similarly, HAHVF was identified by angiography, shunting into the hepatic vein about 50% (**Figure 2A**). The therapeutic effect is limited (**Figure 2B**).

Intensity-modulated radiation therapy (IMRT) commenced 9 days following the TACE. The computerized treatment planning system (Pinnacle) was utilized to determine radiation fields. The clinical target volume (CTV) was

Radiotherapy in treating cancer with hepatic artery/hepatic vein fistula

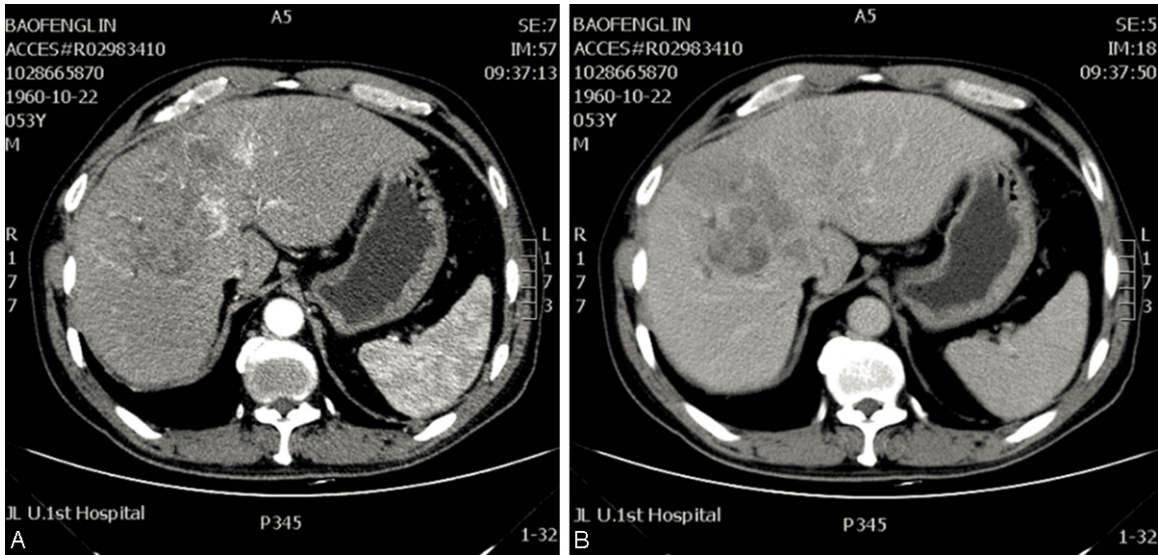


Figure 1. A, B: CT showed a large mass (11.3 cm × 7.2 cm in diameter) in the right hepatic lobe, hepatic vein development advance in arterial phase.

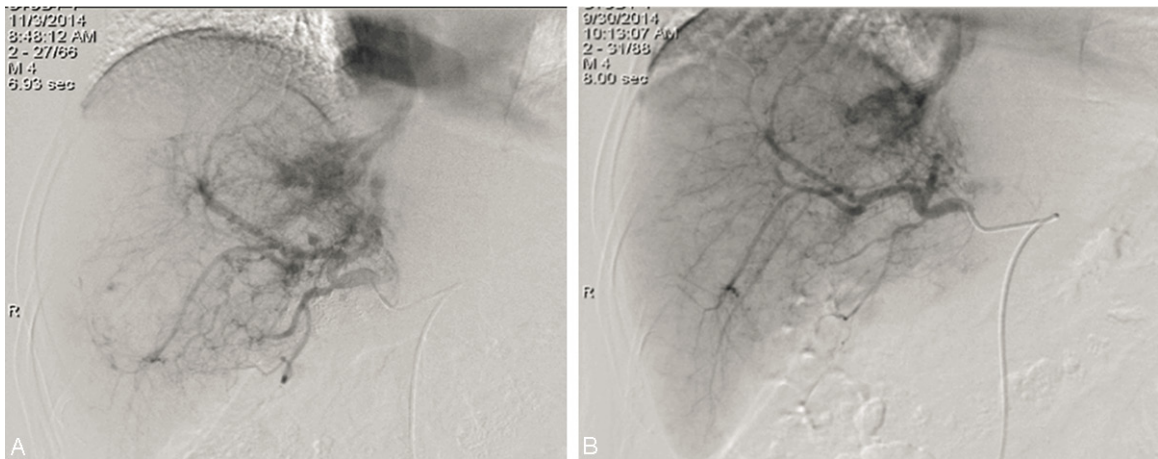


Figure 2. A: Before TACE, angiography showed arteriovenous shunting between hepatic artery and vein. B: After TACE, angiography showed arteriovenous shunting between hepatic artery and vein.

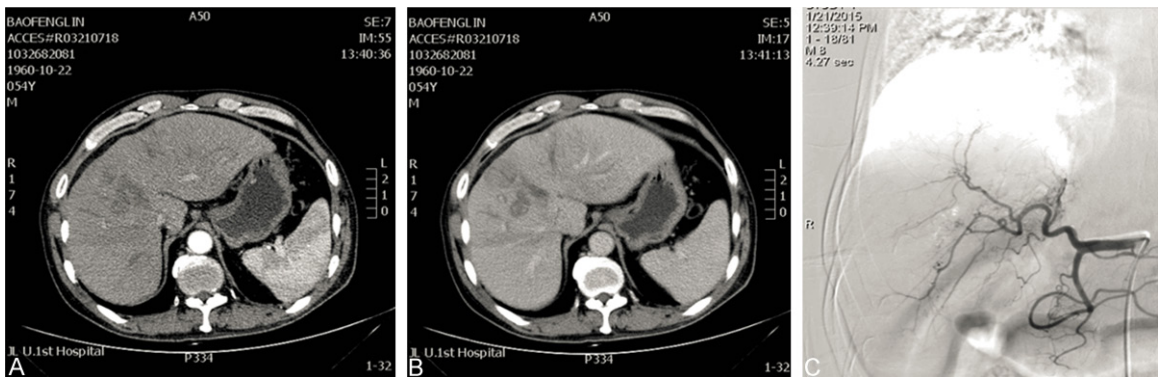


Figure 3. 1 month after radiation. A, B: CT showed the HAHVF had already been obliterated and the tumor volume reduced significantly. C: Complete resolution of the shunt was noted 1 month after radiotherapy by angiography.

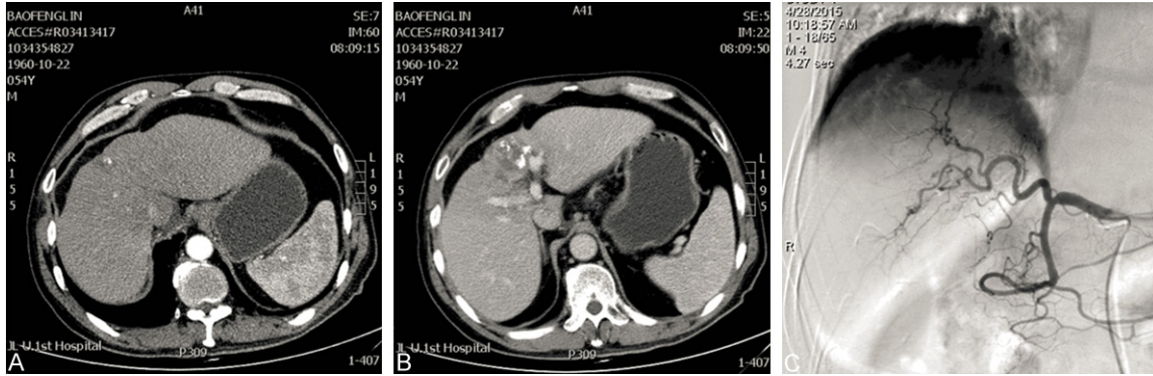


Figure 4. 3 months after radiotherapy. A, B: CT showed multiple group flake low density shadow can be seen in the liver, lesions in scattered and patchy in nodular and iodine oil deposits, slightly strengthened in enhancement scan. The tumor is inactive. C: Complete resolution of the shunt was noted by angiography.

defined as the HAHVF area and the tumor by the radiologist, the planning target volume (PTV) included the CTV plus a 1 cm margin. The patient was treated with 6 MV X-ray using True Beam linear accelerator. The radiation dose was 1.8 Gy per fraction, with a total dose of 48 Gy. The patient tolerated well and with no obvious toxicity. Most important thing is the abdominal pain relieved.

1 month after radiotherapy in January 2015, the patient's AFP dropped to nearly normal limits (9.09 ng/ml) and the CT showed the HAHVF had already been obliterated and the tumor volume reduced significantly (**Figure 3A**). The patient was treated with TACE again and it was established that the HAHVF had been concluded by angiography (**Figure 3B**).

3 month follow up in April 2015: AFP was normal and CT showed multiple low density shadows could be seen in the liver, and the iodine oil deposited in the lesions, slightly strengthened in enhancement scan. The tumor was almost inactivated (**Figure 4A, 4B**). Complete resolution of the shunt was noted by angiography (**Figure 4C**). The patient can be treated with resection or transplantation.

Discussion

The treatment for HCC is based on functional status, liver functional reserve and stage of the tumor [4]. The treatment of choice for hepatocellular carcinoma is surgical resection whenever possible [5]. Surgical resection of HCC can be achieved in patients with a tumor that is amenable to surgical resection and has a good

liver functional reserve. However, most of the patients with HCC have already lost the operation opportunity when was diagnosed [6] and are only candidates for palliative treatment. Patients with either large tumors or multinodular tumors and a good performance status are candidates for TACE [7]. Tumor with arteriovenous shunting (AVS) is a cause of TACE failure in this population of patients [8], which usually means poor prognosis. AVS is a common complication of HCC, the incidence induced by HCC is 28.8-63.2%. Hepatic artery/hepatic venous fistula (HAHVF) is one kind of AVS, rarely happened relatively [9]. It can easily lead to hepatic vein, inferior vena cava, right atrium thrombus formation and lung metastasis. In addition, it can cause pulmonary embolism and systemic embolism after TACE, because of iodized oil and chemotherapeutic drugs directly into the hepatic vein and cannot act on the lesion. Even if the suspension deposit in the lesion, most of them will drain in 1 week, which reduce the efficacy of TACE seriously.

Several embolic materials have been used to try to treat AVS in HCC patients [10]. However, a safe and effective therapeutic method has not yet been established. Radiotherapy for the treatment of cerebral arteriovenous malformations (AVMs) [11] or dural arteriovenous fistulas of the cavernous sinus (DAVFs) [12, 13] has been reported. However, the treatment of AVS in HCC patients using radiotherapy is seldom mentioned. Previously, radiotherapy is seldom mentioned or used for the management of HCC because of the poor tolerance of the whole liver to radiation and the risk of radiation-induced liver disease (RILD). With growing knowledge of

normal liver tolerance and the advances in radiotherapy techniques, partial liver irradiation has yielded some promising results in patients with unresectable HCC [14]. The tolerance radiation dose for 30% liver irradiation has been demonstrated to be as high as 70 Gy. The probable mechanism of using radiotherapy to treat arteriovenous malformations is that irradiation can lead to intimal proliferation and vascular occlusion, which was recognized by Harvey Cushing in 1928. That can be the theory basis of radiotherapy combines for unresectable HCC with AVS. Combination treatment with radiotherapy and TACE will benefit these patients [15].

Conclusions

Radiotherapy is a treatment alternative for HCC patients with AVS. Followed by TACE will bring patients the chance to receive resection or transplantation.

Disclosure of conflict of interest

None.

Address correspondence to: Dr. Lihua Dong, Department of Radiation Oncology, The First Hospital of Jilin University, 71 Xinmin Street, Changchun 130-021, China. E-mail: drlihuadong@163.com

References

- [1] Llovet JM, Burroughs A, Bruix J. Hepatocellular carcinoma. *Lancet* 2003; 362: 1907-17.
- [2] Ngan H, Peh WC. Arteriovenous Shunting in Hepatocellular Carcinoma: Its Prevalence and Clinical Significance. *Clin Radiol* 1997; 52: 36-40.
- [3] Kalogeridi MA, Zygogianni A, Kyrgias G, Kouvaris J, Chatziioannou S, Kelekis N, Kouloulis V. Role of radiotherapy in the management of hepatocellular carcinoma: A systematic review. *World J Hepatol* 2015; 7: 101-12.
- [4] Saraswat VA, Pandey G, Shetty S. Treatment algorithms for managing hepatocellular carcinoma. *J Clin Exp Hepatol* 2014; 4 Suppl 3: S80-9.
- [5] Chen D, Wang R, Meng X, Yan H, Jiang S, Feng R, Zhu K, Xu X, Dou X, Jin L. Prognostic value of serum gamma-glutamyl transferase in unresectable hepatocellular carcinoma patients treated with transcatheter arterial chemoembolization combined with conformal radiotherapy. *Oncol Lett* 2014; 8: 2298-304.
- [6] Murata S, Mine T, Sugihara F, Yasui D, Yamaguchi H, Ueda T, Onozawa S, Kumita S. Interventional treatment for unresectable hepatocellular carcinoma. *World J Gastroenterol* 2014; 20: 13453-65.
- [7] Paul SB, Sharma H. Role of Transcatheter Intra-arterial Therapies for Hepatocellular Carcinoma. *J Clin Exp Hepatol* 2014; 4 Suppl 3: S112-21.
- [8] Hsu HC, Chen TY, Chiu KW, Huang EY, Leung SW, Huang YJ, Wang CY. Three-dimensional conformal radiotherapy for the treatment of arteriovenous shunting in patients with hepatocellular carcinoma. *Br J Radiol* 2007; 80: 38-42.
- [9] Kumar A, Ahuja CK, Vyas S, Kalra N, Khandelwal N, Chawla Y, Dhiman RK. Hepatic arteriovenous fistulae: role of interventional radiology. *Dig Dis Sci* 2012; 57: 2703-12.
- [10] Kim JS, Park YM, Kim NY, Yun HK, Lee KJ, Kim BH, Park SJ, Yeon JW, Jung G. Combination treatment with intrahepatic arterial infusion and intratumoral injection chemotherapy in patients with far-advanced hepatocellular carcinoma and arterioportal or arteriovenous shunts: preliminary results. *Korean J Hepatol* 2011; 17: 120-9.
- [11] Friedman WA, Bova FJ, Mendenhall WM. Linear accelerator radiosurgery for arteriovenous lformations: the relationship of size to outcome. *J Neurosurg* 1995; 82: 180-9.
- [12] Fokas E, Henzel M, Wittig A, Grund S, Engenhardt-Cabillic R. Stereotactic radiosurgery of cerebral arteriovenous malformations: long-term follow-up in 164 patients of a single institution. *J Neurolog* 2013; 260: 2156-62.
- [13] Guo WY, Pan DHC, Wu HM, Chung WY, Shiau CY, Wang LW, Chiou HJ, Yen MY, Teng MM. Radiosurgery as a Treatment Alternative for Dural Arteriovenous Fistulas of the Cavernous Sinus. *AJNR Am J Neuroradiol* 1998; 19: 1081-7.
- [14] Zhong NB, Lv GM, Chen ZH. Stereotactic body radiotherapy combined with transarterial chemoembolization for huge (≥ 10 cm) hepatocellular carcinomas: A clinical study. *Mol Clin Oncol* 2014; 2: 839-44.
- [15] Choi C, Koom WS, Kim TH, Yoon SM, Kim JH, Lee HS, Nam TK, Seong J. A Prospective Phase 2 Multicenter Study for the Efficacy of Radiation Therapy Following Incomplete Transarterial Chemoembolization in Unresectable Hepatocellular Carcinoma. *Int J Radiat Oncol Biol Phys* 2014; 90: 1051-60.