

## Case Report

# Cervical discitis with spinal epidural abscess after percutaneous nucleoplasty: a case report

Ruofeng Yin<sup>1</sup>, Jeremiah Raphael Cohen<sup>2</sup>, Qingsan Zhu<sup>1</sup>, Leichao Zhang<sup>3</sup>, Rui Gu<sup>3</sup>, Hua Xin<sup>4</sup>

Departments of <sup>1</sup>Orthopaedic Surgery, <sup>3</sup>Pathology, <sup>4</sup>Thoracic Surgery, China-Japan Union Hospital, Jilin University, Changchun, China; <sup>2</sup>David Geffen School of Medicine, University of California at Los Angeles, Los Angeles, CA, United States of America

Received June 20, 2016; Accepted August 15, 2016; Epub November 15, 2016; Published November 30, 2016

**Abstract:** Disc space infections are a rare complication that can potentially follow any invasive spinal procedure. Infections of the cervical region, such as epidural abscesses, are particularly rare and should be diagnosed and treated decisively. In this report, we study a 46-year-old male patient with severe neck pain radiating to his left upper extremity after percutaneous cervical Coblation<sup>®</sup> nucleoplasty, a previously undocumented complication. A thorough examination revealed osteomyelitis with an accompanying epidural abscess at the site of related disc. The patient experienced symptomatic relief immediately after emergency debridement and reconstruction of the related segment. Following the administration of culture-sensitive antibiotics and appropriate post-operative management, repeated imaging and physical exam revealed a satisfactory recovery. Taken together, cervical discitis is an infrequent iatrogenic complication with potentially catastrophic sequelae. It is important for understanding potential risks, early diagnosis via physical exam and imaging, and prompt management with open surgical treatment and antibiotic therapy for successful management of this rare complication.

**Keywords:** Spinal epidural abscess, percutaneous nucleoplasty, cervical discitis, coblation nucleoplasty

### Introduction

Disc space infection is a rare complication that can follow any invasive spinal procedure. It is particularly rare in the cervical region and was first described by Turnbull in 1953 [1]. An epidural abscess in the disc space may elicit severe neck pain and neurologic deficits. Post-procedural discitis represents 30.1% of all cases of pyogenic discitis and has been linked to almost every open and minimally invasive spinal procedure including less invasive procedures such as discography [2-6]. Percutaneous cervical nucleoplasty was first reported in 2005 [7], and has been widely used in patients with symptomatic cervical herniated disks [8, 9].

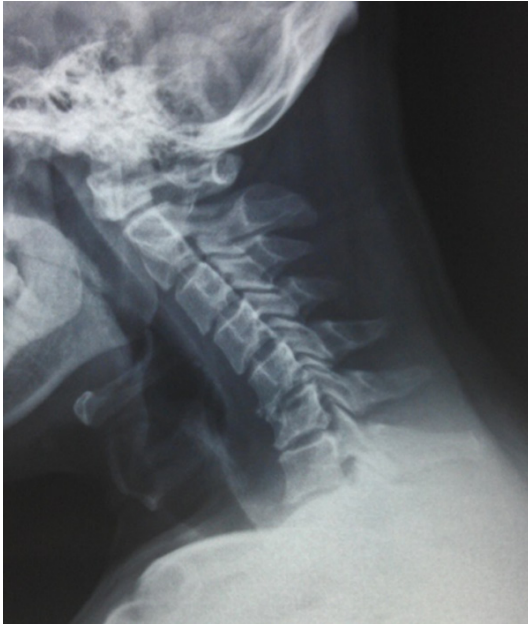Though we believed that the Coblation<sup>®</sup> technique in the treatment of cervical disc disorder is a safe, minimally-invasive procedure with less resulting patient discomfort [10], post operational complications are always possible and should be watched for.

### Case report

A 46-year-old male patient with a noncontributory past medical history underwent percutaneous cervical Coblation<sup>®</sup> nucleoplasty due to neck pain. Three days after the procedure, the patient developed slowly increasingly neck pain with radiation to his left shoulder and hand with seven days after. Cervical bracing was required to support the patient's head and keep his neck in flexion to mitigate the pain. The patient did not develop fever or chills during this period.

Physical examination showed numbness of the left forearm and radial two and a half fingers. Muscle strength from bicep to flexor decrease to IV (-), Visual Analogue Scale (VAS) was 10.

Laboratory examination revealed a white blood cell count of  $18.7 \times 10^9/L$ , and erythrocyte sedimentation rate (ESR) was elevated to 50 mm/h (normal range at 0-20 mm/h), and C-Reactive protein (CRP) elevated to 94.4 mg/L (normal range at <10 mg/L).



**Figure 1.** Segmental kyphotic position due to collapse of C5-6 intervertebral disc.

Lateral neck X-ray showed a disc height loss at C5-6 and C6-7, with the whole cervical spine in an abnormal kyphotic position (**Figure 1**). A follow-up cervical MRI showed signal changes indicating osteomyelitis in the C5 and C6 vertebral bodies with a C5-6 disc space infection and epidural collection (**Figure 2**). A CT scan of the same region revealed a wormy appearance at the involved level (**Figure 3**).

### Treatment

Immediately after the diagnosis was made, the patient was taken to the operating room and put under general anesthesia. An anterior cervical intervertebral disc resection at C5-6 was performed, during which a fistulous channel extending from the disc space to spinal canal was discovered. A standardized anterior cervical decompression was then performed with removal and cleaning of the abscess collection. Afterwards, an anterior titanium cervical internal fixation with an auto-iliac strut bone graft. The wound was closed in layers and drained for 48 hours. A rigid head-neck-chest bracing was prescribed for additional postoperative immobilization. A culture and sensitivity of the purulent material collected intra-operatively revealed *Staphylococcus epidermidis* with sensitivity to ceftriaxone, which was then immediately prescribed.

After surgery, the patient's symptoms of radiating neck pain immediately resolved. The VAS decreased to 3/10 and was proven to have originated from iliac bone harvesting surgical incision. Muscle strength was restored to V 24 hours post operatively. A follow-up MRI at 7 days showed resolution of the epidural collection with no observable signal changes in the C5 and C6 vertebral bodies, and a return to a normal lordotic curvature (**Figure 4**).

### Discussion

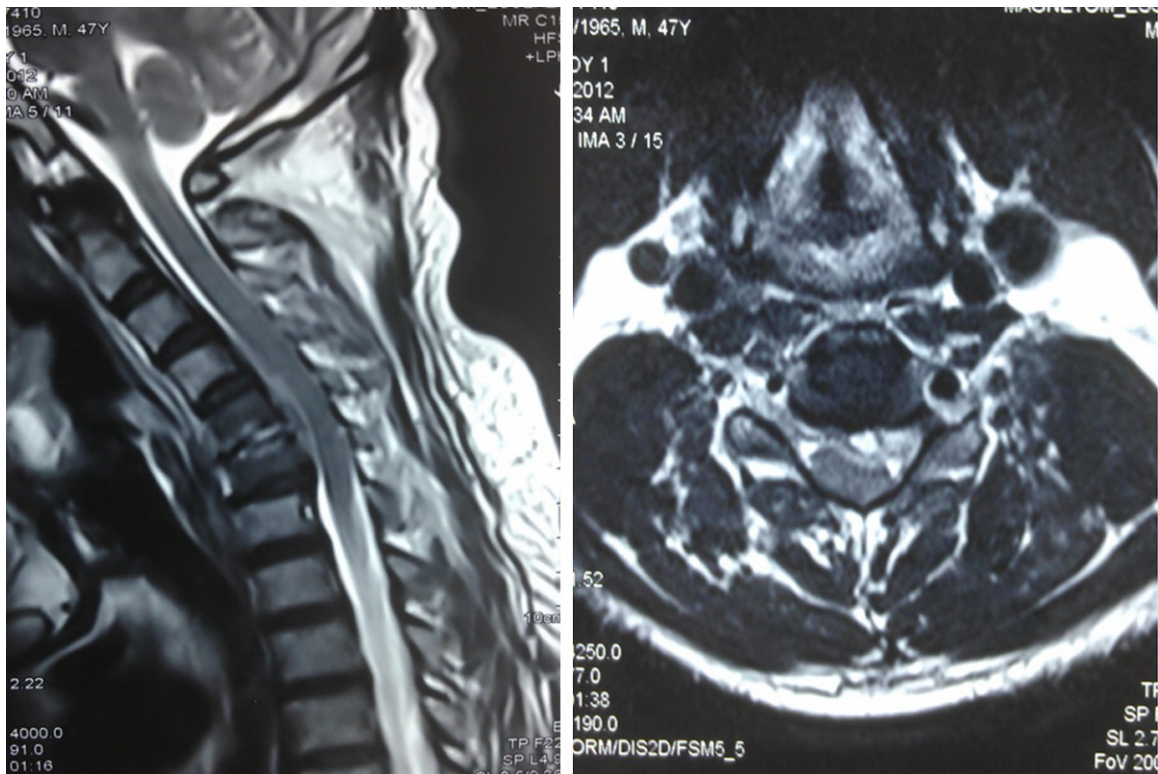
Post-operative infection following direct cervical disc procedures is exceedingly rare [11, 12]. Normal intervertebral discs are largely avascular with nutrition supplied through the vertebral end plates and annular fibrosus via diffusion from capillary plexuses [4, 13]. Additionally, the bone-disc interface is only partially permeable to substrates. The avascular nature of the disc renders it vulnerable to iatrogenic inoculation of bacteria during interventional procedures and makes it particularly difficult to treat with antibiotics alone [4].

Coblation is a new kind of radiofrequency surgery that uses a low reaction temperature to limit the amount of heat delivered to surrounding structures, and was first adopted for treating tonsillar hypertrophy [14]. In 2005, Nardi *et al.* first reported a cervical nucleoplasty with coblation [7]. Lower heat ensures a lower risk of neurological injuries, which makes coblation more popular in minimally invasive nucleoplasty [15, 16].

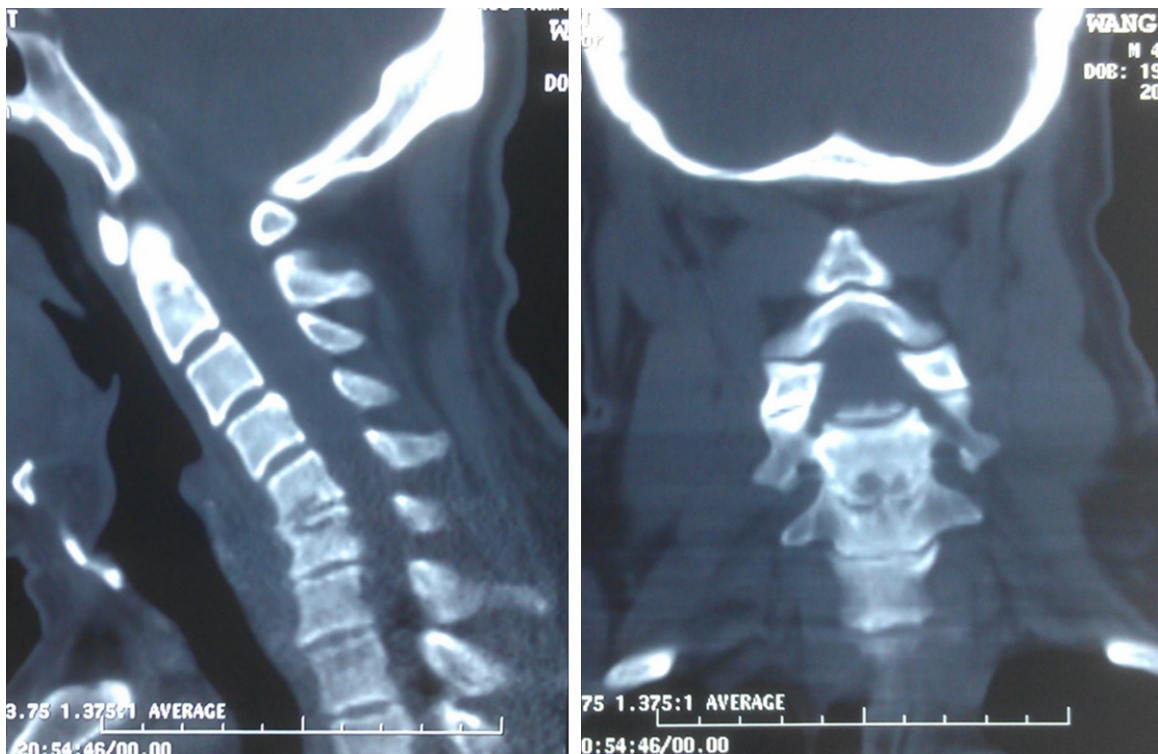
In the development of discitis, osteomyelitis at the involved segment can lead to increased pressure in the disc space. In some patients who undergo nucleoplasty, structural imperfections in the posterior disc or posterior longitudinal ligament can lead to pyogenic fluid drainage into the cervical canal and development of an abscess.

Fever, pain overlying the site of compression, and progressive neurologic deficits has been characterized as the triad sequence of spinal epidural abscess clinical syndrome [17, 18]. Although our patient in this case did not become febrile, he did develop severe neck pain and neurologic symptoms within 3 weeks following nucleoplasty. We therefore suggest that physicians should be aware of the possi-

Cervical discitis with spinal epidural abscess after percutaneous nucleoplasty



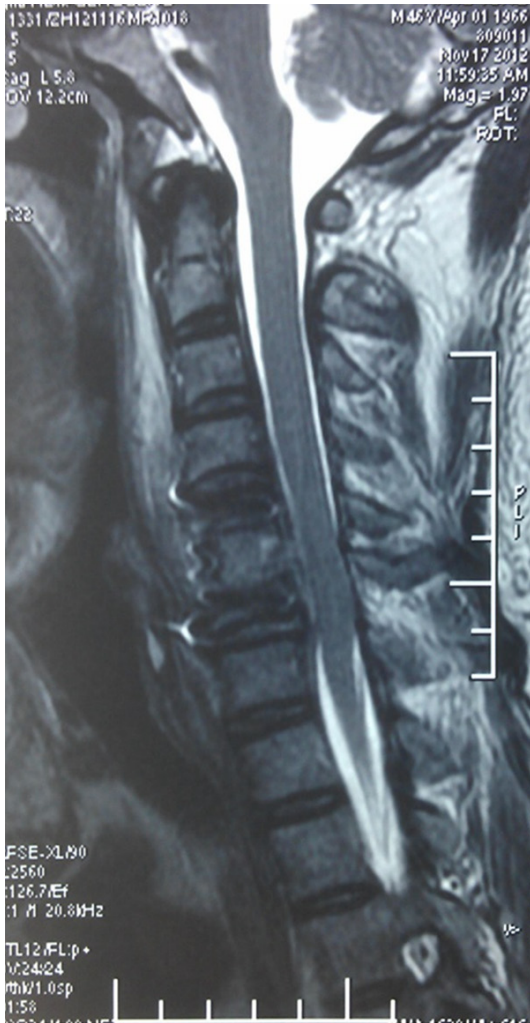**Figure 2.** Cervical MRI image. Left image: signal changes indicating osteomyelitis extend in the C5 and C6 vertebral bodies with a C5-6 disc space infection and epidural collection. Right image: epidural collection to the left side which was in accordance with physical examination findings.



**Figure 3.** Wormy appearance at the involved level indicated osteotomy extension during debridement.



## Cervical discitis with spinal epidural abscess after percutaneous nucleoplasty



**Figure 4.** Follow-up MRI at 7 days showed resolution of the epidural collection with no observable signal changes in the C5 and C6 vertebral bodies, and a return to a normal lordotic curvature.

bility of radiating neck pain, numbness, and weakness in a febrile patient as potential indicators of an underlying disc infection. Once a patient has the related syndrome or suspected discitis, plain radiographs should be obtained to evaluate overall alignment and loss of intervertebral disc space height [19]. CT scan is important to detect destructive lesions in the vertebrae adjacent to the infected disc and accompanied by narrowing of the affected disc space height early in the course of the infection [20]. The result is helpful for volume of vertebrectomy.

An MRI should be obtained to properly determine the spread of infection. Decreased signal intensity in T1 and T2-weighted images typi-

cally coincide with increased signal intensity within the bone marrow of the adjacent vertebral bodies, and are thought to represent edematous changes secondary to an inflammatory process such as osteomyelitis [21]. In this case, the abscess was located immediately posterior to the affected disc at C5-6.

As soon as the diagnosis of an epidural abscess is made, anterior discectomy with drainage of the infected material should be performed as soon as possible. Conservative management may lead to irreversible neurological deficiency or death and should be avoided. During the discectomy and drainage procedure, disc tissue and purulent secretions should be collected and sent for culture and sensitivity analysis.

Radulovic *et al.* reported a cervical spinal epidural abscess after oesophagoscopy where the entire cervical epidural space was irrigated with saline solution delivered through an infant urinary catheter [12]. However, in our case, we opted to mitigate the risk of spinal cord injury and further bacterial inoculation by not irrigating the intra-spinal canal space.

Following a complete debridement of the disc space, posterior longitudinal ligament, and devasted bony endplate, it is important to reconstruct the cervical spine alignment. Auto-graft bone is the most favorable grafting source. Internal or outer instrumentation is necessary to ensure the periodical immobilization. Modern titanium internal fixation has been proven to have resistant effect to bacterial adherence than any other previous metals [12]. Giuseppe *et al.* also proved that synthetic materials are safe and effective for reconstruction during the acute infection phase [22]. The goal of surgery is to remove the infected disc, debride all necrotic and/or infected bone, and provide stabilization with bone graft. This often consists of aggressive anterior corpectomy and autologous bone graft reconstruction. Titanium plate and screws were used in our case to ensure strut grafting in position and allowed the patient to stand up early after the procedure.

Post-operative discitis with epidural abscess is a rare complication that can potentially follow any spinal procedure. Clinicians should be aware of classical symptoms such as decreases in neurologic function and fever follow-

## Cervical discitis with spinal epidural abscess after percutaneous nucleoplasty

ing percutaneous procedures on the cervical disc. Following the diagnosis of an epidural abscess via clinical signs and imaging, emergent management with surgical debridement, culture and sensitivity, and antibiotic therapy should be initiated to prevent permanent neurologic sequelae.

### Disclosure of conflict of interest

None.

**Address correspondence to:** Hua Xin, Department of Thoracic Surgery, China-Japan Union Hospital, Jilin University, 126 Xiantai Street, Changchun 130033, China. E-mail: xinhua1011@126.com

### References

- [1] Turnbull F. Postoperative inflammatory disease of lumbar discs. *J Neurosurg* 1953; 10: 469-473.
- [2] Basu S, Ghosh JD, Malik FH and Tikoo A. Postoperative discitis following single-level lumbar discectomy: Our experience of 17 cases. *Indian J Orthop* 2012; 46: 427-433.
- [3] Fernand R and Lee CK. Postlaminectomy disc space infection. A review of the literature and a report of three cases. *Clin Orthop Relat Res* 1986; 215-218.
- [4] Sharma SK, Jones JO, Zeballos PP, Irwin SA and Martin TW. The prevention of discitis during discography. *Spine J* 2009; 9: 936-943.
- [5] Kapoor SG, Huff J and Cohen SP. Systematic review of the incidence of discitis after cervical discography. *Spine J* 2010; 10: 739-745.
- [6] Lemcke J, Al-Zain F, Mutze S and Meier U. Minimally invasive spinal surgery using nucleoplasty and the Dekompressor tool: a comparison of two methods in a one year follow-up. *Minim Invasive Neurosurg* 2010; 53: 236-242.
- [7] Nardi PV, Cabezas D and Cesaroni A. Percutaneous cervical nucleoplasty using coblation technology. Clinical results in fifty consecutive cases. *Acta Neurochir Suppl* 2005; 92: 73-78.
- [8] Li J, Yan DL and Zhang ZH. Percutaneous cervical nucleoplasty in the treatment of cervical disc herniation. *Eur Spine J* 2008; 17: 1664-1669.
- [9] Halim W, Wullems JA, Lim T, Aukes HA, van der Weegen W, Vissers KC, Gultuna I and Chua NH. The long-term efficacy and safety of percutaneous cervical nucleoplasty in patients with a contained herniated disk. *Pain Pract* 2013; 13: 364-371.
- [10] Wullems JA, Halim W and van der Weegen W. Current evidence of percutaneous nucleoplasty for the cervical herniated disk: a systematic review. *Pain Pract* 2014; 14: 559-569.
- [11] Metcalfe S and Morgan-Hough C. Cervical epidural abscess and vertebral osteomyelitis following non-traumatic oesophageal rupture: a case report and discussion. *Eur Spine J* 2009; 18 Suppl 2: 224-227.
- [12] Radulovic D and Vujotic L. Cervical spinal epidural abscess after oesophagoscopy. *Eur Spine J* 2013; 22 Suppl 3: S369-372.
- [13] Willems PC, Jacobs W, Duinkerke ES and De Kleuver M. Lumbar discography: should we use prophylactic antibiotics? A study of 435 consecutive discograms and a systematic review of the literature. *J Spinal Disord Tech* 2004; 17: 243-247.
- [14] Temple RH and Timms MS. Paediatric coblation tonsillectomy. *Int J Pediatr Otorhinolaryngol* 2001; 61: 195-198.
- [15] Zhu H, Zhou XZ, Cheng MH, Luo ZP and Ai HZ. Coblation nucleoplasty for adjacent segment degeneration after posterolateral fusion surgery: a case report. *J Back Musculoskelet Rehabil* 2012; 25: 235-238.
- [16] Azzazi A, AlMekawi S and Zein M. Lumbar disc nucleoplasty using coblation technology: clinical outcome. *J Neurointerv Surg* 2011; 3: 288-292.
- [17] Lam KS, Pande KC and Mehdian H. Surgical decompression: a life-saving procedure for an extensive spinal epidural abscess. *Eur Spine J* 1997; 6: 332-335.
- [18] Ersahin Y. Spinal epidural abscess: a meta-analysis of 915 patients. *Neurosurg Rev* 2001; 24: 156.
- [19] Silber JS, Anderson DG, Vaccaro AR, Anderson PA, McCormick P; NASS. Management of post-procedural discitis. *Spine J* 2002; 2: 279-287.
- [20] Wang XY, Hu JZ, Liu WH and Li KH. [Diagnosis and treatment of postoperative intervertebral infectio]. *Zhong Nan Da Xue Xue Bao Yi Xue Ban* 2006; 31: 111-113.
- [21] Boden SD, Davis DO, Dina TS, Sunner JL and Wiesel SW. Postoperative diskitis: distinguishing early MR imaging findings from normal postoperative disk space changes. *Radiology* 1992; 184: 765-771.
- [22] D'Aliberti G, Talamonti G, Villa F and Debernardi A. The anterior stand-alone approach (ASAA) during the acute phase of spondylodiscitis: results in 40 consecutively treated patients. *Eur Spine J* 2012; 21 Suppl 1: S75-82.