

Case Report

Onyx embolization and surgical removal as a treatment for hemorrhagic AVM in a hybrid operating room

Jinlu Yu, Yunbao Guo, Baofeng Xu, Xuan Chen, Kan Xu

Department of Neurosurgery, First Hospital of Jilin University, Changchun 130021, China

Received July 20, 2016; Accepted September 15, 2016; Epub November 15, 2016; Published November 30, 2016

Abstract: A ruptured intracranial arteriovenous malformation (AVM) is difficult to treat. Embolization and resection of the ruptured AVM in a hybrid operating room is an effective treatment, but it has not been thoroughly studied. The current study reviewed 8 cases of AVM that were treated with this method. Four of the cases involved male patients, and 4 of the cases involved female patients, with the patients' ages ranging from 16 to 73 years old. The Hunt-Hess classification was grade II for 4 of the cases and grade III for the other 4 cases. All cases began with a cerebral hemorrhage. Digital subtraction angiography (DSA) was performed after the initial diagnosis of AVM, and 3 cases were accompanied by an aneurysm in the feeding artery. AVMs were first embolized with Onyx in a hybrid operating room and then removed via craniotomy surgery. In 1 case of AVM, most of the AVM was removed and the drainage vein was residual, while in the other 7 cases, the area was completely removed. Postoperative DSA showed no remnant of AVM in any of the 8 cases. Three cases were accompanied by flow-related aneurysms. The aneurysms were near the AVM in 2 of the cases, so they were also embolized with Onyx during embolization of the AVM. In the other case, there were 2 aneurysms in the feeding arteries that were far from the AVM. The blood flow was reduced after total resection of the AVM, so this case required follow-up. The patients were followed for six months to 1 year after the procedure, and their Glasgow Outcome Scale (GOS) scores were used for the evaluation. Four of the patients had a GOS score of 5, and the other four patients had a score of 4. Therefore, for a ruptured hemorrhagic AVM, embolization with Onyx before the operation can reduce the AVM blood flow, reduce operative risks, and yield a satisfactory therapeutic effect.

Keywords: Hemorrhagic AVM, Onyx, embolization, hybrid operating room

Introduction

Intracranial arteriovenous malformation (AVM) is a neurosurgical disease that is difficult to treat, especially in cases where the AVM ruptures [1]. For a ruptured AVM, endovascular intervention could be a treatment option to embolize the ruptured section of the AVM. This procedure results in hemodynamic changes of the AVM and redistribution of blood flow, and it carries the risk of hemorrhagic AVM recurrence [2]. Therefore, the most radical approach is a radical resection of the ruptured AVM. In most cases, the risks for surgery on a small AVM are low, while direct surgical removal of a large and complex AVM is a high-risk procedure [3]. Preoperative embolization could effectively reduce the difficulties involved in the surgical removal of a ruptured hemorrhagic AVM, and this treatment is also easy to implement in a hybrid operating room. Many neuro-

surgery centers are already equipped for digital subtraction angiography (DSA) in their modern operating rooms, and hybrid operating rooms have become very popular [4, 5]. Currently, there are few studies that have been conducted on the removal of ruptured AVMs after embolization in a hybrid operating room. Therefore, the current study retrospectively summarized 8 cases of patients who were successfully treated in the Department of Neurosurgery, First Hospital of Jilin University, with the goal of improving the understanding of this type of treatment.

Material and methods

General information

This study included 8 patients with hemorrhagic AVM who were treated at The Department of Neurosurgery of the First Hospital of Jilin Uni-

Onyx embolization and surgical removal as a treatment for hemorrhagic AVM

Table 1. Summary of the information from the clinical cases

No.	Age	Gender	Onset	HH	AVM location	SM classification	Accompanied by aneurysm	AVM embolization	Degree of resection	Postoperative DSA	GOS
1	16	F	IH involving ventricle	III	Left frontal lobes	3	1 aneurysm of the blood supply artery, Onyx embolization	Majority embolization	Most portions were resected, with the venous end residual	No development of AVM	5
2	73	M	Subarachnoid hemorrhage and fourth ventricle hemorrhage	III	Left cerebellar hemisphere	2	1 aneurysm of the blood supply artery, Onyx embolization	Majority embolization	Total resection	No development of AVM	5
3	35	F	IH	II	Leftfronto-parietal lobes	4	2 aneurysms of the blood supply artery, no treatment	Minority embolization	Total resection	No development of AVM	4
4	53	M	IH	III	Left fronto-parietal lobes	3	No	Majority embolization	Total resection	No development of AVM	4
5	48	F	IH	II	Left parietal lobe	2	No	Near-total embolization	Total resection	No development of AVM	5
6	24	F	IH involving ventricle	III	Right fronto-parietal lobes	2	No	Near-total embolization	Total resection	No development of AVM	4
7	52	M	IH	II	Right parietal lobe	1	No	Minority embolization	Total resection	No development of AVM	4
8	37	M	IH	II	Right cerebellar hemisphere	1	No	Majority embolization	Total resection	No development of AVM	5

HH: Hunt-Hess grade; AVM: Arteriovenous malformation; SM grading: Spetzler-Martin grading; GOS: Glasgow Outcome Scale; IH: Intracerebral hematoma.

Onyx embolization and surgical removal as a treatment for hemorrhagic AVM

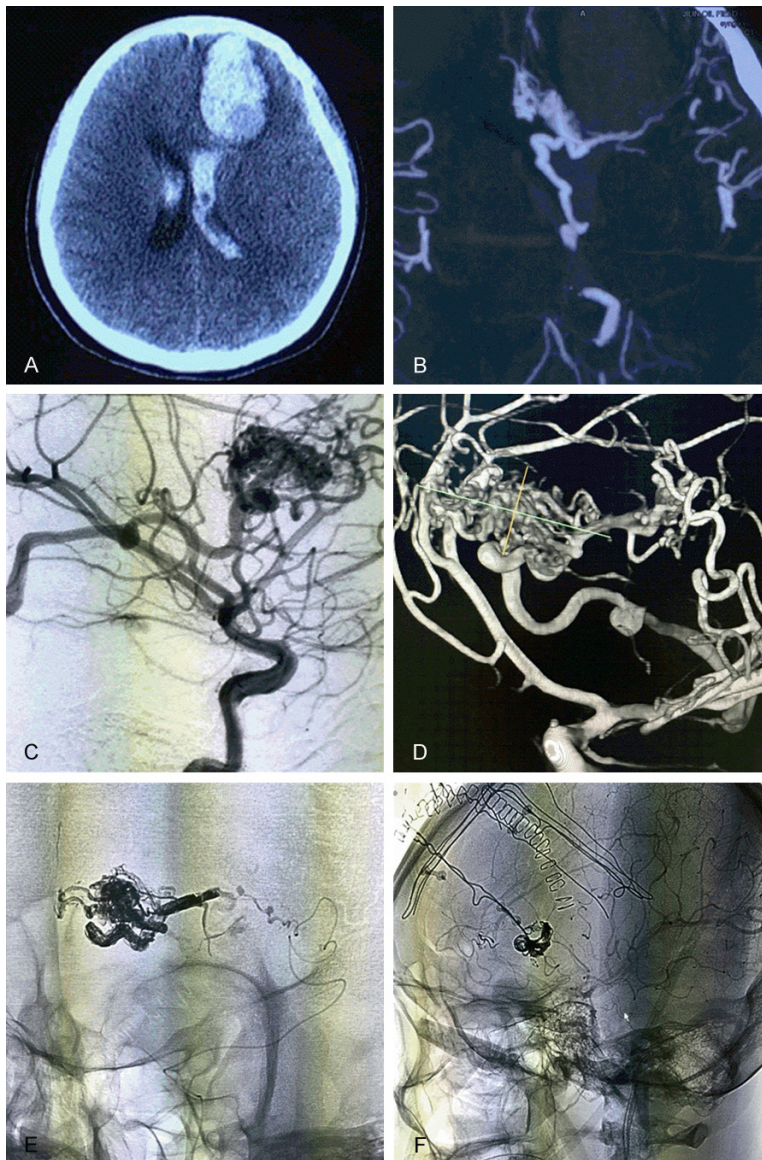


Figure 1. Images from case 1. A: Head CT shows hemorrhage of the left frontal lobe that breaks into the ventricle; B: Head CTA shows an AVM in the frontal lobe, which is fed by the MMA and ACA and drains into the ventricle; C, D: Head DSA examination shows that the AVM was introduced into the straight sinus via the internal cerebral vein, and an aneurysm was found in the blood supply artery; E: Onyx glue was used to embolize most of the AVM; F: Angiography after the craniotomy removal of the AVM shows the venous drainage end of the residual embolism, but an AVM did not develop.

versity from January 2015 to January 2016. All 8 patients underwent interventional embolization in a hybrid operating room before craniotomy for resection of their AVMs. Four of the patients were male, and four patients were female, with ages ranging from 16 to 73 years (average, 42.3 years). Computed tomography (CT) examination after onset showed intracerebral hematomas in 4 patients, intracerebral hematomas involving ventricles in 2 patients,

an intraventricular hemorrhage in 1 patient, and a subarachnoid hemorrhage with a fourth ventricle hemorrhage in 1 patient. According to the Hunt-Hess classification, 4 of the patients were class II and 4 were class III. Detailed clinical data are shown in **Table 1**.

Imaging examinations

Patients underwent computed tomography angiography (CTA) and DSA after onset to definitively diagnose AVM, to observe the location of the AVM and its relationship with the surrounding functional regions, and to measure the size of the AVM. DSA was used to observe both the anterior and posterior circulation simultaneously to determine the source of the feeding arteries, whether the feeding arteries were accompanied by aneurysms, the degree to which venous drainage was obstructed, and whether deep venous drainage was present. The locations of the AVMs were as follows: frontal lobe, 1 case; fronto-parietal lobe, 3 cases; temporal lobe, 2 cases; cerebellum, 2 cases; and feeding arteries, 3 cases. The Spetzler-Martin (SM) classification was used to assess the AVMs as follows: 2 cases were classified as 1 point, 3 cases as 2 points, 2 cases as 3 points, and 1 case as 4 points.

Surgical treatment

Using DSA to observe the structure and hemodynamics of the AVM, the best working angle to expose the direction of the major feeding arteries and embolize the AVM was selected. A Marathon microcatheter was introduced into the feeding arteries, approximately 0.23 ml of DMSO was injected when the catheter tip was near the nidus of the AVM, and Onyx was then injected under the roadmap for the AVM embolization. Other feeding arteries could be select-

Onyx embolization and surgical removal as a treatment for hemorrhagic AVM

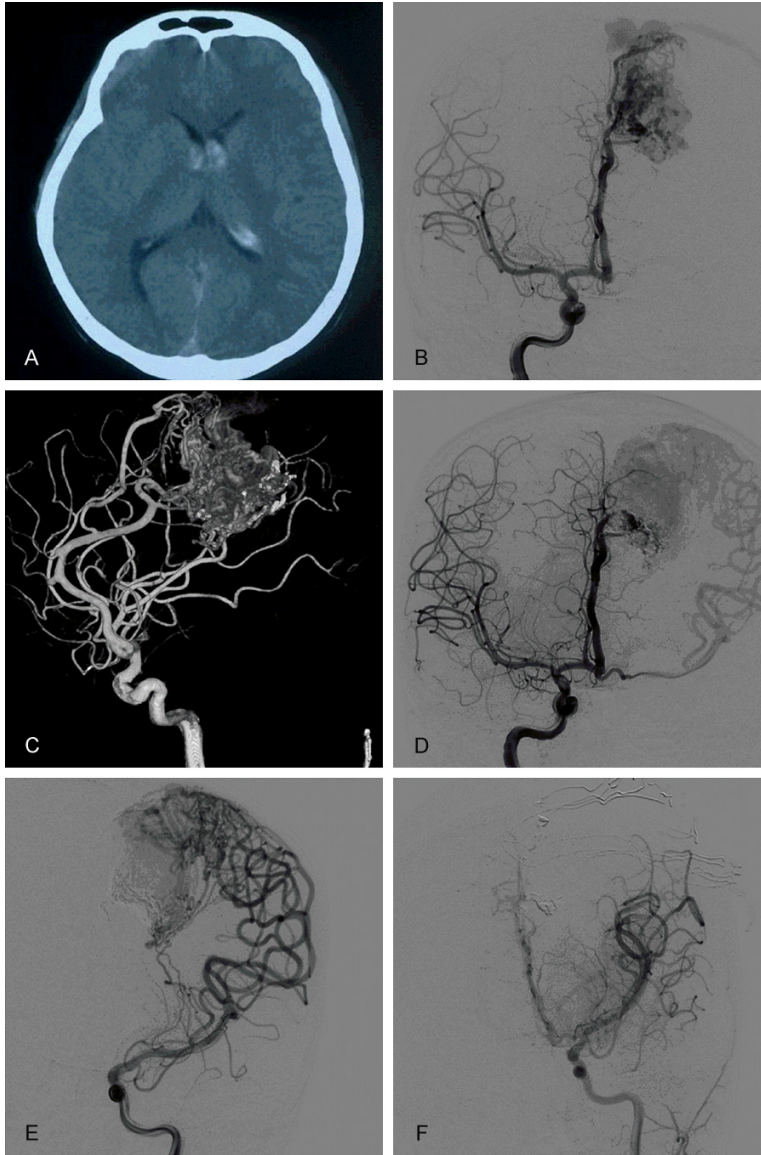


Figure 2. Images from case 3. A: Head CT shows bilateral ventricle hemorrhages that are greater on the left side; B: Right internal carotid artery DSA shows that the AVM was supplied by the distal end of the left ACA and that the AVM was located in the left frontal and parietal lobes; C: 3D-DSA shows 2 aneurysms on the genu of the corpus callosum of the left ACA; D: Embolization of the AVM with Onyx via the ACA and DSA showing a reduction of the AVM volume; E: Left MCA angiography shows part of the AVM located laterally, which was supplied by the cortex of the MCA, and the wedge lenticulostriate artery also participated in the blood supply; an aneurysm is shown at the end of the lenticulostriate artery, which was part of the AVM that was not embolized; F: DSA shows total resection of the AVM after embolization of the medial AVM.

ed for embolization in the case of unsatisfactory embolization of the AVM nidus, and embolization was stopped when the blood flow of the AVM was noticeably reduced or when the embolization was satisfactory. Dyna CT or Xper

CT was performed after embolization to determine AVM positioning, and the appropriate surgical approach was then selected based on the site of the AVM. The AVM was removed along the boundary, and repeat DSA or CT examinations could be performed during the surgery to observe the resection of the AVM and the presence of residual hematomas. DSA was used at the end of the surgery to determine whether the AVM was completely removed.

Postoperative treatment and follow-up

Each patient was given symptomatic treatments postoperatively. A routine head CT was performed to detect the presence of any postoperative complications, such as surgical cavity bleeding or encephaledema and infarction, and to closely observe the changes in the disease condition. In cases where the condition was aggravated, the patient underwent a CT exam and symptomatic treatments. Patients were followed for half a year, and the Glasgow Outcome Scale (GOS) was used for assessments.

Results

The treatment of AVM

Eight cases of AVM were embolized with Onyx (including minority partial embolization in 2 of the cases, majority partial embolization in 3 of the cases, and subtotal embolization in 3 of the cases). Then, the 8 patients underwent resection of the AVM (resection of most of the area with residual drainage in the venous end in 1 case and total removal in the 7 other cases). Postoperative DSA examination

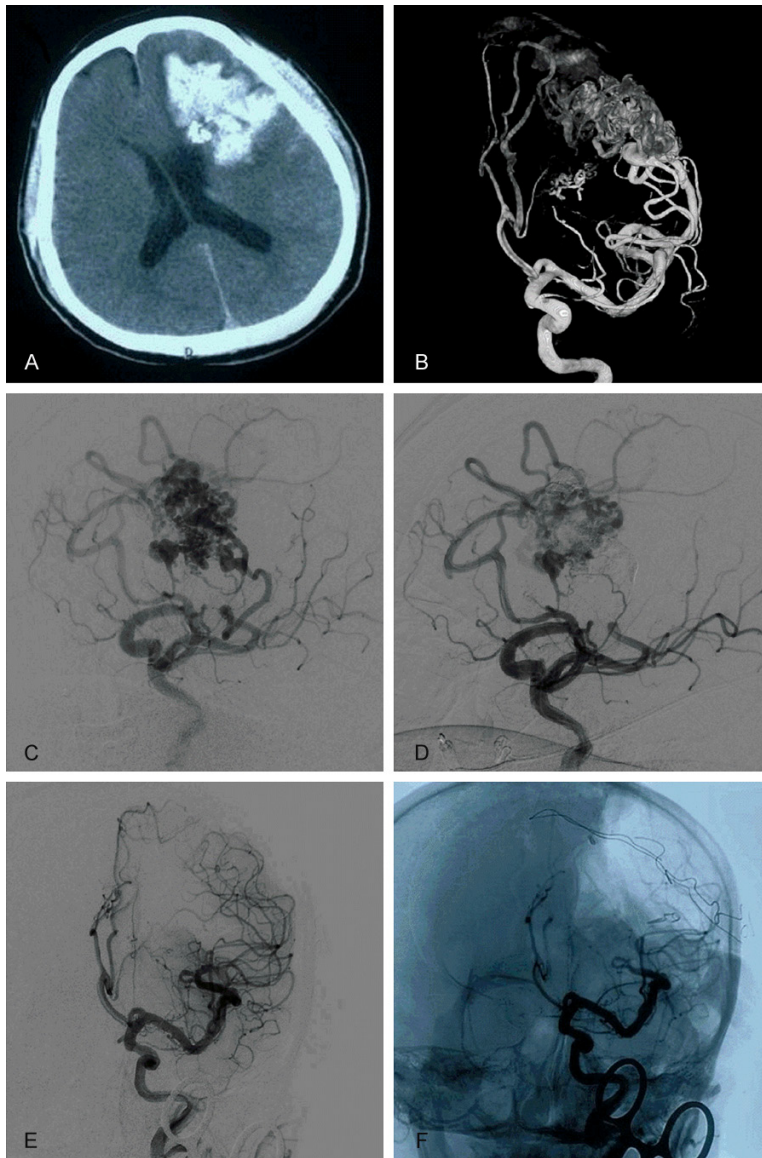


Figure 3. Images from the patient in case 4. A: Head CT shows the hematoma in the left fronto-parietal lobe; B: Head 3D-DSA shows the AVM in the left fronto-parietal lobe, which is fed by the ACA and MCA at the end, and participation of the left lenticulostriate artery in the blood supply; C: The blood supply artery of the AVM is located at the optimal projection angle; D: The AVM was completely embolized with the best working angle; E, F: DSA immediately after the operation shows total resection of the AVM.

showed no development of any new AVMs in any of the patients.

Treatments of aneurysms of the merged feeding artery

Among the 8 patients with AVM, 3 had a flow-related aneurysm in the feeding arteries, and in 2 of these cases, the aneurysms were near the AVM and were subsequently also blocked with

Onyx during the embolization of the AVM. In another case, the feeding artery had two aneurysms that were far from the AVM. The blood flow of the aneurysms was decreased after removal of the AVM, so they were not treated; however, regular observations were made of them following the procedure.

Follow-up results

The GOS was used for the follow-up assessments. The patients were followed for six months to one year after the procedure. The GOS scores were 5 points for 4 of the cases and 4 points for the other 4 cases. Treatment and follow-up results are shown in **Table 1**. Typical cases are shown in **Figures 1-4**.

Discussion

Intracranial AVM is a common cerebrovascular disease that is difficult to treat because of the associated large blood flow. When the volume of the AVM is large, a simple surgical resection carries a higher risk of intraoperative hemorrhage or even hemorrhagic shock; AVMs that are deeply located are difficult to excise via surgery while retaining important functional areas [6]. Furthermore, it is difficult to completely embolize an AVM with endovascular embolization [7]. Additionally, thorough treatment should be provided, especially in cases with intracranial AVM ruptures and hemorrhages, because partial incisions or incomplete embolizations cannot ensure the prevention of postoperative bleeding for ruptured AVMs [8]. Surgery can eliminate AVM but has high risks; endovascular embolization is safer, but it is difficult to thoroughly embolize an AVM with this procedure. Therefore, a combination of surgery and interventional embolization

Onyx embolization and surgical removal as a treatment for hemorrhagic AVM

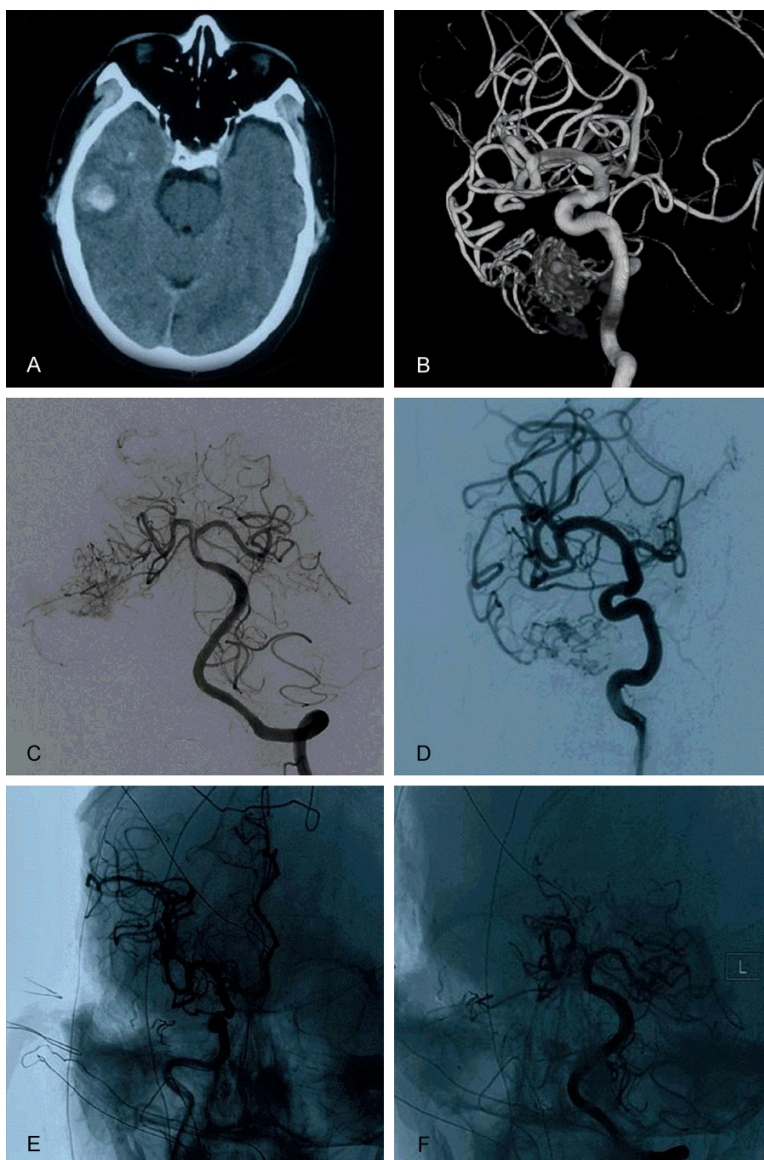


Figure 4. Images of the patient in case 7. A: Head CT shows the hematoma in the right temporal lobe; B: 3D-DSA of the right internal carotid artery shows the AVM in the right temporal lobe, which is fed by the inferior terminal of the MCA; C: Vertebral artery angiography shows that the distal branch of the right PCA is also involved in the blood supply; D: The AVM was partially embolized through the blood supply branch of the MCA; E, F: DSA immediately after the operation shows total resection of the AVM.

should provide better treatment for AVM [9]. However, there are currently few studies on this subject. Therefore, the current study summarized 8 cases of patients who underwent interventional embolization before craniotomy and resection in 2015 in a hybrid operating room.

The concept of hybridization has been suggested repeatedly over time. Initially, because of equipment limitations and limitations of inter-

vention technologies, only intraoperative angiography was available during operations to treat AVM, which is very convenient for use during AVM resections [10]. Sometimes, it can be difficult to find the boundary of a big AVM during surgery, so intraoperative DSA could help accurately distinguish the boundary of the AVM and identify unexpected residual AVMs in these cases. Munshi et al. conducted an intraoperative DSA study involving 25 cases of AVM in 1999, with intraoperative DSA showing residual AVMs in 2 of the cases after resection, corresponding to an incidence of 8%. Therefore, intraoperative DSA also has important applications and value during early AVM resections [11]. In addition to having the ability to provide intraoperative DSA, modern DSA machines also have the functionality of CT. For example, Dyna CT (Siemens) and Xper CT (Philips) can aid in preoperative and intraoperative localization of AVMs and can help determine whether a hematoma combined with an AVM is clearly removed or whether there is new bleeding during the operation [12]. They can merge intraoperative CT with arteriovenous malformations to form 3D images and are easy to implement in a modern hybrid operating room [13]. Among

the 8 cases in the current study, the location of the AVM in case 3 was confirmed several times prior to total resection with DSA inspection because its MMA was diffuse and the boundary was unclear. Additionally, Xper CT was used multiple times to detect the presence of bleeding.

There are many methods of treating intracranial AVM, including surgical resection, emboliza-

tion, and radiation therapy; however, in some cases, the use of a single method is not effective in treating AVM [14]. For an AVM with a higher SM grade, a combination therapy is recommended, such as partial embolization + radiotherapy or surgical resection + radiation therapy for the residuals [8, 15]. However, a combination of embolization and radiotherapy or radiotherapy after resection mainly targets non-ruptured AVMs [16]. After an AVM has ruptured, the best treatment is to completely remove it [17]. Simple surgical excision can easily treat ruptured AVMs of Spetzler-Martin grades I and II [18]. However, for complex AVMs, endovascular embolization before surgical resection may be a more promising treatment. Some AVMs can comprise several compartments, each of which may be supplied by different arteries. When some of the feeding arteries are fine and the AVM is relatively diffuse, embolization is difficult via interventional treatment; if the compartments that cannot be embolized are ruptured and hemorrhagic, embolization of other parts of the AVM may not have a therapeutic effect. In contrast, embolization of the other compartments that can be embolized can reduce the difficulty of an AVM resection and can ultimately provide opportunities for resection. In cases 1 and 4 in the current study, there were multiple feeding arteries in the AVMs and the ruptured and hemorrhagic portions could be removed only by surgical resection; therefore, the other parts needed to be embolized before the AVM could be completely removed.

Materials that are used for the embolization of AVMs are primarily NBCA and Onyx. Onyx is more widely applied, is a non-adhesive liquid embolic material, and can effectively embolize AVMs [19]. The embolization method in combination with surgical removal in a hybrid operating room may be different from the simple application of interventional embolization of an AVM. Preoperative embolization in combination with the surgical removal of an AVM does not emphasize radical embolization of the nidus; instead, the primary goal of this procedure should be embolization of the feeding arteries to reduce the blood flow of the AVM, as this can reduce intraoperative bleeding and excessive perfusion syndrome. For parts of the AVM that cannot be embolized, such as some fine feeding arteries, the risks that accompany surgical

resection of the AVM are not very high. In the 8 patients in this study, the surgical resection was easy after embolization with the described methods. It is important to note that 3 cases in this study had aneurysms in the feeding arteries, which were related to blood flow and mainly due to the high blood pressure of the feeding artery [20]. Regarding treatment for this type of aneurysm, if the aneurysm is near the AVM, it can be embolized along with embolization of the AVM; however, if the aneurysm is far from the AVM, it can be observed via follow-ups. One study found that an aneurysm in the feeding artery can disappear after resection of an AVM [21]. Among the 8 cases in this study, 3 cases involved aneurysms in the feeding arteries in addition to the AVM, including 2 cases with aneurysms near the AVM that were embolized and another case with an aneurysm far from the AVM, which was treated conservatively because of slowed blood flow after the total resection of the AVM. Thus, for ruptured and hemorrhagic AVMs, preoperative embolization with Onyx can reduce blood flow to the AVM, thereby reducing the risks of the surgery and providing a satisfactory therapeutic effect.

Disclosure of conflict of interest

None.

Address correspondence to: Kan Xu and Xuan Chen, Department of Neurosurgery, First Hospital of Jilin University, 71 Xinmin Avenue, Changchun 130021, China. E-mail: jlyu@jlu.edu.cn

References

- [1] Gross BA and Du R. Diagnosis and treatment of vascular malformations of the brain. *Curr Treat Options Neurol* 2014; 16: 279.
- [2] Crowley RW, Ducruet AF, McDougall CG and Albuquerque FC. Endovascular advances for brain arteriovenous malformations. *Neurosurgery* 2014; 74 Suppl 1: S74-82.
- [3] Ajiboye N, Chalouhi N, Starke RM, Zanaty M and Bell R. Cerebral arteriovenous malformations: evaluation and management. *Scientific-WorldJournal* 2014; 2014: 649036.
- [4] Fandino J, Taussky P, Marbacher S, Muroi C, Diepers M, Fathi AR and Remonda L. The concept of a hybrid operating room: applications in cerebrovascular surgery. *Acta Neurochir Suppl* 2013; 115: 113-117.
- [5] Murayama Y, Arakawa H, Ishibashi T, Kawamura D, Ebara M, Irie K, Takao H, Ikeuchi S,

Onyx embolization and surgical removal as a treatment for hemorrhagic AVM

- Ogawa T, Kato M, Kajiwara I, Nishimura S and Abe T. Combined surgical and endovascular treatment of complex cerebrovascular diseases in the hybrid operating room. *J Neurointerv Surg* 2013; 5: 489-493.
- [6] Martinez JL and Macdonald RL. Surgical Strategies for Acutely Ruptured Arteriovenous Malformations. *Front Neurol Neurosci* 2015; 37: 166-181.
- [7] Crimmins M, Gobin YP, Patsalides A and Knopman J. Therapeutic management of cerebral arteriovenous malformations: a review. *Expert Rev Neurother* 2015; 15: 1433-1444.
- [8] Ding D, Xu Z, Shih HH, Starke RM, Yen CP and Sheehan JP. Stereotactic Radiosurgery for Partially Resected Cerebral Arteriovenous Malformations. *World Neurosurg* 2016; 85: 263-272.
- [9] Natarajan SK, Ghodke B, Britz GW, Born DE and Sekhar LN. Multimodality treatment of brain arteriovenous malformations with microsurgery after embolization with onyx: single-center experience and technical nuances. *Neurosurgery* 2008; 62: 1213-1225; discussion 1225-1216.
- [10] Martin NA, Bentson J, Vinuela F, Hieshima G, Reicher M, Black K, Dion J and Becker D. Intraoperative digital subtraction angiography and the surgical treatment of intracranial aneurysms and vascular malformations. *J Neurosurg* 1990; 73: 526-533.
- [11] Munshi I, Macdonald RL and Weir BK. Intraoperative angiography of brain arteriovenous malformations. *Neurosurgery* 1999; 45: 491-497; discussion 497-499.
- [12] Srinivasan VM, Schafer S, Ghali MG, Arthur A and Duckworth EA. Cone-beam CT angiography (Dyna CT) for intraoperative localization of cerebral arteriovenous malformations. *J Neurointerv Surg* 2016; 8: 69-74.
- [13] Kotowski M, Sarrafzadeh A, Schatlo B, Boex C, Narata AP, Pereira VM, Bijlenga P and Schaller K. Intraoperative angiography reloaded: a new hybrid operating theater for combined endovascular and surgical treatment of cerebral arteriovenous malformations: a pilot study on 25 patients. *Acta Neurochir (Wien)* 2013; 155: 2071-2078.
- [14] Lawton MT, Rutledge WC, Kim H, Stapf C, Whitehead KJ, Li DY, Krings T, terBrugge K, Kondziolka D, Morgan MK, Moon K and Spetzler RF. Brain arteriovenous malformations. *Nat Rev Dis Primers* 2015; 1: 15008.
- [15] Oermann EK, Ding D, Yen CP, Starke RM, Bederson JB, Kondziolka D and Sheehan JP. Effect of Prior Embolization on Cerebral Arteriovenous Malformation Radiosurgery Outcomes: A Case-Control Study. *Neurosurgery* 2015; 77: 406-417; discussion 417.
- [16] Nerva JD, Mantovani A, Barber J, Kim LJ, Rockhill JK, Hallam DK, Ghodke BV, Sekhar LN. Treatment outcomes of unruptured arteriovenous malformations with a subgroup analysis of ARUBA (A Randomized Trial of Unruptured Brain Arteriovenous Malformations)-eligible patients. *Neurosurgery* 2015; 76: 563-570; discussion 570; quiz 570.
- [17] Hartmann A and Mohr JP. Acute management of brain arteriovenous malformations. *Curr Treat Options Neurol* 2015; 17: 346.
- [18] Reitz M, von Spreckelsen N, Vettorazzi E, Burkhardt T, Grzyska U, Fiehler J, Schmidt NO, Westphal M and Regelsberger J. Angioarchitectural risk factors for hemorrhage and clinical long-term outcome in pediatric patients with cerebral arteriovenous malformations. *World Neurosurg* 2016; 89: 540-51.
- [19] Elsenousi A, Aletich VA and Alaraj A. Neurological outcomes and cure rates of embolization of brain arteriovenous malformations with n-butyl cyanoacrylate or Onyx: a meta-analysis. *J Neurointerv Surg* 2016; 8: 265-272.
- [20] Alexander MD, Cooke DL, Hallam DK, Kim H, Hetts SW and Ghodke BV. Less can be more: Targeted embolization of aneurysms associated with arteriovenous malformations unsuitable for surgical resection. *Interv Neuroradiol* 2016; 22: 445-51.
- [21] He L, Gao J, Thomas AJ, Fusco MR and Ogilvy CS. Disappearance of a Ruptured Distal Flow-Related Aneurysm after Arteriovenous Malformation Nidal Embolization. *World Neurosurg* 2015; 84: 1496, e1491-1496.