

## Original Article

# Drebrin is a potential diagnostic biomarker for breast cancer

Wenjun Chen<sup>1\*</sup>, Guoping Liu<sup>2\*</sup>, Mei Jin<sup>3</sup>, Peixin Ju<sup>4</sup>, Jianfang Xu<sup>5</sup>, Yong Zhang<sup>6</sup>, Hongwei Zhang<sup>7</sup>

<sup>1</sup>Department of Surgical Oncology, Sir Run Run Shaw Hospital, Zhejiang University College of Medicine, Hangzhou, Zhejiang, China; <sup>2</sup>Department of Thyroid and Breast Surgery, Changhai Hospital, Shanghai, China; <sup>3</sup>Department of Pathology, Sir Run Run Shaw Hospital, Zhejiang University College of Medicine, Hangzhou, Zhejiang, China; <sup>4</sup>Department of General Surgery, Panjin Central Hospital, Panjin, China; <sup>5</sup>Department of Pathology, Zhongshan Hospital, Fudan University, Shanghai, China; <sup>6</sup>Department of Pathology, Cancer Hospital of China Medical University/Liaoning Cancer Hospital & Institute, Shenyang, Liaoning, China; <sup>7</sup>Department of General Surgery, Zhongshan Hospital, Fudan University, Shanghai, China. \*Co-first authors.

Received July 18, 2016; Accepted September 10, 2016; Epub December 15, 2016; Published December 30, 2016

**Abstract:** Breast cancer (BC) is the leading cause of death among solid tumors in women. Although new therapeutic agents have been developed since few decades ago, many patients still died of the disease due to relapse. Because of the mutations and dysregulated expression in multiple genes are closely associated with development, metastasis and prognosis of BC. Novel molecular markers for precise diagnosis of BC are expected. Drebrin is an actin-binding protein involved in the regulation of actin filament organization, and plays a significant role in cell motility. So far, there have been several studies reporting that Drebrin is up-regulated in colorectal cancer, recurrent non-small cell lung cancer and so on. However, the expression of Drebrin in BC is unclear. In this study, measured by immunohistochemical staining, Drebrin showed moderately or strongly positive in majority of the invasive BC specimens (64.13%). Additionally, Drebrin expression was significantly correlated with the expression of Ki67 ( $P=0.020$ ), which can reflect the activity of cell proliferation and has a role in clinical practice as prognostic and predictive factors. In conclusion, Drebrin may be a promising cancer diagnostic biomarker.

**Keywords:** Drebrin, breast cancer, Ki67, biomarker

## Introduction

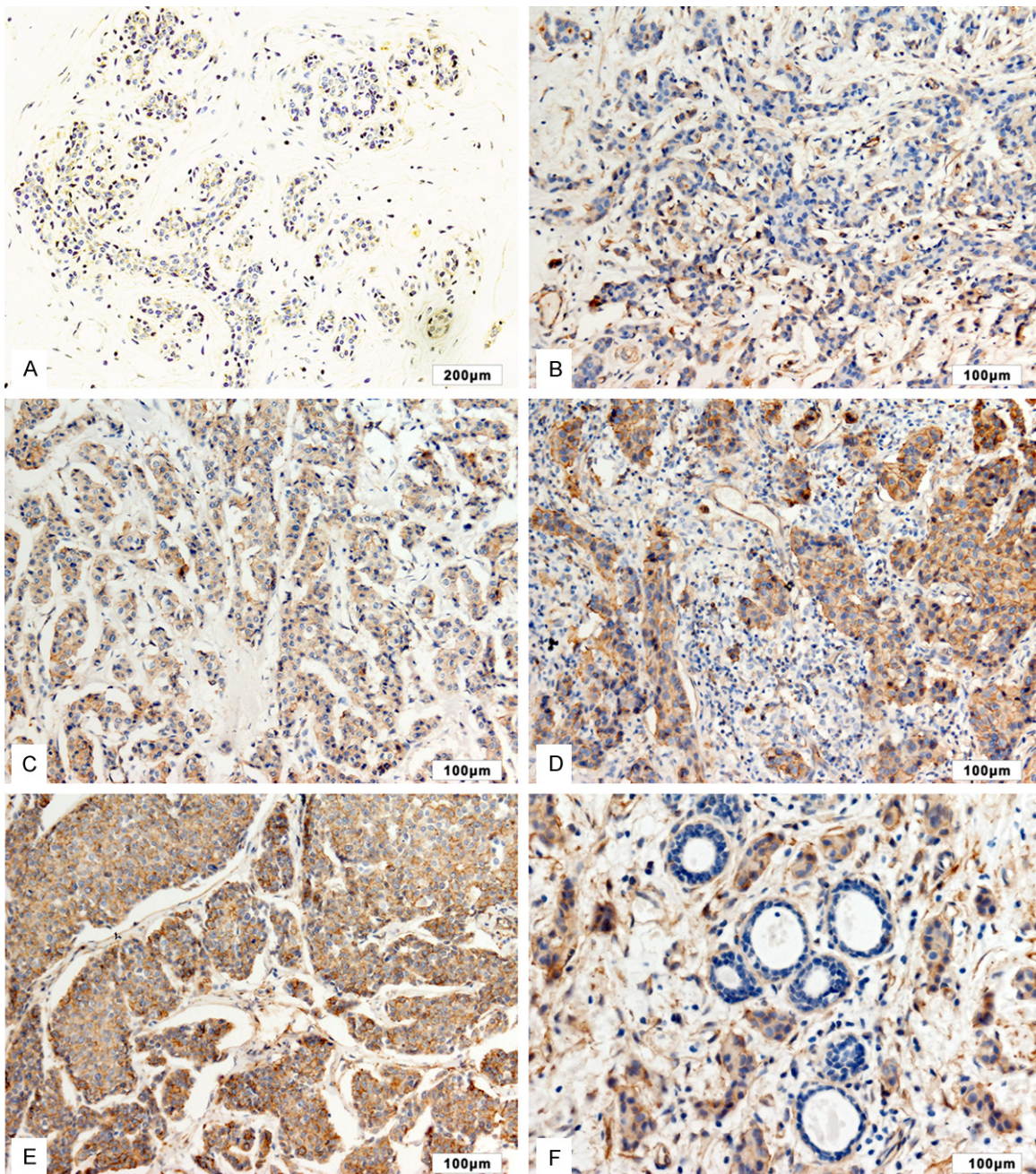
Breast cancer (BC) is the most common malignant cancer among women. The increasing incidence of BC every year causes great physiological and financial burdens for patients. In 2015, BC caused 15% of cancer deaths in females around the world [1]. Researchers recommended routine BC screening in women younger than 50 years old [2]. Because of the mutations and dysregulated expression in multiple genes are closely associated with development, metastasis and prognosis of BC. For successful BC management, the main challenge is to explore sensitive biomarkers that have high efficiency for screening and diagnosing BC malignancy, helpful for making decisions on treatment as well.

Drebrin (developmentally regulated brain protein) is an actin-binding protein, which is a family of ABP (Actin-Binding Proteins) originally

identified in neuronal cells and tissues [3], involving in the regulation of actin filament organization, especially during the formation of neurites and cell protrusions of motile cells [4]. Furthermore, Drebrin is also found in diverse non-neuronal cells, primarily in association with cell processes and intercellular junctions where it again plays a key role in actin remodeling [5-8]. Given the actin reorganization is an important process for tumor cell invasion and migrating, it is not surprising that Drebrin is upregulated in a range of carcinomas [9]. However, the role of Drebrin in BC is unclear.

In this study, we collected adjacent normal breast tissues and invasive BC specimens. Immunohistochemical staining was used to detect the expression of Drebrin in these organizations. A link between Drebrin and BC was established. In the 92 examined specimens, a positive correlation was found between the expression level of Drebrin and Ki67. Our studies sug-

## Drebrin in breast cancer



**Figure 1.** The expression of Drebrin in breast cancer specimens. A: Drebrin was negative in the normal adjacent normal breast tissues. B, C: Drebrin was negative or weakly positive in some little invasive breast cancer specimens. D, E: Drebrin was moderately or strongly positive in the majority of invasive breast cancer. F: Drebrin expression was significantly higher in the breast cancer tissues than that in the normal breast tissues in the same field of view.

gested that Drebrin is a potential target in the diagnosis of BC.

### Material and methods

#### *Patients and specimens*

We obtained 35 adjacent normal breast tissues and 92 BC tumor specimens from pati-

ents, who were diagnosed with BC and underwent complete resection in the Zhejiang University College of Medicine, Zhongshan Hospital and Changhai Hospital between 2013 and 2014. Informed consent was obtained from all patients. BC tumor specimens were collected before any radiotherapy or chemotherapy was applied. Normal breast tissues were collected

## Drebrin in breast cancer

**Table 1.** Drebrin expression in invasive breast cancer specimens

	Negative	Weak positive	Moderate positive	Strong positive
Invasive breast cancer	23 (25%)	10 (10.86%)	19 (20.65%)	40 (43.49%)

at least 5 cm away from the tumor tissues and were further confirmed to be cancer free. All the clinical data of patients such as age, ER/PR/HER2 status, tumor size, lymph node status, local or distant metastatic relapse were available and reviewed. This study was approved by the Ethical Committee of the Zhejiang Medical University, Fudan University and Changhai Hospital.

### *Immunohistochemistry*

After fixed with 10% neutral formalin, paraffin-embedded and surgically excised tissue samples were cut into 4- $\mu$ m thick sections. The sections were deparaffinized in xylene, rehydrated with graded alcohol, and then boiled in citrate buffer (0.01 M, pH 6.0) for 2 min. Endogenous peroxidase activity was inactivated with 3% H<sub>2</sub>O<sub>2</sub> for 10 min at room temperature (RT) and samples were incubated in 10% goat serum at RT for 30 min to reduce the non-specific binding. Tissue sections were incubated with anti-Drebrin monoclonal antibody (1:200 dilution; Abcam) at 4°C overnight. Mouse immunoglobulin was used as isotype controls. Subsequently, the sections were treated with Biotinylated goat anti-mouse serum IgG as a secondary antibody at RT for 1 h. After washing with phosphate-buffered saline (PBS) for three times, the sections were incubated with streptavidin-biotin conjugated with horseradish peroxidase, and the peroxidase reaction was developed with 3,3'-diaminobenzidine tetra hydrochloride. Then counterstaining with hematoxylin was performed and sections were washed with distilled water. Finally, dehydrated with graded alcohol and xylene, sealed slice were examined with microscope. 100 cells were observed and scored per view at  $\times$ 400 magnification. Expression levels were assessed based on the rate of positive cells and staining intensity. The rate of positive cells was categorized as follows: 0, <5%; 1, 5-25%; 2, 26-50%; 3, 51-75%; 4, >75%. The intensity was graded as follows: 0, no staining; 1, weak staining, light yellow; 2, moderate staining, yellow brown; 3, strong staining, brown. The proportion and intensity scores were then multiplied to obtain a final score. Scores of

0-3 were defined as “negative expression”, 4-6 as “weak positive expression”, 7-9 as “moderate positive expression”, and 10-12 as “strong positive expression”.

### *Statistical analysis*

Data were analyze using the SPSS version 13.0 (SPSS, Chicago, IL, USA). The Pearson Chi-square test was used to analyze the potential correlations between Drebrin and clinicopathological factors. *P*-value of <0.05 was considered statistically significant.

## **Results**

### *Drebrin expression was elevated in breast cancer tissues*

Firstly, we used immunohistochemistry to compare the expression of Drebrin in BC tissues to that of corresponding adjacent noncancerous tissues. Drebrin was negative in the normal adjacent breast tissues (**Figure 1A**). While in the invasive BC specimens, Drebrin showed moderately (20.65%, 19/62, **Figure 1D**) or strongly positive (43.49%, 40/92, **Figure 1E** and **Table 1**).

Additionally, we found a sample, which had not only tumor cells but also normal breast duct cells (**Figure 1F**). The expressions of Drebrin in the normal breast tissue and BC were significantly different in the same field of view. In this figure, we can clearly see the expression of Drebrin was positive in cancer tissues but negative in noncancerous tissues. This kind of picture represented the real situation that the expression of Drebrin in patients who has BC. Collectively, the results implicated that Drebrin is overexpressed in BC.

### *The correlation between drebrin expression and clinic-pathological features of breast cancer*

We analyzed the correlation between Drebrin expression and the clinical pathological factors of BC in 92 cases of BC specimens. As shown in **Table 2**, the expression level of Drebrin had significantly positive correlation with the expres-

## Drebrin in breast cancer

**Table 2.** Correlation of Drebrin expression with clinicopathological characteristics of invasive breast cancer

Clinicopathological Factors	Drebrin			P
	All cases	Positive	Negative	
Age				0.904
<50	53	40	13	
≥50	39	29	10	
Lymph node metastasis				0.119
Yes	49	40	9	
No	43	29	14	
ER expression				0.080
Positive	61	41	20	
Negative	31	28	3	
PR expression				0.151
Positive	59	41	18	
Negative	33	28	5	
HER2 expression				0.151
Positive	48	33	15	
Negative	44	36	8	
Ki67 expression				0.020*
Positive	75	60	15	
Negative	17	9	8	

\*P<0.05 indicating a significantly positive correlation.

sion level of Ki67 (P=0.020), but it had no obvious correlation with the patients' age (P=0.904), lymph node metastasis (P=0.119) and the expression level of ER (P=0.080), PR (P=0.151) and Her-2 (P=0.151).

In our study, Ki67 was negative in the normal adjacent breast tissues, while in the invasive BC specimens, Ki67 was positive (96.73%, 89/92, **Table 3**). In sum, the results were consistent with other research and indicated that Ki67 is a biologic BC marker.

### Discussion

Despite improvements of cancer therapeutics, a large number of patients diagnosed with invasive breast carcinomas will eventually die from this disease. Therefore, more effective biomarkers and targets for diagnosing the BC are urgently needed. Drebrin is an actin-binding protein, which was overexpressed in BC in our research. We can confirm that because the expression of Drebrin is significantly higher in the breast cancer tissues than that in the normal breast tissues in the same field of view (**Figure 1F**). Moreover, the positive expression of Drebrin was closely related to the expression of Ki67 in BC. Collectively, this research suggest-

ed that Drebrin is likely a new molecular marker of BC.

Cell invasion requires cell interactions with adjacent cells and extracellular matrix (ECM), proteolytic degradation of ECM, and cell migration [10]. Furthermore, tumor cells need to change their cell morphology for migrating. By remodeling the actin cytoskeleton, migrating cells become polarized and form membrane protrusions, such as lamellipodia and filopodia, and focal adhesions at the leading edge of the migratory front [11]. These membrane protrusions contain filamentous actin and various structural are interacting with the ECM. Such properties enable cells to generate cytoskeletal contraction, so allow the cell body to move forward [11, 12]. In this way, actin cytoskeleton dynamics are considered to play a significant role in cell invasiveness.

Drebrin is believed to be a cytoskeletal modulator involved in the regulation of actin filament organization and plays an important role in cell motility and the control of cell shape especially of motile cells [4, 8]. Most of the past work on Drebrin expression and activity have been focused on neurons, in which Drebrin binds to F-actin and controls actin filament dynamics, neurite morphology and outgrowth [6, 13]. By affecting actin remodeling, Drebrin plays an important role in regulating cell motility in the physiology [14-16] and pathology of neuronal cells [17]. Drebrin exists in three isoforms (E1, E2, and A) generated by alternative splicing and synthesized in patterns depending on the specific developmental stage [18]. To date, Drebrin E2 is known to be expressed in diverse types of non-neuronal cells including stomach and kidney epithelia [5] and T cells, where Drebrin binds the chemokine receptor CXCR4 and regulates immune synapsis [19]. Since the ability of Drebrin to form long, actin-rich protrusions, promote cell migration and cell-cell contact, it is not surprising that Drebrin may have an important role during the cancer metastasis. Moreover, the carboxy terminal of Drebrin is thought to interact with the Ras oncogene product [4, 20]. So far, there have been several studies reporting that Drebrin is up-regulated in epithelial skin tumors

## Drebrin in breast cancer

**Table 3.** Ki67 expression in invasive breast cancer specimens

	Negative	Weak positive	Moderate positive	Strong positive
Invasive breast cancer	3 (3.26%)	32 (34.78%)	51 (55.43%)	6 (6.52%)

[7], colorectal cancer [9], recurrent non-small cell lung cancer [21] and in lymphoblastic leukemia [22]. Some researchers found that Drebrin plays an important role in for cell migration, invasion, and morphology in a series of human glioma cell lines [17]. And some studies proved that Drebrin was essential for progranulin-induced signaling of urothelial cancer cells as in fact Drebrin depletion significantly inhibited the activation of both the Akt and MAPK pathways, which were essential for progranulin-dependent motility and invasion of urothelial cancer cells [23-25]. Up to now, the mechanism of the action of Drebrin tumor is still unclear in some part. What is unclear in terms of tumorigenesis is whether the dysregulation of Drebrin is a primary cause or secondary to other genetic or environmental insults. This is similar to our lack of understanding of how Drebrin is involved in neurological disease as well: are abnormal levels of Drebrin the underlying cause or a pathological marker of other changes [4, 24, 25].

In this study, we found a positive correlation between the expression level of Drebrin and Ki67 in invasive BC specimens. The Ki67 antigen (Kiel University, clone 67), firstly described in 1983 [26], is a nuclear protein expressed in proliferating cells throughout all phases of the cell cycle, and is a clinical pathological factors in many types of cancer. The expression starts in mid G1 and is maintained throughout the S, G2 and M phases of the cell cycle [27]. Ki67 can reflect the activity of cell proliferation. Yerushalemi and colleagues conclude that Ki67 at a level >10-14% defines a high risk group of BC patients [28]. Ki67 expression increases progressively across the continuum from benign breast disease to ductal carcinoma in situ to invasive BC [29, 30]. Ki67 is considered as a biologic BC marker, which have a role in clinical practice as prognostic and predictive factors and as possible targets for future therapies [31]. Because there have a positive correlation between Drebrin and Ki67 in breast cancer; furthermore, Drebrin is a cytoskeletal modulator, which is considered to play a pivotal role in

cell invasiveness. We can conclude that Drebrin may promote the malignant progression of BC and we could take Drebrin as a prognostic or predictive biomarker for BC.

To our knowledge, this is the first study to investigate the expression of Drebrin in BC and clarify the relationship between Drebrin and clinical pathological factors in BC. Our studies provided a preliminary theoretical and experimental basis for Drebrin to be considered as a molecular marker and a potential target in the treatment of BC. Our future work will focus on the feasibility of Drebrin as a potential therapeutic target for invasive BC and the mechanisms of Drebrin in BC.

### Acknowledgements

This work was supported by grants from the Development Center for Medical Science and Technology National Health and Family Planning Commission of the People's Republic of China (W2012FZ017).

### Disclosure of conflict of interest

None.

**Address correspondence to:** Wenjun Chen, Department of Surgical Oncology, Sir Run Run Shaw Hospital, Zhejiang University College of Medicine, 3 East Qingchun Road, Hangzhou, Zhejiang 310016, China. Tel: +86 135-8870-6951; Fax: +86 0571-86044817; E-mail: wenjunchen@139.com; Hongwei Zhang, Department of General Surgery, Zhongshan Hospital, Fudan University, Shanghai 200032, China. Tel: +86 021-64041990; Fax: +86 021-64041990; E-mail: zhang.hongwei@zs-hospital.sh.cn

### References

- [1] Siegel RL, Miller KD and Jemal A. Cancer statistics, 2015. *CA Cancer J Clin* 2015; 65: 5-29.
- [2] Dehkordy SF, Hall KS, Roach AL, Rothman ED, Dalton VK and Carlos RC. Trends in breast cancer screening: impact of US Preventive Services Task Force recommendations. *Am J Prev Med* 2015; 49: 419-422.
- [3] Shirao T. The roles of microfilament-associated proteins, drebrins, in brain morphogenesis: a review. *J Biochem* 1995; 117: 231-236.
- [4] Dun XP and Chilton JK. Control of cell shape and plasticity during development and disease

## Drebrin in breast cancer

- by the actin-binding protein Drebrin. *Histol Histopathol* 2010; 25: 533-540.
- [5] Keon BH, Jedrzejewski PT, Paul DL and Goodenough DA. Isoform specific expression of the neuronal F-actin binding protein, drebrin, in specialized cells of stomach and kidney epithelia. *J Cell Sci* 2000; 113: 325-336.
- [6] Peitsch WK, Bulkescher J, Spring H, Hofmann I, Goerdt S and Franke WW. Dynamics of the actin-binding protein drebrin in motile cells and definition of a juxtannuclear drebrin-enriched zone. *Exp Cell Res* 2006; 312: 2605-2618.
- [7] Peitsch WK, Hofmann I, Bulkescher J, Hergt M, Spring H, Bleyl U, Goerdt S and Franke WW. Drebrin, an actin-binding, cell-type characteristic protein: induction and localization in epithelial skin tumors and cultured keratinocytes. *J Invest Dermatol* 2005; 125: 761-774.
- [8] Peitsch WK, Hofmann I, Prätzel S, Grund C, Kuhn C, Moll I, Langbein L and Franke WW. Drebrin particles: components in the ensemble of proteins regulating actin dynamics of lamellipodia and filopodia. *Eur J Cell Biol* 2001; 80: 567-579.
- [9] Lin Q, Tan HT, Lim TK, Khoo A, Lim KH and Chung M. iTRAQ analysis of colorectal cancer cell lines suggests Drebrin (DBN1) is overexpressed during liver metastasis. *Proteomics* 2014; 14: 1434-1443.
- [10] Demuth T and Berens ME. Molecular mechanisms of glioma cell migration and invasion. *J Neurooncol* 2004; 70: 217-228.
- [11] Ridley AJ, Schwartz MA, Burridge K, Firtel RA, Ginsberg MH, Borisy G, Parsons JT and Horwitz AR. Cell migration: integrating signals from front to back. *Science* 2003; 302: 1704-1709.
- [12] Kirfel G, Rigort A, Borm B and Herzog V. Cell migration: mechanisms of rear detachment and the formation of migration tracks. *Eur J Cell Biol* 2004; 83: 717-724.
- [13] Hayashi K, Ishikawa R, Kawai-Hirai R, Takagi T, Taketomi A and Shirao T. Domain analysis of the actin-binding and actin-remodeling activities of drebrin. *Exp Cell Res* 1999; 253: 673-680.
- [14] Song M, Kojima N, Hanamura K, Sekino Y, Inoue HK, Mikuni M and Shirao T. Expression of drebrin E in migrating neuroblasts in adult rat brain: coincidence between drebrin E disappearance from cell body and cessation of migration. *Neuroscience* 2008; 152: 670-682.
- [15] Dun XP, de Lima TB, Allen J, Geraldo S, Gordon-Weeks P and Chilton JK. Drebrin controls neuronal migration through the formation and alignment of the leading process. *Mol Cell Neurosci* 2012; 49: 341-350.
- [16] Mizui T, Sekino Y, Yamazaki H, Ishizuka Y, Takahashi H, Kojima N, Kojima M and Shirao T. Myosin II ATPase activity mediates the long-term potentiation-induced exodus of stable F-actin bound by drebrin A from dendritic spines. *PLoS One* 2014; 9: e85367.
- [17] Terakawa Y, Agnihotri S, Golbourn B, Nadi M, Sabha N, Smith CA, Croul SE and Rutka JT. The role of drebrin in glioma migration and invasion. *Exp Cell Res* 2013; 319: 517-528.
- [18] Kojima N, Shirao T and Obata K. Molecular cloning of a developmentally regulated brain protein, chicken drebrin A and its expression by alternative splicing of the drebrin gene. *Mol Brain Res* 1993; 19: 101-114.
- [19] Pérez-Martínez M, Gordón-Alonso M, Cabrero JR, Barrero-Villar M, Rey M, Mittelbrunn M, Lamanca A, Morlino G, Calabria C and Yamazaki H. F-actin-binding protein drebrin regulates CXCR4 recruitment to the immune synapse. *J Cell Sci* 2010; 123: 1160-1170.
- [20] Biou V, Brinkhaus H, Malenka RC and Matus A. Interactions between drebrin and Ras regulate dendritic spine plasticity. *Eur J Neurosci* 2008; 27: 2847-2859.
- [21] Mitra R, Lee J, Jo J, Milani M, McClintick JN, Edenberg HJ, Kesler KA, Rieger KM, Badve S and Cummings OW. Prediction of Postoperative Recurrence-Free Survival in Non-Small Cell Lung Cancer by Using an Internationally Validated Gene Expression Model. *Clin Cancer Res* 2011; 17: 2934-2946.
- [22] Vaskova M, Kovac M, Volna P, Angelisova P, Mejstrikova E, Zuna J, Brdicka T and Hrusak O. High expression of cytoskeletal protein drebrin in TEL/AML1 pos B-cell precursor acute lymphoblastic leukemia identified by a novel monoclonal antibody. *Leuk Res* 2011; 35: 1111-1113.
- [23] Xu SQ, Buraschi S, Morcavallo A, Genua M, Shirao T, Peiper SC, Gomella LG, Belfiore A, Iozzo RV and Morrione A. A novel role for drebrin in regulating progranulin bioactivity in bladder cancer. *Cancer Res* 2015; 75: 4945-4945.
- [24] Lovat F, Bitto A, Xu SQ, Fassan M, Goldoni S, Metallì D, Wubah V, McCue P, Serrero G and Gomella LG. Proepithelin is an autocrine growth factor for bladder cancer. *Carcinogenesis* 2009; 30: 861-868.
- [25] Monami G, Emiliozzi V, Bitto A, Lovat F, Xu SQ, Goldoni S, Fassan M, Serrero G, Gomella LG and Baffa R. Proepithelin regulates prostate cancer cell biology by promoting cell growth, migration, and anchorage-independent growth. *Am J Pathol* 2009; 174: 1037-1047.
- [26] Gerdes J, Schwab U, Lemke H and Stein H. Production of a mouse monoclonal antibody reactive with a human nuclear antigen associated with cell proliferation. *Int J Cancer* 1983; 31: 13-20.

## Drebrin in breast cancer

- [27] Kourea HP, Zolota V, Scopa CD. Targeted pathways in breast cancer: molecular and protein markers guiding therapeutic decisions. *Curr Mol Pharmacol* 2014; 7: 4-21.
- [28] Yerushalmi R, Woods R, Ravdin PM, Hayes MM and Gelmon KA. Ki67 in breast cancer: prognostic and predictive potential. *Lancet Oncol* 2010; 11: 174-183.
- [29] Allred DC, Mohsin SK and Fuqua SA. Histological and biological evolution of human premalignant breast disease. *Endocr Relat Cancer* 2001; 8: 47-61.
- [30] Shoker BS, Jarvis C, Davies MPA, Iqbal M, Sibson DR and Sloane JP. Immunodetectable cyclin D 1 is associated with oestrogen receptor but not Ki67 in normal, cancerous and precancerous breast lesions. *Br J Cancer* 2001; 84: 1064-9.
- [31] Kontzoglou K, Palla V, Karaolani G, Karaikos I, Alexiou I, Pateras I, Konstantoudakis K and Stamatakos M. Correlation between Ki67 and breast cancer prognosis. *Oncology* 2013; 84: 219-225.