

## Case Report

# Uniportal video-assisted thoracoscopy for thoracic duct cyst resection without thoracic duct ligation: a case report

Tao Fan\*, Lei Chen\*, Boyou Zhang, Yao Xu, Wei Wang, Hao Hu, Qing Geng

*Department of Thoracic Surgery, Renmin Hospital of Wuhan University, Wuhan, China. \*Equal contributors.*

Received August 24, 2016; Accepted October 14, 2016; Epub December 15, 2016; Published December 30, 2016

**Abstract:** Traditional surgical treatment of thoracic duct cyst consists of removal of the cyst and ligation of thoracic duct connected to it. We proposed a novel surgical technique that avoids the ligation of thoracic duct and minimizes the invasion. A 38-year-old woman with thoracic duct cyst was treated with a novel surgical technique that thoracic duct cyst was longitudinally excised without thoracic duct ligation via uniportal (3-4 cm) video-assisted thoracic surgery (VATS). This novel approach avoids the increase of intraluminal pressure of the duct and alleviates the pain for its minimized incision. There was no recurrence or complications during the twelve months follow-up. Compared with traditional surgical treatment of thoracic duct cyst, this novel approach preserves the original structure and function, and more importantly releases the pressure of the thoracic duct, which should be encouraged for its less trauma and complications.

**Keywords:** Chyle, mediastinum, novel surgery/techniques, thoracic duct, thoracoscopy/VATS

## Introduction

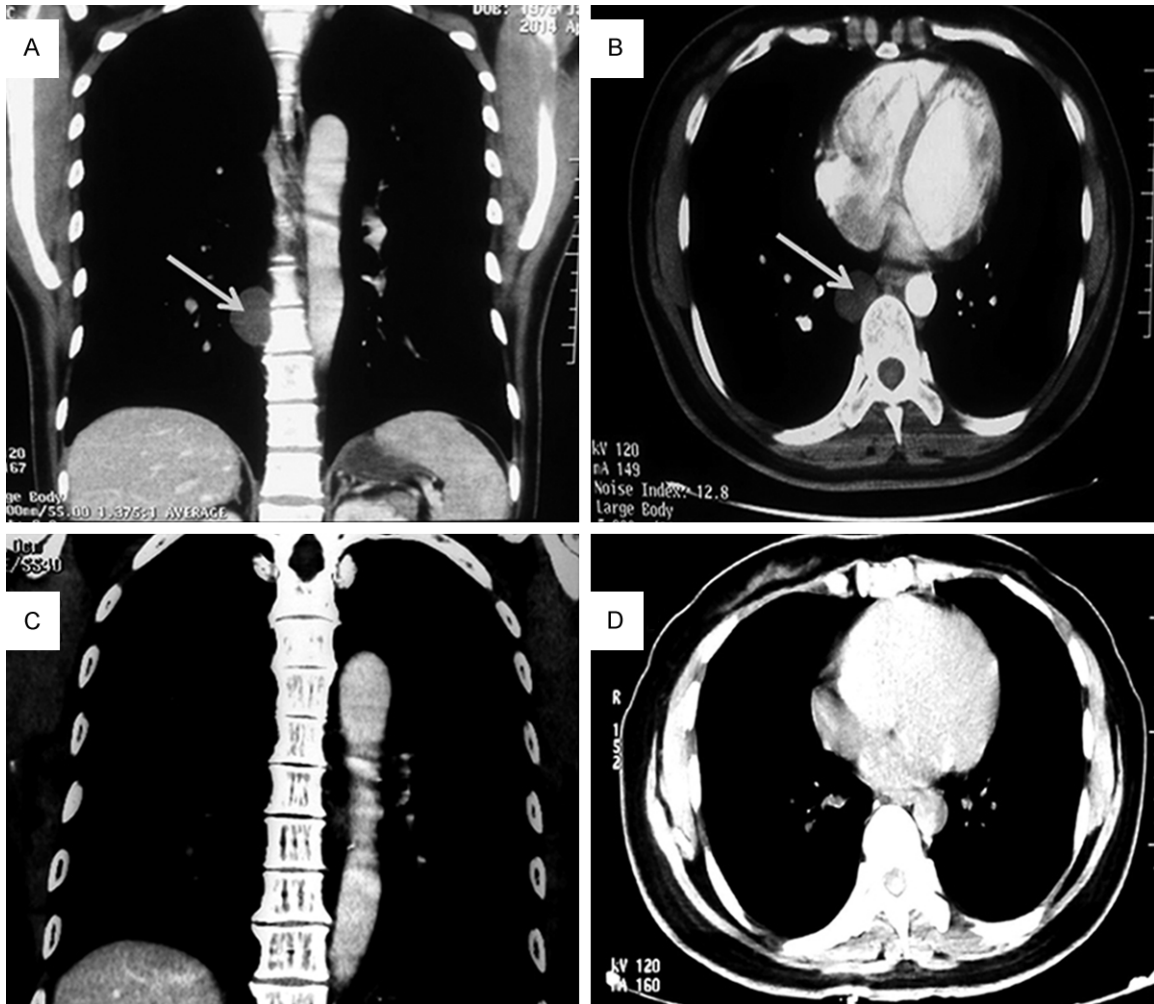
The first reported case of a thoracic duct cyst was found during an autopsy examination by Carbone in 1892 [1]. Such cyst is generally asymptomatic, but it may cause symptoms if there is pressure on adjacent structures. The conclusive diagnosis of mediastinal thoracic duct cyst before operation is difficult and final diagnosis is often based on surgical findings and pathologic results. Surgical resection of the cyst is commonly performed to confirm the diagnosis and prevent the potential complication of cyst rupture and resulting in chylothorax. Standard posterolateral thoracotomy is the usual approach for resection, which includes ligation of all lymphatics connected to it and removes the cyst. After ligation of thoracic duct, few severe complications are described. There are reports of chylothorax [2], chyloperitoneum, chyluria [3], and lower-extremity lymphedema [4], though the incidence is rare. While the exact pathophysiology remains unknown, a direct increase of intraluminal pressure of the duct after ligation leading to the direct extension of chyle is considered to be the reason. We

reported one case of a thoracic duct cyst in the right posterior mediastinum, successfully treated with uniportal VATS. We proposed a novel surgical technique that avoids the increase in intraluminal pressure of the duct and that alleviates the pain of patients via uniportal video-assisted thoracoscopic of thoracic duct cyst resection without thoracic duct ligation.

## Case presentation

A 38-year-old woman presented to our hospital with vague back pain for 10 days. The results of a routine physical examination were unremarkable. A computed tomography (CT) scan revealed a homogenous, non-enhancing mass at the right lower posterior mediastinum (**Figure 1A** and **1B**), with a density of 40 Hounsfield units. The mass was located at the right side of T8, T9 vertebra with a size of 3×4×2 cm. The most likely preoperative diagnosis was that of a posterior mediastinal tumor. Laboratory tests and pulmonary function tests were normal.

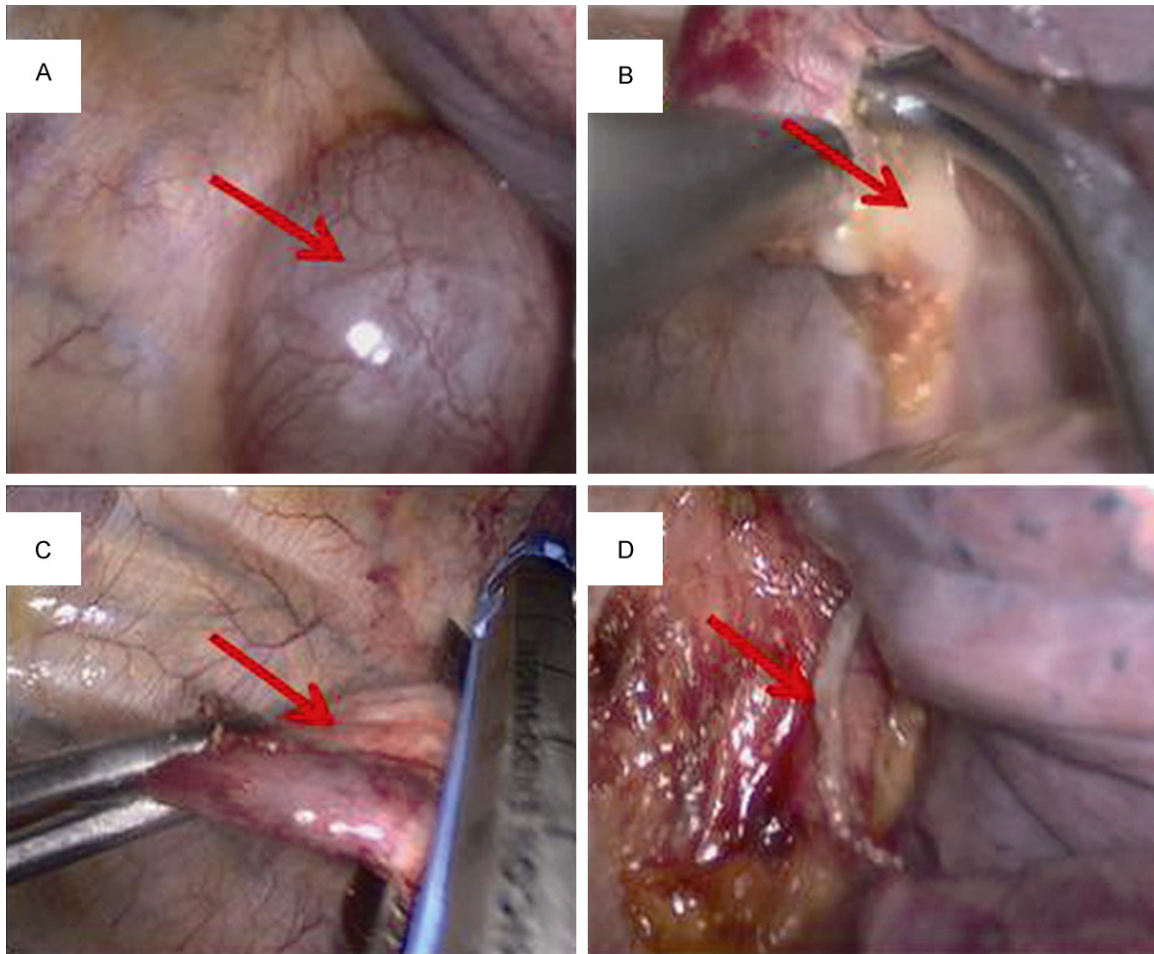
Under general anesthesia, a single-port VATS resection of the mass was performed. After the



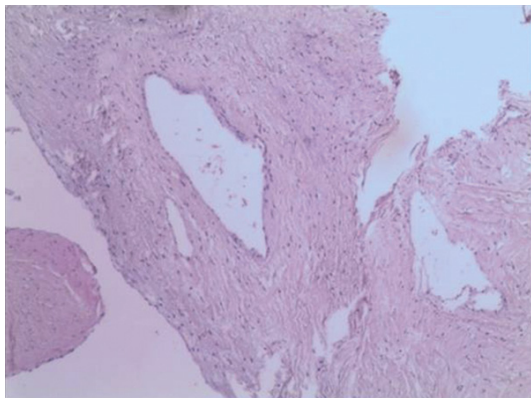
**Figure 1.** CT scan of the mass located in the right lower posterior mediastinum. A. Preoperative transversal plane of the mass. B. Preoperative coronal plane of the mass. C. Postoperative transversal plane of CT scan after the mass recised for twelve month. D. Postoperative coronal plane of CT scan after the mass recised for twelve month.

patient was placed in left lateral decubitus position, a single 2.5 cm incision was made in the 6th intercostal space at the right anterior axillary line. A wound protector (Applied Medical, Rancho Santa Margarita, CA) was applied to prevent contamination of the wound from the tumor. After selective single-lung ventilation, the thoracic cavity and posterior mediastinum were explored under a 30-degree 10 mm scope. The cystic mass was visualized at the right side of T8, T9 vertebra (**Figure 2A**). The mediastinal pleuron was incised using an electrocautery hook. After the mass was punctured, it was suspected to be a thoracic duct cyst because of the milk-like, chylous fluid (**Figure 2B**). The cyst was carefully dissected from its surrounding tissue, and the bottom of the cyst

was found to be connected to the thoracic duct. The cyst was resected longitudinally along the thoracic duct using an EC60A Echelon Flex 60 mm Endopath stapler (Ethicon Endo-Surgery, Cincinnati, OH) (**Figure 2C** and **2D**). Intraoperative blood loss was less than 5 mL. The patient's postoperative course was uneventful without complications. The chest tube was removed on the second postoperative day, and the patient was discharged the following day. The histopathology of the cyst wall showed an inner single layer of endothelial cells, smooth muscle cells, and islets of lymphoreticular cells (**Figure 3**), confirming the diagnosis of thoracic duct cyst. The patient was followed up for twelve months postoperatively with no recurrence or complications (**Figure 1C** and **1D**).



**Figure 2.** A. Gross appearance of thoracic duct cyst. B. The milk-like, chylous fluid in thoracic duct cyst. C, D. Resection of the thoracic duct cyst.



**Figure 3.** Histology (hematoxylin/eosin staining \*200), showing morphologic features of the thoracic duct cyst.

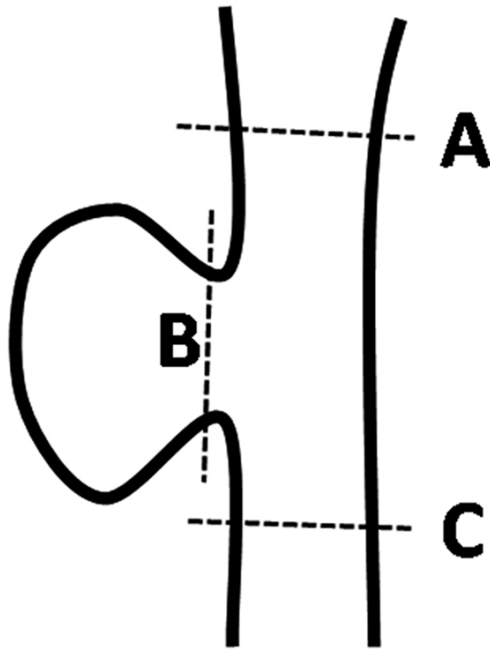
### Discussion

The thoracic duct is the largest lymphatic vessel of the lymphatic system. Thoracic duct cysts

are typically found in the neck, while mediastinal thoracic duct cysts are rare [1]. Thoracic duct cysts are usually asymptomatic. However, diagnosis may be elucidated through clinical history. Symptoms such as coughing, dyspnea on exertion, chest or back discomfort, and dysphagia may be experienced and are often aggravated by food intake [2].

On CT scan, thoracic duct cysts appear as smooth homogenous cystic masses and are difficult to differentiate from other mediastinal cystic lesions, such as pericardial or pleural mesothelial cysts, teratomatous cysts, bronchial or esophageal cysts, and neurenteric and lymphangiomatous cysts. In our case, the leading preoperative diagnosis was neurogenic tumor due to the CT density of 40 Hu. The radiodensity of these cysts has been attributed to the high density of chyle, which predominantly consists of lipids and proteins [1]. Lympho-





**Figure 4.** Line A and line C represent the points of ligation during traditional operation. In this case, the cyst was removed along line B with a new method. Comparing these two methods, the latter preserved the original structure and function, and more importantly released the pressure on the thoracic duct.

graphy, though not mandatory, may aid preoperative diagnosis and confirm communication with the thoracic duct [3]. Definitive diagnosis of mediastinal thoracic duct cysts can only be achieved with surgical excision and histopathology [1].

The pathogenesis of thoracic duct cysts is unclear. Congenital weakness of the ductal wall and degeneration induced by trauma, infection or other inflammation processes have been proposed as potential mechanisms [1, 4]. Upon discovery, removal of these cysts is generally recommended due to risk of rupture potentially leading to chylothorax. These cysts are removed to relieve symptoms and to prevent further growth, rupture, infection, and possible malignant transformation.

The surgical treatment of thoracic duct cyst consists of removal of the cyst and ligation of all lymphatics connected to it [4]. Historically, resections were performed through a standard posterolateral thoracotomy. Video-assisted thoracic surgery (VATS) has significantly developed over the last two decades and offers an

alternative to thoracotomy in resecting benign mediastinal tumors. Conventional VATS is performed via a triple-port or double-port approach. In this case, we performed the procedure through a single-incision, uniportal approach. In contrast to triple-port or double-port VATS, the single-port VATS technique represents the least invasive approach possible, avoiding the use of multiple trocars and minimizing compression of the intercostal nerves. This technique may lessen periosteal and intercostal nerve trauma, decrease the incidence of postoperative neuralgia, and consequently could decrease the length of hospital stay.

In this case, we made a 2.5 cm single incision at the sixth intercostal space across the anterior axillary line. We used our preferred long, curved, two-jointed instruments. A 30-degree camera scope is usually maintained in the upper part of the port and the surgeon's instruments are in the lower part of the port during the dissecting process, in order to get a clear view and perform a safe procedure. Using the surgical technique illustrated in **Figure 4**, we simplified the operative procedure, while making it safe and minimally invasive. Longitudinal excision preserved the physiologic integrity and continuity of the thoracic duct, and more importantly released the pressure on the thoracic duct.

Few serious complications after thoracic duct ligation have been described. There are reports of chylothorax [5], chyloperitoneum, chyluria [6], and lower-extremity lymphedema [7], though the incidence is rare. While the exact pathophysiology remains unknown, a direct increase in intraluminal pressure of the duct after ligation leading to the direct extension of chyle is considered to be a potential mechanism of complications.

One year after resection of the thoracic duct cyst, CT was rechecked to show that no thoracic duct cyst, chylothorax or lung infection recurred (**Figure 1C** and **1D**).

To our knowledge, this case represents the first report of a mediastinal thoracic duct cyst treated successfully without thoracic duct ligation and with uniportal VATS, which keeps the original structure and function, and more importantly, releases the pressure on the thoracic duct. As a novel technique, uniportal video-

assisted thoracoscopic of thoracic duct cyst resection without thoracic duct ligation could be used for the diagnosis and treatment of thoracic duct cyst perfectly.

## Acknowledgements

We are very grateful to Alexander A Brescia for his help to revising this text.

## Disclosure of conflict of interest

None.

**Address correspondence to:** Dr. Qing Geng, Department of Thoracic Surgery, Renmin Hospital of Wuhan University, Wuhan 430060, China. Tel: 0086-27-88041911-82240; Fax: 0086-27-88042292; E-mail: szgqing@126.com

## References

- [1] Okabe K, Miura K, Konishi H, Hara K and Shimizu N. Thoracic duct cyst of the mediastinum. Case report. Scand J Thorac Cardiovasc Surg 1993; 27: 175-177.
- [2] Turkyilmaz A and Eroglu A. A giant thoracic duct cyst: an unusual cause of dysphagia. J Thorac Cardiovasc Surg 2007; 134: 1082-1083.
- [3] Tsuchiya R, Sugiura Y, Ogata T and Suemasu K. Thoracic duct cyst of the mediastinum. J Thorac Cardiovasc Surg 1980; 79: 856-859.
- [4] Gottwald F, Iro H, Finke C and Zenk J. Thoracic duct cysts: a rare differential diagnosis. Otolaryngol Head Neck Surg 2005; 132: 330-333.
- [5] Busquets JM, Rullan PJ and Trinidad-Pinedo J. Bilateral chylothorax after neck dissection. Otolaryngol Head Neck Surg 2004; 130: 492-495.
- [6] Takeno A, Tamura S, Miki H, Tanigawa N, Taniguchi H, Nakahira S, Suzuki R, Nakata K, Takeda Y and Kato T. Chyluria after ligation of the thoracic duct: a rare complication after thoracoscopic-assisted esophagectomy for esophageal cancer. Surg Today 2014; 44: 757-760.
- [7] Raguse JD, Pfizmann R, Bier J and Klein M. Lower-extremity lymphedema following neck dissection—an uncommon complication after cervical ligation of the thoracic duct. Oral Oncol 2007; 43: 835-837.