Int J Clin Exp Med 2016;9(2):2229-2236
www.ijcem.com /ISSN:1940-5901/IJCEM0007371

Original Article

The use of cortical particulate allograft mixed with plasma-rich fibrin in severe maxillary alveolar ridge atrophy

Víctor Beltrán[1,4], Márcio Lazzarini[2], Ricardo Lillo[3], Ramón Fuentes[4], Iván Valdivia-Gandur[5], Walter Stühmer[2], Wilfried Engelke[1]

[1]Department of Oral and Maxillofacial Surgery, Georg-August-University, Göttingen, Germany; [2]Department of Molecular Biology of Neuronal Signals, Max Planck Institute of Experimental Medicine, Göttingen, Germany; [3]Faculty of Dentistry, Universidad Mayor, Santiago, Chile; [4]Research Centre in Dental Sciences (CICO), Dental School, Universidad de La Frontera, Temuco, Chile; [5]Departments of Dentistry and Biomedical, Universidad de Antofagasta, Antofagasta, Chile

Received February 2, 2015; Accepted January 11, 2016; Epub February 15, 2016; Published February 29, 2016

Abstract: Atrophy in the edentulous maxilla typically consists of vertical bone loss in the posterior maxilla due to pneumatization of the maxillary floor and transverse reduction in anterior areas. The purpose of this study was to perform bilateral sinus floor augmentation and maxillary alveolar bone reconstruction by autologous platelet-rich fibrin (PRF) mixed with mineralized cancellous bone allograft and PRF membranes. Method: Six patients (3 men and 3 women, age 46-65 years) with severe maxillary atrophy were selected for this study. The patient's blood was centrifuged to obtain PRF. Mineralized cancellous bone allograft (Zimmer Puros®) was mixed with PRF and applied for sinus floor augmentation in posterior and lateral augmentation in anterior maxillary atrophy. Additionally, PRF membranes were placed over augmented area. Evaluation was carried out before and six months after surgery using CBCT to measure alveolar site dimension. Histology was obtained from corebiopsies taken for implant insertion to evaluate quality of bone regeneration. Results: The use of PRF as cover membrane permitted rapid tissue reparation, high bone quality was detected in sites augmented with bone allograft and PRF. The horizontal alveolar bone volume after 6 months and the vertical bone augmentation increased at about 10 mm. Conclusion: Based on the preliminary case series, the combination of PRF membrane and PRF mixed with bone allograft represents a predictable method of augmenting the sinus floor as well as the deficient anterior maxilla to achieve rehabilitation of the atrophic maxilla with dental implants.

Keywords: Autologous platelet-rich fibrin, cone-beam computed tomography, bone regeneration, bilateral sinus floor augmentation and alveolar bone reconstruction

Introduction

Bone resorption has been frequently found in edentulous patients due to the prolonged use of total dentures without adequate dental support. These cases often represent a clinical challenge for implantology because of insufficient bone height and width after crestal bone atrophy and a severe maxillary sinus pneumatization [1]. For a long time, the gold standard for sinus floor augmentation procedures has been autologous bone transplants, due to their osteoinductive and osteoconductive properties [2]. The main disadvantages are donor site morbidity, size restriction, and the resorption of bone graft [3]. For these reasons, recent studies are looking for bone-substitute materials widely accepted as additional or replacement materials in bone augmentation procedures. Bone allograft with autologous platelet-rich fibrin (PRF) has been adopted as an alternative for bone transplants [4]. PRF is a fibrin matrix in which the platelets, cytokines and cells are trapped and may be released after a certain time [5]. These cytokines have been shown to stimulate the mitogenic response of the periosteum during the early stage of bone repair [6], and in general are strongly associat-

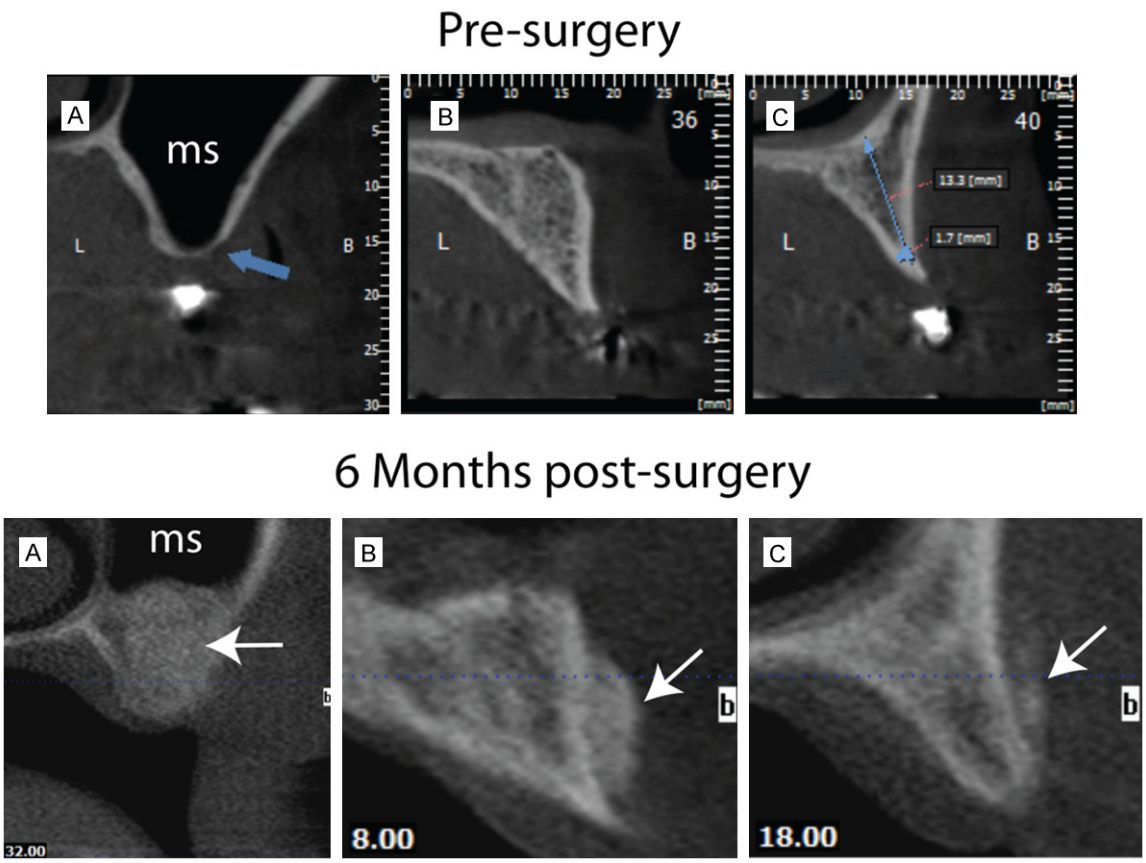

Figure 1. Pre and post-surgery CBCT images of edentulous maxillary with severe sinus bilateral pneumatization ("A" blue arrows in pre-surgery images from left side) and maxillary alveolar atrophy (pre-surgery images, "B" and "C" in Left side). The bilateral sinus lift by placement of mineralized cancellous bone allograft mixed with PRF and PRF membrane generated sufficient bone height (white arrows in "A" image in 6 months post-surgery images). Additionally, increase of the alveolar width was achieved (white arrows in "B" and "C" images in 6 months post-surgery images). ms: maxillary sinus.

ed with the bone healing process [7, 8]. The use of PRF in alveolar bone defect and sinus floor augmentation procedures as an addition to bone graft materials has also been successfully proven [4, 9, 10]. PRF mixed with bone allograft supported by PRF membrane is a new, promising bone augmentation technique before dental implant treatment in patients with atrophied alveolar crest and severe maxillary sinus pneumatization.

Methods

Patient selection and initial measurements

The protocol was approved by the ethical committee of the medical faculty, Universidad de La Frontera, Temuco, Chile (register N°246/006). The inclusion criteria for patients were as follows: Edentulous maxilla with extensive sinus pneumatization (a residual alveolar bone height under the sinus of 5 mm or less), as judged by pre-operative Cone-Beam Computed Tomography (CBCT), and alveolar ridges that needed horizontal augmentation (**Figure 1**). The patients selected had good oral health and no active periodontitis. Patients were excluded from the procedure if their health was compromised or they suffered from drug abuse. One patient required sinus lift in combination with alveolar crest augmentation, three patients bilateral sinus lift and two alveolar ridge augmentation only. From the crossectional images obtained by CBCT of each patient, two cuts were selected that reflected the mesial and distal limits of the maxillary alveolar bone reconstruction (called "outer limiting cut"), the limits were determined by the number of implants to be placed in the site. Horizontal measurements

were made of the alveolar bone at cuts immediately adjacent to the outer limiting cuts in the central incisor, lateral incisor and canine region. Another vertical measure was made on a midline of distance between two cuts that reflected the mesial and distal limits of the sinus membrane elevation proposed.

Platelet rich fibrin preparation

For each patient, PRF was prepared from its venous blood, approximately 5-10 ml, and transferred to the vacutainers. These vacutainers were then centrifuged by 3000 RPM during 10 min (EBA 20; Hettich, Germany). The PRF and PRF membrane were prepared according to the protocol described by Singh [11] and Gassling [9].

Surgical procedures

Patients were given 1750 mg of amoxicillin/clavulanate potassium one hour before their surgery (Augmentin, GlaxoSmithKline, Research Triangle Park, NC, USA). A crestal incision was made with a vestibular relief incision in the premolar region. Using full thickness mucoperiosteal flap, the anterobasal aspect of the sinus wall was exposed. Laterobasal trepanations (left and right sides) by the piezoelectric osteotomy were made directly anterior to the zygomatic buttress at the inferior aspect of the anterior sinus wall. Posteriorly, the sinus membrane was displaced and space created was filled by 2 cc of mineralized cancellous bone allograft (Puros®; Zimmer Dental GmbH, Germany) mixed with PRF. Surgical correction of the alveolar width was also performed by Puros®with PRF. A PRF membrane was then placed to cover the surgical site before flap closure (**Figure 2**). After surgery, the flank of prosthesis was removed. The patient was prescribed 875 mg of Augmentin or amoxicillin twice a day, plus 50 mg of potassium diclofenac every eight hours for five days. In addition, the patients were advised to rinse their mouths daily with chlorhexidine (0.12%) for 10 days and were oriented to follow a strict regimen of soft meals. The patients were examined at three days and one-week post-surgery when the sutures were removed to verify healing. Posteriorly, all patients were controlled regularly. After six months, 6 Laser-Lok tapered internal implant (Biohorizons, Birmingham, AL), 10 Alvim CM and 10 Drive CM (Neodent, Curitiba, Brazil) were placed in the augmentation sites.

Bone biopsy collection during implant insertion

The bone samples used for histological evaluation were obtained as a by product of implant placement. Under local anesthesia, a vertical incision was made buccally in the canine area and continued horizontally and distally on the palatal side of the alveolar crest. A full-thickness flap was raised and mobilized for tension-free closure. After the bone was inspected, and the implant position was determined, a trephine hollow drill was used to prepare the cylindrical placement site. The removed bone biopsy, contained within the trephine, measured 10-12 mm in length and 2.5 mm in diameter. The implants were then inserted into the cylindrical sites, and the torque required for twist was recorded. After the implants were seated, complete wound closure was performed. The biopsied bone was quickly removed from the trephine and fixed in buffered 4% formaldehyde. After a week of fixation, they were decalcified in 5% formic acid for two weeks. The decalcified cylindrical specimens were embedded in paraffin. Posteriorly, the embedded cylinders were cut longitudinally to obtain two equal parts. Then, central sections were obtained by microtome and processed for their stain with hematoxylin and eosin and light microscopy analysis.

Morphometric analysis of CBCT and histologic sections

Morphometric analyses of the surgical site were performed on the CBCT scans of each patient: one taken before the surgical procedure and the other before the biopsy and implant placement (about six months). Histomorphometric analysis were performed on the biopsy images from 5 patients. Areas of the sections were captured for measurement at the appropriate magnification by the camera associated with the light microscopy. Posteriorly, images were processed by photographic software (Adobe Photoshop CC), and the measurements of biomaterial and the trabecular bone areas were performed using the software Image J 1.48 v (Wayne Rasband, National

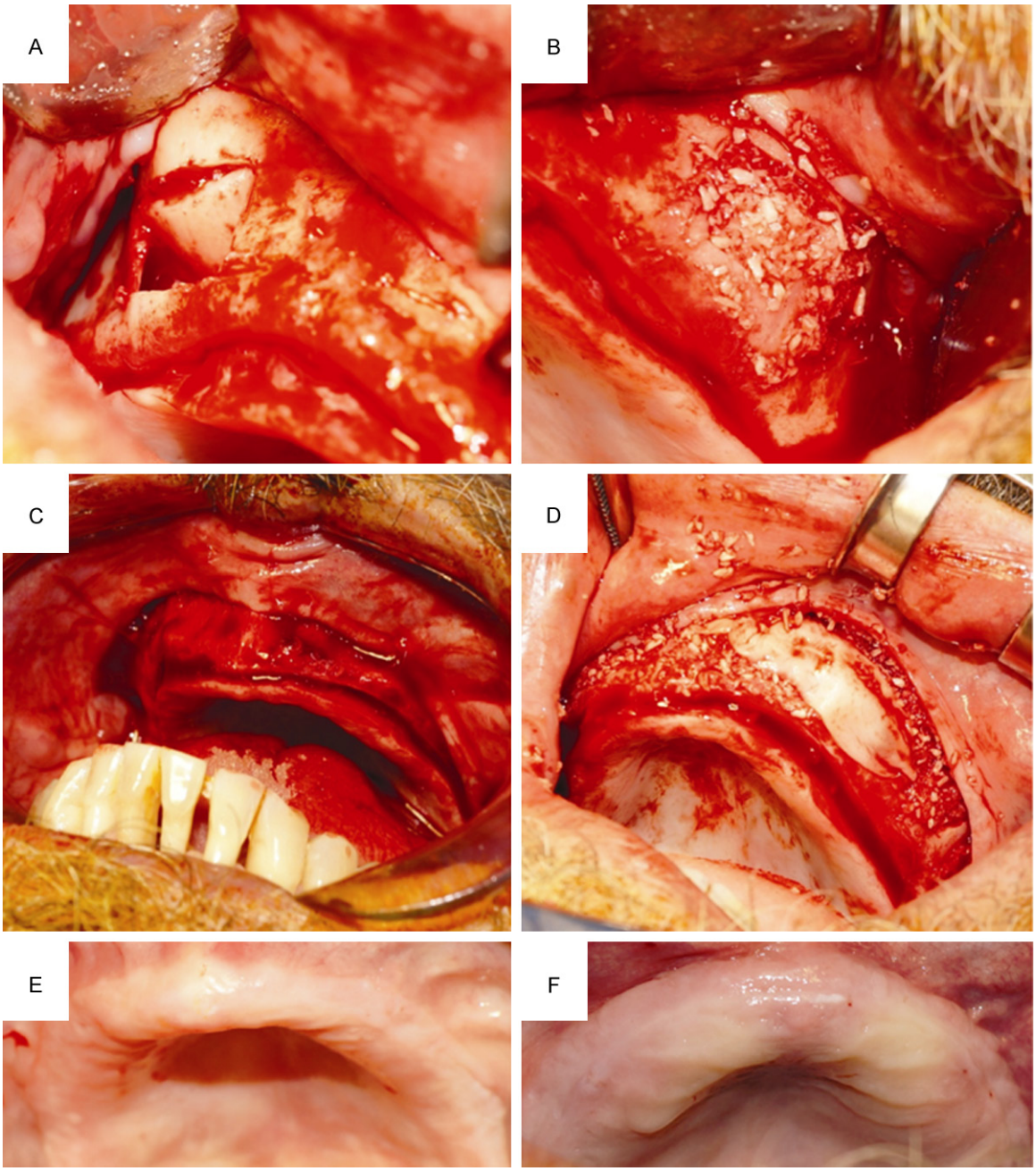

Figure 2. Bilateral sinus floor augmentation by mineralized cancellous bone allograft (Puros®) mixed with PRF using open access technique and alveolar wall reconstruction supported by PRF membrane (A and B). Maxillary alveolar atrophy (C and E) was reconstructed by the application of the same material on the buccal zone. Note that the PRF membrane was mixed with bone allograft (D). Healthy soft tissues and enlarged bone volume were achieved six months after surgery (F).

Institutes of Health, USA) and IBM SPSS Inc software version 23, for descriptive statistics analysis such as mean of percentage. The percentages of biomaterial or trabecular bone areas were calculated by: (biomaterial) or (trabecular) multiplied by 100 and then divided by the total area selected (100%).

Results

Clinical presentation and results

For analysis of the procedure results, one case is presented with its associated images (**Figures 1-3**). A 52-year-old man with a long-

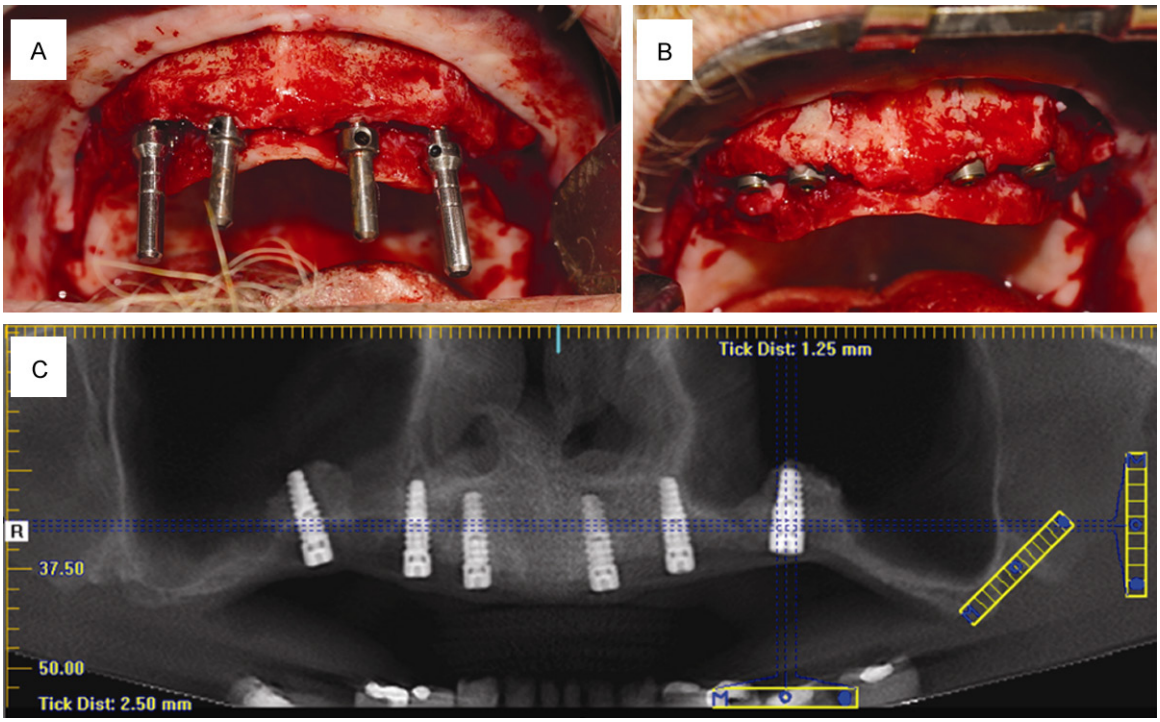

Figure 3. Clinical view of implant placement (A and B). Note the vestibular bone augmented after insertion of mineralized cancellous bone allograft mixed with PRF (B). CBCT shows that the gain of bone permitted six implants placement in a patient with poor bone structure before sinus lift and alveolar bone augmentation surgery (C).

Table 1. Measurements of bone height gain after six months of mineralized cancellous bone allograft with PRF obtained with CBCT

Maxilla side					
Pre-operative (mm)				Post-operative (mm)	
Age (years)	Sex	Right	Left	Right	Left
50	F	4.00	3.50	15.00	14.50
60	M	4.75	3.20	14.00	13.50
65	F	2.67	2.20	13.50	14.00
52	M	3.20	3.50	14.50	14.00

Note that the vertical gain are about 10 mm, which can be considered an efficient outcome of sinus lift.

time upper maxillary edentulous was evaluated for fixed rehabilitation using dental implants. CBCT showed bilateral insufficient height of the implant site with less than 2 mm of vertical bone due to sinus pneumatization and loss of alveolar height (**Figure 1**). Characteristics from type IV to VI were observed in the anterior maxillary bone (from midline to canine), according to the Cawood and Howels alveolar atrophy classification (**Figures 1** and **2**). On the basis of these results, bilateral sinus floor augmentation and reconstruction of the narrow alveolar maxillary ridge were performed, with allograft bone particles mixed with PRF (**Figure 2**). After six months, a total of six Laser-Lok tapered internal implants (Biohorizons, Birmingham, AL) were placed in the maxilla, with stability of 35 Ncm of the initial insertion torque (**Figure 3A-C**).

CBCT and histological analysis

For all the patients, the average pre-surgical anterior alveolar height was 3.8±0.2 mm. Analysis of CBCT, before and after bone augmentation (about six months), revealed a vertical total gain around 10 mm in Maxila (**Table 1**; **Figure 1A**), from 35% to 54% of horizontal alveolar augmentation (**Table 2**; **Figure 1B** and **1C**). Also improvement in bone thickness and continuity between the original bone and grafted area were confirmed (**Figures 1B**, **1C** and **2F**).

Histomorphometric analysis of biopsy from anterior alveolar zone showed new bone formed in relation to the allograft. In general, the microscopic study showed continuous osseous trabeculae with integrated particles of biomaterial integrated. After six months, the permanence average of biomaterial was variable, from 38%

Table 2. Horizontal measurements of bone gain in the maxillary alveolar ridge after six months by mineralized cancellous bone allograft with PRF obtained with CBCT

		Alveolar ridge									
		Pre-operative (mm)					Post-operative (mm)				
		Midline	Lateral Incisor		Canine		Midline	Lateral Incisor		Canine	
Age (years)	Sex		Right	Left	Right	Left		Right	Left	Right	Left
52	M	3.00	4.50	4.00	NA	NA	5.30	7.00	7.20	NA	NA
50	M	3.05	4.25	3.58	4.60	3.40	6.09	6.80	6.50	7.82	7.21
46	F	NA	4.00	NA	4.00	NA	NA	6.50	NA	8.80	NA

Post-operative analysis showed from 35 to 54% of bone gain. The not measured were indicated as "Not Applied" (NA).

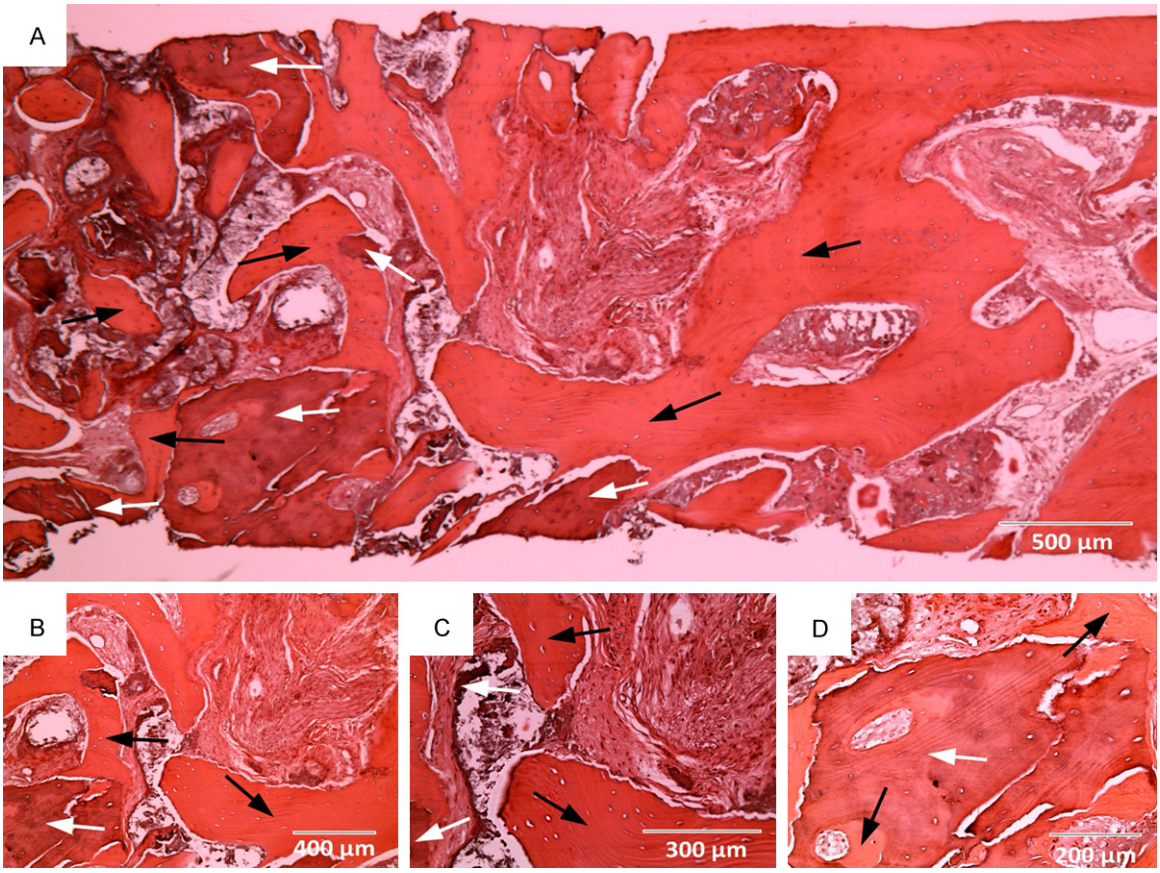

Figure 4. Photomicrograph of the biopsy showing trabecular bone with residual bone substitute (Puros®). In images A to D, the new bone (black arrows) is observed among Puros® particles (white arrows). The biomaterials particles are observed integrated to native bone trabeculae. The augmented image in C and D, show lamellar organization of trabecular bone with superficial osteoclastic action (Howship lacunae), sign of bone reparative activity. After six months, the histology show that the biomaterial is still present, but also reveals reparative activity of vital bone to replace the biomaterial (Hematoxylin Eosin stain).

to 63%. The trabecular bone had appearance of mature bone tissue, having osteocyte lacunae distributed in regular form, and formed approximately a 60% of lamellar bone. Irregular distribution of Howship's lacunae in relation to biomaterial and native bone tissue was observed, presented by tissue remodeling (**Figure 4A-D**).

Discussion

As a result of the sinus lift procedure using a mineralized cancellous bone allograft mixed with PRF and PRF membrane, in the cases described here, a remarkable amount of regenerated bone volume was observed. This condition can be associated with biomaterial stabili-

ty and the multiple properties of PRF for stimulating osteogenic cells by activating growth factors, inducing osteoblast proliferation and differentiation, with a fast bone formation as a consequence [11, 12]. Additionally, the use of PRF membranes in sinus lift procedures, as a lateral coverage for bone graft materials, has also been successfully associated with new bone formation [9, 10].

Alveolar ridge formation and its stability have been a challenge for implantologists after bone graft application. Recently, studies showed successful effect of the PRF with sterilized allogeneic bone grafts in reconstruction of atrophied or destroyed alveolar ridges [13]. In corroboration, our studies supported the favourable effect of PRF mixed with a mineralized cancellous bone allograft and external PRF membrane. This method induced fast regeneration with high bone quality, offering good support for dental implant with initial insertion torque of 35 Ncm. Although it is a difficult clinical parameter to measure, fast healing of soft tissue was observed in the cases described. Several studies demonstrated that PRF accelerates healing at earlier time points, leading to less discomfort to the patient and avoiding, for example, infection, poor wound closure, and delays in formation of strong bone for subsequent implant procedures [14, 15]. In addition, studies in vitro have showed that PRF induces cell proliferation and migration, such as gingival fibroblasts and oral epithelial cells, which contributes to explaining the fast healing [16]. Our histologic description were comparable to the those of Schmitt [17], who reported the close contact of the newly formed bone with the bone substitute using mineralized cancellous bone allograft (Puros®) in the sinus floor augmentation. In conclusion, our report showed that PRF mixed with mineralized cancellous bone allograft and external PRF membrane generates favourable bone support to dental implant by sinus floor augmentation and maxillary alveolar bone reconstruction.

Acknowledgements

This study was supported partially by a research grant of ILAPEO, Curitiba, Brazil and was registred as project research (DI12-PE06) in the Universidad de La Frontera, Temuco, Chile.

Disclosure of conflict of interest

None.

Address correspondence to: Victor Beltrán, Research Centre in Dental Sciences (CICO), Dental School,Universidad de La Frontera, Manuel Montt 112, Temuco, Chile; CP: 4781176; Tel: 56-45-232-5775; E-mail: victor.beltran@ufrontera.cl; Márcio Lazzarini, Department of Molecular Biology of Neuronal Signals, Max Planck Institute of Experimental Medicine, Göttingen, Germany. E-mail: lazzarini@em.mpg.de

References

[1] Misch CM. Maxillary autogenous bone grafting. Dent Clin North Am 2011; 55: 697-713.
[2] Cordaro L. Bilateral simultaneous augmentation of the maxillary sinus floor with particulated mandible. Report of a technique and preliminary results. Clin Oral Implants Res 2003; 14: 201-206.
[3] van den Bergh JP, ten Bruggenkate CM, Krekeler G, Tuinzing DB. Sinus floor elevation and grafting with autogenous iliac crest bone. Clin Oral Implants Res 1998; 9: 429-435.
[4] Barone A, Ricci M, Romanos GE, Tonelli P, Alfonsi F, Covani U. Buccal bone deficiency in fresh extraction sockets: a prospective single cohort study. Clin Oral Implants Res 2015; 26: 823-30.
[5] Mosesson MW. Fibrinogen and fibrin structure and functions. J Thromb Haemost 2005; 3: 1894-1904.
[6] Gruber R, Karreth F, Frommlet F, Fischer MB, Watzek G. Platelets are mitogenic for periosteum-derived cells. J Orthop Res 2003; 21: 941-948.
[7] Lind M. Growth factor stimulation of bone healing. Effects on osteoblasts, osteomies, and implants fixation. Acta Orthop Scand Suppl 1998; 283: 2-37.
[8] Metzler P, von Wilmowsky C, Zimmermann R, Wiltfang J, Schlegel KA. The effect of current used bone substitution materials and platelet-rich plasma on periosteal cells by ectopic site implantation: an in-vivo pilot study. J Craniomaxillofac Surg 2012; 40: 409-415.
[9] Gassling V, Purcz N, Braesen JH, Will M, Gierloff M, Behrens E, Acil Y, Wiltfang J. Comparison of two different absorbable membranes for the coverage of lateral osteotomy sites in maxillary sinus augmentation: a preliminary study. J Craniomaxillofac Surg 2013; 41: 76-82.
[10] Zhang Y, Tangl S, Huber CD, Lin Y, Qiu L, Rausch-Fan X. Effects of Choukroun's platelet-rich fibrin on bone regeneration in combina-

tion with deproteinized bovine bone mineral in maxillary sinus augmentation: a histological and histomorphometric study. J Craniomaxillofac Surg 2012; 40: 321-328.
[11] Singh A, Kohli M, Gupta N. Platelet rich fibrin: a novel approach for osseous regeneration. J Maxillofac Oral Surg 2012; 11: 430-434.
[12] Ozdemir H, Ezirganli S, Isa Kara M, Mihmanli A, Baris E. Effects of platelet rich fibrin alone used with rigid titanium barrier. Arch Oral Biol 2013; 58: 537-544.
[13] Krasny M, Krasny K, Kaminski A, Zadurska M, Piekarczyk P, Fiedor P. Evaluation of safety and efficacy of radiation-sterilized bone allografts in reconstructive oral surgery. Cell Tissue Bank 2013; 14: 367-374.
[14] Davis VL, Abukabda AB, Radio NM, Witt-Enderby PA, Clafshenkel WP, Cairone JV, Rutkowski JL. Platelet-rich preparations to improve healing. Part II: platelet ctivation and enrichment, leukocyte inclusion, and other selection criteria. J Oral Implantol 2014; 40: 511-521.
[15] Liao HT, Marra KG, Rubin JP. Application of platelet-rich plasma and platelet-rich fibrin in fat grafting: basic science and literature review. Tissue Eng Part B Rev 2014; 20: 267-276.
[16] Li Q, Pan S, Dangaria SJ, Gopinathan G, Kolokythas A, Chu S, Geng Y, Zhou Y, Luan X. Platelet-rich fibrin promotes periodontal regeneration and enhances alveolar bone augmentation. Biomed Res Int 2013; 2013: 638043.
[17] Schmitt CM, Doering H, Schmidt T, Lutz R, Neukam FW, Schlegel KA. Histologicalresults after maxillary sinus augmentation with Straumann®BoneCeramic, Bio-Oss®, Puros®, and autologous bone. A randomized controlled clinical trial. Clin OralImplants Res 2013; 24: 576-585.