

Original Article

Observation of curative effect regarding corneal cross-linking treatment of riboflavin combined with 440 nm blue-light cornea for fungal keratitis

Cuiying Zhang^{1,2}, Shufang Wei², Liying Zhang², Weijing Li², Yan Lv², Guoying Mu¹

¹Department of Ophthalmology, Provincial Hospital Affiliated to Shandong University, Jinan 250100, Shandong, China; ²Department of Ophthalmology, Liaocheng People's Hospital in Shandong Province, Liaocheng 252000, Shandong, China

Received August 10, 2015; Accepted December 24, 2015; Epub February 15, 2016; Published February 29, 2016

Abstract: To observe and analyze the curative effects of the treatment of riboflavin combined with 440 nm blue-light corneal cross-linking (CXL) treatment for fungal keratitis via a rabbit model experiment. A model of rabbit fungal keratitis was used through anterior stromal injection in which 24 rabbits were randomly divided into blank control, 360 nm group, and 440 nm group. Both groups underwent CXL treatment. Ultraviolet radiation A (365 nm) and blue-light (440 nm) irradiations were performed for 30 min after 30 min of 0.1% riboflavin eye drops used in 360 nm and 440 nm groups, respectively. Slit-lamp observation, photography of the cornea, calculation of ulcer area, and comparison of examination under confocal microscope were performed for all rabbits on the first, third, and seventh days after treatment. No statistical significance was observed between all groups on the first day after treatment ($P>0.05$). In 3 days after surgery, the cornea ulcer area decreased by 35.65% in the 360 group ($P=0.012$) and 37.94% in the 440 group ($P=0.015$), thus the two groups showing no statistical significance ($P=0.88$). In 7 days after surgery, the area vanished by 59.02% in the 360 group ($P=0.00$) and 55.29% in the 440 group ($P=0.001$), thus the two groups showing statistical significance ($P=0.75$). Riboflavin with 440 nm blue-light irradiation had a positive effect on treatment for fungal keratitis.

Keywords: 440 nm blue-light, CXL, rabbit, fungal keratitis, confocal microscope

Introduction

Fungal keratitis, a type of infectious corneal disease, is the most crucial cause of corneal blindness for its significantly high blind rate. The productive injury of cornea offers a chance to fungus infection. A wide use of antibiotics, cortical hormone, antiviral drugs, and contact lens increase the morbidity of mycosis. Fungus is divided into two types: filamentous bacteria (such as *Fusarium*, *Aspergillus*, *Penicillium*, and dematiaceous fungi) and yeast (*Candida* is the main type). The main pathogenic bacteria in developed countries and colder areas is *Candida albicans*; reports of fungal keratitis across the globe are mainly focusing on the study of *C. albicans*, *Fusarium*, *Aspergillus*, and rare dematiaceous fungi [1]. It is critical to conduct active treatments such as slit-lamp microscopy and smear examination for patients with fungal keratitis according to history. Treating with topi-

cal or combined with systemic antifungal drugs is still the main method nowadays. However, the effects are limited because of the great toxicity and little penetrating power to ocular tissue, making the drug therapy relatively difficult. In addition, corneal ulcer scraping combined with iodine cauterization is also utilized, but effects were limited [2]. The role regarding the therapy of riboflavin combined with 360 nm ultraviolet radiation A (UVA) corneal cross-linking (CXL) for fungal keratitis has been confirmed in animal and clinical experiments [3-7].

Material and methods

Animal model making of fungal keratitis

C. albicans solution preparation: First, strains were revived according to the procedures from the institution offering strains, and then a large number of active ingredients were obtained for trial via fungal culture. Reports across the globe

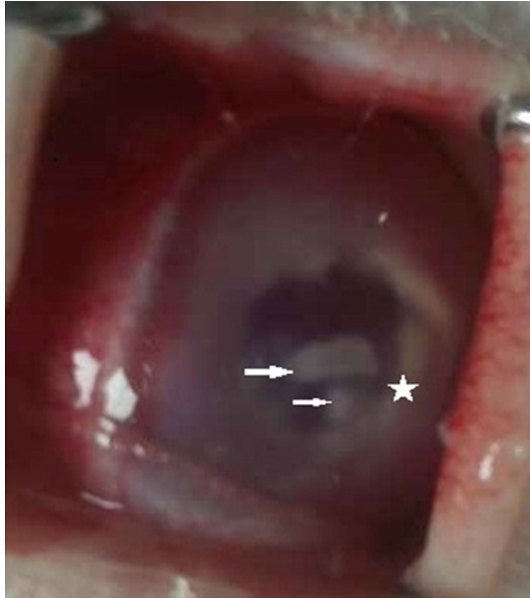

Figure 1. In 3 days after being infected with *Candida albicans*, evident tongue fur with necrotic tissues became stick shaped. The ulcer edges were slightly uplifted and were coarse. Some ulcers were accompanied with satellite lesions. Endothelial plaques were on the endothelial layers and corneas suffered diffusive fog edema. Empyemata were seen in anterior chambers. Arrows represented ulcer foci and satellite lesions, and the places star marked were anterior chamber empyemata.

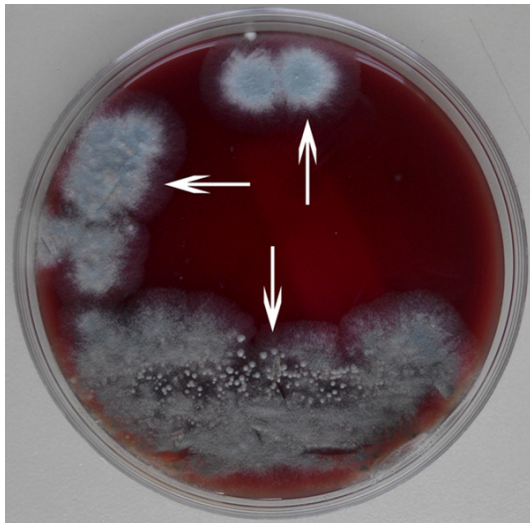


Figure 2. Corneal scrapings were cultured and colonies of *C. albicans* grew (arrows pointed).

on the concentration of bacterial solution making cornea infected with fungus are different. The concentration ranges from 10^6 to 10^{10} CFU/ml, and there is no unified standard now. Nonetheless, the volume of inoculating bacte-

ria solution at a time is limited. The concentration of *C. albicans* solution was 10^6 CFU/ml referring to it in animal experiments by Zhong et al. for the study [8].

Model making of *C. albicans* in rabbits: The animal experiment scheme was approved by Animal Ethics Committee and was in conformity with the principle of animal protection, welfare, ethical principles, and regulations of national animal welfare ethics.

A total of 24 healthy ripe New Zealand White rabbits, 2.5-3.0 kg, male and female, bought from the experimental animal center of Shandong Province, were bred in clean conventional environment with the temperature of 20-25°C and humidity of 40%-70% for 2 weeks. After it, a slit-lamp microscope was used to inspect and confirm the absence of anterior disease of eye, and the right eyes were always set as model eyes. First, experimental rabbits were anesthetized with 10% choral hydrate (3 ml/kg) through intraperitoneal injection, and oxybuprocaine hydrochloride eye drops were used for the surface anesthesia of eyes for three times. Second, heads were fixed, and then the conjunctival sac was irrigated with normal saline after surgery by holding the eyelids open using an eye speculum. Third, the bacterial solution of *C. albicans* was extracted with 1 ml sterile syringe, 0.1 ml solution was injected to central anterior stromal injection, and circular moderate retinal discoloration (d=4 mm) was shaped. Corneal scraping was cultured, and confocal microscope examination was done for many times in 3-5 days after making models.

CXL treatment for fungal keratitis

The cornea was photographed, and the ulcer areas were calculated with IMAGE J software for all experimental rabbits before treatment. CXL treatments were implemented for model rabbits in 360 and 440 groups, while nothing was done to the blank control group on the fifth day after the models of rabbit fungal (*C. albicans*) keratitis were completed. First, experimental rabbits were anesthetized with 10% choral hydrate (3 ml/kg) through an intraperitoneal injection, and oxybuprocaine hydrochloride eye drops were used for surface anesthesia of eyes for three times. Second, heads were fixed, and then conjunctival sac was irrigated with 0.1% riboflavin every 2 min for 0.5 h after surgery by holding the eyelids open using an

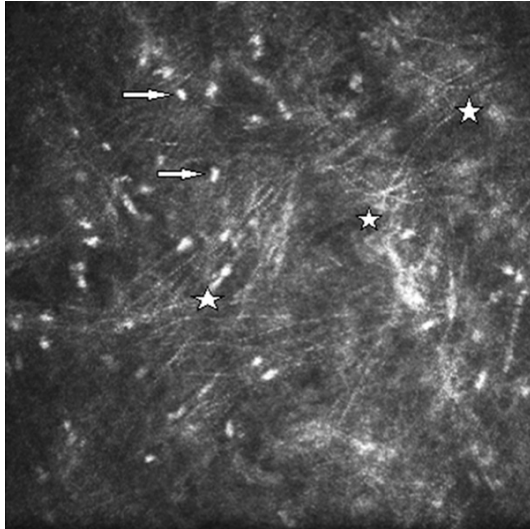


Figure 3. A large number of fungal and inflammatory cell hyphae became cluster cable shaped with high refractive index, and the fungal hyphae were slender and curved under the confocal microscope. Stars represented cluster cable-shaped hyphae, and arrows represented inflammatory cells.

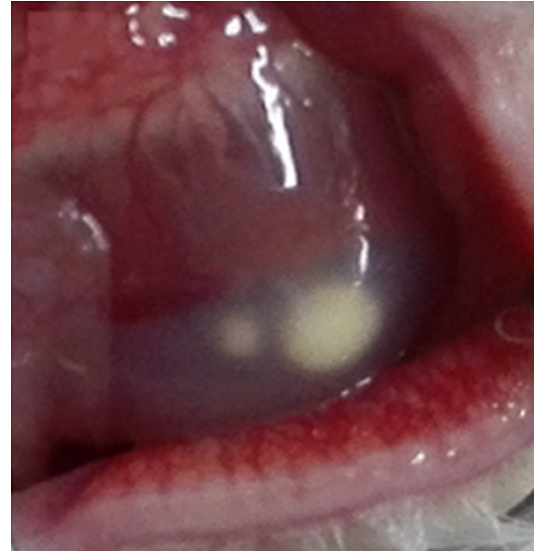


Figure 5. Areas of corneal ulcer focals increased, and satellite lesions were observed around the corneas. Diffusive cornea aggravated, and the irises could not be seen.

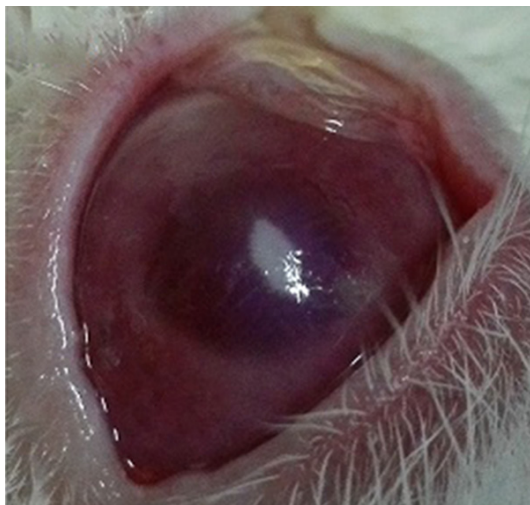

Figure 4. Corneal ulcer was formed, slight edema appeared in cornea, iris texture was seen, and empyemata were not found in anterior chambers.

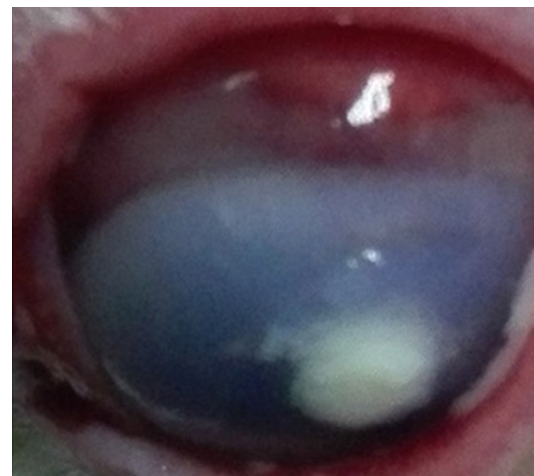


Figure 6. Areas of corneal ulcer focals further increased. Ulcer focals with tongue fur-shaped necrotic tissue mixed with satellite lesions were observed. Ulcer edges were slightly uplifted and coarse. Corneas seriously suffered diffusive fog edemas, and empyemata were found in anterior chambers.

eye speculum. In the experimental group, each cornea was dealt with both 360 nm UVA and 440 nm blue-light irradiation; distance from light source to cornea was 5 cm and the energy was 3 mW/cm². Riboflavin eye drops were administrated every 2 min persistently. The rabbits received tobramycin eye drops one time after surgery and were returned to animal workshop.

Observation indexes

Cornea, ulcer area, and intraocular status were observed in 1, 3, and 7 days after CXL.

The cornea was photographed and the ulcer areas were calculated with IMAGE J software for all experimental rabbits before treatment in 1, 3, and 7 days after CXL. Ulcer areas in all

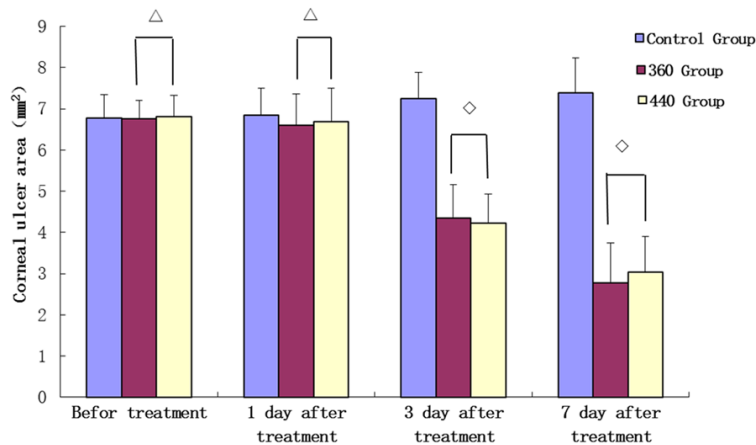


Figure 7. Comparison corneal ulcer area (mm²) before and after treatment with CXL. Note: Δ: Compared with control group P>0.05. ◇: Compared with control group P<0.05.

groups were analyzed using SPSS-17 statistical software. The groups were compared using t test, and multiple- and single-factor variance analysis method, and P<0.05 was considered statistically significant.

Confocal microscope examinations were done in 1, 3, and 7 days after CXL.

Presentation of results

Result of slit-lamp observation

The corneal ulcer was formed (**Figure 1**) in 3-5 days after finishing the model. Corneal scrapings were cultured (**Figure 2**), and confocal microscope examination (**Figure 3**) was performed for many times in 3-5 days after making models. Fungal infection was confirmed if fungal hyphae or spore was found.

Performance of slit-lamp observation before CXL and in 1, 3 and 5 days after corneas were infected with *Candida albicans* (**Figures 4-6**).

Slit-lamp observation was performed 1 day after CXL, and there were no differences compared to the prior.

Slit-lamp observation was applied on the third day after CXL; in the control group, the ulcer focals were larger, corneal edemas were severer, and more empyemata were found in anterior chambers. Corneal ulcer focals were limited; corneal edemas became slighter, and empyemata in anterior chambers were less in 360 and 440 groups.

Slit-lamp observation was performed on the seventh day after CXL, and there were no distinct differences compared to prior. Corneal ulcer focals apparently narrowed; edemas became unapparent, and empyemata in anterior chambers disappeared in 360 and 440 groups. Several ulcer focals vanished and almost healed.

The corneas were photographed and the ulcer areas were calculated with IMAGE J software for all rabbits before treatment in 1, 3 and 7 days before CXL.

There was no statistical significance for the difference before and after the treatment in respective group (P>0.05). There was statistical significance for the difference between 360 and control groups as well as between 440 and control groups (P<0.05). There was no statistical significance for the difference between 360 and 440 groups (P>0.05). Data analysis demonstrated that corneal ulcer areas in the control group became larger as time went on and there were no statistical differences. However, areas of 360 and 440 groups became smaller, and there were statistical significances. There was no significant difference in 1 day before and after CXL. Corneal ulcer areas of 360 and 440 groups remarkably decreased in 3 and 7 days after treatment, and there was no significant difference between the two groups. There was statistical significance for the difference between 360 and control groups as well as between 440 and control groups (**Figure 7**).

Results of confocal microscope inspection

Hyphae and spores were found under confocal microscope for all rabbits before CXL (**Figure 8A-C**).

Hyphae of 360 and 440 groups obviously decreased compared to the control group, and there was no distinct difference between 360 and 440 groups 1 day after CXL (**Figure 9A-C**).

Abundant hyphae were observed in the control group 3 days after CXL. Hyphae in 360 and 440 groups became short stick shaped (**Figure 10A-C**).

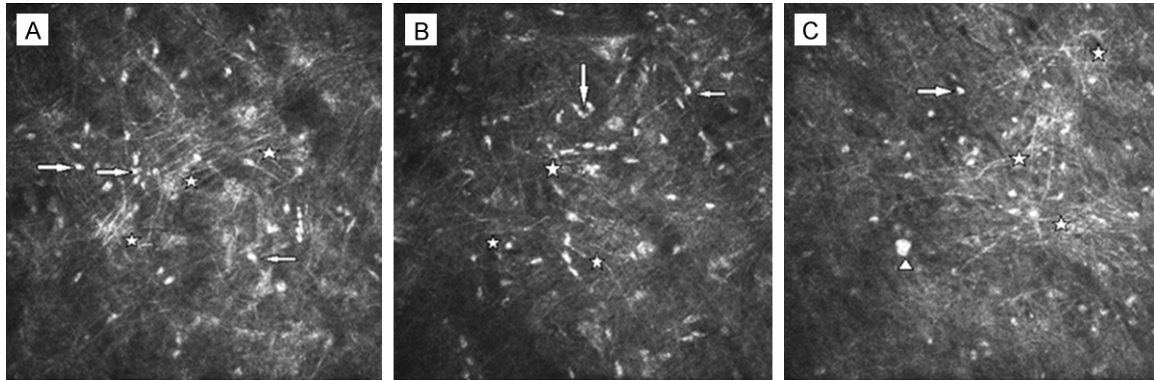


Figure 8. A-C respectively the results of control, 360 and 440 groups under confocal microscope before CXL. A great quantity of hyphae, bits of inflammatory cells, and spores were detected in every group; hyphae were slender, curve, cluster cable shaped, and had a high refractive index. Arrows represented inflammatory cells, stars represented hyphae, and triangles represented spores.

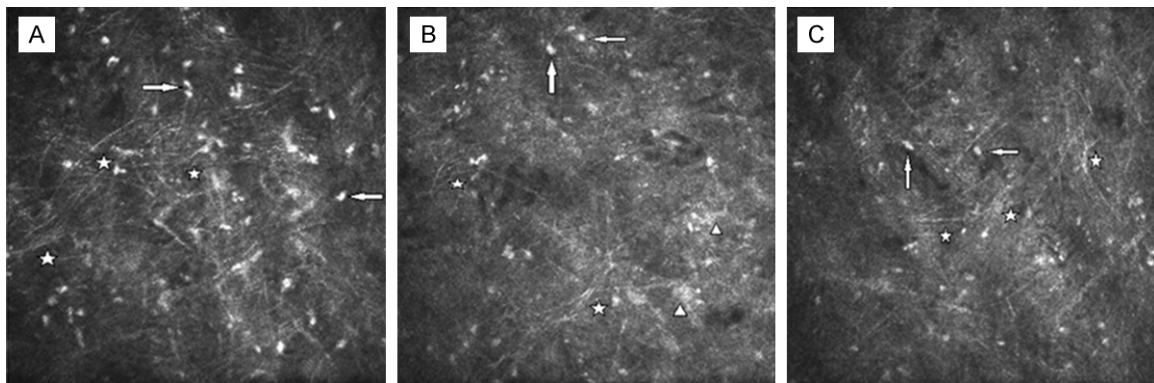


Figure 9. A-C respectively the results of control, 360 and 440 groups under confocal microscope in 1 day after CXL. A good deal of hyphae and inflammatory cells were detected in the control group. Hyphae were slender, curve, cluster cable shaped, and had a high refractive index. Arrows represented inflammatory cells, and stars represented hyphae. B and C. The figures demonstrated that hyphae decreased and became shorter and straighter; inflammatory cells were slightly less in 360 and 440 groups. Arrows represented inflammatory cells, and stars represented hyphae.

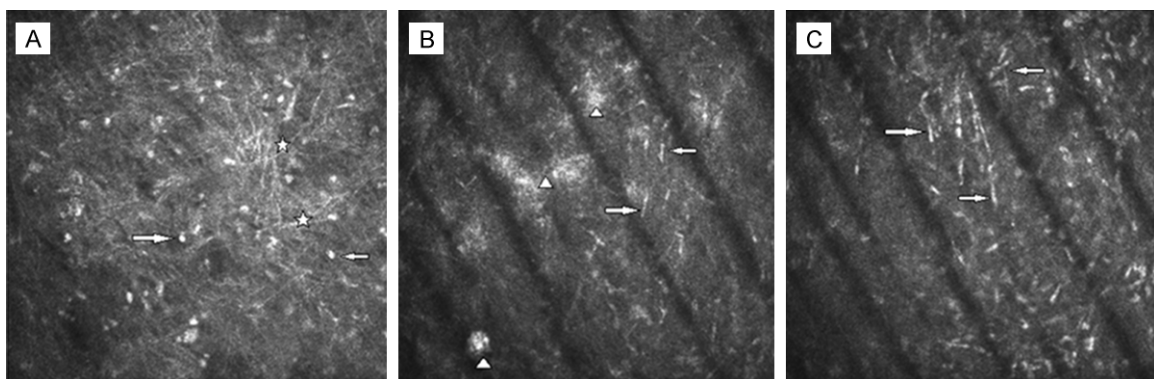


Figure 10. A-C respectively the results of control, 360, and 440 groups under confocal microscope in 3 days after CXL. A. A good deal of hyphae and inflammatory cells were detected in the control group. Hyphae were slender, curve, cluster cable shaped, and had a high refractive index. Arrows represented inflammatory cells and stars represented hyphae. B. A few hyphae and necrosis materials could be monitored. Hyphae became short, stub shaped, and had a high reflective rate in the 360 group. Arrows represented inflammatory cells and triangles indicated necrosis materials. C. Short stub-shaped hyphae with high reflective rate could be found in the 440 group. The places arrows pointed were hyphae.

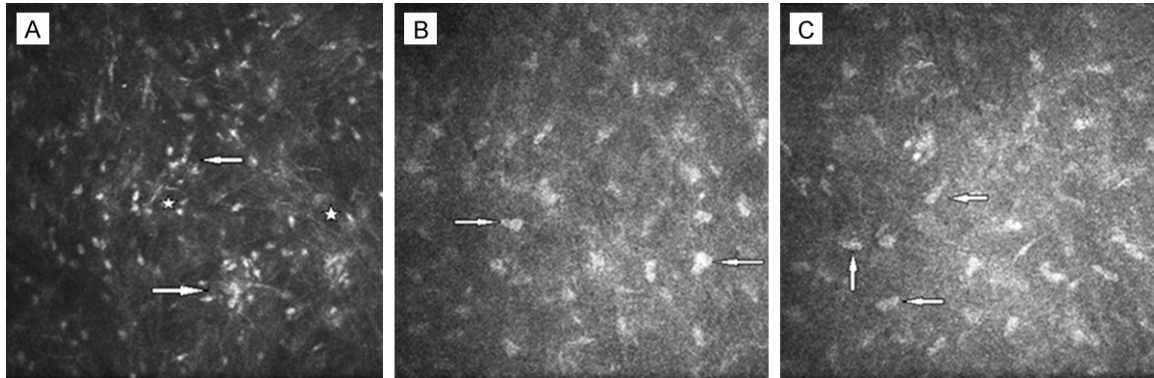


Figure 11. A-C respectively the results of control, 360 and 440 groups under confocal microscope in 7 days after CXL. A. Fungal hyphae decreased and inflammatory cells increased in the control group. Arrows represented inflammatory cells, and stars represented hyphae. B and C. Corneal stromal cells enlarged and increased, and distinct hyphae were not found. The places arrows pointed are corneal stromal cells.

Fungal hyphae reduced and inflammatory cells increased 7 days after CXL; corneal stromal cells enlarged and increased, distinct hyphae were not found, several inflammatory cells were sporadic, and there was no apparent difference in 360 and 440 groups (Figure 11A-C).

Fungus culture results: hyphae and spores were not found in 2 rabbits of 24 model rabbits although smear and culture were done for many times.

Discussion

Injecting spores into corneal stromal cells of rabbits to cause fungal infection in fungal keratitis model is widely used internationally [9]. The method of injecting spores into corneal stromal cells has high success rate, low rate in diverse infection, low cost, and surgery is convenient. But it is easy to appear corneal perforation to cause eye infection. Injecting spores to anterior stromal, which was applied in the model, significantly decreased the probability of corneal perforation. However, there were two cases of corneal perforation due to inadequate anesthesia. The surgery should be slight and anesthesia should be plenitude. Spores should be injected to stromal to cause deep infection.

Confocal microscope was employed to study cornea more than 20 years ago [10]. Due to that the function of confocal section [11], tissue slice, fix, and staining were unnecessary. Although without the steps above, it is easily detect the tangible compositions of normal as well as lesion corneas fully. Confocal microscope inspection for fungal keratitis is accurate, noninvasive, fast, and effective. Fungus culture

could be made from corneal scraping tissues, lesion corneas, and eye pus. Nonetheless, the appearance of positive result may need at least 1 week, positive rate was not high, and elimination of negative result would need 3 weeks. Moreover, hyphae and spores of 2 cases in 24 models detected via confocal microscope could not be found by smear and culture. Thus smear and culture cannot be adopted to the early diagnosis of fungal keratitis; whereas, it can identify the spectrums of pathogens for the clinical treatment instruction.

Riboflavin has two absorption peaks (360 nm and 440 nm), and high energy. UVA irradiation has reached to a larger CXL effects ($W=h \cdot c / \lambda$, λ =wavelength, c =light velocity, h =Planck constant) [12]. The energy of UVA is 5.4 J/cm² (3 mW/cm²) and wavelength is 365 nm (which is lower than the damage threshold of UV to corneal endothelial cell), and crystalline lens and retina are safe in clinical application nowadays. A total of 400 papers on new forms of keratopathy CXL treatment have been published on related journals on PubMed since the first article about CXL issued. A study demonstrated that stable biochemical actions caused by CXL owe to the change of tertiary structure in collagen fibers, preventing proteolytic enzymes arrive at the specific enzymolysis sites [13] after CXL. CXL can not only act on the cornea including improving the hardness and elastic modulus of cornea [12, 14], reducing corneal edema [15, 16], making fibers thick [17], and enhancing the resistance to enzymatic degradation [18, 19], but also bring down the corneal permeability [20, 21] and kill bacteria and fungus [4, 6, 22-25]. The principle is that CXL

treats infectious keratitis [23, 26, 27]. Adverse reactions brought by CXL mainly include the direct damage caused by UV irradiation and indirect injury caused by photochemical effect. The direct damage depends on the wavelength, radiosity, and irradiation time. The indirect injury is induced by free radical produced by riboflavin motivated through UV.

Corneal ulcer areas of fungal keratitis remarkably decreased and recovery speed increased in 3 days after the treatment of 360 nm UVA and 440 nm blue-light irradiation with riboflavin CXL. Ulcer areas could be further reduced and several participants could be cured in 7 days after CXL. However, ulcer areas did not change as time went on in the control group. The fungal hyphae in the cornea were detected with confocal microscope exactly, noninvasively, fast, and effectively. Results indicated that hyphae evidently decreased compared to the control group, and became short, stick, stub shaped from the slender shape and finally disappeared after the CXL treatment of riboflavin with 440 nm blue light and 360 nm UVA irradiation. The CXL treatment of riboflavin with 440 nm blue light and 360 nm UVA irradiation was justified through etiology, but the toxic and side effects need further inspection.

Disclosure of conflict of interest

None.

Address correspondence to: Guoying Mu, Department of Ophthalmology, Provincial Hospital Affiliated to Shandong University, Jinan 250100, Shandong, China. Tel: +86-18953911166; Fax: +86-021-64085875; E-mail: zhangcuiying80@126.com

References

- [1] Kredics L, Narendran V, Shobana CS, Vagvolgyi C and Manikandan P. Filamentous fungal infections of the cornea: a global overview of epidemiology and drug sensitivity. *Mycoses* 2015; 58: 243-260.
- [2] FlorCruz NV and Evans JR. Medical interventions for fungal keratitis. *Cochrane Database Syst Rev* 2015; 4: Cd004241.
- [3] Martins SA, Combs JC, Noguera G, Camacho W, Wittmann P, Walther R, Cano M, Dick J and Behrens A. Antimicrobial efficacy of riboflavin/UVA combination (365 nm) in vitro for bacterial and fungal isolates: a potential new treatment for infectious keratitis. *Invest Ophthalmol Vis Sci* 2008; 49: 3402-3408.
- [4] Makdoui K, Mortensen J and Crafoord S. Infectious keratitis treated with corneal cross-linking. *Cornea* 2010; 29: 1353-1358.
- [5] Spiess BM, Pot SA, Florin M and Hafezi F. Corneal collagen cross-linking (CXL) for the treatment of melting keratitis in cats and dogs: a pilot study. *Vet Ophthalmol* 2014; 17: 1-11.
- [6] Shetty R, Nagaraja H, Jayadev C, Shivanna Y and Kugar T. Collagen crosslinking in the management of advanced non-resolving microbial keratitis. *Br J Ophthalmol* 2014; 98: 1033-1035.
- [7] Said DG, Elalfy MS, Gatziofous Z, El-Zakzouk ES, Hassan MA, Saif MY, Zaki AA, Dua HS and Hafezi F. Collagen cross-linking with photoactivated riboflavin (PACK-CXL) for the treatment of advanced infectious keratitis with corneal melting. *Ophthalmology* 2014; 121: 1377-1382.
- [8] Zhong W, Yin H and Xie L. Expression and potential role of major inflammatory cytokines in experimental keratomycosis. *Mol Vis* 2009; 15: 1303-1311.
- [9] Leal SM Jr and Pearlman E. The role of cytokines and pathogen recognition molecules in fungal keratitis-Insights from human disease and animal models. *Cytokine* 2012; 58: 107-111.
- [10] Cavanagh HD, Jester JV, Essepian J, Shields W and Lemp MA. Confocal microscopy of the living eye. *Ciao J* 1990; 16: 65-73.
- [11] Shang R, Chen S, Li C and Zhu Y. Spectral modulation interferometry for quantitative phase imaging. *Biomed Opt Express* 2015; 6: 473-479.
- [12] Spoerl E, Huhle M and Seiler T. Induction of cross-links in corneal tissue. *Exp Eye Res* 1998; 66: 97-103.
- [13] Macfie A, Hagan E and Zhitkovich A. Mechanism of DNA-protein cross-linking by chromium. *Chem Res Toxicol* 2010; 23: 341-347.
- [14] Ahearne M, Yang Y, Then KY and Liu KK. Non-destructive mechanical characterisation of UVA/riboflavin crosslinked collagen hydrogels. *Br J Ophthalmol* 2008; 92: 268-271.
- [15] Wollensak G, Aurich H, Pham DT and Wirbelauer C. Hydration behavior of porcine cornea crosslinked with riboflavin and ultraviolet A. *J Cataract Refract Surg* 2007; 33: 516-521.
- [16] Ehlers N and Hjortdal J. Riboflavin-ultraviolet light induced cross-linking in endothelial decompensation. *Acta Ophthalmol* 2008; 86: 549-551.
- [17] Wollensak G, Wilsch M, Spoerl E and Seiler T. Collagen fiber diameter in the rabbit cornea after collagen crosslinking by riboflavin/UVA. *Cornea* 2004; 23: 503-507.
- [18] Spoerl E, Wollensak G and Seiler T. Increased resistance of crosslinked cornea against enzy-

- matic digestion. *Curr Eye Res* 2004; 29: 35-40.
- [19] Matsumoto K. Role of bacterial proteases in pseudomonal and serratial keratitis. *Biol Chem* 2004; 385: 1007-1016.
- [20] Stewart JM, Schultz DS, Lee OT and Trinidad ML. Exogenous collagen cross-linking reduces scleral permeability: modeling the effects of age-related cross-link accumulation. *Invest Ophthalmol Vis Sci* 2009; 50: 352-357.
- [21] Stewart JM, Schultz DS, Lee OT and Trinidad ML. Collagen cross-links reduce corneal permeability. *Invest Ophthalmol Vis Sci* 2009; 50: 1606-1612.
- [22] O'Brart DP. Corneal collagen cross-linking: a review. *J Optom* 2014; 7: 113-124.
- [23] Micelli Ferrari T, Leozappa M, Lorusso M, Epifani E and Micelli Ferrari L. *Escherichia coli* keratitis treated with ultraviolet A/riboflavin corneal cross-linking: a case report. *Eur J Ophthalmol* 2009; 19: 295-297.
- [24] Salomao MQ, Chaurasia SS, Sinha-Roy A, Ambrosio R Jr, Esposito A, Sepulveda R, Agrawal V and Wilson SE. Corneal wound healing after ultraviolet-A/riboflavin collagen cross-linking: a rabbit study. *J Refract Surg* 2011; 27: 401-407.
- [25] Sauer A, Letscher-Bru V, Speeg-Schatz C, Touboul D, Colin J, Candolfi E and Bourcier T. In vitro efficacy of antifungal treatment using riboflavin/UV-A (365 nm) combination and amphotericin B. *Invest Ophthalmol Vis Sci* 2010; 51: 3950-3953.
- [26] Wilson SL, El Haj AJ and Yang Y. Control of scar tissue formation in the cornea: strategies in clinical and corneal tissue engineering. *J Funct Biomater* 2012; 3: 642-687.
- [27] Moren H, Malmsjo M, Mortensen J and Ohrstrom A. Riboflavin and ultraviolet a collagen crosslinking of the cornea for the treatment of keratitis. *Cornea* 2010; 29: 102-104.