

## Original Article

# Anterior decompression and internal fixation for lower cervical spine dislocation

Chen Song\*, Kai Wang\*, Ziqi Yu, Liang Zhang, Yalin Yang

*Department of Orthopedics, The Second Hospital of Tianjin Medical University, Tianjin, China. \*Equal contributors.*

Received September 5, 2015; Accepted December 8, 2015; Epub February 15, 2016; Published February 29, 2016

**Abstract:** Objective: To summarize neurological outcome and complications after skull distraction combination of anterior cervical surgery managed with corpectomy, titanium mesh cage reconstruction, and cervical locking plate. Methods: A total of 42 patients with lower cervical spine fracture and dislocation were included in this study between May 2009 and September 2014. The average follow-up time was 18.3 months (ranges 8-24 months). After diagnosed clearly at admission, all patients were used of skull traction. If closed reduction failed, anterior decompression and corpectomy were performed. Titanium mesh cage filled with autograft removed from vertebral and locking plates were applied. The cervical reduction, stabilization, recovery of neurological function, and bone fusion were evaluated for the patients. Results: All patients were achieved reduction successfully and recovered the normal cervical alignment. There were no significant complications occurred during operation. Bone fusion occurred, while implant loosening, pseudarthrosis, and graft settling were not observed in six months follow-up. Dysphagia was noted in two patients and odynophagia in one patient. These two clinical symptoms disappeared without special treatment after three months. No patient was found neurological worsening during preoperative skull traction. There were 12 patients without ASIA level or upper extremity function improvement in 1 year follow-up. The post-operative ASIA grades of the thirty patients were increased at least one level. Conclusions: For the lower cervical fracture and dislocation, preoperative skull traction acting as an initial treatment is safe and effective to restore dislocation to some extent and minimize neurological function deteriorating. If this failed, anterior surgical fixation of using titanium mesh cage and locking plate is a proper choice for short operation time, little hemorrhage volume, low complication rate, and high fusion rate.

**Keywords:** Lower cervical, fracture and dislocation, distraction, anterior decompression

## Introduction

A few objective criteria regarding the treatment of lower cervical spine fracture and dislocation has been improved. Either an anterior approach or posterior surgical stabilization, even the combined procedure, has been widely used during the last decades. But which is the best method to obtain reduction and stabilization still remains controversial. As the advantages combined with posterior procedure have been confirmed, including lower morbidity and complication rates, even the postoperative immediate stabilization is equal to the cervical pedicle screw system, the use of simple anterior decompression and internal fixation for lower cervical vertebra dislocation has been widely recognized [1, 2].

However, the necessity of preoperative traction is what surgeons need to consider subsequent-

ly and based on our experience, anterior surgery combined with skull traction is always attended with satisfactory results in the treatment of lower cervical fracture and dislocation.

## Materials and methods

A total of 42 patients (32 males and 10 females) with lower cervical spine fracture and dislocation were treated by skull traction combined with anterior cervical reduction and internal fixation managed with titanium mesh cage and cervical locking plate in our institution over a 5-year period (May 2009-September 2014), were included in our study. The mean age was 32.3 years ranging from 18 to 49 years. Twenty-four cases were caused by traffic accidents, eleven cases by heavy pound injuries, and seven cases by high fall. In this study, there were 9 patients with C4/5 segment injury, 18 patients with C5/6 segment injury, 15 patients

**Table 1.** Change in ASIA grade from preoperation to postoperative follow-up

Preoperation	n	Postoperative follow-up				
		A	B	C	D	E
A	4	3	1	-	-	-
B	14	1	4	5	4	-
C	16	-	-	3	6	7
D	7	-	-	-	-	7
E	1	-	-	-	-	1

with C6/7 segment injury. Four patients had a concomitant closed head injury and twenty patients had associated fractures: rib (3), humerus (5), distal radius (12), and calcaneus (8). Patients previously undergone other cervical surgeries or dislocations resulted from tumors or infections were excluded from the study. The average follow-up time was 18.3 months (ranges 8-24 months). All patients underwent preoperative evaluation including MRI, CT scan and plain radiographs. The neurological status was recorded according to The American Spinal Cord Injury Association (ASIA) classification at the time of admission. Four cases were grade A, 14 grade B, 16 grade C, 7 grade D, and 1 grade E (**Table 1**). All cases were performed by the same four surgeons, followed the treatment strictly.

#### Preoperative traction

After diagnosed clearly at admission, all patients were followed by skull traction starting from 3 kg with cervical spine maintained in a neutral position and the neck extended (**Figure 1**). Performing lateral plain radiographs for every 20 minutes to evaluate the reduction. If it failed to achieve the reduction, increasing traction weight of 2.5 kg after each perspective until the cervical physiological curve was found on following plain film. When over-traction occurred, the traction was reduced to 3 kg. If reduction was not obtained after continuous traction, or vital signs and neurologic deterioration were found, the traction was also reduced to initial weight and the patient was treated with surgery that anterior decompression, corpectomy, titanium mesh cage reconstruction, and cervical locking plate.

#### Surgical procedure

A standard right-sided anterior approach to the cervical spine was used. After vertebral body exposed adequately, injury segments were

accurate positioned through intraoperative lateral fluoroscopy. Vertebral body posts were inserted into adjacent vertebra of damaged segments. Discectomy was then performed, opening the posterior longitudinal ligament followed by intervertebral disc tissue removal. Either a Caspar retractor or a laminar spreader was used to insert the disc space with fluoroscopy guiding and assessing the reduction. Reduction was carried with compressing the two posts and distraction blunt intervertebral retractor while cervical spine in a slightly flexion position, if necessary manual traction was taken on cervical spine by the assistant surgeon to accomplish the reduction. The fluoroscopy was used to closed monitor the affected vertebra during the procedure. Partial resecting the vertebral body was performed and the removed grinding bone was filled in a suitable titanium mesh cage, located in bone defect. The impaired segments were fixed with a formed cervical anterior locking plate held with unicortical screws to provide the stabilization.

#### Postoperative management

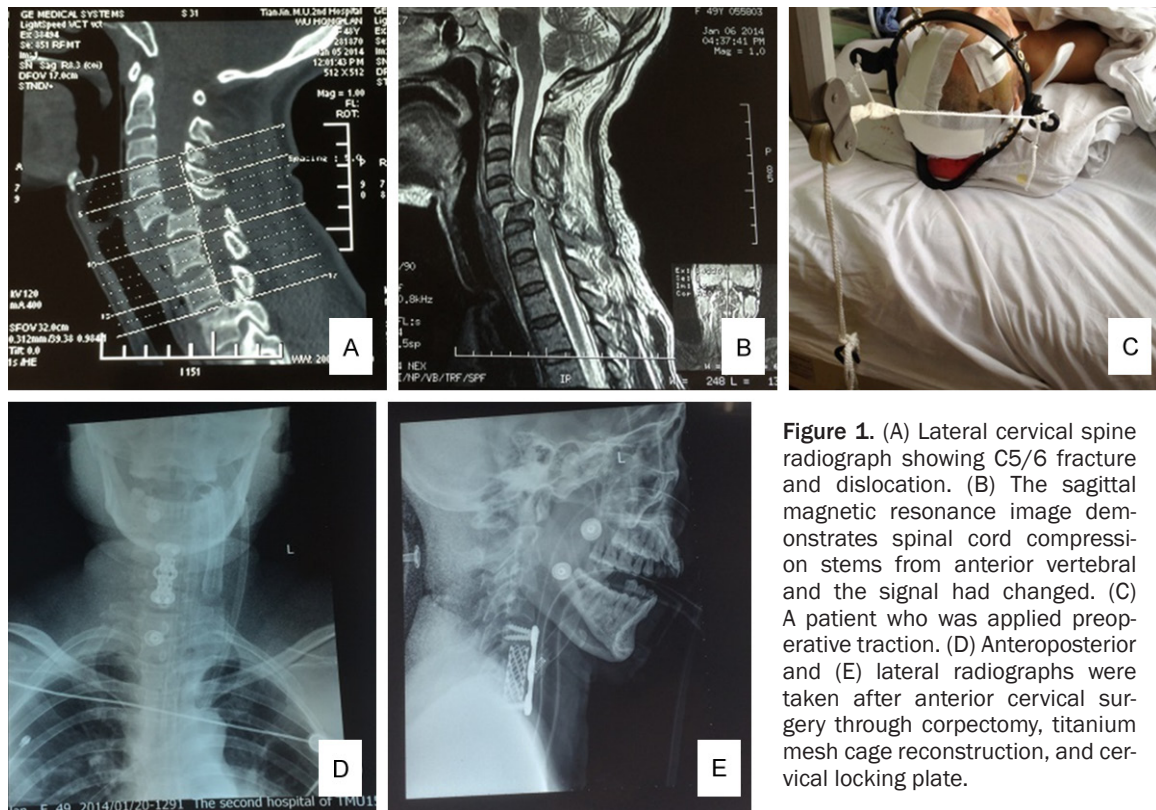
All the patients were maintained upper airway patency and kept from infection through taking antibiotics orally. Drainage of all the patients was recorded every day and their vital signs were monitored closely. If any difficulty in breathing or signs of local bleeding were found, surgical treatment would be implemented immediately in the operating room. Functional exercised was allowed on the first day after surgery and the neck collar was worn for 8 weeks.

#### Outcome evaluations

The radiological evaluations, including anterior and lateral flexion-extension follow-up films were applied at 3, 6 and 12 months after surgery to assess the union, instability, deformity and instrumentation failure. The American spine injury association (ASIA) score system was used to evaluate postoperative patients' neurological function in each follow-up.

#### Results

All patients were achieved reduction successfully and recovered the normal cervical physiological alignment on the postoperative radiographs. There were no esophagus injury, spinal cord injury, vertebral artery injury, nonunion, and instrumentation failures after surgery in



**Figure 1.** (A) Lateral cervical spine radiograph showing C5/6 fracture and dislocation. (B) The sagittal magnetic resonance image demonstrates spinal cord compression stems from anterior vertebral and the signal had changed. (C) A patient who was applied preoperative traction. (D) Anteroposterior and (E) lateral radiographs were taken after anterior cervical surgery through corpectomy, titanium mesh cage reconstruction, and cervical locking plate.

this series. Bone fusion occurred, while implant loosening, pseudarthrosis and graft settling were not observed in the six months follow-up. Complications related to anterior approach were consisted of two dysphagias and one odynophagia. The clinical symptoms disappeared without special treatment after three months. In the 42 patients, neurological worsening was not found during preoperative skull traction and spinal cord injury was recovered with varying degrees after surgery. There were 12 patients without ASIA level or upper extremity function improvement in the postoperative follow-up of 12 months. Thirty patients increased their postoperative ASIA grades by at least one level. No significant improvement of neurologic function was observed after 1 year follow-up (**Table 1**).

## Discussion

Lower cervical fracture and dislocation often caused by violence, including traffic accidents, falls and blunt injuries, often associated with spine cord injury of different degrees. In addition to the high frequency of complications and poor therapeutic effects, it has been a difficult problem in clinical work. Considering the age of patients, nervous compromise, especially the

type of injury, the primary surgical approach includes anterior, posterior and anterior-posterior surgical procedure. But which is the best treatment is still a controversial topic. The biomechanical superiority of posterior operation has been confirmed that it can provide the stability of the three columns and resist flexion-extension forces [3]. Only the following events occur: compression of spinal cord deriving from posterior elements, instability of the cervicothoracic junction, and irreducible unilateral or bilateral facet dislocation, we used the posterior procedure. However, more and more good results have been reported owing to modern instrumentation and proper operative technique, which plays a vital role, including this study. Even though there were no significant differences between the two procedures for the rate of complications, the superiority of the anterior approach as recorded by Aebi et al. [1] makes it become preferring for the treatment of lower cervical spine fracture and dislocation. Therefore, anterior cervical operation has become popular among young doctors because of the short operation time, less trauma and complications, even the lower morbidity [4]. With the advent of cervical spine locking plate system, in which the cortical screws was used, it prevents the screws from backing out, reduc-

es the risk of intraoperative nerve injury, and provides rigid osteosynthesis. Foremost, because of neurological deterioration always derives from traumatic disc rupture which is in front of the spinal cord [5, 6] decompression can be achieved conveniently through anterior cervical approach.

Reduction should be performed as soon as possible after admission, which can restore normal cervical alignment, maintain cervical spine stability. The goals of closed reduction are to obtain spinal cord decompression and enhance neurologic recovery, while, the most important point is to minimize neurologic deficits worsen. For the patients without reduction in lateral plains were increased traction weight of 2.5 kg in a 20 minutes interval until half of the patient's weight, while neurological examination were performed to evaluate neural function. Through this way, preoperative traction can be applied safely and sixteen of forty-two patients have been achieved reduction in our study, while the success rates is recorded from 23% to 91% in previous literatures [7, 8]. However, for the patients closed reduction defeated required surgical treatment, it can always obtain an anatomic reduction through anterior procedure combined with intraoperative discectomy and corpectomy, when it is necessary. Preoperative skull traction significantly decreases the difficulty of intraoperative reduction. This successfully solved the problem of anterior reduction.

The cervical fracture and dislocation was treated by anterior reduction in 1970s, described by Cloward [9]. Lower cervical spine fractures which were always combined with 3-column injury, were reported to require anterior-posterior approach surgery to provide 360-degree stabilization in the past [10]. However, it can be sufficiently treated with anterior cervical decompression and reconstruction with titanium cages and anterior locking plate, following subtotal corpectomy, while early rehabilitation is allowed [1, 11-13]. The titanium mesh cages used in anterior cervical reconstructive surgery have been approved that it is a safe and effective procedure which has achieved cervical intervertebral fusion surgery following corpectomy [14]. The cages bent to fit the bone defect space not only provide bone support, but reconstruct cervical lordosis in seventeen of the twenty-six patients who required corpectomy in our study. The cages are filled with the bone

removed from the corpectomy site which can avoid the donor site morbidity. In the series, all the 26 postoperative patients were achieved immediate strong support and bone graft fusion, however no bone nonunion, neurologic deterioration, or graft collapse occurred in current follow-up. Severe clinical complications after anterior decompression and internal fixation in lower cervical spine fracture and dislocation are shown to be relative few in several studies [1, 2, 13, 15]. Compared with posterior surgical approach, other complications such as instrumentation failure, pseudoarthrosis formation, or reoperation rate (ranged from 1% to 5%) are not higher [1, 13, 16] and the infection and spinal cord complication rate are even lower [4, 17, 18]. The spinal cord and nerve root decompression after discectomy by anterior procedure can be obtained safely. The disruptive disc in the cervical injuries always causes anterior compression to the spinal cord, it is direct and effective to perform anterior decompression. The plate is placed in front of spine to reconstruct cervical physiological curvature and play tension band effect at the injury level. Additionally, for the patients without preoperative MRI, anterior reduction can be applied.

### Conclusions

For majority of lower cervical fracture and dislocation injuries, anterior cervical surgery has been recognized as vital part in making a treatment plan. Preoperative skull traction acting as an initial treatment is safe and effective to restore dislocation of different degrees and minimize neurological function deteriorating. If closed reduction failed, anterior surgical fixation using titanium mesh cages and locking plates is a proper choice for short operation time, little hemorrhage volume, low complication rate, and high fusion rate.

### Acknowledgements

We gratefully acknowledge the kind cooperation of Dr. Huin in the preparation of this Application note.

### Disclosure of conflict of interest

None.

**Address correspondence to:** Dr. Kai Wang, Department of Orthopedics, The Second Hospital of Tianjin Medical University, Tianjin, China. E-mail: c\_mlove@sina.com



## References

- [1] Aebi M, Zuber K, Marchesi D. Treatment of cervical spine injuries with anterior plating. Indications, techniques, and results. *Spine (Phila Pa 1976)* 1991; 16 Suppl 3: S38-45.
- [2] Ripa DR, Kowall MG, Meyer PR Jr, Rusin JJ. Series of ninety-two traumatic cervical spine injuries stabilized with anterior ASIF plate fusion technique. *Spine (Phila Pa 1976)* 1991; 16 Suppl 3: S46-55.
- [3] Do KY, Lim TH, Won YJ, Eck J, An HS. A biomechanical comparison of modern anterior and posterior plate fixation of the cervical spine. *Spine (Phila Pa 1976)* 2001; 26: 15-21.
- [4] Zeidman SM, Ducker TB, Raycroft J. Trends and complications in cervical spine surgery: 1989-1993. *J Spinal Disord* 1997; 10: 523-6.
- [5] Eismont FJ, Arena MJ, Green BA. Extrusion of an intervertebral disc associated with traumatic subluxation or dislocation of cervical facets. Case report. *J Bone Joint Surg Am* 1991; 73: 1555-60.
- [6] Robertson PA, Ryan MD. Neurological deterioration after reduction of cervical subluxation. Mechanical compression by disc tissue. *J Bone Joint Surg Br* 1992; 74: 224-7.
- [7] Vital JM, Gille O, Senegas J, Pointillart V. Reduction technique for uni- and biarticular dislocations of the lower cervical spine. *Spine (Phila Pa 1976)* 1998; 23: 949-54; discussion 955.
- [8] Lambiris E, Zouboulis P, Tyllianakis M, Panagiotopoulos E. Anterior surgery for unstable lower cervical spine injuries. *Clin Orthop Relat Res* 2003; 61-9.
- [9] Cloward RB. Reduction of traumatic dislocation of the cervical spine with locked facets. Technical note. *J Neurosurg* 1973; 38: 527-31.
- [10] Aebi M, Mohler J, Morscher E. Operative stabilisation of dislocations, fractures and fracture-dislocations of the cervical spine. *Ann Acad Med Singapore* 1982; 11: 194-202.
- [11] Hamilton A, Webb JK. The role of anterior surgery for vertebral fractures with and without cord compression. *Clin Orthop Relat Res* 1994; 79-89.
- [12] Garvey TA, Eismont FJ, Roberti LJ. Anterior decompression, structural bone grafting, and Caspar plate stabilization for unstable cervical spine fractures and/or dislocations. *Spine (Phila Pa 1976)* 1992; 17 Suppl 10: S431-5.
- [13] Randle MJ, Wolf A, Levi L, Rigamonti D, Mirvis S, Robinson W, Bellis E, Greenberg J, Salzman M. The use of anterior Caspar plate fixation in acute cervical spine injury. *Surg Neurol* 1991; 36: 181-9.
- [14] Majd ME, Vadhva M, Holt RT. Anterior cervical reconstruction using titanium cages with anterior plating. *Spine (Phila Pa 1976)* 1999; 24: 1604-10.
- [15] Caspar W, Barbier DD, Klara PM. Anterior cervical fusion and Caspar plate stabilization for cervical trauma. *Neurosurgery* 1989; 25: 491-502.
- [16] Goffin J, Plets C, Van den Bergh R. Anterior cervical fusion and osteosynthetic stabilization according to Caspar: a prospective study of 41 patients with fractures and/or dislocations of the cervical spine. *Neurosurgery* 1989; 25: 865-71.
- [17] Bombart M, Roy-Camille R, Castaing J, Derlon JY, Galibert P, Louis R, Saillant G, Senegas J. Recent injuries of the lower cervical spine. *Rev Chir Orthop Reparatrice Appar Mot* 1984; 70: 501-59.
- [18] Graham JJ. Complications of cervical spine surgery. A five-year report on a survey of the membership of the Cervical Spine Research Society by the Morbidity and Mortality Committee. *Spine (Phila Pa 1976)* 1989; 14: 1046-50.