

## Original Article

# Surgical treatment on venous connection of total anomalous pulmonary for neonates

Bo Zhai, Yong-Hong Zhang, Zhong-Jian Chen, Peng-Gao Wang, Fang Yang, Xiang-Yang Dong, Ya-Zhou Cui, Zhen-Liang Chen

Department of Cardiothoracic Surgery, Children's Hospital of Zhengzhou City, Zhengzhou 450000, China

Received September 7, 2015; Accepted January 5, 2016; Epub February 15, 2016; Published February 29, 2016

**Abstract:** Objective: Summarise the analysis of experience and effect of surgical treatment of total anomalous pulmonary venous connection (TAPVC) on neonates. Method: there were 54 patients of neonates TAPVC selected from March, 2011 to March, 2015, among the surgical treatments in our department, including 33 males and 21 females. Operation age is 6 days -28 days ( $15\pm 4.6$ ) days, weight is 2.6-4.5 kg ( $3.7\pm 0.96$ ) kg. Among them, 33 patients are supracardiac type (28 patients' vertical veins were located on the left, and 5 patients' were located on the right), 3 patients are infracardiac type, 16 patients re inner-acardiac type, and 1 patient is mixed type. Supracardiac type and parts of the infracardiac type of TAPVC in which the veins meet in the middle of the chest, so that the pulmonary vein can be routed through the diaphragm as side-to-side anastomosis, and another part of infracardiac type TAPVC adopts the treatment of left atrial anastomosis, ligature or cutting transfixion of the vertical vein. Inner-acardiac type and mixed type TAPVC adopt right axillary incision, which can fully cut down the top of coronary vein and left atrium and atrial septum, so that the pulmonary vein and left atrium can be connected smoothly, meanwhile, the top of the coronary vein shall be separated from the top of the left atrium. Extracorporeal circulation time is 39-143 min, with average time ( $78.76\pm 27.17$ ) min; aorta blocking time is 21-73 min, with average time ( $37.71\pm 10.51$ ) min. Result: Routine placement of cardiac pacemakers was in operation. Operate 19 cases. There were 4 cases of early death after the operation (7.4%). There were 8 cases of low cardiac output syndrome, 4 cases of arrhythmia, and 7 cases of pneumonia. 51 cases of child patients were followed up for periods ranging from 1 month to 3 years. No deaths and child patients for the anastomose operation again due to stenostomia, cardiac ultrasound examination shows that the blood speed of anastomose is lower than 1.4 m/s. Conclusion: During the neonates period, TAPVC patients were satisfied with the clinical effect of surgical treatment.

**Keywords:** Total pulmonary vein connection, neonates, surgical treatment

## Introduction

The types of total anomalous pulmonary venous connection (TAPVC), are diversified, and comprise 1.5% to 3% of heart diseases as well as having a 20% death rate by earlier surgery [1]. Approximately 75% of children patients without surgical treatment are dead within 1 year. As diagnosis and surgical technics improve and develop [2], operative mortality rate has still reached 10%, and surgical treatment has also faced large challenges. Application of Supracardiac anastomose in the treatment of supracardiac type TAPVC, heart-up, right atrium or whole atrium pathway in the treatment of infracardiac type, child patients' death rate and incidence of pulmonary vein after the operation [3, 4] shall be reduced by the seamless suture

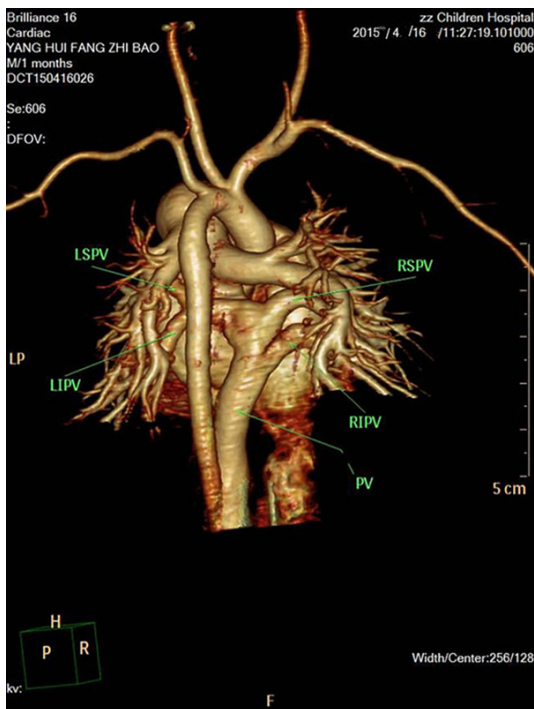
technique [5, 6]. However, the methods mentioned above have experienced difficulties, such as difficulty in exposure and operation [7]. How to improve the prognosis and reduce pulmonary vein obstruction rate in child patients after surgical treatment has been the key point of the research until now [8, 9]. The paper researched TAPVC treatment in the neonatal period from the aspects of operational opportunity selection and operation method to summarise the experience of operation treatment in the neonatal period.

## Materials and methods

### Clinical data

From March, 2011 to March, 2015, among the various types of the TAPVC child patients,

## Total anomalous pulmonary venous connection and treatment



**Figure 1.** Heart of infracardiac type TAPVC [GTA].

among the surgical treatments in our department, 54 patients of neonates TAPVC, includes 33 males and 21 females, with operation age of 6 days -28 days ( $15 \pm 4.6$ ) days, and weight of 2.6-4.5 kg ( $3.7 \pm 0.96$ ) kg. According to the Darling type, 33 patients are supracardiac type (28 patients' vertical veins are located on the left, and 5 patients' are located on the right), 4 cases are infracardiac type, 16 cases are inner-cardiac type, and 1 case is mixed type (upper-right pulmonary vein entering into the precava individually near the right atrium, the rest 3 lines of pulmonary vein were induced into the top of coronary vein). 54 cases in the child patients combined with ASD or Botallo's foramen closing size are 3.1-6.8 mm ( $5.4 \pm 2.9$ ) mm, and 12 cases where the artery catheter was not closed (PDA), 6 cases are tricuspid valve backflow with preoperative pneumonia, 7 cases re ventilator assisted therapy for respiratory failure (All emergency operations were performed). 54 cases are lung artery high pressure of different degrees.

The child patients in this group have difficulty in cultivation due to different degree of cyanosis, without increase in weight, shortness of breath and weak crying. After respiratory tract infection, they came to our hospital for treatment on

the shortness of breath and other symptoms or 120 emergency access to the hospital. Preoperatively cardiac ultrasound was carried out. Chest X-ray, electrocardiogram and blood oxygen saturation ( $SPO_2$ ) were determined for diagnosis, among them, 15 cases examined showed enhanced cardiovascular 64-CT check: 1 case was mixed type TAPVC, 12 cases were supracardiac type TAPVC, and 2 cases were infracardiac type TAPVC (Figure 1). X-ray Chest radiography is right atrium, with enlargement. The ratio of heart and chest ranged between 0.60-0.75, with more lung blood. Lung artery is prominent. Preoperative  $SPO_2$  is in the range 0.65-0.91.

### *Treatment method*

54 cases are TAPVC children patients were diagnosed definitively, and treated by operation. 15 cases were conducted by emergency operation due to no significant improvement in respiratory function or unstable circulation of combined pneumonia, under the condition of ineffective treatment administered by the department of internal medicine.

All child patients underwent operation under the medium and low temperature of extracorporeal circulation. 12 cases of combined patent ductus arteriosus (PDA) became free under the cooling phase after the contribution of extracorporeal circulation and the application of No. 7 silk thread to ligature; one of them is uncompleted ligature, then cut the pulmonary artery with a pledgetted mattress of 5-0 Prolene after cardiac arrest and remaining artery catheter transfixion, 6-0 Prolene sutures dissected pulmonary artery, both supracardiac type and infracardiac type (TAPVC) adopt the location in the middle of the chest, and resistance of the ascending aorta, cold retrograde crystalloid cardioplegia, and after cardiac arrest, cut along the rear wall of the left root of the left atrium which is parallel to the direction of the rest of the veins, then cut the main pulmonary vein along the long axis, and part of infracardiac type TAPVC2 case adopt anastomose inside the left atrium to correct and cure, with supplemented heart up in 1 case and right posterior of right atrium free exposure in 2 cases, in order to expend incision and cut off part of the tissue around the incision, and use 6/0 Prolene to suture continuously and put the rear wall of the left atrium and pulmonary vein

## Total anomalous pulmonary venous connection and treatment

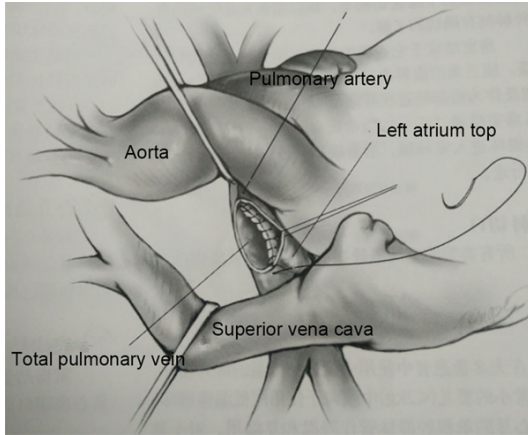
into complete anastomose. If the entire pulmonary vein is relatively narrow, it can be attempted to extend the confluence of anastomose to the left, the upper and lower branches of the pulmonary veins, one case is that the left branch of the pulmonary vein was narrow and adapted to non-endometrial contact suture technique. (the "sutureless" neoatrium technique), which adopts autologous pericardial patch to repair ASD and extend the volume of the left atrium as well as direct suture with Botallo's foramen, with ligature vertical vein after the stable of cardiac resuscitation. The operation on inner-acardiac type TAPVC adopts the method of: from left lateral position, right axillary incision and the fourth intercostal into chest, from incision of right atrium, cut off top of coronary vein, left atrium and atrial septum completely, to form new ASD, and make completely clear the pulmonary vein and left atrium, in order to use appropriate autologous pericardial patch and 5/0 Prolene to suture continuously and repair the new forming incision of ADS, and put the coronary vein sinus to be isolated with left atrium at the same time. 1 case of the mixed type of TAPVC adopts the sole open incision of right precava at upper right of pulmonary vein, and other 3 pulmonary veins shall be opened at coronary vein sinus. Since the distance between the upper right incision of the pulmonary vein and ASD is large, we adopt the method to cut along the long axis inclined left to the top of right atrium (avoid injury the sinoatrial node), and cut off the top of the coronary vein, left atrium and atrial septum, then expand ASD to the left roof part, then use autologous pericardial patch (1 patch, guarantee the size of pericardial patch can be enough) and inner tunnel form to drain the upper right pulmonary vein to ASD, and make sure there are no impediments between upper right pulmonary vein and left atrium. And use pericardium fragments to repair ASD, in order to avoid the narrowing of the precava, use the precava while dilated and cut the bovine pericardium in the position of the top right atrium close to the auricle, open superior and inferior vena cava and then give the normal application of dopamine and dobutamine, nitroglycerin, milrinone and epinephrine. In general, install the temporary pacing lead on epicardial, the child patients with heart rate of cardiac resuscitation less than 140 beats/minutes showing no obvious affect after giving isoproterenol shall use a

temporary pacemaker to do the heart pacing, maintain heart rate at around 160 beats/minute. The situation of deformity correction can be understood by the routine TEE (transesophageal echocardiography) examination before shutdown of operation, in order to continue therapy with antibiotics to prevent infection post operation.

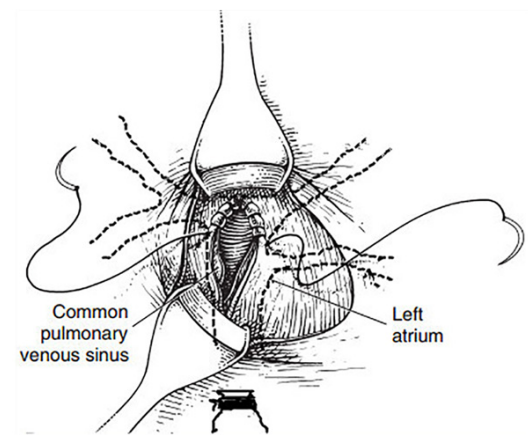
### Result

Extracorporeal circulation time is 39-143 min, with average  $(78.76 \pm 27.17)$  min, aorta blocking time is 21-73 min, with average  $(37.71 \pm 10.51)$  min, no delayed sternal closures. Postoperative mechanical ventilation time is 2-21 days, with average  $(3.01 \pm 2.87)$  days. 4 cases died after operation, including 3 cases of supracardiac type, one case is 9 days for preoperative child patients because pneumonia is complicated with respiratory failure, given by endotracheal intubations treatment for 3 days, with worsened condition and unstable circulation, under the emergency surgical treatment, the lowest open-chest systolic pressure is 30 mmHg, it died for heart failure 2 days later, the other 3 cases are the child patients could not take off the breathing machine because of postoperative intensive pneumonia, family gave up treatment. 1 case is infracardiac type of TAPVC died because of irregular heartbeat and it couldn't be rectified after that extracorporeal circulation, considering the time is long enough for aorta blocking time (80 min), intraoperative heart is turned over of time slightly long, related to the heart pulling, myocardial ischemia, hypoxia and other poor myocardial protection. Among the rest 50 cases of children patients, 8 cases are low cardiac output syndrome recovered satisfactorily after active heart strengthening, diuresis, anti-infection and rehydration treatment of enough nutrition. 4 cases are arrhythmia (including 2 cases of supraventricular tachycardia, 1 case of frequent ventricular premature beat, 1 case of nodal heart rate), and 7 cases of pneumonia. 19 cases of postoperatively adopted heart failure symptoms, temporary pacemaker. 51 cases of child patients followed up for 3 years and 1 month. No death and anastomose stenostomia reoperation in the child patients. The anastomose speed of mitral blood flow checked by cardiac ultrasound for both blow was 1.4 m/s.

## Total anomalous pulmonary venous connection and treatment



**Figure 2.** Treatment of supracardiac path, supracardiac type TAPVC.



**Figure 3.** Treatment of anastomosing in left atrium, infracardiac type TAPVC.

### Discussion

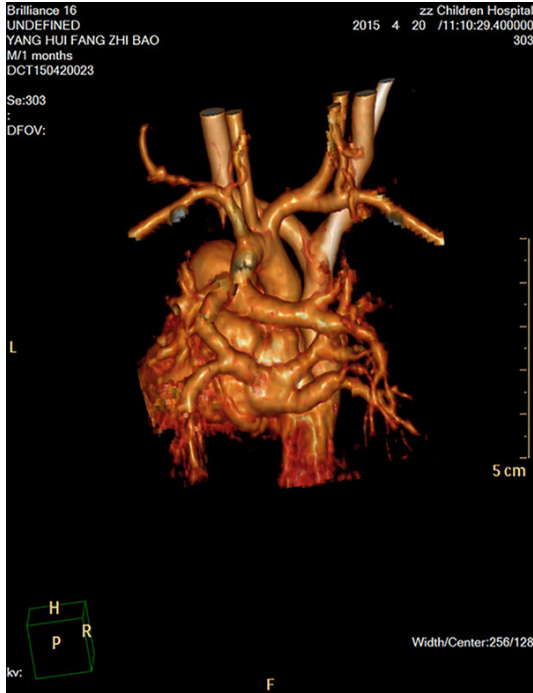
#### *Summary of experience on treatment of the neonates TAPVC surgical*

Time to choose for the surgery; TAPVC is one of the few heart diseases that requires surgical treatment during the neonatal period. If it is left without surgery, about 75% shall die within 1 year. For the child patients that have pulmonary vein backflow obstruction, the death rate could be up to 50% within 3 months [10]. Because the child patients' pulmonary vein blood flow and venous blood flow are returned to the right atrium, it can easily lead to early pulmonary hypertension [11]. The left heart only relies on the defected atrial septal or unclosed Botallo's foramen to backflow the blood, resulting in

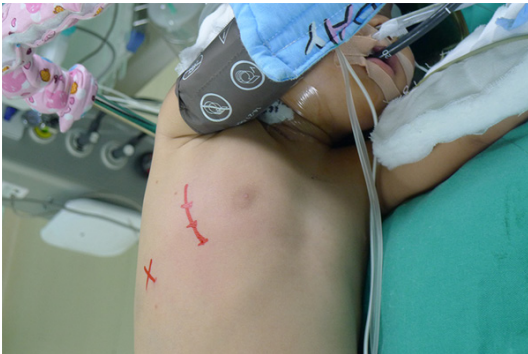reduced blood volume of the left ventricular system, and hypoplastic left heart. If the ASD is small or the pulmonary vein is narrow, circulatory failure syndromes such as pulmonary oedema, pulmonary artery hypertension and systemic hypoperfusion etc. can occur in children after birth. Therefore, each type of TAPVC child upon diagnosis, surgical treatment shall be performed, for the child patients with pneumonia accompanying respiratory failure that have poor effect after conservative treatment or getting worse, emergency surgery shall be performed. The correction on the heart deformity is conducive to the pneumonia treatment.

Surgery types to choose for the TAPVC operation; the long-term effects are closely related to the size of anastomose for the supracardiac type and infracardiac type of TAPVC children patients 33 [12]. For the cases of supracardiac type of TAPVC, children patients all use the heart path, as the earliest "upturning method" operation exposure and the myocardial protection is poor, and the anastomose can be easily distorted and deformed, etc. leading to a high mortality rate. For the "Left and right atrium combined incision", the incidence rate of post-operative atrial arrhythmia is up to 20-50%, which is related to the operation inside the atrium [13]. The "heart path method" (Figure 2) adopted is to perform side-to-side anastomosis in the exposed back wall of the left atrium among the ascending aorta, superior precava and the combined pulmonary vein. In order to reduce the narrow size of anastomose narrowing, the main points to be noted are as follows: 1) after extracorporeal circulation is established, the combined pulmonary vein shall be fully dissociated, and both sides are free to the pulmonary vein bypass. 2) incise the back wall of the left atrium parallel to the direction of the summary vein, and incise longitudinally in the combined pulmonary vein, cut off part of the organization to expand the incision around, 3) for the narrow combined pulmonary vein, the anastomose can be extended to perform an up and down bypass of the left and right pulmonary vein, for the narrow pulmonary vein bypass, the "sutureless" neoatrium technique [14] shall be adopted to conduct the anastomose. The suturing at the pulmonary vein ostia can be avoided by this technology, to prevent the intimal hyperplasia, and replace the common pericardial vein wall with the cardiac ves-

## Total anomalous pulmonary venous connection and treatment

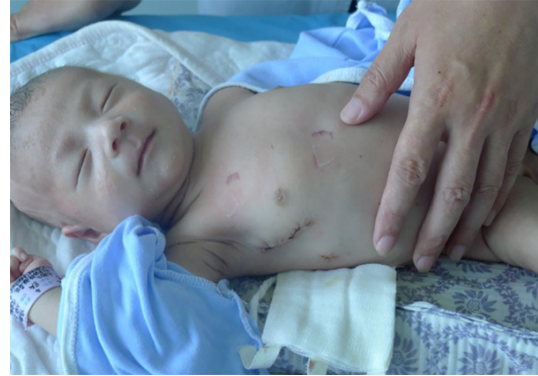

**Figure 4.** Infracardiac type TAPVC [CTA] after operation.



**Figure 5.** Treatment of cutting beneath right oxter, inner-acardiac type TAPVC.

cle, resulting in the reduction on its physical distance to the left atrial posterior wall, and avoid uneven tension pull, reduce anastomose tension, lower the “pouch ring shrinkage” effect, ensure the smooth flow at the anastomose, effectively reduce the pulmonary vein and prevent the occurrence of the early pulmonary vein obstruction after surgery. 6-0 or PDS 5-0 absorbable suture can be used for the suturing. During the process, pay attention to shallow suture the pericardial tissue around the pulmonary vein and left atrial incision edge tissues to avoid damage to the diaphragm



**Figure 6.** Postoperation of cutting beneath right oxter, children patients, inner-acardiac type TAPVC.

nerve. When pulling the suture, it shall avoid excessive force to prevent suture breakage or tissue tearing. For this type of TAPVC, whether ligature is needed for the vertical vein, it has been still controversial [15], we adopt ligature for the supracardiac type, and cut off and transfixion for the infracardiac type.

The proportion of infracardiac type TAPVC was low, there were only 5 cases of child patients, the therapeutic method of an early sample operation was desired to turn the heart upward, then made left atrium and summary vein anastomose, however we found it is hard to expose and protect the heart and the myocardia, it can also take too much time to assist extracorporeal circulation, so this treatment couldn't ensure that the anastomosing junction is large enough to offer good protection from myocardia. The left atrium and summary vein anastomose of second sample later in the operation can be exposed by the right side of the heart. In this sample, it adopted a therapy of two anastomose in the left atrium (Figures 3 and 4). The effect of this therapy was better than turning the heart upward. There were also some clinical reports about such aspects [16].

In the case of inner-acardiac type TAPVC, we all chose the clinostatism on the left side, cut down the gap of the fourth or fifth costal beneath and the right oxter into the thorax (Figure 5), chose the cutting section of right atrium, wiped out the ethmoid roof of the coronary vein sufficiently, to form a new ASD with left atrium and atrial septum, then circulate the pulmonary vein and left atrium smoothly, with-proper size of autologous pericardial patch, 5/0

## Total anomalous pulmonary venous connection and treatment

Prolene sutures to suture and repair the newly formed ASD. Simultaneously, select the sinuses of coronary vein at the side of left atrium. Pay attention to X-ray chest radiography when choosing the cut beneath of the right outer, and know the relationship between heart and gap of costals before entering the gaps. Don't choose the gap of the fourth costal to enter the chest blindly, otherwise for position of heart of child patients is higher or lower, choosing a gap blindly shall lead to hard explosion to the heart, and increase the difficulty of the operation. The length of the straight cut under right outer was only about 4 centimetres, the cut to avoid sawing the sternum is covert, minimally invasive and decent. Follow-up visiting showed no abnormal thoracic wall (**Figure 6**).

In sample 1 of mixed type TAPVC, the upper right pulmonary vein was cut at the vein in the upper right antrum, the other three pulmonary veins were cut at the opening of the ethmoid roof of the coronary vein. Since the cutting of the upper right pulmonary vein was extensive, we removed the ethmoid roof of the coronary vein and left atrium, atrial septum, expanded the ASD to the position of left roof, then applied autologous pericardial patch (just one pitch, make sure the pericardial patch is large enough) to move the upper right pulmonary vein to the site of ASD by inner track form, and made upper right pulmonary vein as well as left atrium unobstructed. Use the bottom of the pericardial patch to repair ASD, secluded the sinus of coronary vein at the side of left atrium at the same time. In order to prevent the vein of the top antrum to become too narrow, we cut it along with the left side of the long axis of top antrum vein (without harming the atrionector), then broadened it with a bovine pericardial patch.

Postoperative treatment; During operation we set up a routine to lead the heart table temporary pacemaker, because of the influence on extracorporeal circulation and intracardiac operation, parts of child patients' heart rate were between 110 and 140 times per minute after their hearts are recovered. For heart rate of child patients changed inconspicuously after taking vascular active medicine, we used heart table temporary pacemaker, set heart rate of the pacemaker at about 160/min. During the postoperative treatment in the intensive care

unit, we set up a proper pace-making heart rate by referring to the changes of respiratory and circulatory system and the recovery of self-heart rate. Since child patients were young, their tracheae and bronchi were slender and thin, only a little secreta can cause a clogging of the respiratory tract, the management was relatively difficult, therefore, 1) enhance the management of the respiratory tract. 2) clear the sputum in tracheae and bronchi, apply fibre bronchoscope to clean tracheae when it is necessary. 3) execute aseptic technique strictly in the process of respiratory tract management. 4) for such children patients' recovery and prognosis, it's crucial to choose the proper antibiotics in the light of sputum culture and drug sensitive test.

### *Curative effect analysis of neonates TAPVC*

With the improving of myocardial protecting technology and operation technology, clinical application of various treating instrument of neonates, the mortality of TAPVC children patients has significantly decreased [17]. There were 54 samples in this group, 4 died after operation, (7.4%). During follow-up visiting, all kinds of examinations indicated that 51 samples of child patients' heart functions were well, occurrence of respiratory tract infection obviously reduced. Their active stamina also increased gradually. By analysing the curative effect of operative treatment of 54 samples of neonates TAPVC, we can conclude that once the diagnosis of TAPVC in child patients is apparent, the operation therapy shall be executed immediately. Recent curative effect of this therapy is satisfactory, and long-term prognosis needs further observation.

### **Disclosure of conflict of interest**

None.

**Address correspondence to:** Zhen-Liang Chen, Department of Cardiothoracic Surgery, Children's Hospital of Zhengzhou City, Zhengzhou 450000, China. Tel: +13938292859; Fax: +8603718551-5700; E-mail: zhenliangchendoc@sina.com

### **References**

- [1] Yoshimura N, Fukahara K, Yamashita A, Doki Y, Takeuchi K, Higuma T, Senda K, Toge M, Matsuo T, Nagura S, Aoki M, Sakata K, Obi H. Cur-

## Total anomalous pulmonary venous connection and treatment

- rent topics in surgery for isolated total anomalous pulmonary venous connection. *Surg Today* 2014; 44: 2221-6.
- [2] Padalino MA, Cavalli G, De Franceschi M, Mancuso D, Maschietto N, Vida V, Milanese O, Stelilin G. Surgical outcomes of total anomalous-pulmonary venous connection repair: a 22-year experience. *J Card Surg* 2014; 29: 678-85.
- [3] Husain SA, Maldonado E, Rasch D, Michalek J, Taylor R, Curzon C, Neish S, Calhoon JH. Total anomalous pulmonary venous connection: factors associated with mortality and recurrent pulmonary venous obstruction. *Ann Thorac Surg* 2012; 94: 825-31.
- [4] Milovanović V, Mimić B, Vulićević I, Divac I, Parezanović V, Ilić T, Djukić M, Jovanović I, Ilić S. Outcomes of surgery for total anomalous pulmonary venous drainage. *Srp Arh Celok Lek* 2014; 142: 164-9.
- [5] Mueller C, Dave H, Prêtre R. Primary correction of total anomalous pulmonary venous return with a modified sutureless technique. *Eur J Cardiothorac Surg* 2013; 43: 635-40.
- [6] Yoshimura N, Oshima Y, Henaine R, Matsuhisa H. Sutureless pericardial repair of total anomalous pulmonary venous connection in patients with right atrial isomerism. *Interact Cardiovasc Thorac Surg* 2010; 10: 675-8.
- [7] Jinghao Z, Botao G, Zhiwei X, Jinfeng L. The research on operation of obstructed total anomalous pulmonary venous connection in neonates. *ScientificWorldJournal* 2014; 2014: 576569.
- [8] Hoashi T, Kagisaki K, Oda T, Kitano M, Kurosaki K, Shiraishi I, Yagihara T, Ichikawa H. Long-term results of treatments for functional single ventricle associated with extracardiac type total anomalous pulmonary venous connection. *Eur J Cardiothorac Surg* 2013; 43: 965-70.
- [9] Karaci AR, Harmandar B, Aydemir NA, Sasmazel A, Balci AY, Saritas T, Yekeler I, Bilal MS. Early and intermediate term results for surgical correction of total anomalous pulmonary venous connection. *J Card Surg* 2012; 27: 376-80.
- [10] Konstantinov IE. Primary sutureless repair of total anomalous pulmonary venous connection. The value of intrapleural hilar reapproximation. *J Thorac Cardiovasc Surg* 2006; 132: 729-730.
- [11] Kohli V, Sachdev MS, Joshi RK, Joshi R. Post-op systemic hypertensive crises in an infant with total anomalous pulmonary venous connection. *Indian J Pediatr* 2009; 76: 755-756.
- [12] Suarez MR, Panos AL, Salerno TA, Ricci M. Modified "sutureless" anastomosis for primary repair of supracardiac total anomalous pulmonary venous connection. *J Card Surg* 2009; 24: 564-566.
- [13] Kelle AM, Backer CL, Gossett JG, Kaushal S, Mavroudis C. Total anomalous pulmonary venous connection. Results of surgical repair of 100 patients at a single institution. *J Thorac Cardiovasc Surg* 2010; 139: 1387-1394.
- [14] Hickey EJ, Caldaroni CA. Surgical management of post-repair pulmonary vein stenosis. *Semin Thorac Cardiovasc Surg Pediatr Card Surg Annu* 2011; 14: 101-108.
- [15] Chowdhury UK, Subramaniam KG, Joshi K, Varshney S, Kumar G, Singh R, Venugopal P. Rechanneling of total anomalous pulmonary venous connection with or without vertical vein ligation: results and guidelines for candidate selection. *J Thorac Cardiovasc Surg* 2007; 133: 1286-1294.
- [16] Zheng JH, Xu ZW, Liu JF, etc. Treatment of neonates obstructive TAPVC. *Chin J Thorac Cardiovasc Surg* 2011; 27: 709-712.
- [17] Modi A, Vohra HA, Brown I, Langley SM. Successful surgical correction of total anomalous pulmonary venous drainage in the sixth decade. *Ann Thorac Surg* 2008; 86: 1684-1686.