

Original Article

Combined application of fibrin sealant and polyglycolic acid felt in surgery for pneumothorax due to emphysema

Yu Liu, Deyao Xie, Chuang Chi, Xiaoming Lin, Chaoxi Lin

Department of Thoracic Surgery, The First Affiliated Hospital of Wenzhou Medical University, Wenzhou, China

Received September 8, 2015; Accepted December 5, 2015; Epub February 15, 2016; Published February 29, 2016

Abstract: Background: The combination of fibrin sealant and poly glycolic acid (PGA) felt is a good means used to prevent alveolar air leakage or bile leakage after liver resection, which can provide a better sealing effect on alveolar air leakage or bile duct. This work aims to investigate the combined application of fibrin sealant and PGA felt in surgical treatment for pneumothorax due to emphysema. Methods: 78 emphysema patients with pneumothorax were randomly divided into study group (35 cases) and control group (43 cases). During pulmonary bulla resection by video-assisted thoracoscopic surgery, the fibrin sealant combined with PGA felt was used in study group, and the partial pleural pleura rubbing was used in control group. The chest drainage time after surgery, hospital stay and recurrence rate of pneumothorax after 1 year between two groups were compared. Results: The chest drainage time after surgery in study group was significantly shorter than control group (4.91 ± 1.29 days vs. 7.47 ± 2.12 days, $P < 0.05$). The hospital stay in study group was also significantly shorter than control group (7.86 ± 1.73 days vs. 11.09 ± 2.33 day, $P < 0.05$). The recurrence rate of pneumothorax after 1 year in study group was significantly lower than control group (5.71% vs. 23.26%, $P < 0.05$). Conclusions: The combined application of fibrin sealant and PGA felt can improve the treatment effect in surgery for pneumothorax due to emphysema, compared to using partial pleura rubbing.

Keywords: Fibrin sealant, poly glycolic acid, emphysema, pneumothorax

Introduction

In recent years, with the population aging, there are more and more emphysema patients with pneumothorax in clinic. For these patients, the thoracoscopic resection of pulmonary bulla is a good choice [1]. However, the surgeons are often faced with the dilemma of postoperative persistent air leakage. Previously, the pleura rubbing is often used to deal with this problem [2], but the outcome is not very satisfactory. The combination of fibrin sealant and polyglycolic acid (PGA) felt is a good means used to prevent alveolar air leakage or bile leakage after liver resection. It can provide a better sealing effect on alveolar air leakage or bile duct [3, 4]. However, there is little evidence that reveals the optimum techniques for their combined application to surgery for pneumothorax due to emphysema. The present study investigated the combined application of fibrin sealant and PGA felt in surgery for pneumothorax due to emphysema, and evaluated its efficacy

and safety compared to single partial pleural rubbing. The objective was to provide a reference for further clinical application of this combined technique.

Subjects and methods

Subjects

78 emphysema patients with pneumothorax in First Affiliated Hospital of Wenzhou Medical University from August 1st 2007 to January 31st 2012 were enrolled in this study. They were all male, and were not associated with severe asthma. All patients were randomly divided into study group (35 cases) and control group (43 cases), which were treated with combined fibrin sealant (prepared from fibrinogen and thrombin) and PGA felt and partial pleura rubbing during surgery, respectively. There was no difference of gender, age or duration of pneumothorax between two groups ($P > 0.05$) (Table 1). This study was approved by the Ethics

Table 1. Perioperative data in two groups

Group	Study (n=35)	Control (n=43)	P
Age (year)	68.03±5.19	67.65±6.12	0.246
Gender (male/female)	35/0	43/0	1.0
Duration of pneumothorax (day)	7.34±1.98	7.05±1.85	0.809

Committee of Wenzhou Medical University. Written informed consent was obtained from all participants.

Treatment methods

The pulmonary bulla resection by video-assisted thoracoscopic surgery was performed in two groups, according to reported operation [5, 6], with minor modification. The basal pulmonary bulla was resected using 60 mm endoscopic linear cutter (Ethicon Endo-Surgery, Inc., OH, USA). In study group, during surgery, the combined fibrin sealant and PGA felt was applied as follows: Firstly, half amount of lyophilized human fibrinogen (Shanghai RAAS Blood Products Co., Ltd., Shanghai, China) was sprayed on the stripped residual surface of bulla resection and residual pulmonary surface through the main thoracoscopic hole. Secondly, the PGA felt (Gunze Co., Kyoto, Japan) was soaked in half amount of lyophilized human thrombin (Shanghai RAAS Blood Products Co., Ltd., Shanghai, China), and then patched covering the residual surface. Finally, the remaining half amount of lyophilized human fibrinogen and lyophilized human thrombin were sprayed on the patch rapidly (**Figure 1**). In control group, during surgery, the partial pleura rubbing performed. The chest drainage time after operation, hospital stay and recurrence rate of pneumothorax after 1 year in two groups were observed.

Statistical analysis

Data were presented as mean ± SD. SPSS 17.0 software (SPSS Inc., IL, USA) was used for statistical analysis. The univariate analysis was conducted using the chi-square test for categorical data and the t-test for measurement data. $P < 0.05$ was considered as statistically significant.

Results

No postoperative death was found in two groups. 3 patients (2 cases in study group and 1 case in control group) experienced postoper-

ative pulmonary infection. They were cured after anti-infective therapy. The chest drainage time after surgery in study group was 4.91 ± 1.29 days, which was significantly shorter than 7.47 ± 2.12 days in control group ($P < 0.05$).

The hospital stay in study group was 7.86 ± 1.73 days, which was also significantly shorter than 11.09 ± 2.33 days in control group ($P < 0.05$). The recurrence rate of pneumothorax after 1 year in study group was 5.71% (2/35), which was significantly lower than 23.26% (10/43) in control group ($P < 0.05$) (**Table 2**).

Discussion

In many lobectomy cases where it is difficult to directly suture the pleural defect, the fibrin sealant is often used to prevent the air leakage [7-10]. The fibrin sealant is prepared from lyophilized human fibrinogen and lyophilized human thrombin. The action mechanism of fibrin sealant is that it imitates the final phase of the blood coagulation process [11]. Fibrinogen is indispensable for the formation of a fibrin clot. Fibrinogen transforms to fibrin in the presence of thrombin and calcium ion [12, 13]. Fibrin sealant is a kind of biological glue. It can be absorbed by the body, and cannot generate allogenic reaction [14, 15]. PGA is a kind of polymer material, and has good biocompatibility. It can be degraded gradually after 15 weeks from implantation in the human body tissues, and can be completely absorbed. It is widely used as suture material in clinical surgery [16]. It is reported that, in thoracotomy, the combined application of fibrin sealant and PGA has better treatment effect on alveolar air leakage than using fibrin sealant alone [17-20]. Results of the present study show that, the combined application of fibrin sealant and PGA felt can improve the treatment effect in surgery for pneumothorax due to emphysema, compared to using partial pleural rubbing alone. In addition, there is no increased risk of infection in this method.

The postoperative air leakage is a major cause of morbidity after emphysema resection. It leads to prolonged chest drainage time that is associated with pain and immobilization, which consequently increases the risk of empyema occurrence and other serious complications [21]. In the present study, the subjects are male

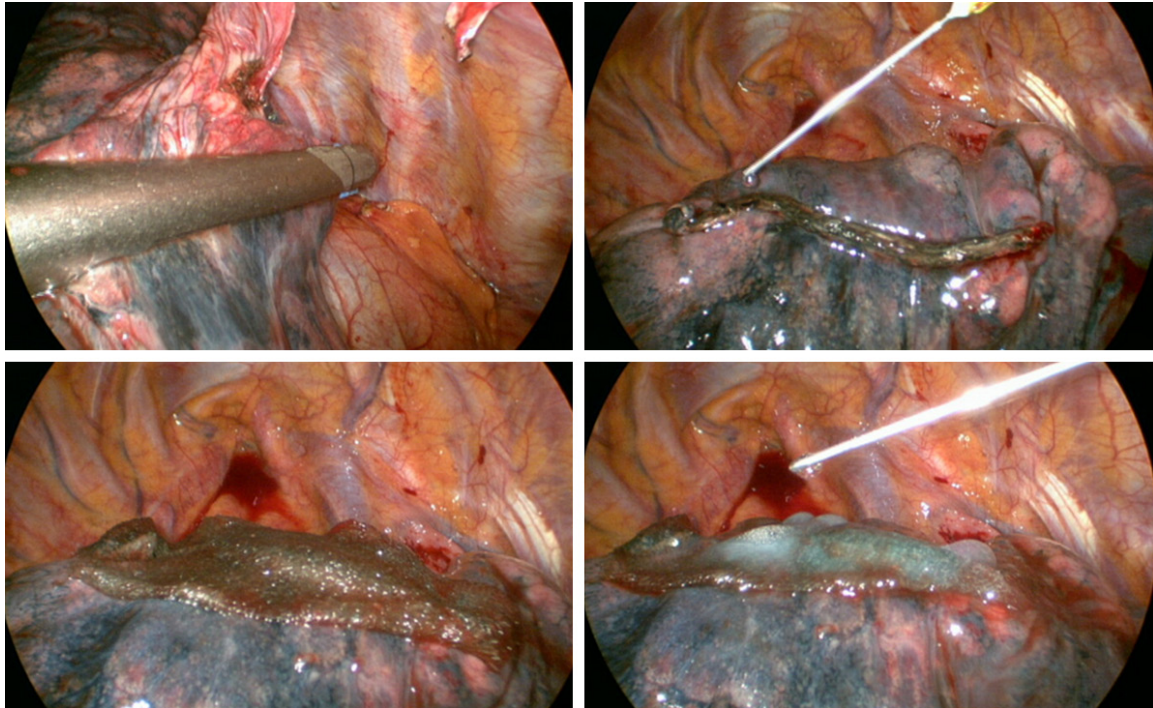


Figure 1. Combined application of fibrin sealant and PGA felt during pulmonary bulla resection.

Table 2. Comparisons of clinical data between two groups

Group	Study (n=35)	Control (n=43)	P
Chest drainage time (day)	4.91±1.29	7.47±2.12	0.018
Recurrence rate of pneumothorax	5.71% (2/35)	23.26% (10/43)	0.030
Hospital stay (day)	7.86±1.73	11.09±2.33	0.041

air leakage, so triple-layer PGA felt and fibrin sealant are often recommended [25]. The results of the present study are consistent with the conclusion obtained from previous studies [3, 27].

elderly patients. These patients often have a history of smoking for many years. In these patients, as the compliance of lung is poor, the pinhole leak exists at the bottom of pulmonary bulla after cutter resection, leading to adhesion of pleural cavity and lung surface damage after stripping. This causes air leakage for a long time and high recurrence rate of pneumothorax [22]. The traditional method of pleura rubbing is not satisfactory, and it may increase the probability of bleeding. Results of the present study find that, a combined application of fibrin sealant and PGA felt can reduce chest drainage time and postoperative recurrence rate of pneumothorax. In this study, the “sandwich” technique (fibrinogen-thrombin soaked PGA-fibrin glue) is used in the surgery, so the target region can be adhered more closely. As confirmed in previous studies [23, 24], the viscosity and osmolality of this technique is improved, and it may produce good sealing effect at the base of micro recesses of lung surface. The stronger sealants are required to prevent the

Conclusions

Compared to traditional method of pleura rubbing, the combined application of fibrin sealant and PGA felt can significantly improve the treatment effect in surgery for pneumothorax due to emphysema. This technique may be suitable for selective emphysema patients with pneumothorax.

Disclosure of conflict of interest

None.

Address correspondence to: Dr. Yu Liu, Department of Thoracic Surgery, The First Affiliated Hospital of Wenzhou Medical University, Shangcai Village, Ou-hai District, Wenzhou, China. E-mail: yuliucn1@126.com

References

- [1] Xu X, Chen H, Yin W, Wei B, Xiao D, Liu J, He J. Video-assisted thoracoscopic management for

- emphysema associated with contralateral destroyed lung. *J Thorac Dis* 2013; 5: 165-168.
- [2] Abyholm F, Storen G, Geiran O. Spontaneous pneumothorax. *Scand J Thorac Cardiovasc Surg* 1975; 9: 281-286.
- [3] Itano H. The optimal technique for combined application of fibrin sealant and bioabsorbable felt against alveolar air leakage. *Eur J Cardiothorac Surg* 2008; 33: 457-460.
- [4] Kobayashi S, Nagano H, Marubashi S, Wada H, Eguchi H, Takeda Y, Tanemura M, Doki Y, Mori M. Fibrin sealant with PGA felt for prevention of bile leakage after liver resection. *Hepatogastroenterology* 2012; 59: 2564-2568.
- [5] Chen YJ, Luh SP, Hsu KY, Chen CR, Tsao TC, Chen JY. Video-assisted thoracoscopic surgery (VATS) for bilateral primary spontaneous pneumothorax. *J Zhejiang Univ Sci B* 2008; 9: 335-340.
- [6] Horio H, Nomori H, Suemasu K. Video-assisted thoracoscopic surgery in spontaneous hemopneumothorax. *Jpn J Thorac Cardiovasc Surg* 1998; 46: 987-991.
- [7] Mouritzen C, Drömer M, Keinecke HO. The effect of fibrin glueing to seal bronchial and alveolar leakages after pulmonary resections and decortications. *Eur J Cardiothorac Surg* 1993; 7: 75-80.
- [8] Porte HL, Jany T, Akkad R, Conti M, Gillet PA, Guidat A, Wurtz AJ. Randomized controlled trial of a synthetic sealant for preventing alveolar air leaks after lobectomy. *Ann Thorac Surg* 2001; 71: 1618-1622.
- [9] Wain JC, Kaiser LR, Johnstone DW, Yang SC, Wright CD, Friedberg JS, Feins RH, Heitmiller RF, Mathisen DJ, Selwyn MR. Trial of a novel synthetic sealant in preventing air leaks after lung resection. *Ann Thorac Surg* 2001; 71: 1623-1629.
- [10] Fabian T, Federico JA, Ponn RB. Fibrin glue in pulmonary resection: a prospective, randomized, blinded study. *Ann Thorac Surg* 2003; 75: 1587-1592.
- [11] Oliver DW, Hamilton SA, Figle AA, Wood SH, Lamberty BG. A prospective, randomized, double-blind trial of the use of fibrin sealant for face lifts. *Plast Reconstr Surg* 2001; 108: 2101-2105, 2106-2107.
- [12] Brummel-Ziedins K, Orfeo T, Jenny NS, Everse SJ, Mann KG. Blood coagulation and fibrinolysis. In: Greer JP, Foerster J, Lukens JN, Rodgers GM, Paraskevas F and Glader BE, editors. *Wintrobe's clinical hematology*. Philadelphia: Lippincott Williams & Wilkins; 2003. pp. 721-725.
- [13] Sierra DH, O'Grady K, Toriumi DM, Foresman PA, Rodeheaver GT, Eberhardt A, Feldman DS, Lemons JE. Modulation of mechanical properties in multiple-component tissue adhesives. *J Biomed Mater Res* 2000; 52: 534-542.
- [14] Wang Z, Li J, Zhou GH, Chen AQ, Jiang ZB. Clinical application of fibrin sealant in cardiac surgery. *J Surg Concepts Pract* 2003; 8: 260-264.
- [15] Radosevich M, Goubran HI, Burnouf T. Fibrin sealant: scientific rationale, production methods, properties, and current clinical use. *Vox Sang* 1997; 72: 133-143.
- [16] Saito Y, Minami K, Kobayashi M, Nakao Y, Omiya H, Imamura H, Sakaida N, Okamura A. New tubular bioabsorbable knitted airway stent biocompatibility and mechanical strength. *J Thorac Cardiovasc Surg* 2002; 123: 161-167.
- [17] Tsuda T, Nakamura T, Yamamoto Y, Teramachi M, Kiyotani T, Lee YH, Shimizu Y. Prevention of postoperative air leakage from lungs using a purified human collagen membrane-polyglycolic acid sheet. *Ann Thorac Surg* 1999; 68: 339-342.
- [18] Miyamoto H, Futagawa T, Wang Z, Yamazaki A, Morio A, Sonobe S, Izumi H, Hosoda Y, Hata E. Fibrin glue and bioabsorbable felt patch for intraoperative intractable air leaks. *Jpn J Thorac Cardiovasc Surg* 2003; 51: 232-236.
- [19] Gika M, Kawamura M, Izumi Y, Kobayashi K. The short-term efficacy of fibrin glue combined with absorptive sheet material in visceral pleural defect repair. *Interact Cardiovasc Thorac Surg* 2007; 6: 12-15.
- [20] Matsumura Y, Okada Y, Shimada K, Endo C, Chida M, Sakurada A, Sato M, Kondo T. New surgical technique of pulmonary segmentectomy by ultrasonic scalpel and absorbable sealing materials. *Kyobu Geka* 2004; 57: 31-37.
- [21] Belda-Sanchis J, Serra-Mitjans M, Iglesias Sentis M, Rami R. Surgical sealant for preventing air leaks after pulmonary resections in patients with lung cancer. *Cochrane Database Syst Rev* 2010; CD003051.
- [22] Murray KD, Ho CH, Hsia JY, Little AG. The influence of pulmonary staple line reinforcement on air leaks. *Chest* 2002; 122: 2146-2149.
- [23] Nakajima S, Fukuda T, Hasue M, Sengoku Y, Haraoka J, Uchida T. New technique for application of fibrin sealant: rubbing method devised to prevent cerebrospinal fluid leakage from dura mater sites repaired with expanded polytetrafluoroethylene surgical membranes. *Neurosurgery* 2001; 49: 117-123.
- [24] Dickneite G, Metzner H, Pfeifer T, Kroez M, Witzke G. A comparison of fibrin sealants in relation to their in vitro and in vivo properties. *Thromb Res* 2003; 112: 73-82.