

## Original Article

# Clinical effects of laser photocoagulation in 160 cases of retinopathy of prematurity

Caiping Shi, Ji Jin, Bin Lu, Huihui Zhu, Huaying Xie, Yanhong Ren, Jia Feng

*Department of Ophthalmology, The Children's Hospital, Zhejiang University School of Medicine, Hangzhou 310006, Zhejiang Province, China*

Received September 14, 2015; Accepted December 24, 2015; Epub February 15, 2016; Published February 29, 2016

**Abstract:** Objective: This study aimed to observe the clinical effects of laser photocoagulation in treating retinopathy of prematurity (ROP), and to explore the influence of anesthesia on the disease prognosis. Methods: The study involved the retrospective analysis of 312 eyes treated with laser photocoagulation. The prognosis of ROP was observed, and its relationships with such factors as the gestational age, birth weight, age of onset, gestational age when firstly performed the laser photocoagulation correction (FPLPC), lesion site, additional lesions, photocoagulation number and anesthetic method used were analyzed. Results: The lesions present in 293 of the eyes completely resolved, while those of the remaining 19 eyes progressed (lesion regression and progression groups, respectively). The comparison of the gestational age, birth weight, age of onset, and FPLPC-gestational age between the two groups showed no statistically significant differences ( $t = 1.461, 0.088, 1.571$ , and  $1.576$ , respectively;  $P > 0.05$ ); the comparison of the anesthetic method used and the number of additional lesions too showed no significant differences between the groups ( $\chi^2 = 0.3285$  and  $0.203$ , respectively;  $P > 0.05$ ). The differences in the presence of lesions in region I and the photocoagulation numbers were statistically significant between the two groups ( $\chi^2 = 18.08, P < 0.05$ ;  $t = 3.522, P < 0.05$ , respectively). The FPLPC-gestational age and the photocoagulation numbers were correlated with the lesion progression after photocoagulation. Logistic regression analysis revealed that AP-ROP was associated with the progress of the photocoagulation-induced postoperative pathological changes ( $P = 0.001$ ). Conclusions: Laser photocoagulation is an effective treatment modality for ROP. Employing different anesthetic methods does not significantly affect the post-photocoagulation prognosis of ROP.

**Keywords:** Laser photocoagulation, prematurity, retinopathy of prematurity, therapy

## Introduction

Retinopathy of prematurity (ROP) is a retinal vascular disease that occurs in preterm children, and is an important cause of childhood blindness [1, 2]. Because of the differences among the patients in terms of the demographic characteristics (country, race, and population) as well as those in the perinatal care and screening standards, the incidence and risk factors of ROP are varying [3-6]. The WHO had included ROP control in the "2020 plan of vision" [7]. In recent years, the improvements in perinatal and neonatal emergency medicine in our country have continuously increased the survival rates of the low-birth-weight and preterm children; consequently, the incidence and blinding rates of ROP have also correspondingly increased [1, 2, 8, 9]. The improvement of the quality of life of the surviving preterm children and lowering of the visual disability

rates are important issues being addressed in the current development and management of Chinese medicine. Effective ways to prevent ROP-induced blindness are early detection, early diagnosis, and timely intervention. Currently, binocular indirect ophthalmoscopic laser delivery to the retinal avascular zone is recognized as the best method for treating ROP [10]. Our hospital used the binocular indirect ophthalmoscope imaging technology to perform retinal photocoagulation on a total of 312 eyes of 160 preterm children with ROP, using a 532-nm semiconductor laser beam, the results of which are presented here.

## Material and methods

### Subjects

The study involved 160 children with ROP (312 eyes) who underwent indirect ophthalmoscopic

## Clinical observation of laser photocoagulation

laser therapy at our hospital between March 2009 and March 2014. Of the 160 children, 101 were male (198 eyes), and 59 were female (114 eyes); the mean gestational age at birth was  $28.68 \pm 1.90$  weeks (range, 25-34 weeks) and the mean weight at birth was  $1,274.40 \pm 347.25$  g (580-2,535 g). All of the eyes with ROP were photographed by experienced ophthalmologists using a wide-angle retinal imaging system for children (RetcamII, Massie Research Laboratories Inc., USA), and the locations of the ROP lesions were recorded in each case. The binocular indirect ophthalmoscope and a +20D (diopter) lens were used for screening the eyes in a dilated state for ROP; when necessary, a scleral depressor was used to observe the entire eye; especially, the developmental state of the peripheral retina and the lesions were recorded in detail. The ROP was classified on basis of the International Classification of Retinopathy of Prematurity (ICROP). The inclusion criteria, based on the recommendations of the Early Treatment for ROP (ETROP) cooperative group [6, 7], were: 1) prethreshold disease type I: phases 1, 2, and 3 of ROP in region I, accompanied by plus disease; phase 3 ROP in region I, unaccompanied by plus disease; or phases 2 and 3 of ROP in region II, accompanied by the plus disease; 2) threshold lesion: phase 3 ROP for five continuous or eight intermittent clock-hours, accompanied by plus disease; 3) plus disease: defined as the presence of retinal vascular dilation and tortuosity in the posterior pole for at least two quadrants. The patients with ROP findings consistent with the threshold disease and prethreshold disease type I underwent laser treatment within 24 h, once parental consent was obtained; the patients with aggressive ROP underwent emergency laser treatment. Of the 160 patients included in this study, 92 eyes of 46 patients presented the prethreshold disease type I, and 220 eyes of 114 patients presented the threshold disease. This study was conducted in accordance with the declaration of Helsinki. This study was conducted with approval from the Ethics Committee of Zhejiang University. Written informed consent was obtained from all participants' guardians.

### *Preoperative preparation*

The patients were fasted and forbidden any fluids from 4 h before the surgery, during which intravenous rehydration was administered. The patients were routinely administered Mydrin

eyedrops (5 g/L tropicamide and 5 g/L phenylephrine HCl; Santen Pharmaceutical Co.) for mydriasis an hour before the surgery (1 drop/administration at 10 min intervals for a total of 4 times).

### *Anesthetic preparation*

The surgery was performed on the radiation beds of the care unit. Local anesthesia was performed using Alcaine eye drops (Alcon Inc.), and a nasal catheter was inserted for oxygen; meanwhile, the patient's stability was monitored by an electrocardiogram (ECG). The patient's head was positioned by experienced nurses. Thermal insulation of the anesthetized patient was maintained in the operating room with a warm-to-touch heating blanket. The body temperature, blood pressure, heart rate, and oxygen saturation were routinely monitored. A 0.2 mg/kg solution of midazolam was intravenously administered, and the concentration of sevoflurane was adjusted to 6%; the oxygen flow rate was set at 5 L/min. Tracheal intubation was performed when the patient's jaw relaxed and the breathing significantly decreased after the administration of the sevoflurane inhalant through the mask. During the surgery, the anesthesia was maintained with sevoflurane, maintained at a concentration of 3-4%. The oxygen concentration was maintained at 21-30%, and the SpO<sub>2</sub> at 95-98%; a micro-pump was used to control the amount of liquid perfusion. The patient's breathing was controlled by a breathing machine.

### *Surgical approach*

After the patient's head was fixed, photocoagulation was performed by binocular indirect ophthalmoscopic laser delivery to the retinal ridge and peripheral avascular area with the assistance of a +20D lens, using the Novus Spectra high-power 532 laser system (Lumenis Inc., USA). The distal peripheral retina was target for laser photocoagulation using a scleral depressor. The power of the laser beam was set as 160-220 mW, with a time interval of 0.3 s and a space interval of 0.3 spots, and a laser burn of off-white intensity was selected to be appropriate for treatment.

### *Postoperative eye care and follow-up*

After surgery, the patients were administered Cravit eye drops four times a day and Tobradex

**Table 1.** Characteristics of the study groups

	Lesion regression group	Lesion progression Group
Cases (n)	150	10
Eyes (n)	293	19
Gender	94 boys, 56 girls	7 boys, 3 girls
Gestational age (weeks)	28.70 ± 1.91	27.80 ± 1.40
Onset age (days)	61.61 ± 22.40	56.00 ± 22.13
FPLPC-gestational		
Age (weeks)	37.18 ± 3.08	35.60 ± 3.57
Birth weight (g)	1278.91 ± 354.26	1206.40 ± 216.90
Photocoagulation spots (spot)	613.99 ± 404.91	976.00 ± 748.63
Anesthesia		
Local anesthesia	82 cases	6 cases
General anesthesia	68 cases	4 cases

ointment two times a day, for a week. All of the patients were subjected to periodic reviews at 1 week, 2 weeks, 1 month, 3 months, 6 months, 9 months, 12 months, 18 months, and 24 months post-treatment by laser photocoagulation. The previously mentioned wide-angle digital retinal imaging system for children (RetCam II, Massie Research Laboratories Inc.) was used for recording the lesion regression or progression in the retinal vascular and avascular zones; the retinal vascular dilation, tortuosity, and regression, as well as the conditions of the cornea, iris, pupils, and lens were recorded. The efficacy of the treatment in terms of effecting the regression of the ROP was then evaluated. In cases where the lesion-zones had been missed during initial treatment and in those presenting vascular crest development and non-reduced plus disease within 2 weeks of the photocoagulation, the treatment was repeated.

#### Data analysis

The children with ROP were grouped into two groups on the basis of the results recorded at the last follow-up: the lesion regression (293 eyes of 150 patients) and lesion progression (19 eyes of 10 patients) groups. The patients who presented postoperative findings of normal retinal vessels, regressed vascular ridge and neovessels, subsided plus disease, normal retinal anatomical structures, and photocoagulation fusion plaques formed by the pigment plaques were included in the lesion regression group. The patients with postoperative vitreous

hemorrhage, fibrovascular proliferation, poor retinal structures, and the disease progression to 4 to 5 phase (partial or total retinal detachment) were divided into the lesion progression group. The statistical analysis used the SPSS17.0 statistical software. According to the prognosis, the patients were divided into the lesion regression group and the lesion progression group, the gestational age, birth weight, onset age, firstly performed the laser photocoagulation correction (FPLPC)-gestational age of the 2 groups were compared with the two sample mean t test,

the lesion region, extent, anesthesia method, plus disease of the two groups were performed the continuously corrected  $\chi^2$  test, with  $P < 0.05$  considered as the statistical significance. The Pearson correlation analysis was applied to study the factors that were related to the disease progression after the photocoagulation surgery.

## Results

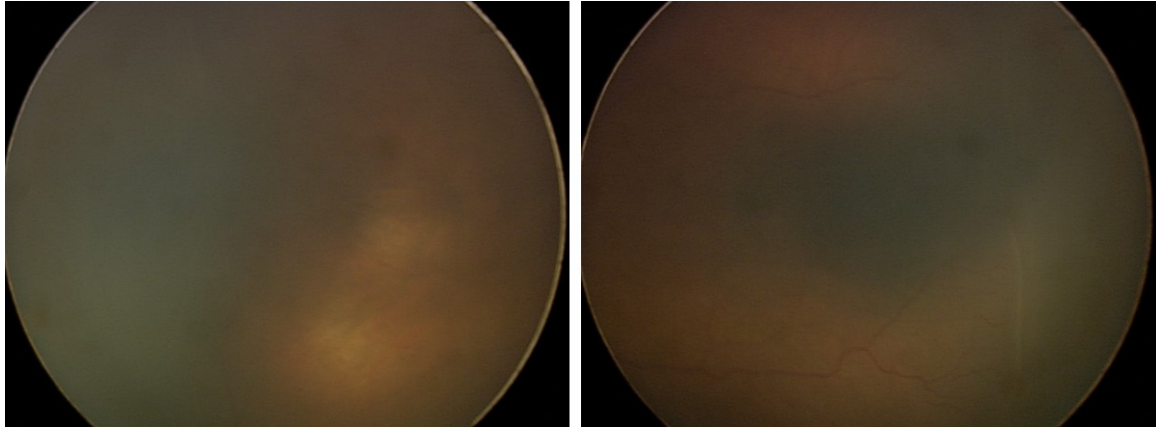
### Characteristics of subjects

In this study, a total of 312 eyes from 160 ROP patients were enrolled, including 101 boys (198 eyes), and 59 girls (114 eyes); the gestational age was 25~34 (28.68 ± 1.90) weeks, and the birth weight was 580~2535 (1274.40 ± 347.25) g. All the patients underwent 532-nm semiconductor laser treatment under an indirect ophthalmoscope, and were divided into the lesion regression group and the lesion progression group after the treatment according to the prognosis; the characteristics of the two groups are shown in **Table 1**.

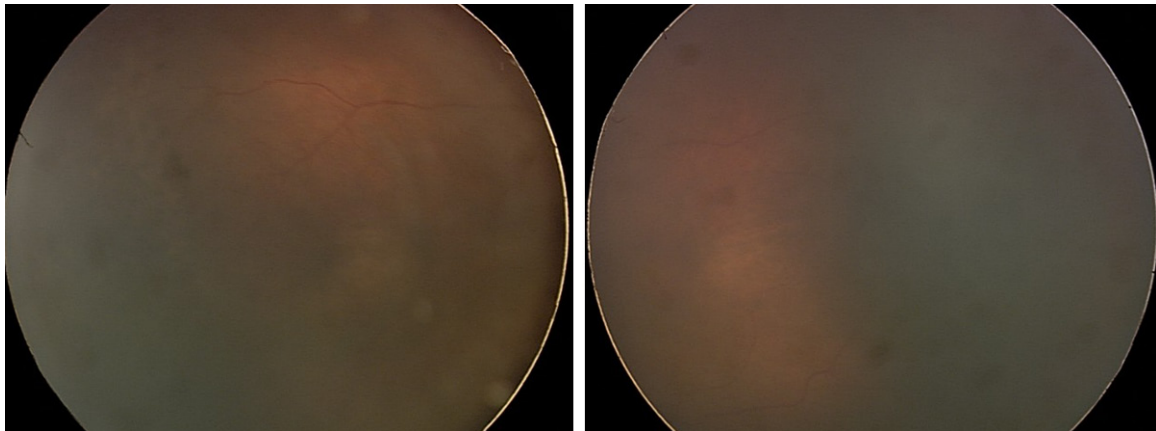
### Effectiveness analysis of photocoagulation treatment

Among the 312 ROP eyes, a total of 289 eyes exhibited complete lesion regression after the first laser photocoagulation treatment, and 4 eyes exhibited lesion regression after the 2<sup>nd</sup> laser photocoagulation treatment, i.e., the lesion ridges in the retinal vascular and avascular zones regressed, there existed no dilation and tortuosity of retinal blood vessels, the total

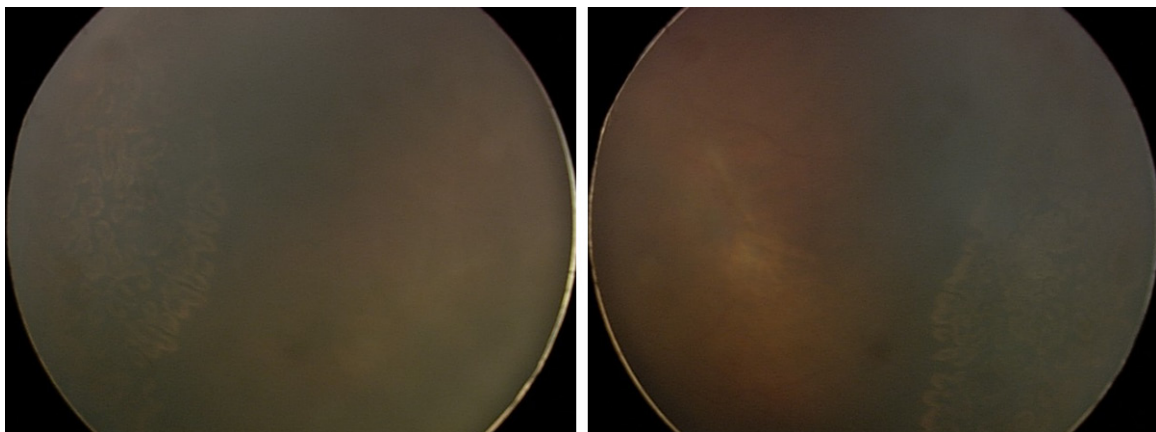
## Clinical observation of laser photocoagulation



**Figure 1.** Two days before LP.



**Figure 2.** One week after LP.



**Figure 3.** One month after LP.

cure rate was 93.91% (**Figures 1-3**), and 19 eyes exhibited lesion progression (6.09%), 7 eyes exhibited partial fibrous proliferation, 12

eyes continuously progressed to limited retinal detachment and underwent vitreoretinal surgery; there existed no intraoperative and post-



## Clinical observation of laser photocoagulation

**Table 2.** Pearson correlation analysis among the ROP prognosis and gender, birth weight, FPLPC-gestational age, onset age, laser spots and anesthesia method

Prognosis	Gender	Birth weight	FPLPC-gestational age	Onset age	Laser spots (right eye)	Laser spots (left eye)	Anesthesia method	Acute aggressive type
Prognosis	0.055	-0.067	-1.184*	-0.122	0.279*	0.263*	-0.085	0.317**
Gender		0.100	0.019	0.111	-0.084	-0.132	-0.012	-0.054
Birth weight			0.281*	-0.083	-0.251*	-0.221*	0.176*	0.044*
FPLPC-gestational age				0.652*	0.198**	0.250*	0.361*	-0.056*
Onset age					0.133	0.167**	0.221*	-0.048*
Laser spots (right eye)						0.804*	0.089	0.188
Laser spots (left eye)							-0.143	0.155
Anesthesia method								0.063
Acute aggressive type								1

\*Significantly correlated at the bilateral level of 0.05. \*\*Significantly correlated at the bilateral level of 0.01. FPLPC: laser photocoagulation correction.

operative iris burns, miosis, lenticular opacity, macular burns, eye infections and other complications.

*Comparison of birth weight, gestational age, onset age, FPLPC-gestational age, anesthesia method and plus disease*

After the ROP photocoagulation, the lesion regression group showed the following characteristics: the birth weight was 580 to 2535 g (average,  $1278.93 \pm 354.26$  g), the gestational age was 25 to 34 weeks (mean,  $28.7 \pm 1.91$  weeks), the onset age was 15~161 days after the birth (average,  $61.61 \pm 22.40$  days after birth), the FPLPC-gestational age was 32 to 45 weeks (average,  $37.18 \pm 3.08$  weeks); the lesion progression group had the following characteristics: birth weight was 950 to 1614 h (average,  $1206.40 \pm 216.90$  g), gestational age was 26 to 30 weeks (mean,  $27.8 \pm 1.40$  weeks), onset age was 19 to 105 days after birth (average,  $56.00 \pm 22.13$  days), FPLPC-gestational age was 29 to 43 weeks (mean,  $35.6 \pm 3.57$  weeks). Comparisons between the two groups revealed that the birth weight, gestational age, onset age, and FPLPC-gestational age had no statistically significant difference ( $t = 1.461, 0.088, 1.571, 1.576$ ;  $P > 0.05$ ). Meanwhile, comparisons between the two groups also revealed that 82 cases of the lesion regression group involved local anesthesia and 68 cases involved general anesthesia, while the lesion progression group had 6 cases of local anesthesia and 4 cases of general anesthesia, the lesion regression group had 42

cases of plus disease, and the lesion progression group had 4 cases; the anesthesia method and the incidence of plus disease between the 2 groups showed no significant difference ( $\chi^2 = 0.3285, 0.203$ ;  $P > 0.05$ ).

*Comparative analysis of retinal lesion sites and laser photocoagulation spots*

The region I lesion was noted in 19 eyes, among which 13 eyes exhibited lesion regression (68.42%), and 6 eyes exhibited lesion progression (31.58%); the region II lesion was noted in 293 eyes, among which 280 eyes exhibited lesion regression (95.56%), and 13 eyes exhibited the lesion progression (4.44%); the disease progression rate in region I was significantly higher than that in region II, and the difference was statistically significant ( $\chi^2 = 18.48$ ,  $P < 0.001$ ).

The photocoagulation spots in the lesion regression group were  $613.99 \pm 404.91$ , and those in the lesion progression group were  $976.00 \pm 748.63$ ; the two sample mean t test revealed a statistically significant difference ( $t = 3.522$ ,  $P < 0.05$ ). The photocoagulation spots in the lesion progression group were significantly greater than those in the lesion regression group.

*Correlation analysis of gestational age, birth weight, FPLPC-gestational age, anesthesia method, laser points, and prognosis*

Among the 312 eyes, 22 eyes were of the acute progressive posterior ROP (AP-ROP), and

18.18% (4/22) progressed to stage 4a after the photocoagulation surgery, thus requiring further vitreoretinal surgery. Among the 293 eyes of the lesion regression group, AP-ROP was noted in 14 eyes (4.78%), while non-AP-ROP was observed in 279 eyes (95.22%); among the 19 eyes of the lesion progression group, AP-ROP was observed in 8 eyes (42.10%), while non-AP-ROP was observed in 11 eyes (57.89%). AP-ROP of the lesion progression group was significantly greater than that in the lesion regression group, and the difference was statistically significant ( $\chi^2 = 32.45$ ,  $P = 0.000$ ).

The Pearson correlation analysis among the ROP prognosis and gender, birth weight, FPLPC-gestational age, onset age, laser spots and anesthesia method, etc., showed that the FPLPC-gestational age, laser spots, and acute aggressive ROP type, etc., were related with post-photocoagulation lesion progression ( $P < 0.05$ , **Table 2**). The lesion prognosis after the photocoagulation was set as the dependent variable, and the univariate analysis indicated significant factors (namely, the ROP lesion partition, threshold lesion, aggressive ROP, and laser points) were set as the independent variables for the evaluation of the relationships between these factors and the effects of the photocoagulation treatment, by logistic regression analysis. Whether the impact of each of the factors on the effects of treatment was statistically significant was first analyzed for variable selection; ultimately, aggressive ROP showed significant a regression impact and was selected into the model. The results showed that, at  $\alpha = 0.05$ , aggressive ROP showed statistical significance and was the independent risk factor for the prognosis of laser photocoagulation. The possibility of lesion progression in patients with aggressive ROP after photocoagulation was 14.667 times greater than that in those with non-aggressive ROP (95% CI: 3.145~57.084,  $P = 0.001$ ).

### Discussion

ROP is a retinal vascular disease that occurs in preterm children, because of the immature retinal development, retinal ischemia and neovascularization, proliferative retinopathy, and the resulting tractive retinal detachment. Certain studies had shown that the generation of ROP could be divided into two stages: the first stage

mainly exhibits hypoxia-resulted vascular occlusion, the second stage mainly involves post-hypoxia neovascularization stage [11-13]. The laser could damage the retinal avascular zone, reduce the retinal metabolic oxygen demand, eliminate the retinal ischemia, reduce the ischemia and hypoxia-induced neoangiogenetic growth factors, and inhibit the occurrence and development of new blood vessels, thus terminating the progression of ROP. Currently, domestic and foreign researchers all agree that laser photocoagulation is the most important means to control the lesion progression of early ROP [14-16]. The indirect ophthalmoscopic laser could treat the peripheral retinal lesions under the help of direct vision and a scleral depressor, with accurate positioning and a simple treatment process; the 532-nm semiconductor laser was the infrared laser, the penetrative ability was strong, and could be absorbed by the retinal pigment thus produce the photocoagulation, it mainly acted on the middle and outer layers of choroid, and could penetrate the cloudy lens and mildly hemorrhagic vitreous body, thus the complications were fewer, and the incidence of intraocular hemorrhage was lower, and the damages towards the choroid and retina were slight [8]. In this study, 312 eyes underwent the laser treatment, after the first laser surgery, 289 eyes exhibited lesion regression, and after the second laser surgery, 4 eyes exhibited lesion regression, while 19 eyes exhibited partial fibrous proliferation and continuously progressed to the limited retinal detachment; after subsequent vitreoretinal surgery, the total cure rate was up to 93.91%. The results confirmed that the laser treatment was the ideal choice for ROP. Kim and Lee [17] performed photocoagulation towards the peripheral retina avascular zone of threshold-phase ROP, and 86% (96/111) lesions exhibited complete regression after the surgery. Gunay et al. [18] retrospectively studied the situations of 202 eyes of 113 ROP cases after the laser photocoagulation therapy, among which 141 eyes were in the prethreshold stage, 29 eyes were in the threshold stage, and 32 eyes were in the acute aggressive stage; after the photocoagulation, 171 eyes exhibited the complete regression (84.7%). The results of this study were consistent with the foreign literature, and there were no intraoperative and postoperative complications such as iris burns, miosis, lenticular opacity, and eye infections.

At the same time, the patients were divided into the lesion progression group and the lesion regression group according to the prognosis, and comparisons of birth weight, gestational age, onset age, FPLPC-gestational age, anesthesia method and plus disease showed no statistically significant difference, suggesting the laser treatment prognosis had no significant correlation with the birth weight, gestational age, onset age, FPLPC-gestational age, anesthesia method and plus disease, similar to Kim and Lee [17]. In addition, Gotz-Wieckowska et al. [19] and Talu et al. [20] considered that the lower the birth weight and the smaller the FPLPC-gestational age, the bigger the possibility of poor prognosis after the laser photocoagulation. Our results were not fully consistent with their results. The possible reasons might be related with the development status of systemic multi-system and multi-organ disease when the preterm children were born, such as the combination of neonatal apnea, poor neonatal lung development and neonatal pneumonia. We still need further studies and comparative data to validate this assumption. We compared the region I of retinopathy, laser photocoagulation spots, and aggressive ROP between the 2 groups, and found that the differences had the statistical significance: the lesion progression rate in region I was significantly higher than that in region II, and the number of photocoagulation spots in the lesion progression group was significantly higher. It was reported in the domestic and foreign literature that the incidence of adverse prognosis in region I was 3.3 times that in region II [21], but in this study, the incidence of disease progression of ROP laser treatment in region I was relatively higher than that in region II, as high as 7.11 times. The results suggested that the lesions in region I often implied an adverse prognosis, and needed a high degree of vigilance.

Currently, as for the anesthesia method in the laser photocoagulation treatment reported in the domestic literature, a few surgeries were performed under local anesthesia, when it would be difficult to ensure the children's complete quietness, and some surgeries were carried out under general anesthesia, but most children were of low birth weight when they underwent the ROP surgery; in addition, their vitals were low, and some children would even lose the surgical opportunity or exhibit anesthesia accidents because it was difficult for

them to tolerate the general anesthesia. Our study found that different anesthesia methods showed no significant difference towards the lesion regression and progression after the ROP laser treatment. However, our study also found that 5 children exhibited apnea under local anesthesia (5.49%), 3 cases exhibited corneal edema (3.30%) while under general anesthesia, 1 case (1.10%) exhibited difficulty during withdrawal from the breathing machine, and no other complications appeared. We speculated that the apnea that appeared under local anesthesia might be associated with the non-perfect development of the children's respiratory system, as well as the intraoperative oculocardiac reflex and the locally anesthetized eye could not completely alleviate the pain. Normally, the apnea could be remitted after pausing the surgery and stimulating the soles, so that the operation could be continued. The corneal edema might be associated with the temperature control of the, radiation bed, children's writhing under the local anesthesia, and relatively long operation time, etc. In the one case of general anesthesia where the patient exhibited difficulty during withdrawal from the ventilator, this child had the poor development of respiratory system preoperatively, and the general conditions were poor, and this child's tolerance towards the general anesthesia was poor, and postoperative respiratory infections appeared, which increased the difficulty during withdrawal from the breathing machine. Therefore, we believed that the whole body conditions should be weighed when selecting the anesthesia method for ROP laser surgery, and should also be combine with information regarding the extent of the ocular lesion and the expected operation time when performing the surgery. As for the children with respiratory dysplasia and poor general conditions, they could not tolerate general anesthesia, while exhibiting less systemic side effects under the local anesthesia, and they might show the advantages of timely and effective laser photocoagulation. As for the older children that had good body conditions, wide eye lesion ranges, severe lesions, expected long operation time, and difficulties to hold the head fixed, general anesthesia would be better for the laser photocoagulation treatment.

In summary, currently, laser photocoagulation is the most important and most effective clinical method for the ROP treatment. The post-

photocoagulation effects were affected by many factors, and the aggressive ROP was the most important type. Our study found that the ROP treatment effects had no significant correlation with the anesthesia method; therefore, when we chose the anesthesia method, the children's general conditions and eye lesions should be weighed, so that a safe and effective anesthesia method could be chosen to minimize the complications.

## Disclosure of conflict of interest

None.

**Address correspondence to:** Caiping Shi, Department of Ophthalmology, The Children's Hospital, Zhejiang University School of Medicine, No. 57 Zhugan Road Xiacheng District, Hangzhou 310006, Zhejiang Province, China. Tel: +86 0571 88873295; Fax: +86 0571 86531658; E-mail: caipingshcn@163.com

## References

- [1] Multicenter trial of cryotherapy for retinopathy of prematurity: preliminary results. Cryotherapy for Retinopathy of Prematurity Cooperative Group. *Pediatrics* 1988; 81: 697-706.
- [2] Palmer EA, Flynn JT, Hardy RJ, Phelps DL, Phillips CL, Schaffer DB and Tung B. Incidence and early course of retinopathy of prematurity. The Cryotherapy for Retinopathy of Prematurity Cooperative Group. *Ophthalmology* 1991; 98: 1628-1640.
- [3] Phan MH, Nguyen PN and Reynolds JD. Incidence and severity of retinopathy of prematurity in Vietnam, a developing middle-income country. *J Pediatr Ophthalmol Strabismus* 2003; 40: 208-212.
- [4] Mutlu FM and Sarici SU. Retinopathy of prematurity: incidence and risk factors. *Expt Rev Ophthalmol* 2007; 2: 267-274.
- [5] Saldır M, Sarici SU, Mutlu FM, Mocan C, Altınsoy HI and Özcan O. An analysis of neonatal risk factors associated with the development of ophthalmologic problems at infancy and early childhood: a study of premature infants born at or before 32 weeks of gestation. *J Pediatr Ophthalmol Strabismus* 2010; 47: 331-337.
- [6] Hoogerwerf A, Schalijs-Delfos NE, van Schooneveld MJ and Termote JU. Incidence of retinopathy of prematurity over the last decade in the Central Netherlands. *Neonatology* 2010; 98: 137-142.
- [7] Gilbert C and Foster A. Childhood blindness in the context of VISION 2020—the right to sight. *Bull World Health Organ* 2001; 79: 227-232.
- [8] An international classification of retinopathy of prematurity. The Committee for the Classification of Retinopathy of Prematurity. *Arch Ophthalmol* 1984; 102: 1130-1134.
- [9] Lomuto CC, Galina L, Brussa M, Quiroga A, Alda E, Benítez AM, Bouzas L, Dinerstein NA, Erpen N, Falbo J, Manzitti J, Marinaro S, Nieto R, Sepúlveda T and Visintín P. Epidemiology of retinopathy of prematurity in public services from Argentina during 2008. *Arch Argent Pediatr* 2010; 108: 24-30.
- [10] Hunetr DG and Repka MX. Diode laser photocoagulation for threshold retinopathy of prematurity. A randomized study. *Ophthalmology* 1993; 100: 238-244.
- [11] Smith LE. Pathogenesis of retinopathy of prematurity. *Semin Neonatol* 2003; 8: 469-473.
- [12] Chen J, Stahl A, Hellstrom A and Smith LE. Current update on retinopathy of prematurity: screening and treatment. *Curr Opin Pediatr* 2011; 23: 173-178.
- [13] Fielder AR and Posner EJ. Neonatal ophthalmology. In: Rennie JM, editor. *Robertson's Textbook of Neonatology*. London: Elsevier Churchill Livingstone; 2005. pp. 835-850.
- [14] Ng EY, Connolly BP, McNamara JA, Regillo CD, Vander JF and Tasman W. A comparison of laser photocoagulation with cryotherapy for threshold retinopathy of prematurity at 10 years: part 1. Visual function and structural outcome. *Ophthalmology* 2002; 109: 928-934; discussion 935.
- [15] Early Treatment For Retinopathy Of Prematurity Cooperative Group. Revised indications for treatment of retinopathy of prematurity: results of the early treatment for retinopathy of prematurity randomized trial. *Arch Ophthalmol* 2003; 121: 1684-1694.
- [16] Axer-Siegel R, Maharshak I, Snir M, Friling R, Ehrlich R, Sherf I, Shalev B, Sirota L and Weinberger D. Diode laser treatment of retinopathy of prematurity: anatomical and refractive outcomes. *Retina* 2008; 28: 839-846.
- [17] Kim JE and Lee AC. Demographic changes and response to laser treatment in threshold retinopathy of prematurity: 10-year experience. *J Pediatr Ophthalmol Strabismus* 2010; 47: 231-235.
- [18] Gunay M, Celik G, Ovali F, Yetik H, Aktas A and Gunay BO. One-year clinical outcome after laser treatment for retinopathy of prematurity at a tertiary center in Turkey. *Int Ophthalmol* 2014; [Epub ahead of print].
- [19] Gotz-Wieckowska A, Kociekci J, Burchardt-Kroll E and Gadzinowski J. The results of diode



## Clinical observation of laser photocoagulation

- treatment of active phase of retinopathy of prematurity. *Klin Oczna* 2003; 105: 395-397.
- [20] Talu S, Cormos D, Zaharia G, Stefanut C, Popa M and Lucaci DI. Prognostic factors for laser treatment in retinopathy of prematurity. *Oftalmologia* 2011; 55: 84-89.
- [21] Foroozan R, Connolly BP and Tasman WS. Outcomes after laser therapy for threshold retinopathy of prematurity. *Ophthalmology* 2001; 108: 1644-1646.