

## Case Report

# Recurrence of central neurocytoma in the brain parenchyma: a case report

Dawei Wang<sup>1,2</sup>, Yanqiu Wang<sup>2</sup>, Wei Wei<sup>1</sup>, Zongze Guo<sup>1</sup>

<sup>1</sup>Department of Neurosurgery, 1st Hospital of China Medical University, Shenyang 110001, Liaoning, People's Republic of China; <sup>2</sup>Department of Neurosurgery, Benxi Central Hospital, Benxi 117000, Liaoning, People's Republic of China

Received July 7, 2015; Accepted January 15, 2016; Epub February 15, 2016; Published February 29, 2016

**Abstract:** Central neurocytomas and extraventricular neurocytomas are rare benign tumors of the central nervous system located in different parts of the brain. Notably, central neurocytomas can recur and disseminate into the ventricles of the brain after total resection. Here we report a case of central neurocytoma recurrence in the brain parenchyma that occurred 10 years after resection.

**Keywords:** Central neurocytomas, extraventricular neurocytoma, brain parenchyma, recurrence

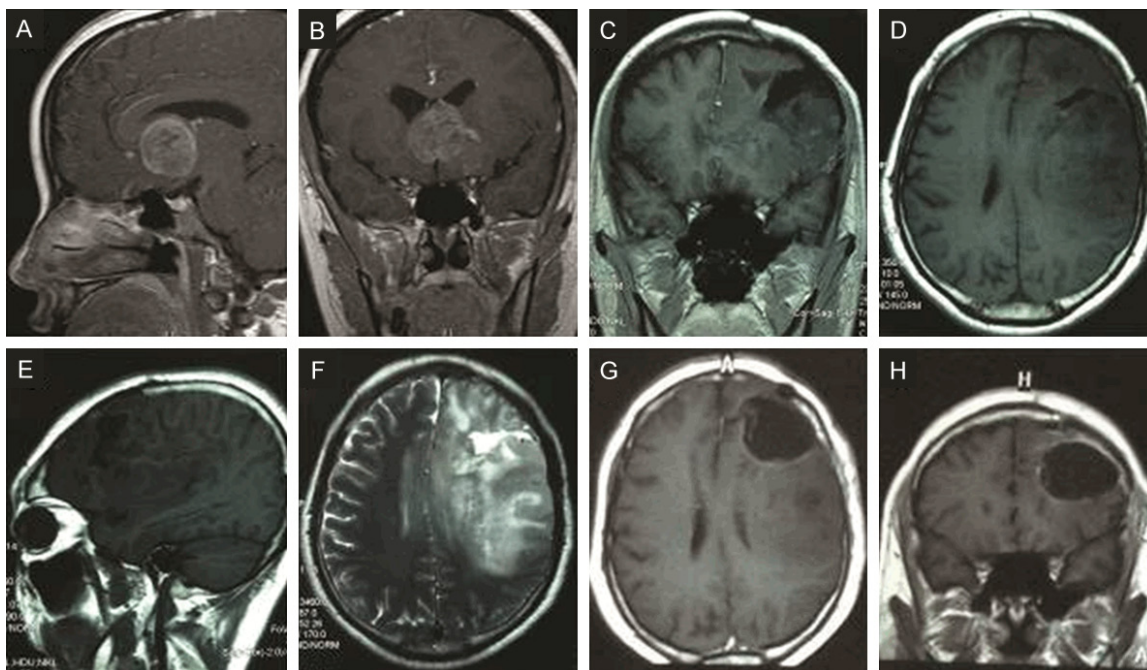
### Introduction

Central neurocytomas (CNs), first described by Dr. Hassoun [1], are small cell neuronal tumors commonly located near the foramen of Monro (septum pellucidum) or the lateral or third ventricles. CNs are rare neuronal neoplasms that account for 0.25-0.5% of all primary central nervous system tumors. Although CNs have been thought to be the relatively low-grade tumors, accumulating evidence suggests that some CNs are more aggressive with a propensity for recurrence and progression [2]. Moreover, most CN patients are young adults who have symptoms of increased intracranial pressure. Extraventricular neurocytomas (EVNs) are tumors with biological and histopathological characteristics similar to CNs but that originate from extraventricular parenchymal tissue [3]. In the 2007 World Health Organization (WHO) classification of central nervous system tumors, EVNs were identified as a separate entity and variant of CN [4]. Herein, we report a rare case of CN recurrence in the brain parenchyma.

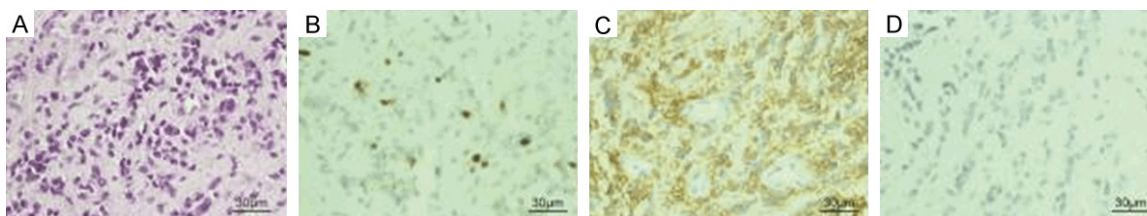
### Case presentation

A 29-year-old man was admitted to the neurosurgery department at our hospital due to per-

sistent severe headache lasting for 2 months in 2004. His neurological exam was unremarkable. Magnetic resonance images (MRI) showed a T1 isointensity and T2 hyperintensity lesion close to the foramen of Monro, with heterogeneous contrast enhancement (**Figure 1**). Subsequently, the patient underwent a transcortical craniotomy and gross total block resection without any complications. The tumor was yellow and friable, and we did not notice any hemorrhage or necrosis in the lesion. The tumor margin was clearly defined. Pathological examination confirmed the diagnosis of neurocytoma. Histopathological analysis showed an oligodendroglioma-like honeycomb appearance and that the tumor was composed of homogenous, small uniform cells (**Figure 2**). The cytoplasm was not well defined, and the nuclei were round and slightly lobulated. Aggregation of the anuclear tumor cells were found in some areas as well. Delicate vasculature formed a branching network in a pattern similar to that seen in oligodendroglioma. Endothelial proliferation and necrosis were absent. Moreover, immunohistochemical staining identified that the tumor was positive for synaptophysin and negative for NeuN. The cell proliferation index with Ki67 was 5% (**Figure 2**). Eventually, the patient was discharged without any neurologic deficits. One year later, the patient developed intermittent



**Figure 1.** Pre-operative MR images showing (A, B) heterogeneous enhancement of lesion near the foramen of Monro in 2004. (C-E) Pre-operative contrast-enhanced T1 weighted images showing a nonenhancing lesion in the left frontal area around the initial operative route in 2014, and (F) pre-operative T2 weighted images showing a hyperintensity lesion in the left frontal area around the initial operative route in 2014. (G, H) MR images taken after the second operation.

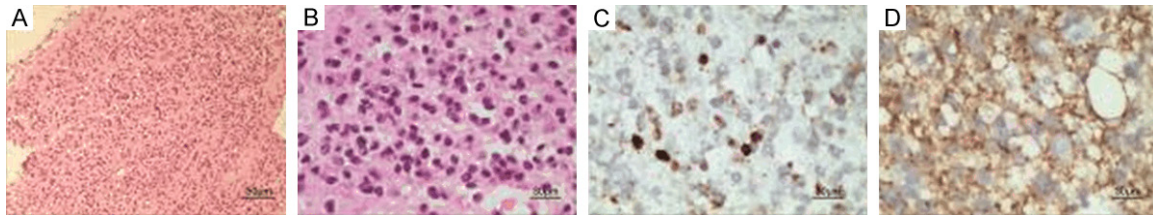


**Figure 2.** Histopathologic staining of the lesion resected during the first craniotomy. (A) The tumor was composed of uniform round cells with or without clear cytoplasm (hematoxylin-eosin staining; magnification, ×400), (B) Immunohistochemical staining demonstrating neoplastic cells exhibiting immunoreactivity with a MIB-1 (Ki-67) labeling index of 5% (magnification, ×400). Tumor cells showed (C) immunopositivity for synaptophysin and (D) immunonegativity for neuronal nuclei (magnification, ×400).

right facial spasms, and medication yielded effective control of this symptom. At the 36-month follow-up, the patient had been stable without any signs of neurological dysfunction.

Ten years later, the patient was admitted to our hospital again due to the onset of grand mal seizures associated with loss of consciousness. Repeated MRI revealed a non-enhancing lesion of T2 hyperintensity and T1 hypointensity in the left frontal area close to his previous

operative route (**Figure 1**). Subsequently, the patient underwent a left frontal craniotomy, and a tumor was removed with mild bleeding as the tumor was not dura. Consequently, pathological examination confirmed the tumor to be a neurocytoma (**Figure 3**). Based on his clinical history, the tumor location, and the pathological results, we confirmed the final diagnosis of CN. Consequently, the patient was treated with adjuvant radiotherapy. At the 6-month follow-up, the patient had been stable without any signs of neurological dysfunction. Informed



**Figure 3.** Histopathologic staining of the lesion resected during the second craniotomy. A, B. The tumor was composed of uniform round cells with or without clear cytoplasm (hematoxylin-eosin staining, magnification,  $\times 100$  in A, and  $\times 400$  in B). C. Immunohistochemical staining demonstrating neoplastic cells exhibiting immunoreactivity with a MIB-1 (Ki-67) labeling index of 5% (magnification,  $\times 400$ ). D. The tumor cells showed immunopositivity for synaptophysin.

consent has been obtained from the patient for publishing this case and related photographs.

## Discussion

In general, CNs are thought to be benign; however, recurrence of CNs as well as dissemination into the ventricles of the brain during long-term postoperative follow-up have been reported. To date, 19 cases of CN with recurrence at the ventricles of the brain or spinal cord have been reported [5], but only one case of CN recurrence in the dura has been reported [6]. The present case is the first reported case of CN recurrence in the brain parenchyma.

One possible mechanism of CN dissemination is the seeding of tumor cells along the surgical trajectory. During the resection procedure, tumor cells can remain along the operative route and grow [7]. Another possible mechanism is the spreading of tumor cells through the cerebrospinal fluid (CSF). According to published reports, neurocytoma recurrence can occur along the CSF pathway in the ventricles of the brain or spinal cord. We believe that dissemination of neurocytoma cells to the brain parenchyma is due to the flow of CSF through the lateral ventricle during surgical intervention.

Although the exact mechanism of CN recurrences through the operative route is unknown, surgeons should sterilize the operative field carefully, changing surgical tools frequently. In addition, neurosurgeons should remove tumor fragments completely prior to closure with the goal of preventing this rare recurrence along the trajectory. The recurrent CN always spreads through the CSF with Ki-67 index elevation. Our case exhibited an atypical CN (either with a

mitotic index of  $\geq 3/10$  high-power fields or MIB-1  $> 2\%$ ) with Ki-67 index elevation. In addition, safe maximal resection is considered to be the optimal therapeutic option, with the best long-term prognosis and survival. Adjuvant radiotherapy is suitable for patients with incomplete resection or an atypical neurocytoma [3]. Moreover, a recurrent neurocytoma can be very aggressive, and radiotherapy should be applied immediately after operation in such cases [8]. As such, in order to prevent CN recurrence, it is important to monitor these patients closely and carefully. On the other hand, it is also possible that in our case, a CN and an EVN occurred simultaneously in different locations of the brain. Though, to date, no cases of multiple neurocytomas have been reported.

Our case report provides further evidence of CN recurrence and the first evidence that CN recurrence can occur in the brain parenchyma. This information will be helpful for the diagnosis and management of CN.

## Acknowledgements

The authors thank all the other staff of the neurosurgery department of the First Hospital of China Medical University for their support.

## Disclosure of conflict of interest

None.

**Address correspondence to:** Zongze Guo, Department of Neurosurgery, 1st Hospital of China Medical University, No. 92 Beier Road, Heping District, Shenyang 110001, Liaoning, People's Republic of China. Tel: +8613940059988; E-mail: 15841439542@163.com

## References

- [1] Hassoun J, Gambarelli D, Grisoli F, Pellet W, Salamon G, Pellissier JF and Toga M. Central neurocytoma. An electron-microscopic study of two cases. *Acta Neuropathol* 1982; 56: 151-156.
- [2] Kaur G, Kane AJ, Sughrue ME, Oh M, Safaee M, Sun M, Tihan T, McDermott MW, Berger MS and Parsa AT. MIB-1 labeling index predicts recurrence in intraventricular central neurocytomas. *J Clin Neurosci* 2013; 20: 89-93.
- [3] Sharma MC, Deb P, Sharma S and Sarkar C. Neurocytoma: a comprehensive review. *Neurosurg Rev* 2006; 29: 270-285; discussion 285.
- [4] Louis DN, Ohgaki H, Wiestler OD, Cavenee WK, Burger PC, Jouvet A, Scheithauer BW and Kleihues P. The 2007 WHO classification of tumours of the central nervous system. *Acta Neuropathol* 2007; 114: 97-109.
- [5] Mozes P, Szanto E, Tiszlavicz L, Barzo P, Cserhati A, Fodor E and Hideghety K. Clinical Course of Central Neurocytoma with Malignant Transformation-An Indication for Craniospinal Irradiation. *Pathol Oncol Res* 2014; 20: 319-25.
- [6] Savitr Sastri BV, Arivazhagan A, Santosh V and Chandramouli BA. Distant extraventricular recurrence in central neurocytoma. *Neurol India* 2011; 59: 926-927.
- [7] Salunke P, Bhardwaj LK, Gupta K and Das K. Ectopic recurrence of craniopharyngioma along the surgical tract. *Neurol India* 2011; 59: 137-139.
- [8] Leenstra JL, Rodriguez FJ, Frechette CM, Giannini C, Stafford SL, Pollock BE, Schild SE, Scheithauer BW, Jenkins RB, Buckner JC and Brown PD. Central neurocytoma: management recommendations based on a 35-year experience. *Int J Radiat Oncol Biol Phys* 2007; 67: 1145-1154.