

## Case Report

# Treatment of nasopharyngeal carcinoma with multiple liver metastases: a case experience of sustained complete response

Jianfang Wang<sup>1</sup>, Chaoyang Xu<sup>2</sup>

<sup>1</sup>Department of Radiotherapy, Shaoxing People's Hospital, Shaoxing Hospital of Zhejiang University, Shaoxing, China; <sup>2</sup>Department of Breast and Thyroid Surgery, Shaoxing People's Hospital, Shaoxing Hospital of Zhejiang University, Zhejiang, China

Received September 22, 2015; Accepted December 6, 2015; Epub February 15, 2016; Published February 29, 2016

**Abstract:** Nasopharyngeal carcinoma (NPC) with distant metastases has poor prognosis. Metastatic sites are usually multifocal and involve bones, lungs and liver. Management of metastatic disease is essentially palliative and is based on chemoradiotherapy. A 48-year-old man with a solitary liver metastasis from a newly diagnosed NPC was treated by segmentectomy. Prior to radiotherapy, neoadjuvant chemotherapy and erbitux followed by concurrent chemoradiotherapy was administered. The liver metastatic site was resection by transcatheter arterial chemoembolization (TACE). Complete remission of the primary disease was achieved, although the size of the hepatic lesion was increased. After resection of the liver metastasis lesion, no sign of local or distant recurrence was noted during the 6-month follow up. NPC with a liver metastasis responds at neoadjuvant or concurrent chemotherapy. Since we excluded extrahepatic lesions and disease was completely locoregionally controlled, the decision to surgically remove the hepatic lesion was justified with a reasonable outcome.

**Keywords:** Metastases, complete response, prognosis

## Introduction

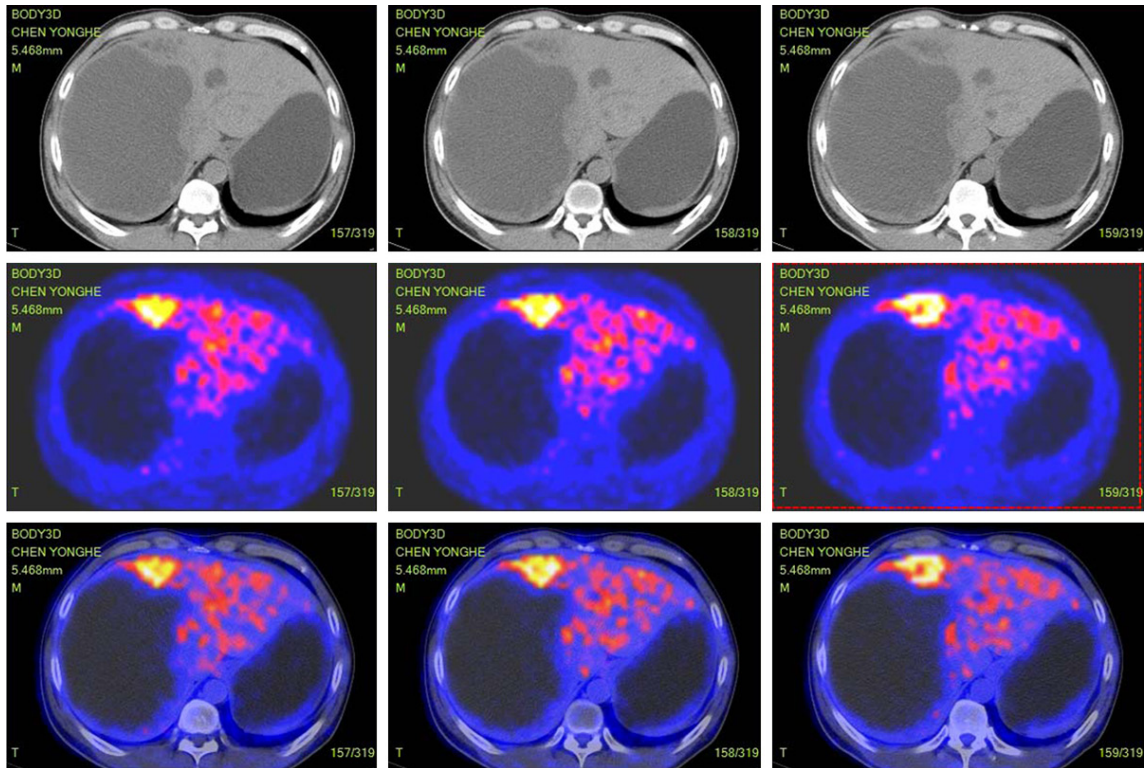
Nasopharyngeal carcinoma (NPC) is a squamous cell carcinoma arising from the epithelium of the NPC [1]. Most cases are reported from Southeast Asia, where the incidence of the disease is 20-30 per 100,000, while in Western countries it is less than one per 100,000 [2, 3]. We report a case of NPC with larger liver metastases that was successfully treated with radiotherapy and chemotherapy to the primary site. Informed consent was obtained from the patient.

## Case report

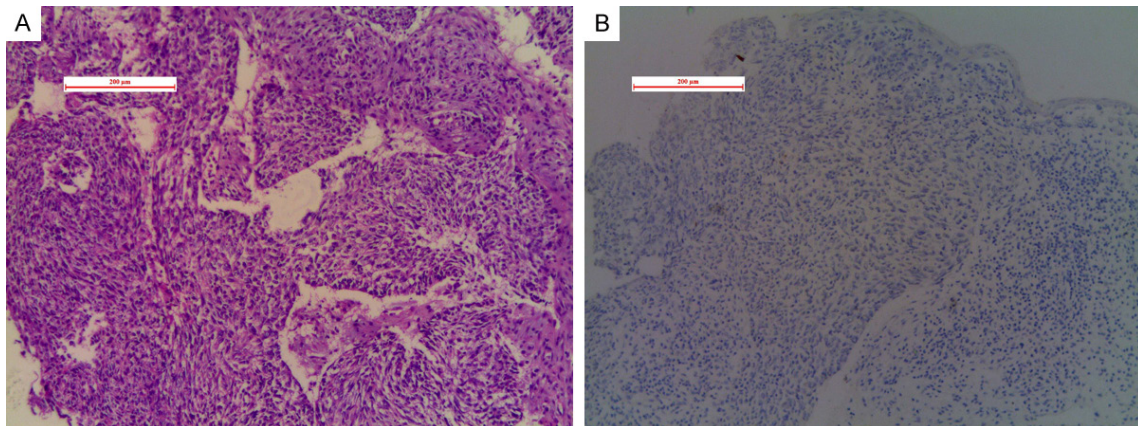
A 48-year-old man presented with a 1-year history of ear pus, nasal congestion, runny nose, and tears in the blood. Magnetic resonance imaging (MRI) showed nasopharyngeal tumor and bilateral enlargement of cervical lymph nodes. Abdominal B ultrasound showed multiple liver cystic mass lesions. Positron Emission

Tomography-computed tomography (PET-CT) showed NPC with multiple intrahepatic metastatic cancers (**Figure 1**). On nasopharyngoscopy, a fungating mass was found in his nasopharynx and was biopsied. Histopathological examination revealed a non-keratinizing carcinoma of the nasopharynx (**Figure 2**). The chromogenic in situ hybridization (CISH) examination showed EBER was positive expression (**Figure 3**). As depicted in **Figure 3**, CK, CK8/18, P63 and Ki-67 were positive expression. CD3, CD45, CD20, CD79a and EMA were negative expression. Genomic DNA was extracted and mutations of KRAS gene were detected by scorpions amplification refractory mutation system (Scorpions ARMS), and the result showed that the KRAS were wild-type in this patient (**Figure 4**). According to the American Joint Committee on Cancer Staging it was a Stage IVb (T4N2M1) nasopharyngeal carcinoma. The patient underwent neoadjuvant chemotherapy with taxol, cisplatin and targeted therapy with erbitux every three weeks for two cycles. By the end of che-

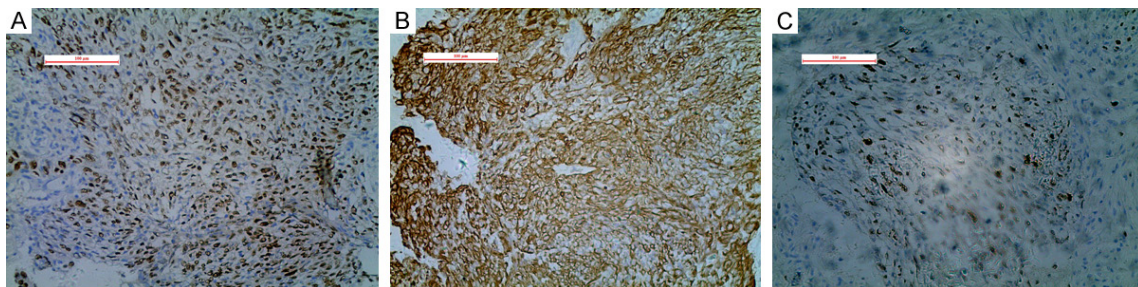
## Treatment of nasopharyngeal carcinoma with multiple liver metastases



**Figure 1.** PET-CT showed nasopharyngeal carcinoma with multiple intrahepatic metastatic cancers.

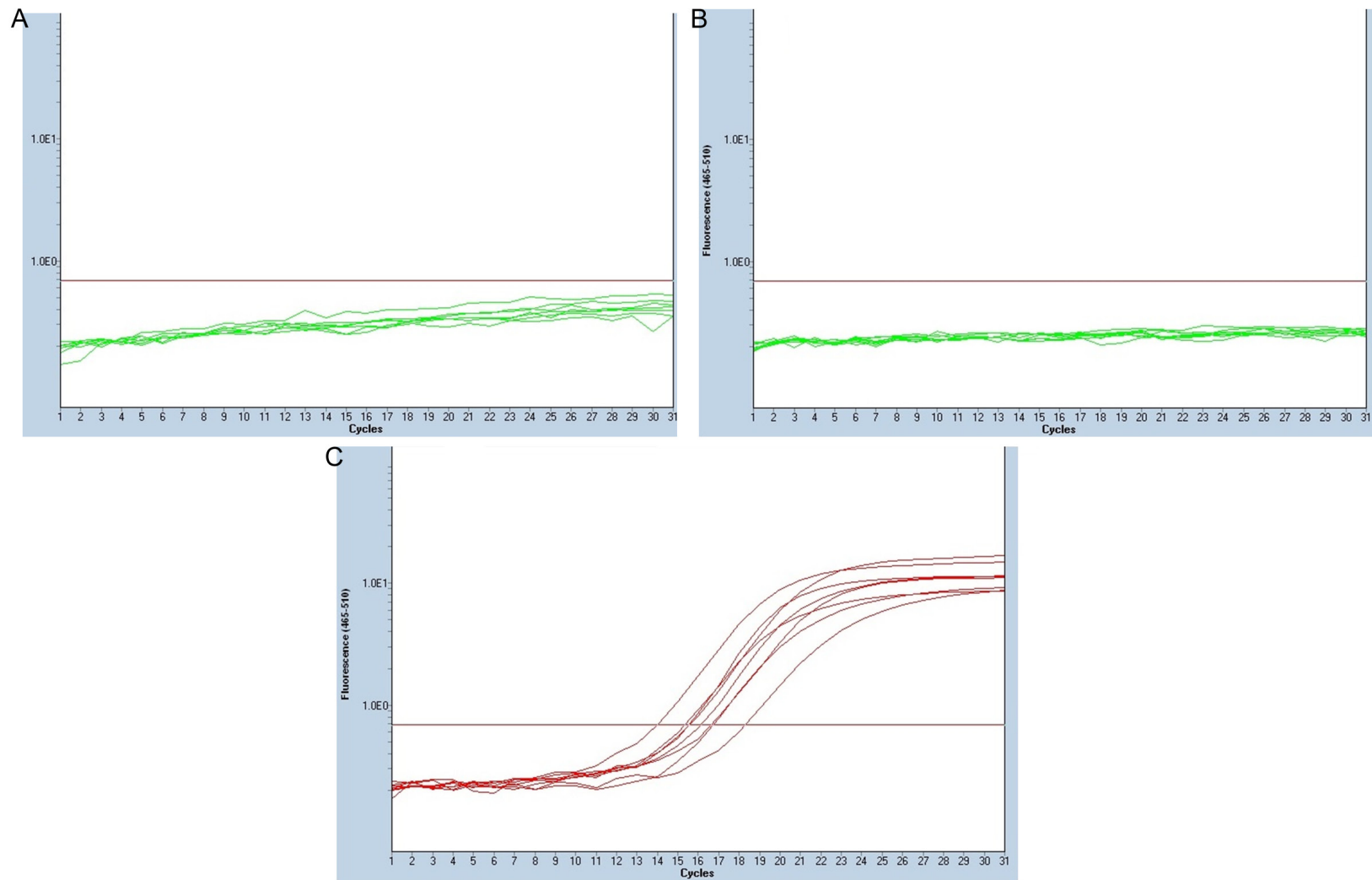


**Figure 2.** A. Histopathological examination revealed a non-keratinizing carcinoma of the nasopharynx (HE $\times$ 100); B. The chromogenic in situ hybridization (CISH) examination showed EBER was positive expression (HE $\times$ 100).

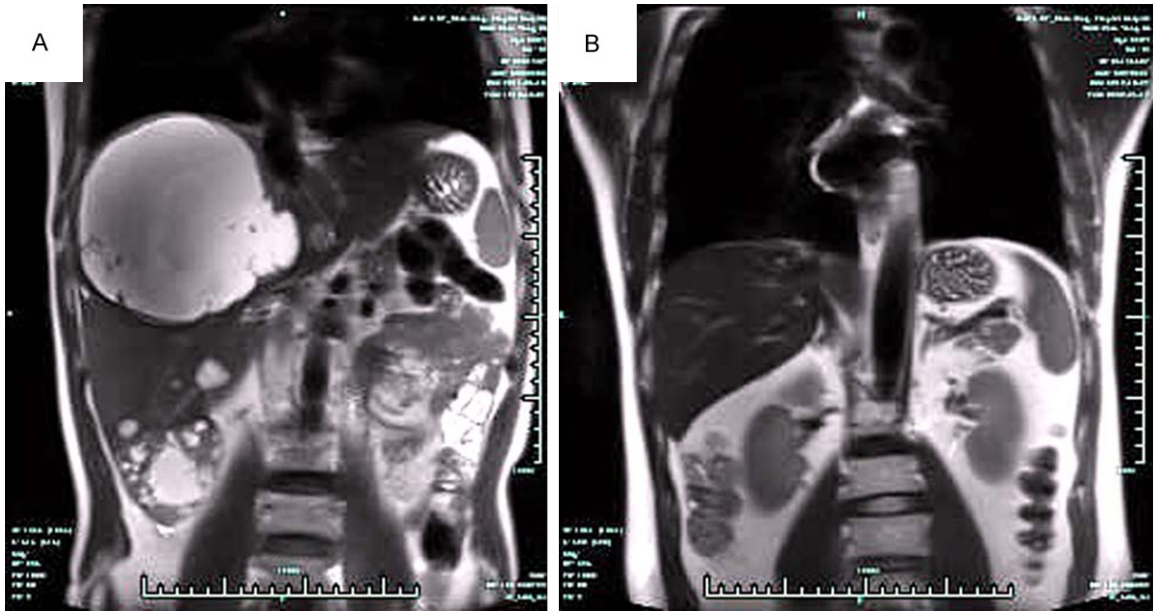


**Figure 3.** A. Immunohistochemical examinations showed that P63 was positive expression (HE $\times$ 100); B. Immunohistochemical examinations showed that CK was positive expression (HE $\times$ 100); C. Immunohistochemical examinations showed that Ki-67 was positive expression (HE $\times$ 100).

## Treatment of nasopharyngeal carcinoma with multiple liver metastases



**Figure 4.** Genomic DNA was extracted and mutations of KRAS gene were detected by scorpions amplification refractory mutation system (Scorpions ARMS). A. KRAS was negative expression; B. Negative control; C. Positive control.



**Figure 5.** A. Before the treatment of TACE, liver metastatic site was showed; B. After the treatment of Gamma knife, liver metastatic site was complete remission.

motherapy, the diameter of cervical lymph nodes and hepatic lesion reduced significantly along with a remarkable reduction of the nasopharyngeal mass. Concurrent radiotherapy was the next step of treatment. During a two-month period, a total dose of 68 Gy was delivered to the primary tumor and 50 Gy to the neck lymph nodes, while concurrently an erbitux every week. In the subsequent 5 months of follow-up, no evidence of other organs metastatic was documented and transcatheter arterial chemoembolization (TACE, DDP70 mg, FUDR1000 mg, THP40 mg, iodized oil 4 ml) resection of the liver metastatic site was decided. By the end of TACE, liver metastatic site was complete remission except right hepatic lobe. Adjuvant chemotherapy (Nedaplatin and Taxol) and erbitux was administered after TACE resection of the metastatic site. The metastatic site of right hepatic lobe was resection by Gamma knife and 2 years later the patient remains with no evidence of local or distant recurrence of the disease (Figure 5).

#### Discussion

Liver is one of nasopharyngeal carcinoma the main sites of metastases, the median survival time was 5 months, which is the leading cause of death in patients [4]. Autopsy data show that

a considerable number of NPC patients died of liver metastases. Combined chemotherapy is the standard treatment for metastatic nasopharyngeal carcinoma and is usually palliative. In this case, the neoadjuvant treatment with the targeted drugs erbitux and chemotherapy taxol and cisplatin was shown, and the diameter of nasopharyngeal mass and hepatic lesion was partial remission.

TACE is an effective and potentially curative procedure for patients with liver metastases from colorectal malignancies, with a five-year survival rate of 30%-51%, according to various studies [5]. However, the role of TACE for the treatment of metastatic disease originating from other primaries, like nasopharynx, is not well established. There are very few studies define long-term outcome in patients undergoing TACE for treatment of liver metastases from NPC carcinomas. The Memorial Sloan-Kettering group has reported two cases of liver resection for metastases from NPC carcinoma with long-term outcome [6]. Similar results were reported by Elias and associates in five patients with head and neck tumors who had undergone liver resection [7]. In accordance with these rare reports, we present a single case of liver resection for NPC primary with reasonable outcome although the follow-up is limited.

## Treatment of nasopharyngeal carcinoma with multiple liver metastases

In conclusion, our patient had a liver metastasis from NPC at the time of diagnosis, which responds at concurrent chemotherapy. Since we excluded extrahepatic lesions and disease was completely locoregionally controlled, the decision to surgically remove the hepatic lesion was justified with a reasonable outcome.

### Acknowledgements

This study was supported by grants from the National Natural Science Foundation of China (grant No. 81341135), Natural Science Foundation of Zhejiang Province (grant No. Q13H-160045), Science and Health Care Foundation of Zhejiang Province (grant No. 2013KYA204, 2014KYB279), and Shaoxing nonprofit technology applied research projects of China (grant No. 2012B70055 and 2013B7082).

### Disclosure of conflict of interest

None.

### Authors' contribution

Jiangfang Wang obtained medical history, searched and reviewed the literature, drafted the manuscript, and edited the final version. Chaoyang Xu obtained patient follow-up information, carried out the histopathological studies, and edited the final version.

**Address correspondence to:** Dr. Chaoyang Xu, Department of Breast and Thyroid Surgery, Shaoxing People's Hospital, Shaoxing Hospital of Zhejiang University, Shaoxing, Zhejiang, China. Tel: +86-575-88229168; Fax: +86-575-86228888; E-mail: xu-chaoayang2001@126.com

### References

- [1] Chee Ee Phua V, Loo WH, Yusof MM, Wan Ishak WZ, Tho LM, Ung NM. Treatment Outcome for Nasopharyngeal Carcinoma in University Malaya Medical Centre from 2004-2008. *Asian Pac J Cancer Prev* 2013; 14: 4567-4570.
- [2] Liu X, Luo HN, Tian WD, Lu J, Li G, Wang L, Zhang B, Liang BJ, Peng XH, Lin SX, Peng Y, Li XP. Diagnostic and prognostic value of plasma microRNA deregulation in nasopharyngeal carcinoma. *Cancer Biol Ther* 2013; 14: 1133-1142.
- [3] Robinson M, Suh YE, Paleri V, Devlin D, Ayaz B, Pertl L, Thavaraj S. Oncogenic human papillomavirus-associated nasopharyngeal carcinoma: an observational study of correlation with ethnicity, histological subtype and outcome in a UK population. *Infect Agent Cancer* 2013; 8: 30.
- [4] Li X, Fan WJ, Zhang L, Zhang XP, Jiang H, Zhang JL, Zhang H. CT-guided percutaneous microwave ablation of liver metastases from nasopharyngeal carcinoma. *J Vasc Interv Radiol* 2013; 24: 680-684.
- [5] Pan CC, Lu J, Yu JR, Chen P, Li W, Huang ZL, Zhao M, Huang ZM, Xia YF, Wu YH, Wu PH. Challenges in the modification of the M1 stage of the TNM staging system for nasopharyngeal carcinoma: A study of 1027 cases and review of the literature. *Exp Ther Med* 2012; 4: 334-338.
- [6] Weitz J, Blumgart LH, Fong Y, Jarnagin WR, D'Angelica M, Harrison LE, DeMatteo RP. Partial hepatectomy for metastases from noncolorectal, nonneuroendocrine carcinoma. *Ann Surg* 2005; 241: 269-276.
- [7] Elias D, Cavalcanti de Albuquerque A, Eggenspieler P, Plaud B, Ducreux M, Spielmann M, Theodore C, Bonvalot S, Lasser P. Resection of liver metastases from a non colorectal primary: indications and results based on 147 monocentric patients. *J Am Coll Surg* 1998; 187: 493.