

## Original Article

# Clinical characteristics of cerebral infarction in the perioperative period of colorectal cancer excision

Bin Ye<sup>1</sup>, Li Chen<sup>1</sup>, Jin-Sheng Zeng<sup>2</sup>, Chao Qin<sup>1</sup>, Zhi-Jian Liang<sup>1</sup>, Su-Dan Zeng<sup>1</sup>, Li-Xia Yu<sup>1</sup>

<sup>1</sup>Department of Neurology, The First Affiliated Hospital of Guangxi Medical University, Nanning 530021, Guangxi Province, P. R. China; <sup>2</sup>Department of Neurology, The First Affiliated Hospital of Sun Yat-sen University, Guangzhou 510080, Guangdong Province, P. R. China

Received October 9, 2015; Accepted December 31, 2015; Epub February 15, 2016; Published February 29, 2016

**Abstract:** Objective: This study aimed to investigate clinical characteristics as well as potential pathogenesis of cerebral infarction in the perioperative period of colorectal cancer excision. Methods: Retrospective analysis was performed using the clinical data of 11 cases with perioperative cerebral infarction, screened out from 4,879 patients that received colorectal cancer excision. Results: A total of 4,879 patients that received colorectal cancer excision were included in the screening, and 11 (0.22%) were found to have developed perioperative cerebral infarction. Among the 11 cases, 5 presented (while the other 6 did not) histories of conventional stroke risk factors such as hypertension, diabetes, hyperlipidemia, brain stroke etc. Pathologic findings confirmed well-differentiated adenocarcinoma in screened-out patients (5 with colon cancer, and 6 with rectal cancer). Cerebral infarction was observed in 2, 3, 2 and 4 cases on day 1, 2, 3 and 4-6 after surgery, respectively. Single intracranial high-intensity infarction signal was confirmed in 4 cases (36.36%), while multiple high-intensity signals from areas with various blood supplies in 7 cases (63.64%). Increased levels of carcino-embryonic antigen (CEA), CA19-9, CA125 and D-dimer were observed in 6, 4, 7 and 8 cases, respectively. Conclusion: Cerebral infarction in the perioperative period of colorectal cancer excision usually appears in patients within 3 days after surgery, mostly with abnormal levels of serum tumor markers, while some with multiple infarction signals from intracranial areas had overlapped blood supplies. The pathogenesis may be related to hypercoagulability.

**Keywords:** Colorectal cancer, cerebral infarction, perioperative period, clinical characteristics

## Introduction

Somatic malignant tumor may be the direct cause of vascular oppression and infiltration, hypercoagulability, non-bacterial thrombotic endocarditis (NBTE) etc., which brings about cerebral infarction in patients with cancer [1-3]. The risk of cerebral infarction is dramatically elevated in such patients [4-6]. And malignant tumor-targeted treatments including surgery, chemotherapy, radiotherapy etc. will also affect the incidence of cerebral infarction. Colorectal cancer is a common type of malignant tumor, and its incidence is gradually increasing along with the changes in economic development, lifestyle, eating patterns and dietary structure [7]. Surgical excision is presently one of the major treatments for colorectal cancer. Therefore, cerebral infarction may probably appear with an increasing incidence due to the

perioperative stress-related blood pressure fluctuation, changed coagulative state etc. [8]. Cerebral infarction is a rare but severe perioperative neurological complication, with a reported incidence varying between 0.08% and 2.90% [9]. However, so far there have been few researches on the pathogenesis and clinical characteristics of perioperative cerebral infarction in patients with colorectal cancer.

In this retrospective study, 11 patients with perioperative cerebral infarction were screened out from those that underwent colorectal cancer excision during hospitalization in the First Affiliated Hospital of Guangxi Medical University between January 2006 and January 2015. Clinical data of selected patients were analyzed to explore clinical characteristics as well as potential pathogenesis of perioperative cerebral infarction in those with colorectal cancer.

## Subjects and methods

### Subjects

Patients with perioperative cerebral infarction were screened out from those that received surgical excision for colorectal cancer during hospitalization in the Frist Affiliated Hospital of Guangxi Medical University from January 2006 to January 2015. The inclusion criteria included localized symptoms of neurological deficit such as limb asthenia, numbness, hypaesthesia and dysarthria etc., which could be explained by the fresh infarction foci revealed by intracranial CT and MRI scanning and DWI (diffusion-weighted imaging) sequence scan, as was verified by MRI scanning 21 days later. The exclusion criteria consisted of non-perioperative cerebral infarction in patients with colorectal cancer; patients with colorectal cancer complicated by other malignant tumors, or with brain metastasis; hematological diseases; cerebral hemorrhage and shortage of reliable encephalic imaging data. The diagnostic criteria for colorectal cancer and acute cerebral infarction were as per the National Comprehensive Cancer Network (NCCN) guideline [10] and the American College of Cardiology (ACC) newly-updated standard [11], respectively. The definition of perioperative period was in accordance with what Leemingsawat et al. [8] had described, that's from the day of the surgery to the seventh day thereafter. Case inclusion was jointly decided by a neurologist blinded to this study and a specialist of gastrointestinal surgery.

### Methods

The study had collected demographic data such as gender, age etc., as well as histories of conventional stroke risk factors such as hypertension, diabetes, hyperlipidemia, atrial fibrillation, myocardial infarction, smoking and alcohol abuse, pulmonary or limb embolism, brain stroke etc. Neurological scoring was performed using the National Institutes of Health Stroke Scale (NIHSS) as per collected data such as symptoms and signs at the onset of the stroke. Thirty-day prognosis was evaluated using the modified Rankin Scale (mRS) in order to avoid the influence of colorectal cancer development on limb function. And unfavorable prognosis was suggested if mRS  $\geq 2$  points. Patient information collection was comprised of the site of the colorectal cancer, type of the tumor cells,

metastasis, blood pressure fluctuation during surgery, surgical blood loss, anesthetic method and the onset time of cerebral infarction within or after the surgery. Pre-operational examinations included hematological tests such as routine blood test, biochemical examination, examination of four coagulation indices (PT, APTT, TT and FIB), D-dimer, tumor markers etc., as well as other tests such as electrocardiogram, ultrasonic cardiogram (UCG), B-mode ultrasound (BUS) scan of the neck and the abdomen, transcranial Doppler (TCD) imaging, chest X-ray scanning, abdominal and pelvic CT and MRI scanning (both unenhanced and enhanced), colonoscopy etc. Examinations after cerebral infarction included cranial CT and MRI scanning as well as DWI sequence scanning etc.

## Results

### Results on colorectal cancer

The study included a total of 4,879 patients who underwent colorectal cancer excision during hospitalization. And perioperative cerebral infarction was spotted in 11 patients (0.22%). One patient had family history of rectal cancer. All patients first complained of bloody stool, abdominal pain and distention, which were then hospitalized for surgery when tumor-like neoplasm was discovered via digital rectal examination and colonoscopy. Post-operative pathologic findings all suggested tubular adenocarcinoma, with 5 patients determined as colon cancer while 6 as rectal cancer. Hepatic metastasis was found in 3 patients, while metastasis was absent in other patients revealed by cranial CT and MRI scanning, enhanced CT scanning on chest and abdomen, and whole-body PET/CT. Radical resection was applied in 8 patients, and extended radical operation in 3. General anesthesia was adopted for all the 11 patients. Parametric levels of blood pressure fluctuation, blood loss and serum tumor markers are listed in **Table 1**.

### Results on cerebral infarction

Five patients presented histories of stroke risk factors such as hypertension, diabetes, smoking and alcohol abuse, brain stroke etc. CTA/MRA examination suggested narrowed A1 segment of the right anterior cerebral artery in 1 patient. Scleroses of bilateral intracranial ver-

## Clinical characteristics of colorectal cancer surgery

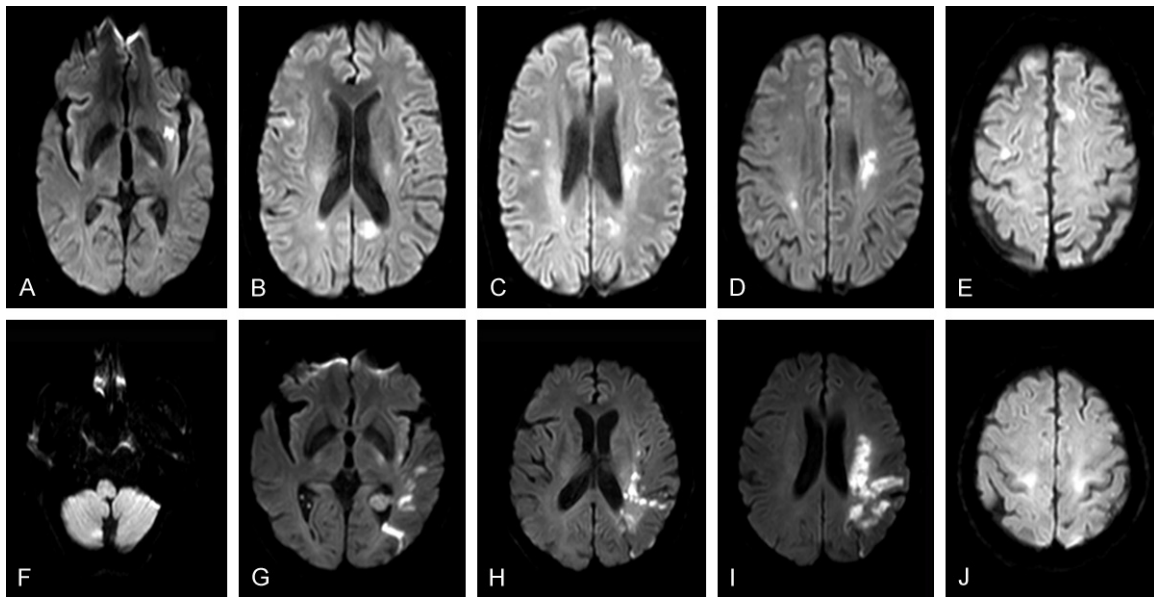
**Table 1.** Results of 11 patients with colorectal cancer

Serial number	Gender	Age	Type of tumor cells	Cancer diagnosis	Duration of hypotension in surgery > 1 h	Blood loss in surgery > 1000 ml	Stage of the tumor	CEA (ng/ml)	CA19-9 (U/ml)	CA125 (U/ml)	D-dimer (ng/ml)
1	Male	55	Stage 1-2 tubular adenocarcinoma	Right hemicolon cancer	+	+	T2N0M0	> 1500	186.90	185.70	1091
2	Male	71	Stage 2 tubular adenocarcinoma	Rectal cancer with hepatic metastasis			T3N1M1	2.95	2.65	32.13	420
3	Female	47	Stage 2 tubular adenocarcinoma	Ascending colon cancer with hepatic metastasis	+		T2N0M0	4.68	5.60	131.60	890
4	Male	65	Stage 2 tubular adenocarcinoma	Sigmoid colon cancer		+	T3N0M0	25.41	482.10	101.90	3734
5	Male	70	Stage 2 tubular adenocarcinoma	Rectal cancer			T2N1M0	13.53	18.39	7.60	230
6	Female	56	Stage 2 tubular adenocarcinoma	Rectal cancer	+		T2N0M0	7.37	56.10	349.60	2347
7	Male	49	Stage 2 tubular adenocarcinoma	Rectal cancer with hepatic metastasis			T3N1M1	0.64	5.30	14.50	460
8	Female	53	Stage 2 tubular adenocarcinoma	Rectal cancer			T3N0M0	12.50	22.00	191.40	1297
9	Male	60	Stage 2 tubular adenocarcinoma	Sigmoid colon cancer	+		T2N0M0	6.79	25.12	87.13	1100
10	Male	55	Stage 1-2 tubular adenocarcinoma	Rectal cancer		+	T3N0M0	1.20	17.80	10.90	260
11	Female	60	Stage 2 tubular adenocarcinoma	Ascending colon cancer			T2N0M0	0.89	78.60	105.70	790

+: The described condition exists.

**Table 2.** Results of 11 patients with cerebral infarction

Serial number	Gender	Age	Stroke risk factor	Site and number of cerebral infarction	Head-and-neck CTA & MRA	Onset time of cerebral infarction	NIHSS score	mRS score 30 d after infarction
1	Male	55	None	Multiple lesions in the left frontal, temporal, parietal and occipital lobes, as well as the head of caudate nucleus on the right side	Narrowed A1 segment of the right anterior cerebral artery	1	7	1
2	Male	71	Histories of brain stroke and hypertension	Multiple lesions in bilateral areas of corona radiata, basal ganglia and thalamus	Bilateral scleroses of intracranial vertebral artery	2	9	2
3	Female	47	None	One lesion in the right pons area	No abnormality	6	5	0
4	Male	65	Histories of brain stroke and hypertension	Multiple lesions in the right frontal and parietal lobes, as well as the right basal ganglia area	No abnormality	3	5	6
5	Male	70	Histories of hypertension, smoking and alcohol abuse	Multiple lesions in the right cerebellar hemisphere, bilateral basal ganglia areas, left thalamus and pons	No abnormality	1	11	6
6	Female	56	None	Multiple lesions in the right temporal and occipital lobes, as well as the right thalamus	No abnormality	4	17	2
7	Male	49	None	Multiple lesions in the right cerebellum; left temporal, occipital and parietal lobes; left corona radiata and right frontal lobe	No abnormality	6	21	0
8	Female	53	None	Multiple lesions in bilateral frontal lobes, corona radiata, splenium of the left corpus callosum, and the basal ganglia area	No abnormality	2	3	6
9	Male	60	Diabetes	One lesion in the right basal ganglia area	No abnormality	3	11	0
10	Male	55	None	One lesion in the left temporal lobe	No abnormality	5	9	3
11	Female	60	Histories of brain stroke and hypertension	One lesion in the left basal ganglia area	No abnormality	2	7	3



**Figure 1.** A-E. A 53-year-old female. Diffusion-weighted imaging: Multiple infarctions in supply areas of cerebral arteries. F-J. A 49-year-old male. Diffusion-weighted imaging: Multiple infarctions in supply areas of cerebral arteries.

tebral arteries were also discovered in 1 patient. While no vascular or cardiac abnormalities were spotted in other patients via cranial CTA/MRA, UCG, TCD and neck BUS scanning. All patients presented acute neurological deficit symptoms to varying degrees, such as limb asthenia, numbness and dysarthria etc. And somnolence and obnubilation etc. were found in 3 patients. Cerebral infarction was observed in 2, 3, 2 and 4 cases on day 1, 2, 3 and 4-6 after surgery, respectively. Cerebral hemorrhage was excluded via cranial CT and MRI scanning as well as DWI sequence scanning. Cerebral infarction was confirmed by T1, T2 and DWI high-intensity signals. All patients received another round of MRI (both unenhanced and enhanced) and DWI sequence scanning 21 days later, to verify cerebral infarction and rule out brain tumor or metastasis. Single intracranial high-intensity infarction signal was confirmed in 4 patients (36.36%), while multiple high-intensity signals from areas with various blood supplies in 7 (63.64%) **Figure 1**. Neurological scoring was performed using the National Institutes of Health Stroke Scale (NIHSS). Thirty-day prognosis after stroke was evaluated using the modified Rankin Scale (mRS), and results had shown 4 cases with favorable prognosis (mRS = 0-1 point), 4 with unfavorable prognosis (mRS = 2-5 points), and 3 deaths (mRS = 6 points) (**Table 2**).

#### *Treatment and outcome*

General nutritional support was provided and fasting required for all patients before surgery. Appropriate fluid infusion, blood transfusion and hemostatic treatment were adopted for patients suffering from blood pressure fluctuation and hemorrhage in surgery. Targeted treatments after stroke included dehydration therapy to reduce intracranial pressure, brain cell nourishment and neural rehabilitation, etc. No patient received intravenous thrombolysis or anti-platelet therapy. One out of the 3 deaths was caused by cerebral infarction, the other 2 by multiple organ failure (MOF).

#### **Discussion**

Malignant tumor will lead to increased risk of cerebral infarction, which suggests a correlation between cerebral infarction and malignant tumor [4-6]. A few researches have unraveled explicit characteristics of partial cerebral infarction patients with cancer. In the study carried out by Kim et al. [12] in 2012, 348 from 2,562 patients with acute cerebral infarction included along the continuum were screened out as complicated by active cancer. Seventy-one in those 348 patients (20.40%) presented increased D-dimer levels and multiple infarctions from intracranial areas with various arterial supplies, but no conventional stroke risk

factors. Also, similar reports on cancer complicated by cerebral infarction are gradually increasing [13, 14]. Most patients in our study did not have conventional stroke risk factors, but had increased CEA, CA19-9, CA125 and D-dimer levels in peripheral circulation, as well as multiple infarctions from intracranial areas with various arterial supplies for a single onset. Such findings are consistent with prior researches, suggesting that there exist characteristics specifically related to colorectal cancer complicated by cerebral infarction.

Cerebral infarction is a rare but severe perioperative neurological complication, which usually takes place on the day of the surgery or 7 days thereafter [15]. A study carried out in the US targeting perioperative cerebral infarction of non-cardiac and non-vascular surgeries includes 130,000 patients and lasts for 18 years [16]. According to its results, conventional stroke risk factors such as hypertension, hyperlipidemia, smoking, alcohol abuse and obesity etc. are also risk factors of perioperative cerebral infarction. The incidence to develop perioperative cerebral infarctions increases to more than twice if the patients have brain stroke history. And the incidence of brain stroke has been raised by 25% in diabetic patients. Among patients included in our study, 3 had history of brain stroke, and 5 had other risk factors such as hypertension, diabetes, smoking and alcohol abuse etc. And the pathogenesis of brain stroke in these patients might be probably the same as that of non-perioperative cerebral infarction. Multiple infarctions from intracranial areas with various blood supplies were observed in 6 patients without stroke risk factors, and the pathogenesis of such infarctions was worth studying.

Malignant tumor may be the direct cause for vascular oppression and infiltration, hypercoagulability, NBTE etc., which brings about cerebral infarction in patients with cancer [1-3]. And hypercoagulable state is already confirmed as one important pathogenesis for complicated cerebral infarction in patients with malignant tumor [17]. The study by Jovin et al. [18] has shown increased level of serum CA125 and hypercoagulability in patients with malignant tumor complicated by cerebral infarction, indicating that the mucoprotein characteristics of CA125 may be related to hypercoagulability,

and thus participate in the genesis of cerebral infarction in patients with malignant tumor. Hypotension is also considered as one of the major causes of perioperative cerebral infarction. The stress state that perioperative patients are going through is relevant to factors such as persistent hypotension and hypercoagulable state etc., which may contribute to the incidence of cerebral infarction [8, 19]. It was found in our study that partial patients had hypotension and increased serum CEA, CA19-9, CA125 and D-dimer levels, all of which were potential factors participating in the development of perioperative cerebral infarction in patients with colorectal cancer.

No patient received intravenous thrombolysis or anti-platelet therapy in our study. One out of the 3 deaths was caused by cerebral infarction and the other 2 by multiple organ failure (MOF). Although ultra-early thrombolytic therapy is viewed as a very effective approach to treat cerebral infarction, recent surgical history within three months is still a contraindication. Therefore the fatality and disability rates of perioperative cerebral infarction are increased due to the limited treatment. As revealed by the study of Chalela et al. [20] who treat 36 cases of ultra-early cerebral infarction via arterial injection of recombinant tissue-type plasminogen activator (rt-PA), partial or complete recanalization of occluded vessels is achieved by arterial thrombolysis in 80% of the patients with perioperative cerebral infarction. No or merely mild neurological deficit symptoms are present in 38% of the patients. The mortality is similar to that of arterial thrombolysis in patients with non-perioperative cerebral infarction. The incision bleeding rate is 17%, with only slight blood loss (< 30 mL) in most patients. The incidence of intracranial hemorrhage increases to about 25% of the patients, but only 8% with aggravated symptoms. Mortazavi et al. [21] have performed arterial thrombolysis on 3 arthroplastic patients with perioperative cerebral infarction, and succeeded in restoring blood flow through the occluded vessels. Two of the 3 patients are discharged from the hospital without any disability, and 1 dies from hemorrhagic complication. The detailed clinical efficacy remains to be observed as a result of the limited number of cases, and the shortage of large-scale clinical trials. The treatment and prognosis of perioperative cerebral infarction in



patients that have undergone colorectal cancer excision are still yet to be further investigated.

The retrospective nature of the study, relatively smaller number of cases included, and clinical data collection limited by in-patient treatment requirements have altogether restricted more in-depth discussion on the pathogenesis of perioperative cerebral infarction in patients with colorectal cancer, which can be better elucidated through active large-scale prospective multicenter studies in the future.

## Acknowledgements

This work was supported by National Natural Science Foundation of China (NSFC NO. 30860088 and 81260186 to Z.L.) and Guangxi Natural Science Foundation (GNFC No. 0832134, 0991149 and 2015jjAA40737 to Z.L.).

## Disclosure of conflict of interest

None.

**Address correspondence to:** Zhi-Jian Liang, Department of Neurology, The First Affiliated Hospital of Guangxi Medical University, No. 6 Shuangyong Road, Nanning 530021, Guangxi Province, P. R. China. Tel: +86-0771-5352627; Fax: +86-0771-5352627; E-mail: liangzjiandr@163.com

## References

- [1] Devulapalli S, Pinto N, Gandotra C, Jayam-Trouth A and Kurukumbi M. A rare case of occipital stroke as a consequence of nonbacterial thrombotic endocarditis in ovarian clear cell carcinoma: a case report. *Case Rep Neurol* 2012; 4: 84-91.
- [2] Park HY, Lee HS, Chang H, Kim YS and Cho KH. Multifocal strokes as the initial manifestation of metastatic tumors. *Neurologist* 2010; 16: 322-324.
- [3] Stergiopoulos K, Vasu S, Bilfinger T and Poon M. Embolic stroke in a patient with metastatic renal cell cancer. *Hellenic J Cardiol* 2011; 52: 256-258.
- [4] Zöller B, Ji J, Sundquist J and Sundquist K. Risk of haemorrhagic and ischaemic stroke in patients with cancer: a nationwide follow-up study from Sweden. *Eur J Cancer* 2012; 48: 1875-1883.
- [5] Navi BB, Reiner AS, Kamel H, Iadecola C, Elkind MS, Panageas KS and DeAngelis LM. Association between incident cancer and subsequent stroke. *Ann Neurol* 2015; 77: 291-300.
- [6] Selvik HA, Thomassen L, Logallo N and Næss H. Prior cancer in patients with ischemic stroke: the Bergen NORSTROKE study. *J Stroke Cerebrovasc Dis* 2014; 23: 919-925.
- [7] Liu S, Zheng R, Zhang M, Zhang S, Sun X and Chen W. Incidence and mortality of colorectal cancer in China, 2011. *Chin J Cancer Res* 2015; 27: 22-28.
- [8] Leemingsawat P, Kongsayreepong S, Komoltri C, Prayoonwiwat N and Nilanont Y. Incidence and risk factors of perioperative stroke in Siriraj Hospital. *J Med Assoc Thai* 2012; 95: 1167-1172.
- [9] Limburg M, Wijdicks EF and Li H. Ischemic stroke after surgical procedures: clinical features, neuroimaging, and risk factors. *Neurology* 1998; 50: 895-901.
- [10] Levine RA, Chawla B, Bergeron S and Wasvary H. Multidisciplinary management of colorectal cancer enhances access to multimodal therapy and compliance with National Comprehensive Cancer Network (NCCN) guidelines. *Int J Colorectal Dis* 2012; 27: 1531-1538.
- [11] Jauch EC, Saver JL, Adams HP Jr, Bruno A, Connors JJ, Demaerschalk BM, Khatri P, McMullan PW Jr, Qureshi AI, Rosenfield K, Scott PA, Summers DR, Wang DZ, Wintermark M and Yonas H. Guidelines for the early management of patients with acute ischemic stroke: a guideline for healthcare professionals from the American Heart Association/American Stroke Association. *Stroke* 2013; 44: 870-947.
- [12] Kim SJ, Park JH, Lee MJ, Park YG, Ahn MJ and Bang OY. Clues to occult cancer in patients with ischemic stroke. *PLoS One* 2012; 7: e44959.
- [13] Lee EJ, Nah HW, Kwon JY, Kang DW, Kwon SU and Kim JS. Ischemic stroke in patients with cancer: is it different from usual strokes? *Int J Stroke* 2014; 9: 406-412.
- [14] Kim JM, Jung KH, Park KH, Lee ST, Chu K and Roh JK. Clinical manifestation of cancer related stroke: retrospective case-control study. *J Neurooncol* 2013; 111: 295-301.
- [15] Sharifpour M, Moore LE, Shanks AM, Didier TJ, Kheterpal S and Mashour GA. Incidence, predictors, and outcomes of perioperative stroke in noncarotid major vascular surgery. *Anesth Analg* 2013; 116: 424-434.
- [16] Bateman BT, Schumacher HC, Wang S, Shaefi S and Berman MF. Perioperative acute ischemic stroke in noncardiac and nonvascular surgery: incidence, risk factors, and outcomes. *Anesthesiology* 2009; 110: 231-238.
- [17] Schwarzbach CJ, Schaefer A, Ebert A, Held V, Bolognese M, Kablau M, Hennerici MG and Fatar M. Stroke and cancer: the importance of cancer-associated hypercoagulation as a pos-

- sible stroke etiology. *Stroke* 2012; 43: 3029-3034.
- [18] Jovin TG, Boosupalli V, Zivkovic SA, Wechsler LR and Gebel JM. High titers of CA-125 may be associated with recurrent ischemic strokes in patients with cancer. *Neurology* 2005; 64: 1944-1945.
- [19] Bijker JB, Persoon S, Peelen LM, Moons KG, Kalkman CJ, Kappelle LJ and van Klei WA. Intraoperative hypotension and perioperative ischemic stroke after general surgery: a nested case-control study. *Anesthesiology* 2012; 116: 658-664.
- [20] Chalela JA, Katzan I, Liebeskind DS, Rasmussen P, Zaidat O, Suarez JJ, Chiu D, Klucznick RP, Jauch E, Cucchiara BL, Saver J and Kasner SE. Safety of intra-arterial thrombolysis in the postoperative period. *Stroke* 2001; 32: 1365-1369.
- [21] Mortazavi SM, Kakli H, Bican O, Moussouttas M, Parvizi J and Rothman RH. Perioperative stroke after total joint arthroplasty: prevalence, predictors, and outcome. *J Bone Joint Surg Am* 2010; 92: 2095-2101.