

Original Article

Posterior intervertebral pressing single segmental fixation treatment of thoracolumbar fracture dislocation

Jiangbo Zhong¹, Wei Zhang², Weiming Gong¹, Peng Wang¹, Hongliang Song¹, Bin Ning¹, Kai Zhao¹, Jianmin Sun³

¹Department of Spine, Jinan Central Hospital Affiliated to Shandong University, Jinan 250013, China; ²Department of Orthopedics, Shandong Provincial Hospital Affiliated to Shandong University, Jinan 250010, China; ³Department of Spine, Shandong Provincial Hospital Affiliated to Shandong University, Jinan 250010, China

Received October 10, 2015; Accepted December 25, 2015; Epub February 15, 2016; Published February 29, 2016

Abstract: Thoracolumbar fracture dislocation often appears bony structure damage in centrum, lamina, pedicle, and spines. This study investigated the clinical efficacy of screwing through injured vertebra, posterior intervertebral pressing, single segmental fixation and traditional across injured vertebra on treating thoracolumbar vertebral fracture dislocation. 19 patients with thoracolumbar vertebral fracture receiving single segmental pedicle screw fixation through injured vertebra (group A) and traditional short-segment pedicle screw fixation across injured vertebra (group B) for more than 12 months were retrospectively analyzed. Perioperative indicators were observed. Nerve function recovery, imaging changes, and complications were compared before surgery, one week after surgery, and the last follow-up. ASIA score at last follow-up in both groups increased significantly compared before surgery ($P < 0.05$), while no obvious different was observed between two groups ($P > 0.05$). Group A presented markedly better performance in operation time, intraoperative blood loss, incision length, and complications than group B ($P < 0.05$). Two groups both showed significantly improved imaging indicators after surgery ($P < 0.05$). During the last follow-up, injured vertebral leading edge height ratio was similar between two groups ($P > 0.05$). Group A was better in Cobb angle, dislocation rate, and injured spinal canal occupation rate than group B ($P < 0.05$). Both single segmental pedicle screw fixation through injured vertebra and traditional short-segment pedicle screw fixation across injured vertebra can recover the clinical function of thoracolumbar vertebral fracture dislocation, while the former showed better general efficacy than the latter.

Keywords: Thoracolumbar spine, fracture dislocation, pedicle screw, functional recovery, imaging

Introduction

Thoracolumbar fracture dislocation accounts for about 20% of spinal injury. It belongs to unstable type fracture damaging three columns at the same time [1]. Except bony structure damage in centrum, lamina, pedicle, and spines, thoracolumbar fracture dislocation often merges ligament, intervertebral disc and nerve tissue injury [2]. Currently, it is still controversy about surgical procedure. Anterior approach operation can rebuild well anterior support, but is difficult for restoration and obtain firmly fixation. Traditional posterior four pins across segmental restoration and fixation technology cannot satisfy fracture and dislocation vertebral reset, and may appear excessive distraction [3]. In recent years, most scholars

adopted three centroms six pins restoration and fixation including the injured vertebra and obtained satisfactory effect [4]. By using the calf specimens to simulate single segmental pedicle screw fixation through injured vertebra and traditional short-segment pedicle screw fixation across injured vertebra in treating thoracolumbar fracture, studies confirmed that there was no significant difference in the stability of reconstructed spine between two methods [5]. Since spin could be located in injured vertebra, does it necessary to fix the inferior normal vertebral body? Or fix and fusion another normal intervertebral disc? We adopted single segmental pedicle screw fixation through injured vertebra on 10 cases of patients with thoracolumbar fracture dislocation from June 2010, and found its curative effect was satis-

Surgical treatment of thoracolumbar fracture dislocation

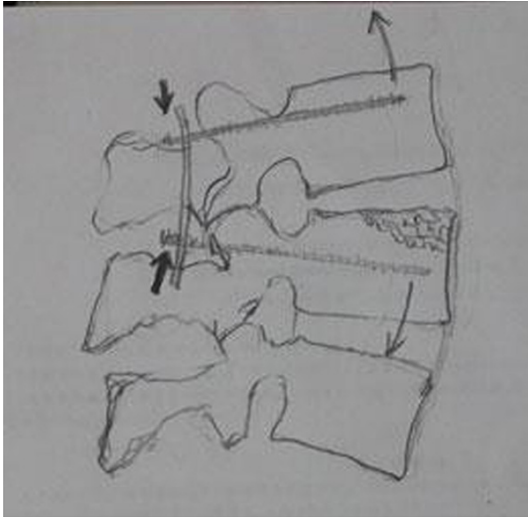


Figure 1. Posterior vertebra formed a fulcrum during compression, which let the anterior marginal intervertebral space relatively open to promote anterior edge restoration under the condition of the overall intervertebral space narrowing through level principle.

Table 1. ASIA grading comparison between two groups

Group	Cases	Pre-operation					Last follow-up				
		A	B	C	D	E	A	B	C	D	E
A	10		2	5	3		1	1	3	5	
B	9	1	2	4	2		1	1	2	2	3

factory compared with traditional short-segment pedicle screw fixation across injured vertebra in the same period.

Clinical information and methods

General information

19 patients with thoracolumbar fracture dislocation received surgical treatment between June 2010 and June 2014 were enrolled in Jinan central hospital affiliated to Shandong University, including 17 males and 2 females with average age as 37.2 (21-52) years old. 8 cases were because of traffic accident injury, 8 cases were caused by high falling injury, and 3 cases were injured by crush. Injured portion: T11/L2 segment, 7 cases; T12/L1 segment, 6 cases; L1/2 segment, 4 cases; T10/L1 segment, 2 cases; all were superior vertebral dislocation combined with inferior vertebral fracture. 16 cases combined with spinous process fracture, 19 cases combined with supraspinal

and interspinous ligaments fracture, 15 cases combined with lamina fracture; 13 cases combined with transverse process fracture; 13 cases combined with rib fractures, and 10 cases combined with hemopneumothorax. No patients merged pedicle fracture but nerve damage. 10 cases combined with spinal dura mater fracture and cauda equina escape. AO type: B1 type, 4 cases; C1 type, 13 cases; C2 type, 2 cases.

This study has been pre-approved by the ethical committee of Jinan central hospital affiliated to Shandong University and has obtained written consents.

Operation method

All patients received posterior open reduction, vertebra canal open window decompression pedicle screw fixation in 12 days after injury.

Midline incision was performed on patients with prone position to show intervertebral disc and articular process. Spine, interspinous ligament, and supraspinal ligament structure were reserved.

Decompression: Laminar space was opened to explore spinal cord compression degree from the heavier side of spinal cord before restoration. If broken bone or nucleus pulposus tissue existed in the spinal canal, expanding the window scope to remove it. If combined with epidural rupture or neurofilament escape, returning them and repairing the dura mater. Subcutaneous fat could be taken to cover broken dura mater surface for the difficult case.

Restoration: Restore the nerve through the interspinous small window. Though most patients combined posterior zygapophyseal twisting and locking, restoration was generally not difficult. Part of the articular process joint can be removed if necessary.

Nailing and fixation: 10 cases received single segmental fixation, namely implanting two pedicle screws through the fractured and dislocated vertebra, and posterior single segmental compression fixation. The other 9 cases were adopted with transpedicular fixation across the injured vertebra technique, namely implanting two pedicle screws through the upper and lower adjacent vertebra, and fixing two intervertebral

Surgical treatment of thoracolumbar fracture dislocation

Table 2. Perioperative period indications comparison (\pm s)

Group	Cases (n)	Age (year)	Operation time (min)	Blood loss (ml)	Incision (cm)	Complication incidence (%)
A	10	38.1 \pm 16	90.7 \pm 16	205 \pm 20	7.8 \pm 1.0	0
B	9	36.8 \pm 18	125.6 \pm 20	311 \pm 32	11.0 \pm 1.3	11.1%
<i>P</i> value		> 0.05	< 0.05	< 0.05	< 0.05	< 0.05

Table 3. Imaging indications comparison (\pm s)

Group	N	Injured vertebral leading edge height ratio (%)		Dislocation rate (%)		Cobb angle (°)		Spinal canal occupation rate (%)	
		Pre-operation	Last follow-up	Pre-operation	Last follow-up	Pre-operation	Last follow-up	Pre-operation	Last follow-up
A	10	77.28 \pm 5.7	90.8 \pm 2.3 [#]	31.75 \pm 1.3	1.63 \pm 1.6 [#]	28.76 \pm 3.35	3.9 \pm 3.9 [#]	35.22 \pm 2.3	5.20 \pm 2.51 [#]
B	9	75.43 \pm 6.1	88.6 \pm 5.1 [#]	32.23 \pm 1.0	8.32 \pm 2.1 [#]	29.21 \pm 5.21	9.2 \pm 5.3 [#]	33.89 \pm 1.95	16.32 \pm 3.75 [#]
<i>P</i> value		> 0.05	> 0.05	> 0.05	< 0.05	> 0.05	< 0.05	> 0.05	< 0.05

[#]*P* < 0.05, compared with pre-operation.

spaces. Open the intervertebral space from the anterior edge based on lever principle to promote fractured anterior edge restoration (**Figure 1**). Avoid squashing cracked intervertebral disc tissue into the posterior vertebral canal during compression, and using nerve dissection probe to explore the front neural canal to avoid spinal cord compression.

Fusion: All cases received posterolateral fusion. Transverse process fusion was applied for decompressive interlaminectomy. Zygapophyseal joint and interspinous bone graft fusion were performed on the opposite side.

Postoperative management: All patients were seated in one week after surgery under the brace support. 19 patients received more than 12 months follow-up, with mean time as 22.3 months.

Observation index

Perioperative indicators: Operation time, intraoperative blood loss, incision length, and the incidence of complications.

Imaging indicators: Injured vertebral leading edge height ratio, Cobb angle, dislocation rate (DR), and injured spinal canal occupation rate before surgery, one week after surgery and last follow-up were observed. Dislocation rate refers to: measuring vertebral displacement distance (DD) and dislocated vertebral body diameter (VD), calculate the DR = DD/VD \times 100%. Spinal canal occupation rate means the middle sagittal diameter percentage of the

most obvious part of the compressed vertebral canal compared with the upper and lower adjacent vertebral canal.

Neurological function evaluation

The American spinal injury association (ASIA) international standard for neurological classification of spinal cord injury (2006) was applied for function score at before surgery and the last follow-up.

Statistical analysis

All data were analyzed by SPSS 17.0 software. Measurement data was presented as \pm s and calculated by t-test. Enumeration data was tested by Kruskal-Wallis test.

Results

Neurological function evaluation

ASIA score at last follow-up in both groups increased significantly compared before surgery (*P* < 0.05), while no obvious different was observed between two groups (*P* > 0.05) (**Table 1**).

Perioperative period indicators

Single segmental pedicle screw fixation group showed obviously better performance in operation time, intraoperative blood loss, incision length, and complications than cross segment pedicle screw fixation group (*P* < 0.05). One case appeared screw extraction in cross seg-

Surgical treatment of thoracolumbar fracture dislocation

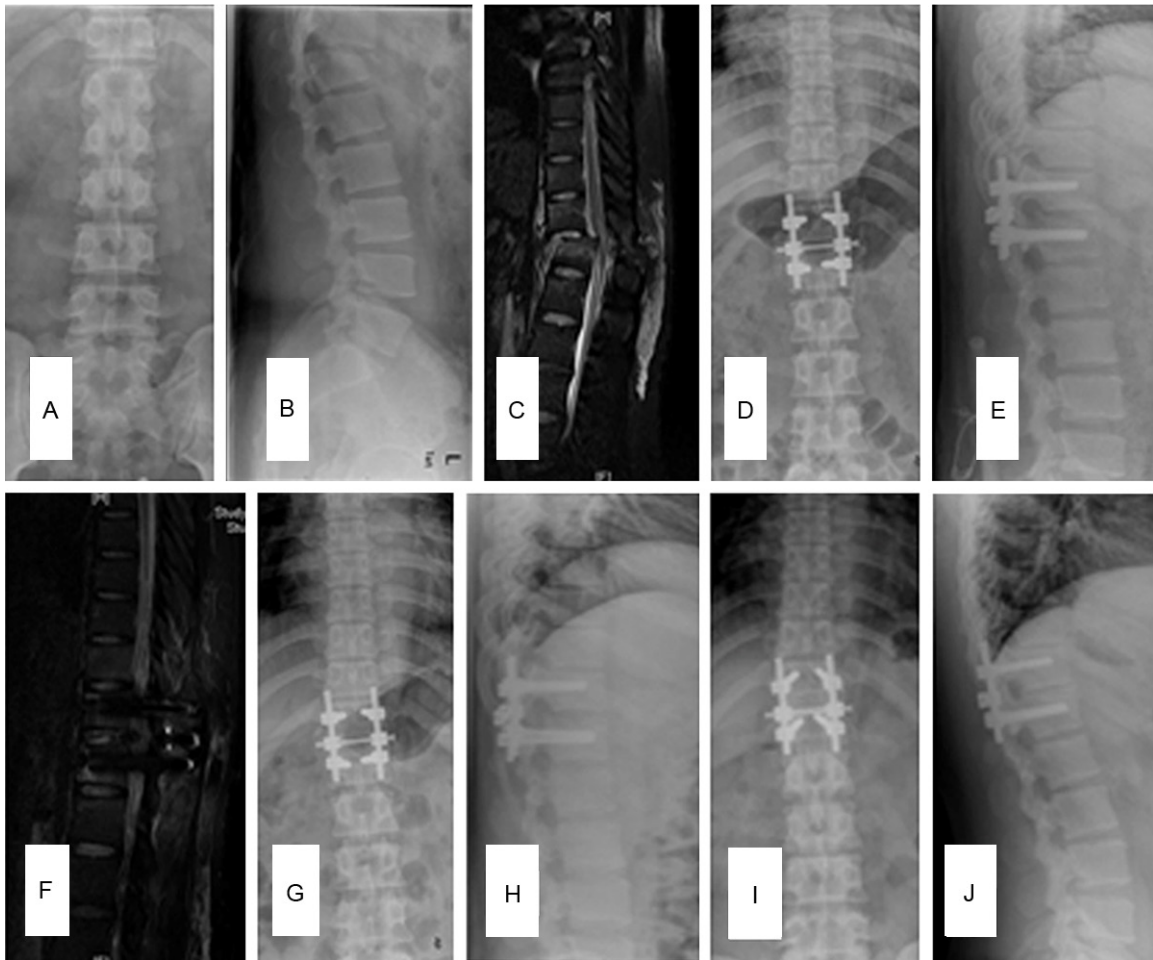


Figure 2. Male patient, 26 years old. He admitted because of lumbar back pain and double lower limbs paralysis for 2 hours caused by falling. ASIA grade was C before surgery and reached E at half a year after operation. A and B. T11/12 fracture dislocation before surgery. C. spinal cord compression. D-F. Fracture dislocation restore well without spinal cord compression at 1 week after surgery. G and H. structure was good at three months after surgery. I, J. intervertebral space reduced but spinal sequence was good at two years after surgery.

ment group, whereas no complication was observed in single segment group (**Table 2**).

Imaging indicators

No statistical difference was found in preoperative injured vertebral leading edge height ratio, Cobb angle, dislocation rate, and injured spinal canal occupation rate ($P > 0.05$). Two groups both showed significantly improved imaging indicators after surgery ($P < 0.05$). During the last follow-up, injured vertebral leading edge height ratio was similar between two groups ($P > 0.05$). Group A was better in Cobb angle, dislocation rate, and injured spinal canal occupation rate than group B ($P < 0.05$) (**Table 3**; **Figures 2** and **3**).

Discussion

The characteristics of the thoracolumbar fracture dislocation and operation strategy

Thoracolumbar vertebral fracture dislocation is similar to burst fracture on imaging, but with complete different damage mechanism. The former is formed by shear, rotating and flex violence, inducing anterior and posterior longitudinal ligament, intervertebral disc, and posterior bone and ligament structure damage. It greatly damages both the static and dynamic intervertebral structure stability, and complicated with spinal cord and nerve root injury [6]. Sometimes vertebral can restore spontaneously after injury. Imaging shows not serious fracture and dis-

Surgical treatment of thoracolumbar fracture dislocation

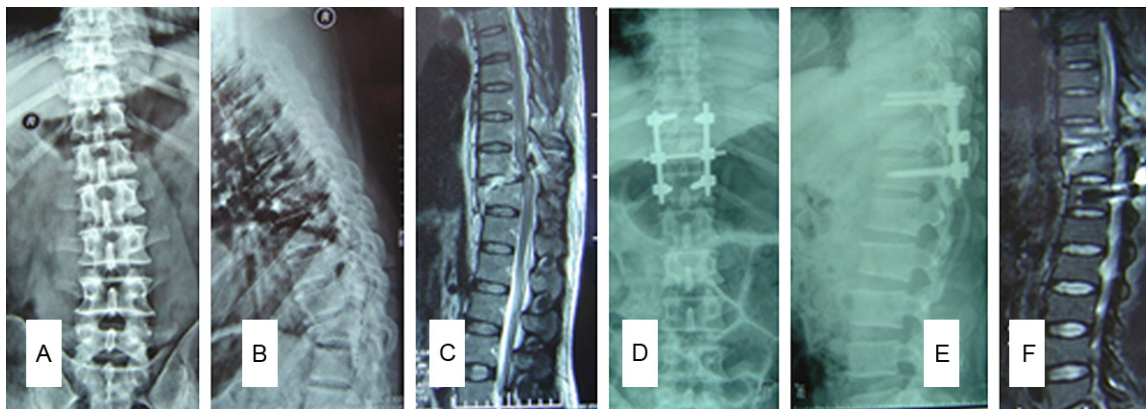


Figure 3. Male patient, 38 years old. He admitted because of waist back pain with double lower limbs paralysis for 4 hours caused by crashing. ASIA grade was C before operation and reached D after surgery. A and B. T11/12 fracture dislocation before surgery. C. Spinal cord compression. D-F. Fracture dislocation restore was poor. T11 still showed anterior dislocation, affecting spinal canal and spinal cord with poor sequence.

location, and no obvious invading vertebral canal, but patients appear serious neurological symptoms such as paraplegia. For this part of the patient, it should be highly suspected the existence of the vertebrae dislocation.

The principle of surgical treatment of thoracolumbar fracture dislocation is: (1) To recover the normal sequence of spine; (2) sufficient vertebral canal decompression in order to promote neural function recovery; (3) rebuilding the permanent stability of spine; and (4) early mobilization and rehabilitation training [7]. However, consensus has not been formed about the surgery way. Anterior surgery can reconstruct vertebral body fracture and keep good front support. On the contrary, its wound is large and cannot repair the posterior structure with poor stability. It sometimes cannot restore the complicated anterior, posterior and lateral dislocation. As a result, most scholars believed that simple anterior surgery should not be applied to unstable thoracolumbar fracture dislocation [8]. Posterior surgery fixed methods include: four nails fixation across injured vertebra, six nails fixation through the injured vertebra (these two methods contain two disc segments, thus we call them short segment fixation), six nails fixation across injured vertebra (containing four segments and named long segment fixation), and four nails fixation through the injured vertebra (containing only injured disc segment and called single segment fixation).

Four nails fixation across injured vertebra was used early and obtained satisfactory curative

effect. However, reports about complications including postoperative fixation failure, screw breakage, rod shortage, injured vertebral height loss, and secondary loss of spinal corrective degree increased gradually following the increase of clinical application [9, 10]. It was because of the distance between two nails was far, and the dislocation space was not stable. Due to the suspension effect of fixation, dislocated vertebra shifting ahead in the surgery is difficult to achieve ideal restoration and unstable (**Figure 3**). Meanwhile, as the anterior and posterior longitudinal ligament and intervertebral disc destruction, we cannot longitudinal open the intervertebral space excessively and restore the fractured vertebra satisfactorily. After the surgery, because of the distance between fixed segments, and the function of quadrilateral effect, lateral side was instable, leading to short rod phenomenon caused by too large load on internal fixation. In view of the above reasons, in order to increase stability, many scholars adopted long segmental fixation by adding fixed segments [11, 12]. Long segmental fixation did increase the spinal stability, but it obviously enlarged surgical trauma and fused too many normal segments that increase patients' cost. Furthermore, such improvement measures did not fundamentally change fixation way, therefore failed to effectively reduce the failure rate of internal fixation and loss of correct degree. To make up the abovementioned deficiency, six nails fixation through injured vertebra was applied in recent years and elevated restoration and fixation effect [13].

Surgical treatment of thoracolumbar fracture dislocation

Since the thoracolumbar fracture dislocation is caused by transverse shear violence, it is mainly with serious dislocation and lighter fracture. It generally affects anterior superior border of the vertebra that is correspond to imaging findings. At the same time, most of the patients were young and the bone strength was high that can provide enough support for implanted pedicle screws. In this case, why we have to fix the normal intervertebral space under the dislocation? Therefore, we investigated the corresponding theory basis through imaging data, intraoperative finding, mechanics principle and relevant information. We found that some scholars have adopted single segment fixation through injured vertebra in patients with spine fracture or fracture dislocation [14, 15]. Its advantage was remarkable: further shorten the operation time; small incision and small trauma; reduce the loss of motion segment; good vertebral restoration effect; shorter internal fixation span that avoids the suspension effect and quadrilateral effect, thus reducing the internal fixation load.

It was found that patients with thoracolumbar fracture dislocation gained satisfactory curative effect by receiving single segment intervertebral fixation [16]. Intervertebral bone graft fusion was applied at the same time to avoid segmental instability. There is still controversy about whether bone graft fusion is needed during pedicle screws restoration and fixation through injured vertebra. Guven et al. [17] adopted four kinds of treatment methods in 72 cases. No patients received bone graft fusion in two groups applying long and short segmental fixation through the injured vertebra, still obtained good spinal corrective degree maintenance and early spinal stable reconstruction. Roop Sing [18] used posterior screw rod fixation and posterolateral fusion treatment on 66 thoracolumbar fracture dislocation patients with neurological symptoms, confirming that posterolateral fusion was safe and reliable for thoracolumbar fracture dislocation after a median 24 months' follow-up. The reason of internal fixation failure and loss of corrective angle loss is relatively complex. It was generally considered to be caused by multiple factors, including spinal injury mechanism and severity, operation method selection, internal fixation material design, production and usage, patient's bone condition, surgical technique,

bone graft, and rehabilitation activity, etc. Whether graft or not should consider the above factors comprehensively [19]. We thought intervertebral fusion presented large trauma and severe hemorrhage; serious damage on posterior structure of vertebra; to resect intervertebral disc, shave their vertebral upper and lower cartilage endplate, existing the risk of spinal cord or nerve root secondary injury; cortical bone particle is easy to take off again into the spinal canal damaging nerve tissue. We simplified the above operation method during single segmental fixation: preserve and repair the posterior bone and ligament structure; open window decompression only from one side; fuse the zygapophyseal joint and intervertebral space on the other side to gain satisfactory restoration and stability. Though the anterior intervertebral body mechanics stability was important for spine, we did not perform the anterior fusion. The reason was as follows: (1) shorter internal fixation spans to avoid the suspension effect and reduces the quadrilateral effect, greatly reducing the internal fixation load; (2) Intervertebral compression further increased the interspinous stability of injured segment. Single segment fixation was not easy to appear fatigue fracture for smaller fixed scope, little activity, and smaller stress; (3) Preserve, restore, and reconstruct posterior bone and ligament structure to increase the spinal stability; (4) reduce posterior column bony structure damage by unilateral open window decompression between vertebral plate; (5) Decompression lateral intertransverse fusion, zygapophyseal joint fusion and intervertebral plate bone graft fusion on the other side to provide permanent stability. (6) Long-term screw-rod system retention to provide support. We adopted single segmental fixation through injured vertebra to treat thoracolumbar fracture dislocation on 10 cases, and follow-up for average 22.3 months. We obtained satisfactory therapeutic effect with neural function improvement, reliable restoration and fixation, and no screw rod fracture or protrusion deformity.

Key points of surgical technique and matters needing attention

As abovementioned, longitudinal open fixation method cannot be adopted on thoracolumbar fracture dislocation. We should take intervertebral compression fixation. During posterior ped-

Surgical treatment of thoracolumbar fracture dislocation

icle screw rods compression, it may form a fulcrum behind the vertebral body. Based on the lever principle, during the whole intervertebral space narrowing, intervertebral space on the anterior edge was relatively open to promote fractured anterior edge of vertebra restoration. Compression also lowered the intervertebral height that increased the intervertebral stability. This study found that intervertebral height decreased obviously in single segmental compression fixation group after surgery and in follow-up, but the spine sequence and form were good without posterior protrusion deformity.

Compression process should avoid the ruptured intervertebral disc tissue enter the spinal canal causing spinal cord or nerve root injury. Therefore, intervertebral plate bone window detection should be performed during the compression process. Since the injured intervertebral space posterior margin was gradually clipped during compression, the probability of intervertebral disc entering the vertebral canal was low. No patients appeared the phenomenon of intervertebral disc tissue enter the spinal canal.

According to preoperative MR and intraoperative finding, there were few broken bone and intervertebral disc tissue falls off into the spinal canal. Only one case appeared broken intervertebral disc tissue into the spinal canal, 12 cases were intervertebral disc and posterior bony vertebral arch structure clamps compression, and 6 patients showed no obvious spinal cord compression. Even so, intervertebral space open window on the heavier side before restoration was necessary. We explored the compression degree of spinal cord through the window, and expanded the window to remove the broken bone or nucleus pulposus in the spinal canal. We then returned neurofilament and repaired the dural sac if combined dura matter broken and neurofilament escape. For most dural sac mending is difficult, subcutaneous fat piece can be took to fill and cover the membrane surface. Another role of open window was to perform fracture dislocation traction, open restoration and compression fixation under the neural probe exploration, avoiding excessive violence.

9 cases received four nails fixation across injured vertebra. It was found in the operation that the dislocated vertebral body was hard to

achieve ideal spinal sequence, and restoration was difficult. Though the injured intervertebral space height was good, it aggravated intervertebral instability, leading to poor restoration and fixation effect. The other 10 patients received single segmental compression fixation and obtained satisfactory result.

Surgical indication, merit and demerit

We believed that the surgical indications of single segmental fixation through injured vertebra in treating thoracolumbar fracture dislocation include: AO type B1, B3, C1.1, and C2.1. Together with the following conditions: (1) pedicle integrity; (2) good vertebral bone; (3) fractured vertebral compression $\leq 50\%$; (4) single segmental fracture dislocation; (5) load grade ≤ 4 . Especially for B1 type fracture dislocation, with slight bony structure injury, and not involved in pedicle and osseous endplate. Shorten the posterior column and open the anterior column, so as to contact the PLC fracture-end to restore the tension band structure behind PLC [20].

Intervertebral posterior compression combined single segmental fixation has the following advantages: (1) Single segment intervertebral compression. Posterior vertebra formed a fulcrum during compression, which let the anterior marginal intervertebral space relatively open under the condition of the overall intervertebral space narrowing through level principle. It restored the fracture and dislocation. (2) Single segment compression significantly decreased intervertebral height and activity, leading to smaller stress and enhanced stability. (3) Fusing posterior zygapophyseal joint and between vertebral plates had slight impact on spinal activity and physiological function. (4). Shorten the operation time with smaller trauma and less bleeding, resulting in quickly postoperative recover. However, this surgical indication was relatively narrow and the technique request was high. At the same time, preoperative carefully analyzing image information, pedicle enter point and nailing direction to ensure success at one time. If unstable phenomenon was found in the surgery, we must increase the fixed segments.

Disclosure of conflict of interest

None.

Surgical treatment of thoracolumbar fracture dislocation

Address correspondence to: Dr. Jianmin Sun, Department of Spine, Shandong Provincial Hospital Affiliated to Shandong University, No. 9677 of the People's Republic of China, Shandong Jinan Jingshi Road, Jinan 250010, China. Tel: +86-0531-85695059; Fax: +86-0531-85695059; E-mail: sun-jianmin@sina.com

References

- [1] Xing D, Chen Y, Ma JX, Song DH, Wang J, Yang Y, Feng R, Lu J, Ma XL. A methodological systematic review of early versus late stabilization of thoracolumbar spine fractures. *Eur Spine J* 2013; 22: 2157-2166.
- [2] Wood KB, Li W, Lebl DR, Ploumis A. Management of thoracolumbar spine fractures. *Spine J* 2014; 14: 145-164.
- [3] Bernstein M. Easily missed thoracolumbar spine fractures. *Eur J Radiol* 2010; 74: 6-15.
- [4] Liljenqvist U, Halm H, Castro WH, Mommsen U. Thoracic fracture-dislocations without spinal cord injury: a case report and literature review. *Eur Spine J* 1995; 4: 252-256.
- [5] Harris MB. Commentary: Thoracolumbar spine fractures: is more knowledge better? *Spine J* 2013; 13: 222-223.
- [6] Sapkas GS, Papagelopoulos PJ, Papadakis SA, Themistocleous GS, Stathakopoulos DP, Efsthathiou P, Sapoutzi-Krepia D, Badekas A. Thoracic spinal injuries: operative treatments and neurologic outcomes. *Am J Orthop (Belle Mead NJ)* 2003; 32: 85-88.
- [7] Baumann F, Krutsch W, Pfeifer C, Neumann C, Nerlich M, Loibl M. Posterolateral Fusion in Acute Traumatic Thoracolumbar Fractures: A Comparison of Demineralized Bone Matrix and Autologous Bone Graft. *Acta Chir Orthop Traumatol Cech* 2015; 82: 119-125.
- [8] Tezeren G, Kuru I. Posterior fixation of thoracolumbar burst fracture: short-segment pedicle fixation versus long-segment instrumentation. *J Spinal Disord Tech* 2005; 18: 485-488.
- [9] Elzinga M, Segers M, Siebenga J, Heilbron E, de Lange-de Klerk ES, Bakker F. Inter- and intraobserver agreement on the Load Sharing Classification of thoracolumbar spine fractures. *Injury* 2012; 43: 416-422.
- [10] Modi HN, Chung KJ, Seo IW, Yoon HS, Hwang JH, Kim HK, Noh KC, Yoo JH. Two levels above and one level below pedicle screw fixation for the treatment of unstable thoracolumbar fracture with partial or intact neurology. *J Orthop Surg Res* 2009; 4: 28.
- [11] Vu TT, Morishita Y, Yague I, Hayashi T, Maeda T, Shiba K. Radiological Outcome of Short Segment Posterior Instrumentation and Fusion for Thoracolumbar Burst Fractures. *Asian Spine J* 2015; 9: 427-432.
- [12] Fakurnejad S, Scheer JK, Patwardhan AG, Havey RM, Voronov LI, Smith ZA. Biomechanics of thoracolumbar burst fractures: methods of induction and treatments. *J Clin Neurosci* 2014; 21: 2059-2064.
- [13] Kim BG, Dan JM, Shin DE. Treatment of thoracolumbar fracture. *Asian Spine J* 2015; 9: 133-146.
- [14] Fu MC, Nemani VM, Albert TJ. Operative Treatment of Thoracolumbar Burst Fractures: Is Fusion Necessary? *HSS J* 2015; 11: 187-189.
- [15] Pouw MH, Deunk J, Brink M, Dekker HM, Kool DR, van Vugt AB, Edwards MJ. Is a pelvic fracture a predictor for thoracolumbar spine fractures after blunt trauma? *J Trauma* 2009; 67: 1027-1032.
- [16] Guven O, Kocaoglu B, Bezer M, Aydin N, Nalbantoglu U. The use of screw at the fracture level in the treatment of thoracolumbar burst fractures. *J Spinal Disord Tech* 2009; 22: 417-421.
- [17] Singh R, Rohilla RK, Kamboj K, Magu NK, Kaur K. Outcome of pedicle screw fixation and monosegmental fusion in patients with fresh thoracolumbar fractures. *Asian Spine J* 2014; 8: 298-308.
- [18] Liu S, Li H, Liang C, Long H, Yu B, Chen B, Han G, Zhang X, Li F, Wei F. Monosegmental transpedicular fixation for selected patients with thoracolumbar burst fractures. *J Spinal Disord Tech* 2009; 22: 38-44.
- [19] Weerink LB, Folbert EC, Kraai M, Smit RS, Hegeman JH, van der Velde D. Thoracolumbar spine fractures in the geriatric fracture center: early ambulation leads to good results on short term and is a successful and safe alternative compared to immobilization in elderly patients with two-column vertebral fractures. *Geriatr Orthop Surg Rehabil* 2014; 5: 43-49.
- [20] Phan K, Rao PJ, Mobbs RJ. Percutaneous versus open pedicle screw fixation for treatment of thoracolumbar fractures: Systematic review and meta-analysis of comparative studies. *Clin Neurol Neurosurg* 2015; 135: 85-92.