

## Original Article

# Handling measures for the implantable vascular access device to prevent of catheter fracture/disruption

Tian-Tian Tang, Yun-Tao Li, Li-Na Zhang, Hai-Ping Li, Cui-Zhi Geng, Tao Zhou

Department of Breast Center, Fourth Hospital of Hebei Medical University, Shijiazhuang 050011, China

Received October 11, 2015; Accepted January 27, 2016; Epub February 15, 2016; Published February 29, 2016

**Abstract:** This study aims to investigate the causes of catheter fracture and handling measures for implantable vascular access devices to prevent catheter fracture. We retrospectively examined 3088 adult patients with catheter fracture/disruption caused by totally implantable vascular access devices (TIVDs). In the 3088 cases, implantation was via the internal jugular vein in 2909 cases and the subclavian vein in 179 cases. Catheter fracture/disruption occurred in 13 patients (0.42%). In 7 cases in which implantation was via the internal jugular vein (left side,  $n = 4$  and right side,  $n = 3$ ), the incidence of catheter fracture/disruption was 0.24% (7/2909). Four patients had catheter fracture, and 3 patients had catheter disruption. Among those with subclavian venipuncture, 6 patients had catheter fracture/disruption, with an incidence rate of 3.35% (6/179), including 4 cases of implantation via the left side and 2 cases of implantation via the right side. The incidence of catheter fracture/disruption in the internal jugular venipuncture was significantly lower than that in the subclavian venipuncture ( $\chi^2 = 38.938$ ,  $P = 0.000$ ). All of the cases of catheter fracture/rupture were treated safely, without any deaths in all the patient groups. Acuteness activity, body shape, improper operation, catheter material, and special anatomical structure are the causes of catheter fracture/disruption. Performing the appropriate surgical method and informing patients to avoid strenuous activities could reduce the incidence of catheter fracture/disruption.

**Keywords:** Implantable vascular access device, catheter fracture, catheter disruption, risk factors, reasons, handling measures

## Introduction

A totally implantable vascular access device (TIVD) is a small reservoir connected to a venous catheter and positioned in the subcutaneous tissue. It was first used in oncologic patients in the early 1980s [1]. Currently, the device has become an integral part of daily clinical routine [2, 3], allowing both administration of chemotherapy and blood aspiration without repeated venesection [4].

Compared to the peripherally inserted central venous catheter, TIVD has a simple feature, is more secure, and can be indwelled in the body over a long period [5, 6]. Moreover, most patients reported high overall satisfaction with the use of TIVDs [7]. TIVDs may be associated with some complications such as pneumothorax, arterial perforation, and arrhythmias; and mechanical problems such as catheter fracture/disruption and catheter migration; infections; extravasations; occlusions; and vein

thrombosis [8, 9]. Most of its complications can be effectively prevented by adequate procedures of insertion and management. However, some rare cases may be fatal, such as pneumothorax, arterial perforation, and catheter fracture/disruption. The rate of catheter fracture/disruption is estimated to range from 0.1% to 2.1% [10-14]. The most remarkable complications are catheter line fractures with fragment displacement to the pulmonary circulation [15]. Many causes can lead to catheter fracture/disruption, and physicians should take adequate measures to prevent it. The aim of this study was to investigate the causes of and treatment measures to prevent catheter fracture/disruption in the use of TIVDs.

## Materials and methods

### Setting and participants

From December 2008 to May 2014, 3088 TIVDs were inserted in the Fourth Hospital of

Hebei Medical University. Their ages ranged from 28 to 63 years (mean, 49.33 years). Of the patients, 2909 underwent implantation via the internal jugular vein; and 179, via the subclavian vein. The indwelling time ranged from 42 to 1000 days (mean, 508.55 days). This study was conducted in accordance with the declaration of Helsinki. This study was conducted with approval from the Ethics Committee of Hebei Medical University. Written informed consent was obtained from all participants.

### *Types of TIVDs*

The totally implantable catheters used consisted of 7-Fr or 8-Fr catheters and silicone ports from Bard Inc. In the cases of catheter fracture/disruption, a 7-Fr catheter was used in 2 cases and an 8-Fr catheter was used in 11 cases.

All the implantation procedures were performed in the operating room, under local infiltration anesthesia. Confirmatory chest radiography was always performed after the placement, and all of the patients were examined by a physician before discharge.

### *Statistical analysis*

Data were analyzed by using the SPSS13.0 statistical software. Statistical significance was set at  $P = 0.05$ .

### **Results**

Of the 3088 cases of catheter implantation, 13 (0.42%) presented catheter fracture/disruption as complication. Of the 7 cases (0.24%, 7/2909) of implantation via the internal jugular vein, 4 were via the left internal jugular vein and 3 were via the right internal jugular vein. Of the 6 cases (3.35%, 6/179) of implantation via the subclavian vein, 4 were via the left subclavian vein and 3 were via the right subclavian vein. In all of the cases, the tip of the catheter was in the right atrium. The incidence of catheter fracture/disruption with subclavian vein puncture was significantly higher than that with internal jugular vein puncture ( $\chi^2 = 38.938$ ,  $P = 0.000$ ). Of the 13 patients with catheter fracture/disruption, 10 had catheter fracture and 3 had catheter disruption.

In 4 cases of catheter fracture where the catheter was implanted via the internal jugular vein,

implantation was via the left side in 2 cases, the port-catheter junction in 1 case, and the puncture site in 1 case. The fracture position of another 2 catheter fracture via the right side, both of them fracture in the ministry of turn-back of the catheter. Six cases of catheter fractures had pinch-off syndrome and were invariably located between the clavicle and the first rib.

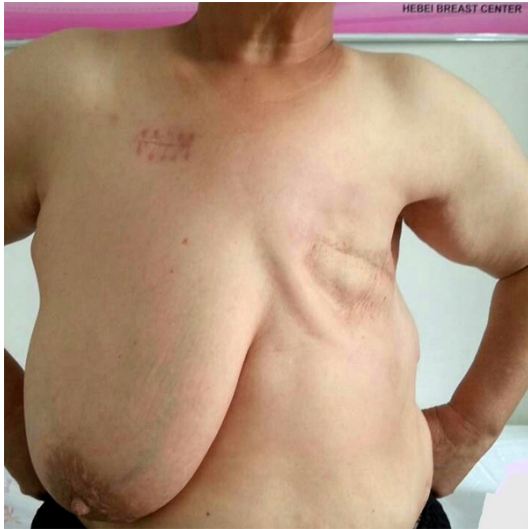
In 3 cases of catheter disruption in which implantation was via the internal jugular vein, implantation was via the left side in 2 cases and the right side in 1 case. Two cases in which implantation were via the left side, catheter disruption was found in the port-pipe junction and in 5 locations with rupture, respectively. One case was treated via by right side in the ministry of turn-back of the catheter.

Pinch-off syndrome was diagnosed in 6 cases, and the catheters were immediately removed. In 3 patients with catheter fracture, 4 catheter fragments were percutaneously retracted by an interventional radiologist from the right atrium by using a snare catheter through a 6-Fr femoral vein access, without further complications. However, unfortunately, in 1 patient, a catheter fragment was accidentally dropped into the pulmonary artery. Finally, it was removed with sternotomy by thoracic surgeons. Another 3 patients with catheter disruption underwent direct port and catheter removal.

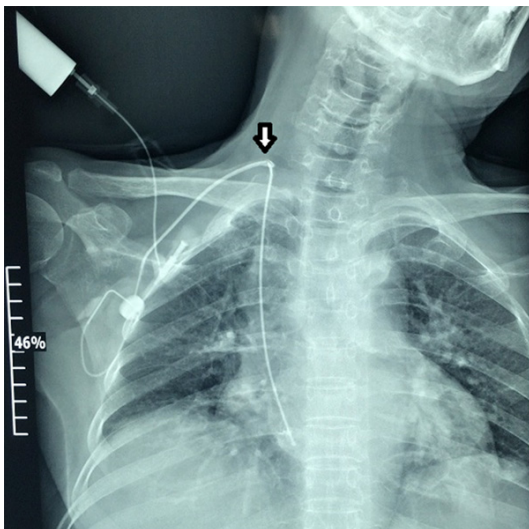
### **Discussion**

Although rarely reported, catheter fracture/disruption is a potentially dangerous complication encountered in clinical practice, which can occur during the time of indwelling or TIVD removal. Because catheter fracture/disruption is asymptomatic, its real incidence may be higher. Though asymptomatic, it can also lead to serious local inflammation, thrombus embolism, arrhythmia, and even sudden death [16-18]. Catheter fracture/disruption is an accidental event, and nurses should always be alert to the occurrence of this complication in the daily care of patients with, especially when no blood is observed or when resistance is noted during the flushing of the catheter [19].

The risk factors of catheter fracture/disruption include long-term use and repetitive operation; manufacturing defect; material degradation;



**Figure 1.** Long-term lack of side breast in the obesity patient's made lateral partial.



**Figure 2.** Chest x ray contrast radiography showing the exosmotic contrast agent in the fractured catheter in the cervical part.

fibrin clot and calcium deposition in the catheter [20]; the polar angle of the catheter; mechanical damage, especially in the removal process; inflammation; and poor location such as in the pinch-off syndrome [21].

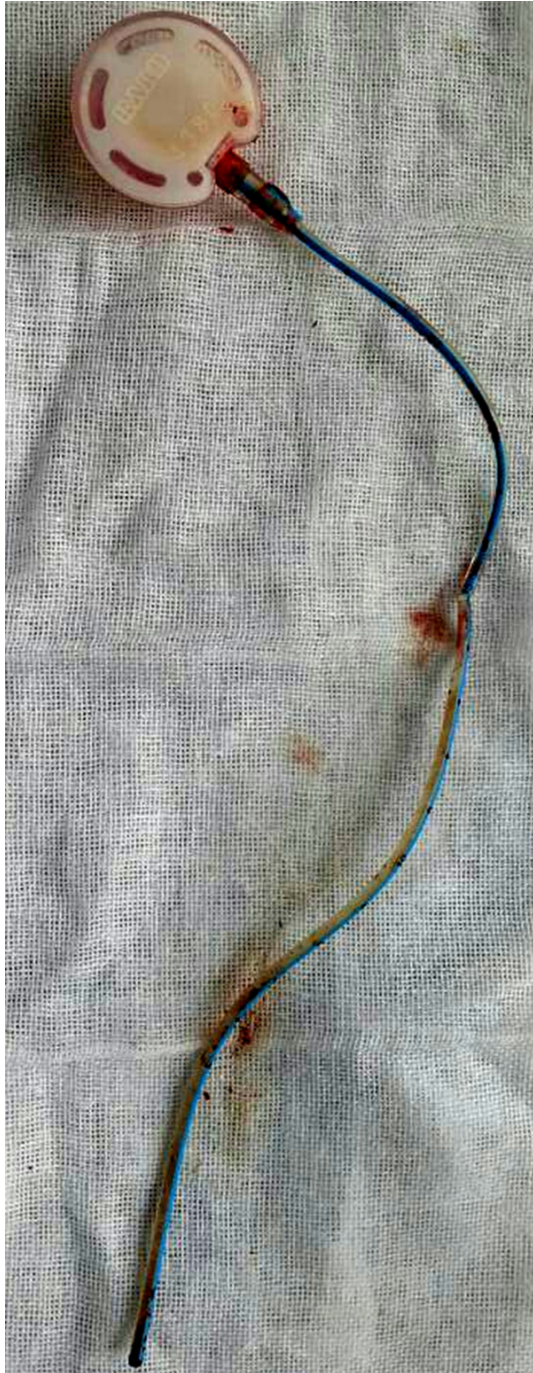Catheter fracture/disruption mainly occurs in the port-catheter junction, the subcutaneous tunnel, the ministry of turn-back of the catheter, and the intravenous catheter. Catheter fracture can migrate into the precaval vein, right atrium, right ventricle, and postcaval vein along

with the blood flow. Few cases of catheter fracture will migrate into the pulmonary artery. In our study, 4 cases (30.8%) occurred in the port-catheter junction, of which 3 were catheter fractures and 1 was catheter disruption. One case (7.69%) of catheter fracture occurred in the ministry of turn-back, 2 cases (15.4%) of catheter fracture occurred in the intravenous catheter, and 6 cases (46.15%) had pinch-off syndrome.

Six cases of catheter fracture/disruption due to pinch-off syndrome occurred in this group, in which implantation was via the left side in 4 cases and the right side in 2 cases. Pinch-off syndrome, also called "catheter clip syndrome" [21], can be defined as the anatomic and mechanical compression of a catheter as it passes between the clavicle and the first rib at the costoclavicular space. When the catheter is surgically placed by using a percutaneous puncture medial to the midclavicular line, the catheter travels through the costoclavicular space next to the subclavian vein rather than inside it, making it vulnerable to compression with shoulder movement. The incidence of pinch-off syndrome is about 1%. However, the incidence of catheter fracture caused by pinch-off syndrome can reach up to 40% [22]. Before the occurrence of catheter fracture/disruption, resistance occurs during infusion. However, the infusion can be administered smoothly if patients raise their arms or maintain a certain position. The narrow catheter lumen is detected on chest radiography. In the presence of catheter disruption, the patient will feel pain from swelling during infusion. On the other hand, in the presence of catheter fracture, the nurse will find no blood during catheter withdrawal. The TIVD should be removed immediately if catheter clip syndrome occurs. In our study, 6 catheter fractures were observed, in which the tip of the catheter was in the right atrium and removal was performed by means of interventional radiology. The key to the prevention of pinch-off syndrome is to avoid the clavicle and first rib during TIVD implantation or to choose the internal jugular vein approach. We have never encountered pinch-off syndrome in our center because we never choose the subclavian vein in the final stage of implementation.

We found 7 cases of catheter fracture/disruption in our study, including 4 cases of catheter





**Figure 3.** The fractured catheter of TIVD.

fracture and 3 cases of catheter disruption. 1 catheter fracture was in the ministry of turn-back, also was the puncture position, nurse found the swelling subcutaneously in the cervical part when they infusion, X-ray confirm the catheter fracture. Two cases of catheter fracture occurred in the intravenous catheter, and another case of catheter fracture occurred in

the port-catheter junction. All of these cases were found by the nurse during infusion and were radiographically confirmed. Surgeon factor may cause puncture site fractures. Port-catheter junction fracture may have several causes as follows: (1) The gab of the port-catheter junction. The catheter should be connected into the gab. Overshoot of the gab to the bottom of the port should be avoided; otherwise, the catheter will be crushed by the lock, which can lead to catheter fracture and even catheter detachment. (2) The position of the port. The port should be located in the ipsilateral lateral skin and as far as possible below the clavicle to avoid line on the edge of the clavicle. Otherwise, the port-catheter junction is just near the edge of clavicle. In an obese patient, the extrusion of the ipsilateral breast will lead to elevation of the port, which in turn leads to friction with the clavicle. Two patients had obesity in our study. Lateral partial caused by the long-term lack of a side breast in obese patients will lead to catheter fracture because the slanting of the side of the body will increase the pull of the catheter. Moreover, vigorous exercise or sharp coughing in daily life suggests long-term repeated pull between the port and the catheter, which is also one of the causes of catheter fracture (**Figure 1**). (3) Regarding other causes include, the 2 cases of fracture in the intravenous catheter in our study suggest that the cause may be the polar angle in the ministry of turn-back, combined with the friction in daily life. The catheter material can also lead to catheter fracture, considering that we found multiple bursts in the catheter, the position being neither in the ministry of turn-back or in the parts exposed to friction.

Once catheter fracture/disruption is suspected, it should be confirmed by performing chest radiography or by means of contrast agent injection (**Figures 2 and 3**).

Although catheter fracture/disruption is rare, awareness of its possible occurrence is important for patients. The catheter should be removed by means of interventional radiology to avoid further complications.

Prevention is more important. First, the physician should choose the appropriate type and size of the TIVD, the appropriate position, and tube angle for smooth insertion, and avoid damaging the catheter during the operation.

Second, nursing staff should use a suitable infusion speed and accurate heparin concentration when flushing the TIVD. Proper maintenance of the device will reduce the probability of catheter fracture/disruption. Nursing staff also need to provide patient education and inform patients to avoid vigorous exercise and frequent movement. The patients should be warned to undergo routine examination in order to detect problems.

## Disclosure of conflict of interest

None.

**Address correspondence to:** Tao Zhou, Department of Breast Center, Fourth Hospital of Hebei Medical University, Shijiazhuang 050011, China. Tel: +86 13930462390; Fax: +86 311 66696234; E-mail: taozhoudoc@163.com

## References

- [1] Niederhuber JE, Ensminger W, Gyves JW, Liepman M, Doan K and Cozzi E. Totally implanted venous and arterial access system to replace external catheter in cancer treatment. *Surgery* 1982; 92: 706-712.
- [2] Vescia S, Baumgärtner AK, Jacobs VR, Kiechle-Bahat M, Rody A, Loibl S and Harbeck N. Management of venous port systems in oncology: a review of current evidence. *Ann Oncol* 2008; 19: 9-15.
- [3] Barwińska-Pobłocka K, Wydra D, Abacjew-Chmyłko A and Szkop-Dominiak A. The use of venous ports in oncological patients. *Ginek Pol* 2013; 84: 339-343.
- [4] Greene FL, Moore W, Strickland G and McFarland J. Comparison of a totally implantable access device for chemotherapy (Port-A-Cath) and long-term percutaneous catheterization. *South Med J* 1988; 81: 580-583.
- [5] Maki DG, Kluger DM and Crnich CJ. The risk of bloodstream infection in adults with different intravascular devices: a systematic review of 200 published prospective studies. *Mayo Clin Proc* 2006; 81: 1159-1171.
- [6] O'Grady NP, Alexander M, Burns LA, Dellinger EP, Garland J, Heard SO, Lipsett PA, Masur H, Mermel LA, Pearson ML, Raad II, Randolph AG, Rupp ME and Saint S. Guidelines for the prevention of intravascular catheter-related infections. *Am J Infect Control* 2011; 39: S1-34.
- [7] Chang DH, Kabbasch C, Bovenschulte H, Libicher M, Maintz D and Bangard C. Experiences with power-injectable port systems: complications, patient satisfaction and clinical benefit. *Rofo* 2013; 185: 454-460.
- [8] Gallieni M, Pittiruti M and Biffi R. Vascular access in oncology patients. *CA Cancer J Clin* 2008; 58: 323-346.
- [9] Sakamoto E, Hasegawa H, Komatsu S, Norimizu S, Shingu Y, Inaba K, Taguchi Y, Ito Y, Watanabe M, Arimoto A, Isaji T, Makino A, Miura Y and Santo M. Complications after implantation of subcutaneous central venous port. *Gan To Kagaku Ryoho* 2013; 40: 613-616.
- [10] Barbetakis N, Asteriou C, Kleontas A and Tsilikas C. Totally implantable central venous access ports. Analysis of 700 cases. *J Surg Oncol* 2011; 104: 654-656.
- [11] Kim JT, Oh TY, Chang WH and Jeong YK. Clinical review and analysis of complications of totally implantable venous access devices for chemotherapy. *Med Oncol* 2012; 29: 1361-1364.
- [12] Biffi R, de Braud F, Orsi F, Pozzi S, Mauri S, Goldhirsch A, Nolè F and Andreoni B. Totally implantable central venous access ports for long-term chemotherapy, a prospective study analyzing complications and costs of 333 devices with a minimum follow-up of 180 days. *Ann Oncol* 1998; 9: 767-773.
- [13] Koller M, Papa MZ, Zweig A and Ben-Ari G. Spontaneous leak and transection of permanent subclavian catheters. *J Surg Oncol* 1998; 68: 166-168.
- [14] Yildizeli B, Laçın T, Batirel HF and Yüksel M. Complication and management of long-term central venous access catheters and ports. *J Vasc Access* 2004; 5: 174-178.
- [15] Busch JD, Herrmann J, Heller F, Derlin T, Koops A, Adam G and Habermann CR. Follow-up of radiologically totally implanted central venous access ports of the upper arm: long-term complications in 127,750 catheter-days. *AJR Am J Roentgenol* 2012; 199: 447-452.
- [16] Karam AR, Hourani MH and Al-Kutoubi AO. Catheter fracture and migration into the coronary sinus: an unusual migration site: case report and review. *Clin Imaging* 2009; 33: 140-143.
- [17] Liu JC, Tseng HS, Chen CY, Chern MS and Chang CY. Percutaneous retrieval of 20 centrally dislodged Port-A catheter fragments. *Clin Imaging* 2004; 28: 223-229.
- [18] Filippou DK, Tsikkinis C, Filippou GK, Nissiotis A and Rizos S. Rupture of totally implantable central venous access devices (Intravports) in patients with cancer: report of four cases. *World J Surg Oncol* 2004; 2: 36.
- [19] Surov A, Buerke M, John E, Kösling S, Spielmann RP and Behrmann C. Intravenous port catheter embolization: mechanisms, clinical features, and management. *Angiology* 2008; 59: 90-97.
- [20] Muguet S, Couraud S, Perrot E, Claer I and Souquet PJ. Clearing obstructed totally im-

## Reason and measures of port catheter fracture

- plantable central venous access ports: an efficient protocol using a second needle. *Support Care Cancer* 2012; 20: 2859-2864.
- [21] Aitken DR and Minton JP. The "pinch-off sign": a warning of impending problems with permanent subclavian catheters. *Am J Surg* 1984; 148: 633-636.
- [22] Prager D and Hertzberg RW. Spontaneous intravenous catheter fracture and embolization from an implanted venous access and analysis by scanning electron microscopy. *Cancer* 1987; 60: 270-273.