

Original Article

Secondary operation of “scarless” (in neck) endoscopic thyroid surgery: initial experiences of single center

Hua Tian, Yong Wang, Zhiyu Li, Ping Wang, Li Chen

Department of General Surgery, 2nd Affiliated Hospital of Zhejiang University School of Medicine, Hangzhou 310009, China

Received October 12, 2015; Accepted January 27, 2016; Epub February 15, 2016; Published February 29, 2016

Abstract: This study aims to explore safety and feasibility of secondary “scarless” (in neck) endoscopic thyroid (SET) surgery. Six patients performed secondary operations of SET from January of the year 2012 to January of 2015. The anterior breast approach using sternocleidomastoid side pathway or central isthmus pathway was selected for operation. Clinical data of secondary operation patients of SET were collected and the initial experiences in surgery were concluded retrospectively. The results indicated that all secondary operation patients were performed in SET surgery and none of the surgeries were converted to open thyroid surgery. Postoperative complications were observed. Total remnant thyroidectomy and central neck lymph node dissection was performed in a patient with relapse of bilateral thyroid papillary microcarcinoma. Total remnant thyroidectomy and suffering side thyroidectomy were performed in two patients with postoperative recurrent multinodular goiter. The total remnant thyroidectomy+central VI and selective ipsilateral compartments II, III, IV deep cervical lymph node dissection (LND) was performed in one patient with postoperative partial endoscopic thyroidectomy who had been diagnosed thyroid papillary carcinoma. The remnant thyroidectomy was performed in two patients with postoperative recurrent thyroid cystadenoma 2-years later and one patient with postoperative neck subcutaneous planting lesions. In conclusion, secondary operation of SET still can be performed safely in patients with a cosmetic demand by taken protective measures during operation. Its still have its feasibility of secondary operation of SET for minority patients with esthetic demands. Its limitation due to risk could be follow-up investigation by randomized clinical trials for confirmation.

Keywords: Thyroid neoplasm, video-assisted surgical techniques, secondary operation

Introduction

The first endoscopic neck surgery was reported in 1996 by Gagner [1] for the treatment of primary hyperparathyroidism, and in 1997 Hüscher performed a video-assisted thyroid lobectomy [2]. Since then, the evolutionary development of endoscopic thyroid surgical technologies has rapidly progressed because of its advantages in providing a cosmetic scarless appearance and minimal invasive trauma, and endoscopic thyroid surgery has been accepted by patients with esthetic demands. Since the first endoscopic thyroid operation was performed one decade ago in China, the endoscopic thyroid surgical technologies and surgical instrument innovations have been applied in clinical practice [3, 4]. The indications of endoscopic thyroid surgery have been expanded persistently by skilled thyroid spe-

cialists, and many concepts in thyroid endoscopy surgery have been updated continuously. Neck thyroid surgery and second operation of bilateral thyroid papillary microcarcinoma were once regarded as contradictory in the scarless endoscopic thyroid surgery [5], and are still considered as restricted zones by many experts in thyroid surgery despite the fact that patients have esthetic expectations. However, the efforts have not stopped. Since the beginning of this century, more than three thousand SET surgical operations have been performed in our thyroid specialty center. The thyroid diseases spectrum treated with SET range from benign tumor and functional thyroid disorder to advanced thyroid carcinoma [6, 7]. From January of 2012, secondary operation of SET has been performed successfully in six patients based on a large scale SET experience. The secondary operation of SET is limited by its rel-

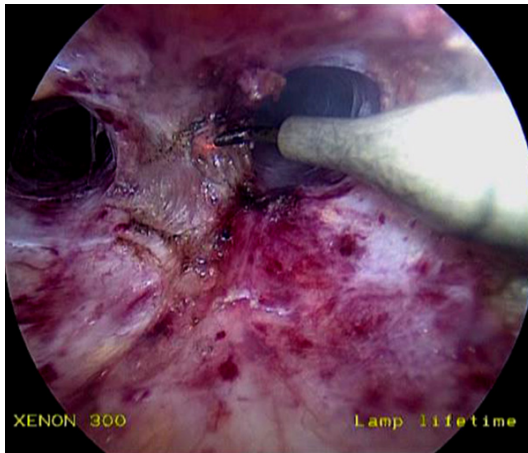


Figure 1. Use of an electrical coagulation hook to separate the tough connective tissue adhesion induced by the first operation.

atively higher postoperative complication rate compared to the original operation. Therefore, the purpose of the report is to analyze its safety and feasibility of secondary operation of SET, surgical approach pathway our adopted and protection measurements in surgery to ameliorate the disadvantages were also discussed based on the literature.

Materials and methods

Patients

Informed consent was obtained from all of our patients. Six patients underwent secondary operation of SET between January of 2012 and January of 2015 in the surgical ward of our free affiliated hospital. The study was conducted according to the guidelines of the Declaration of Helsinki and was also approved by the hospital's ethical committee. The median age of the patients (1 male and 5 female) was 37.3 years (range: 28-46 years). The median interval time from the first time of thyroid operation to the secondary operation of SET was 3.48 years (range: 1 month-8 years). Preoperative evaluations were performed before the secondary operation. The first operation was obtained, and we checked the record of recurrent laryngeal nerve exploration. Preoperative bilateral vocal cord movement status was inspected using electronic laryngoscope. The remnant thyroid gland location and deep cervical lymph nodes were defined by thyroid ultrasonography or computerized tomography scan. The thyroid

and parathyroid function and calcium concentration were determined before the operation. Fine-needle aspiration was performed in six patients. A relapse in bilateral thyroid papillary microcarcinoma was diagnosed at the 3-year follow up. One patient with multiple lesions of thyroid microcarcinoma was diagnosed one week after the first SET. Two patients with recurrent simple multinodular goiter and two patients with postoperative recurrent thyroid cystadenoma 2-years later underwent surgery, as did one patient with postoperative neck subcutaneous planting lesion. One patient with thyroid papillary carcinoma underwent endoscopic partial thyroidectomy after the diagnosis.

The study eligibility criteria were selected as follows: (a) Patients agreement to minimally invasive endoscopic thyroid resection. (b) Normal heart and lung functions, normal tolerance to anesthesia, and normal coagulation. (c) Mass in the thyroid with a diameter of equal or less than 5 cm. (d) Acceptance of the risk hazard of secondary operation of scarless endoscopic thyroid surgery. The exclusion criteria were as follows: (a) Maximum diameter of mass >5.0 cm. (b) Serious cardiac and pulmonary disease or dysfunction that would put the patient at risk during the endoscopy operation; (c) Unwillingness to undergo minimally invasive endoscopic surgery.

Surgical procedures

Tracheal intubation with electrode-enhanced catheter was performed under intravenous and inhalational anesthesia. Intraoperative neuromonitoring (Medtronic, USA) was used for perioperative real time detection of recurrent laryngeal nerve [8]. All procedures were performed by one surgical team. The original trocar scar of the first endoscopic surgery was removed. The majority of the steps have been reported in a previous article [6]. A skin incision 1.5 cm in length was made bilaterally at the circumareolar line. Subcutaneous dissection was performed bilaterally from the incision to the thyroid cartilage and the sternocleidomastoid muscle. We used an electrical coagulation hook and harmonic scalpel to separate the tough connective tissue adhesion (**Figure 1**) induced at the original thyroid surgery. The adhesion of the suture in the linea Alba cervicalis and the fibrous stripes adhesion between the thyroid

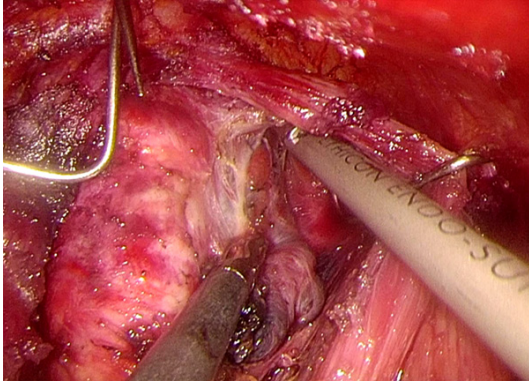


Figure 2. Identifying the superior parathyroid in thyroid peduncle and preservation of the blood supply from the posterior ramus of the superior thyroid artery through the central isthmus pathway.

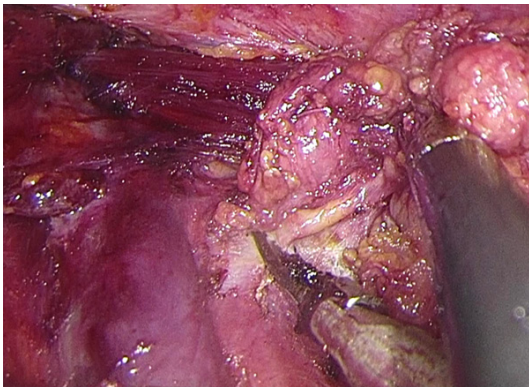


Figure 3. Selective deep cervical lymph node resection of compartments II, III, and IV was performed in secondary operation of scarless endoscopic thyroid surgery in a patient of papillary carcinoma (in sternocleidomastoid side pathway).

gland and the anterior jugular muscles were separated as well.

Central isthmus pathway

If the isthmus of thyroid had been preserved well during the original operation, we chose the central isthmus pathway to divide the thyroid gland in front of the trachea. The middle of the trachea was determined as an anatomical landmark that separates the fibrous adhesion induced in first operation and reveals the lesion of the remnant thyroid gland. The recurrent laryngeal nerve was explored at the tracheo-esophageal groove from the inferior pole of the remnant thyroid [9]. Real time intraoperative neuromonitoring was used for detection of the recurrent laryngeal nerve with 3.0 mA stimulat-

ing current. The nerve distribution and activity was clarified based on the electromyographic waveform signal, and the lesions and remnant thyroid were resected to prevent from the recurrent laryngeal nerve injury. We identified the superior parathyroid in the thyroid peduncle and preserved its blood supply from the posterior ramus of the superior thyroid arterial (**Figure 2**).

Sternocleidomastoid side pathway

If the adhesion tissue in the central isthmus pathway is tough and difficult to separate or the thyroid isthmus had been resected during the first operation, we used the harmonic scalpel to expand the neck subcutaneous operating space in the lateral direction. The sternocleidomastoid side area between the sternocleidomastoid and the belt-shaped anterior cervical muscle were separated. We followed this sternocleidomastoid side pathway and revealed the lesions the remnant thyroid. With the help of intraoperative neuromonitoring and staying away from the distribution of the recurrent laryngeal nerve, SET was performed and the lesion in the remnant thyroid was resected.

If the lesion in the remnant thyroid gland was diagnosed by preoperative fine-needle aspiration or perioperative pathological frozen section, the lymph nodes in the central neck area around the anterior tracheal zone should be dissected. The selective deep cervical lymph nodes of the ipsilateral compartments II, III, and IV were performed when metastasis to the deep cervical lymph was suspected after the surgical exploration (**Figure 3**). The resected thyroid specimen was stored in a plastic bag and taken out through the 1.2 cm incision of the breast-chest approach. The resected remnant thyroid tissue was evaluated and the parathyroid was identified by pathological frozen section diagnosis. Isolated parathyroid was segmented and transplanted into the sternocleidomastoid. Drains were placed inside the wound and came out from one side circumareolar.

Results

Secondary operations of SET

All patients underwent SET successfully, and none of the procedures had to be converted to

open thyroid operation. The total remnant thyroidectomy and central neck lymph node dissection was performed in a patient with relapse of bilateral thyroid papillary microcarcinoma. Total remnant thyroidectomy and thyroidectomy of the affected side was performed in two patients with postoperative recurrent multinodular goiters. The total remnant thyroidectomy+central VI and selective ipsilateral compartments II, III, and IV deep cervical lymph node dissection was performed in patients who had undergone postoperative partial endoscopic thyroidectomy and were diagnosed with thyroid papillary carcinoma. The remnant thyroidectomy was performed in patients with postoperative recurrent thyroid cystadenoma 2 years later, and in one patient with postoperative neck subcutaneous planting lesion.

Postoperative characters and complications in secondary operation of SET surgery

Mean operative time of scarless endoscopic thyroidectomy was 130 min (range: 40-220 min). Average total postoperative bleeding volume was 105 ml and none of the patients required re-operation for bleeding. Average postoperative hospitalization time was 3.2 days. None of the patients developed postoperative permanent hypocalcemia and acid-base imbalance. Transient hypocalcemia caused by hypoparathyroidism resulted in hand and foot numbness in three patients. Two patients had postoperative transient unilateral recurrent laryngeal nerve palsy. Postoperative electronic laryngoscopy showed normal bilateral vocal cord movement after one month. The number of dissected central neck lymph nodes in bilateral thyroid papillary microcarcinoma was five without any evidence of metastasis. Twelve lymph nodes were resected in the thyroid papillary carcinoma patient and two lymph nodes were positive for metastasis after selective dissection of deep cervical ipsilateral lymph node compartments II-IV. The postoperative follow-up by ultrasonography and emission computerized tomography examination indicated that there was no residual or regional recurrence on the diseased side. Two patients with thyroid carcinoma required oral levothyroxine sodium tablets postoperatively for endocrine therapy. In addition, levothyroxine sodium tablets for replacement therapy in the four benign thyroid disease patients regulated in gradient

according to the thyroid functional parameters.

Discussion

The firstly endoscopic neck surgery for treatment of primary hyperparathyroidism was reported by Gagner in 1996 [1] and Hüscher et al. [2] in 1997, who used a video-assisted thyroid lobectomy. Since then, the evolutionary development of endoscopic thyroid surgical technologies has rapidly progressed due to its advantages in cosmetic scarless appearance and minimal invasive trauma [4], and endoscopic thyroid surgery has been accepted by the patients with esthetic demand as well. The first endoscopic thyroid operation was performed one decade ago in China and since then the endoscopic thyroid surgical technologies and surgical instrument innovations have been applied in clinical practice. The indications of endoscopic thyroid have been expanded persistently by skilled thyroid specialist, and many concepts in thyroid endoscopy surgery have been continuously updated. The neck thyroid surgery history and second operation of bilateral thyroid papillary microcarcinoma was once regarded as a contraindication in SET surgery [5]. The difficulties and postoperative complications in secondary operation using completely endoscopic thyroidectomy will be increased due to anatomical destruction and tough adhesion of connective tissue induced by the first thyroid operation. Therefore, it was considered as a restricted zone and despite those secondary operation patients still have esthetic expectation. Due to contributions and efforts of specialist and researcher in thyroid surgery, the development of endoscopic thyroid surgical technology and innovation in instrument have rapidly progressed in the last years [3, 4, 6]. With the help of these progress and experiences enrichment in endoscopic surgery, the further attempt in secondary operation of SET becomes impossible.

Preoperative evaluation of the original thyroid operation is an essential step in grasping information of remnant thyroid tissue and recurrent laryngeal nerve exploration record. The parathyroid hormone level is required for determination. In addition, the anatomical structure of adjoining organs was determined by enhanced computerized tomography to choose the most

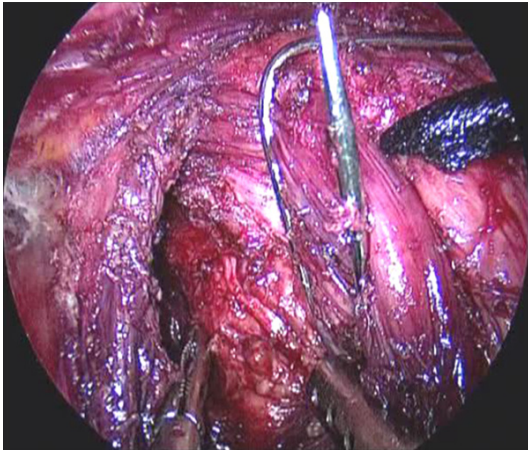


Figure 4. Recurrent laryngeal nerve distribution was exploration from sternocleidomastoid side direction under endoscopy.

appropriate surgical approach and extent of thyroidectomy. The safety and benefits-risk hazard should be emphasized in communication with patients and their relatives in valid document.

The main difficulty during the secondary operation of SET is the tough scar adhesion induced by the original operation, which makes it challenging to separate the tissue and establish a surgical field in the cervicothoracic region. Therefore, many scholars advocate that the interval time of secondary operation is appropriate within one week or three months of the first operation [10]. The mentioned timing is beneficial for the anatomical separation and for reducing the injury to the operative site. The two pathways in SET surgery were selected by our practical experience with establishing the endoscopic operation space. The central isthmus pathway was selected in patients in whom the isthmus had been preserved during the original operation. The middle of the trachea can be viewed as the anatomical landmark when the isthmus is divided [4]. In addition, further separation of the two sides reveals the lesion of the remnant thyroid gland. The sternocleidomastoid side pathway was chosen when the central thyroid isthmus gland had been resected during the first operation and the adhesion was tough to dissect. The subcutaneous operative site of the neck can be expanded in the lateral direction using a harmonic scalpel. The sternocleidomastoid side area between the sternocleidomastoid and the anterior cervi-

cal belt-shaped muscle were separated because this area is rarely separated during the original operation and therefore lacks adhesions. Following this sternocleidomastoid side pathway, the lesions can be revealed in the remnant thyroid. From our experience, relapsed tumor in the thyroid is usually located in the lateral border or the terminal point of the thyroid. The sternocleidomastoid side pathway is easily separated. The procedure in this pathway can maintain a distance to the tough adhesion of the thyroid isthmus and avoid the division of the anterior jugular muscles. The operative area is enlarged and appropriate for remnant thyroid resection and recurrent laryngeal nerve exploration from the sternocleidomastoid side direction under endoscopy (**Figure 4**). In addition, further deep cervical lymph nodes can be dissected conveniently through this pathway in patients with thyroid malignancies.

Injury to the recurrent laryngeal nerve is a serious postoperative complication and the incidence of nerve injury in secondary operation of the thyroid is increased based on a retrospective study [11]. Protection of the recurrent laryngeal nerve is keypoints in secondary operation of SET surgery [12]. Based on our experience of SET surgery, intraoperative neuromonitoring provides help with exploring the distribution of the recurrent laryngeal nerve. Due to the anatomical destruction and adhesion during the first operation, the recurrent laryngeal nerve is difficult to explore during the secondary operation. Recurrent laryngeal nerve distribution and activity can be clarified according to the electromyographic waveform signal with stimulating current [13]. The lesions in the remnant thyroid could be resected if they cling to the gland tissue to maintain an adequate distance from the recurrent laryngeal nerve. In our practice of secondary operation of SET, no recurrent laryngeal nerve injuries occurred due to the selection of mentioned surgical approach pathways and real-time intraoperative neuromonitoring.

Hypoparathyroidism is another serious postoperative complication in thyroid surgery [14]. Parathyroid dysfunction will be aggravated by the secondary thyroid surgery. Preservation of the parathyroid is necessary in reducing postoperative permanent hypoparathyroidism in secondary operation of SET surgery. In situ

preservation of the parathyroid gland and its blood supply is an effective way to prevent postoperative permanent hypothyroidism and hypocalcemia during secondary SET surgery [15]. The bilateral superior parathyroid gland location is relative regular and located near the vessels of the superior thyroid peduncle. Therefore, in our secondary operation of SET surgery practice, the identification of the superior parathyroid in the thyroid peduncle and preservation of its blood supply from the posterior ramus of the superior hyoid artery is an essential step in preserving parathyroid function. The inferior thyroid artery is responsible for eighty percent of the blood supply of the parathyroid gland, and the maximum degrees of preservation of the inferior parathyroid is necessary by avoiding the ligation of the main branch of the inferior thyroid arterial and ligation of the grade three branch attached to the gland tissue [16]. Finally, the postoperative identification of the parathyroid in the resected specimen and pathological diagnosis by perioperative frozen section for autologous parathyroid transplantation into the sternocleidomastoid is another treatment for reducing postoperative permanent hypothyroidism after secondary SET surgery [17].

Cervical lymphadenectomy is a vital component of surgery in thyroid malignancies. The viewpoint of routine central region lymph node dissection is accepted for the treatment of thyroid papillary microcarcinoma in SET surgery [6, 18]. Preventive deep cervical lymph node resection has not been advocated in lymph node negative (cN0) thyroid carcinoma patients, but it can be considered for palpable lymph node positive (cN1) patients with functional neck lymph node dissection. Caron *et al* proposed selective deep cervical lymph node dissection for cN1 thyroid carcinoma patients besides the II and IV compartments [19, 20]. The NCCN guidelines of thyroid carcinoma in the 2013 edition indicate that the compartments II and V deep cervical lymph nodes should be resected if there is evidence of lymph node metastasis or invasiveness of tumor based on clinical presentation or the metastasis to the deep cervical lymph nodes of compartment III [21]. The conventional procedures of modified radical neck dissection (MRND) and selective neck lymph node dissection (SLND) resulted in a long L-shaped scar after conven-

tional surgery [22]. Scarless endoscopic selective deep cervical lymph node resection for the treatment of T1 low risk thyroid carcinoma patients result in good cosmetic appearance based on follow-up investigation [6, 23]. The scarless endoscopic selective deep cervical ipsilateral compartments II, III, IV lymph node resection was successfully performed in our reported secondary operation of SET; however, the long-term efficacy may need follow-up investigation.

The successful practice in our six secondary operations of SET surgery shows that the selection of an appropriate surgical approach pathway and the recurrent laryngeal nerve detection through intraoperative neuromonitoring are beneficial for the operative success. Secondary operation of SET surgery still can be performed safely and is feasible in patients with a strong cosmetic demand. Secondary operation of SET surgery can be performed by the team with skillful SET surgical technique and strict inclusive criteria. Recently, three-dimensional endoscopic technology has been used to restore the stereoscopic structure of the operative field and may have the advantage of recurrent laryngeal nerve exploration and parathyroid preservation [7]. Endoscopic thyroidectomy through the oral vestibular approach (ETOVA) has been reported lately by Wang *et al* to be safe, efficacious and with good cosmetic results [24]. It may also be selected in the secondary operation of SET surgery.

Our experience with the secondary operation of SET surgery in six patients based on more than three thousand SET experiences showed that the surgical risk was little higher than during the first time, but the postoperative complications can be alleviated by taking protective measures, and we also stressing the importance of preoperative accurate diagnosis of thyroid nodules through ultrasound-guided fine needle aspiration in the first time operation [25]. Improving the perioperative frozen section diagnosis quality and accuracy is another way to reduce the secondary operation rate of SET surgery. Our preliminary report in secondary operation of SET surgery is our initial experience in attempting treatment of thyroid diseases. It still have its feasibility of the secondary operation of SET for the minority patients with esthetic demands. Its limitation due to risk

could be follow-up investigation by randomized clinical trials for confirmation.

Acknowledgements

This work was supported by surgical endoscopic thyroid center team work of 2nd affiliated hospital of Zhejiang university school of medicine. This study was also supported by Nature Science Fund of Zhejiang Province (Grant No. Y16H030020).

Disclosure of conflict of interest

None.

Address correspondence to: Ping Wang, Department of General Surgery, 2nd Affiliated Hospital of Zhejiang University School of Medicine, No. 88 of Jiefang Road, Hangzhou 310009, China. E-mail: zjuth@zju.edu.cn

References

- [1] Gagner M. Endoscopic subscarlessparathyroidectomy in patients with primary hyperparathyroidism. *Br J Surg* 1996; 83: 875.
- [2] Hüscher CS, Chiodini S, Napolitano C, Recher A. Endoscopic right thyroid lobectomy. *Surg Endosc* 1997; 11: 877.
- [3] Ciftci F, Sakalli E, Abdurrahman I. Total versus bilateral subtotal thyroidectomy for benign multi-nodular goiter. *Int J Clin Exp Med* 2015; 8: 4596-4600.
- [4] Dionigi G, Boni L, Duran-Poveda M. Evolution of endoscopic thyroidectomy. *Surgical Endoscopy* 2011; 25: 3951-3952.
- [5] Miccoli P, Materazzi G, Berti P. Minimally invasive thyroidectomy in the treatment of well differentiated thyroid cancer: indications and limits. *Curr Opin Otolaryngol Head Neck Surg* 2010; 18: 114-118.
- [6] Li Z, Wang P, Wang Y, Xu S, Cao L, Que R, Zhou F. Endoscopic lateral neck dissection via breast approach for papillary thyroid carcinoma: a preliminary report. *Surg Endosc* 2011; 25: 890-896.
- [7] Mao LN, Wang P, Li ZY, Wang Y, Song ZY. Risk factor analysis for central nodal metastasis in papillary thyroid carcinoma. *Oncol Lett* 2015; 9: 103-107.
- [8] Christopher Lee, Brendan C, Stack JR. Intraoperative neuromonitoring during thyroidectomy. *Exp Rev Anticancer Ther* 2011; 11: 1417-1427.
- [9] Heineman TE, Kadkade P, Kutler DI, Cohen MA, Kuhel WI. Parathyroid Localization and Preservation during Transcervical Re5section of Substernal Thyroid Glands. *Otolaryngol Head Neck Surg* 2015; 4: 1-5.
- [10] Erbil Y, Bozbora A, Ademoglu E, Salmaslioglu A, Ozarmagan S. Is timing important in thyroid reoperation? *J Otolaryngol Head Neck Surg* 2008; 37: 56-64.
- [11] Lee CY, Long KL, Eldridge RJ, Davenport DL, Sloan DA. Preoperative laryngoscopy in thyroid surgery: Do patients' subjective voice complaints matter? *Surgery* 2014; 156: 1477-1482.
- [12] Mohil RS, Desai P, Narayan N, Sahoo M, Bhatnagar D, Venkatachalam VP. Recurrent laryngeal nerve and voice preservation: routine identification and appropriate assessment-two important steps in thyroid surgery. *Ann R Coll Surg Engl* 2011; 93: 49-53.
- [13] Dralle H, Sekulla C, Lorenz K, Brauckhoff M, Machens A. The German IONM Study Group. Intraoperative monitoring of the recurrent laryngeal nerve in thyroid surgery. *World J Surg* 2008; 32: 1358-1366.
- [14] Edafe O, Prasad P, Harrison BJ, Balasubramanian SP. Incidence and predictors of post-thyroidectomy hypocalcaemia in a tertiary endocrine surgical unit. *Ann R Coll Surg Engl* 2014; 96: 219-223.
- [15] Lorente-Poch L, Sancho JJ, Ruiz S, Sitges-Serra A. Importance of in situ preservation of parathyroid glands during scarless thyroidectomy. *Br J Surg* 2015; 102: 359-367.
- [16] Park YM, Shin SC, Lee WY. Surgical technique for preservation of inferior parathyroid gland. *Otolaryngology-Head and Neck Surgery* 2014; 151: 181.
- [17] Selberherr A, Scheuba C, Riss P, Niederle B. Postoperative hypoparathyroidism after thyroidectomy: efficient and cost-effective diagnosis and treatment. *Surgery* 2015; 157: 349-353.
- [18] White ML, Doherty GM. Level VI lymph node dissection for papillary thyroid cancer. *Minerva Chir* 2007; 62: 383-393.
- [19] Caron NR, Tan YY, Ogilvie JB, Triponez F, Reiff ES, Kebebew E, Duh QY, Clark OH. Selective modified radical neck dissection for papillary thyroid cancer- is level I, II and V dissection always necessary? *World J Surg* 2006; 30: 833-840.
- [20] Sugitani I, Fujimoto Y, Yamada K, Yamamoto N. Prospective outcomes of selective lymph node dissection for papillary thyroid carcinoma based on preoperative ultrasonography. *World J Surg* 2008; 32: 2494-2502.
- [21] National comprehensive cancer network. NCCN clinical practice guideline in oncology (NCCN guideline™) thyroid carcinoma (2013 version).
- [22] Kang SW, Jeong JJ, Yun JS, Sung TY, Lee SC, Lee YS, Nam KH, Chang HS, Chung WY, Park CS. Gasless endoscopic thyroidectomy using

- trans-axillary approach: surgical outcome of 581 patients. *Endocr J* 2009; 56: 361-369.
- [23] Wilhelm D, Reiser S, Kohn N, Witte M, Leiner U, Mühlbach L, Ruschin D, Reiner W, Feussner H. Comparative evaluation of HD 2D/3D laparoscopic monitors and benchmarking to a theoretically ideal 3D pseudodisplay: even well-experienced laparoscopists perform better with 3D. *Surg Endosc* 2014; 28: 2387-2397.
- [24] Wang CC, Zhai H, Liu W, Li J, Yang J, Hu Y, Huang J, Yang W, Pan Y, Ding H. Thyroidectomy: A novel endoscopic oral vestibular approach. *Surgery* 2014; 155: 33-38.
- [25] Perros P, Boelaert K, Colley S, Evans C, Evans RM, Gerrard Ba G, Gilbert J, Harrison B, Johnson SJ, Giles TE, Moss L, Lewington V, Newbold K, Taylor J, Thakker RV, Watkinson J, Williams GR; BritishThyroid Association. Guidelines for the management of thyroid cancer. *Clin Endocrinol (Oxf)* 2014; 81: 1-122.